

Urinothorax: A rare cause of severe respiratory distress

Alka Chandra, Amrendra Pathak, Anu Kapur, Neha Russia, Nikhil Bhasin

Abstract

A case of massive right pleural effusion in a postoperative patient of percutaneous nephrolithotomy leading to severe respiratory distress is reported. A high degree of clinical suspicion and prompt intervention by insertion of an intercostal drainage tube prevented the patient from going in to respiratory failure. The development of arrhythmias confused the picture increasing the morbidity of the patient. However, the patient was managed in an intensive care unit with intercostal chest tube insertion and antiarrhythmic agents. After correction of the specific cause of the effusion the intercostal tube was removed on the 4th day without further recurrence of the effusion.

Keywords: Percutaneous nephrolithotomy, pleural effusion, urinothorax

Access this article online

Website: www.ijccm.org

DOI: 10.4103/0972-5229.132501

Quick Response Code:



Introduction

The retroperitoneal leakage of urine resulting from a disruption/obstruction of the urinary tract is known as urinoma. The resultant retroperitoneal or intraperitoneal collection of urine finds a way across transdiaphragmatic barrier due to persistent high pressure. Therefore, a concomitant ipsilateral or bilateral pleural effusion should raise suspicion of urinothorax. Thoracocentesis followed by measurement of creatinine in the pleural fluid is a procedure to establish the true diagnosis.^[1] Initially, it was described by Corriere *et al.* in 1968 in their studies on ureteral obstruction in dogs.^[2] Nowadays, cases of urinothorax have been described in human patients. Increased awareness of this entity coupled with the availability of advanced imaging and scintigraphic techniques have resulted in the early diagnosis of urinothorax cases.^[3]

Case Report

A 65-year-old female patient developed chest pain and respiratory distress on the 2nd day of a

percutaneous nephrolithotomy (PCNL) done for lithiasic ureteral obstruction. Since, the patient had evident left bundle branch block in the preoperative electrocardiogram (ECG), was in evident respiratory distress and chest discomfort, a 12 lead ECG was done, which showed a paroxysmal supraventricular tachycardia. It was treated with amiodarone 5 mg/kg given through slow intravenous infusion and later with diltiazem 30 mg 3 times in a day. The troponin-T and creatine phosphokinase-MB were negative. On physical examination, there were markedly decreased breath sounds on the right side of chest with crepitations. The respiratory rate was 35/min, pulse 142/min and blood pressure 110/82 mm of Hg. Arterial blood gas analysis showed a type I respiratory failure with PO₂-50 mm Hg, PCO₂-33.3 mm Hg, pH-7.5, HCO₃-22.2 mmol/L, O₂ saturation 86%. The chest radiograph, as shown in Figure 1, revealed a large fluid collection with a collapsed right lung. Chest ultrasonography confirmed a pleural effusion. The patient was transferred to the intensive care unit for further management.

Thoracocentesis was performed which yielded 1.5 L of straw colored fluid with distinctive smell of urine. Fluid analysis revealed a total protein of 0.9 g/dL, pH 7.13, lactate dehydrogenase (LDH) 868 U/L, glucose 28 mg/dL, creatinine 11 mg/dL and urea of 115 mg/dL with a cellularity of 2800/mm³. The bacteriological

From: Departments of Urology, and Anaesthesia and critical care, Hindurao Hospital, New Delhi, India

Correspondence: Dr. Alka Chandra, 802, South Delhi Apartment, Sector 4, Dwarka, New Delhi, India.
E-mail: dralkadelhi@yahoo.co.in

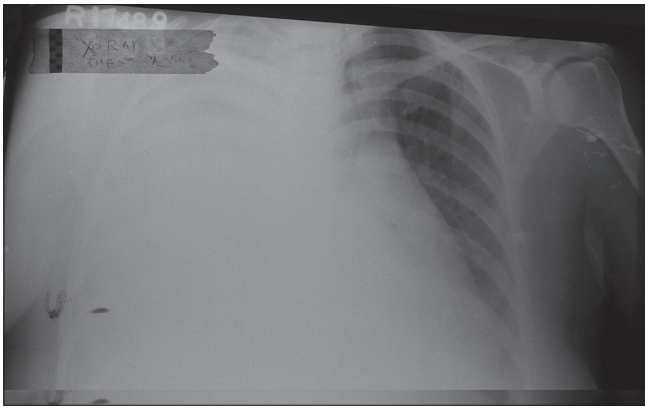


Figure 1: Right side massive pleural effusion

examination of the fluid revealed no micro-organism in Gram's stain and no acid fast bacilli in Ziehl-Nielsen stain. The fluid culture was negative. The serum LDH levels were 439 U/L, blood urea 115 mg/dL and serum creatinine of 3.4 mg/dL. The routine examination of urine was normal, but the microscopy revealed plenty of red blood cells and pus cells. The urine culture was negative. The electrolytes showed no disarrangements. Ultrasonography revealed a persistent effusion and an intercostal chest tube (ICD) was inserted allowing the drainage of 3 L of fluid. A central venous cannulation was done to guide fluid therapy. The patient had a single functional kidney in which PCNL was done. The blood urea and serum creatinine levels started rising and the patient developed oliguria. A decision was made to put a Double J (DJ) stent and change the ureteric catheter to correct oliguria. In the operation theater, it was found that the ureteric catheter had slipped from its position which was the cause for obstruction and recurrent collection. The respiratory distress subsided and arrhythmias secondary to the hypoxemia were controlled after DJ stenting. The ICD was removed on the 4th day when there was a full expansion of lung as shown in the Figure 2. The patient was transferred to the ward and was discharged home on the 10th day.

Discussion

Urinothorax can be divided into two categories. (1) Obstructive urinothorax due to bilateral obstructive uropathy and (2) traumatic urinothorax due to unilateral traumatic injury of the urinary system, mostly iatrogenic.^[4] It is a rare cause of transudative pleural effusion secondary to obstructive uropathy. There are two theories under debate concerning the mechanisms responsible for the transdiaphragmatic evasion of urine. (1) Urine may travel through lymphatic drainage into pleural space or (2) retroperitoneal urine firstly enters the peritoneal cavity and afterwards

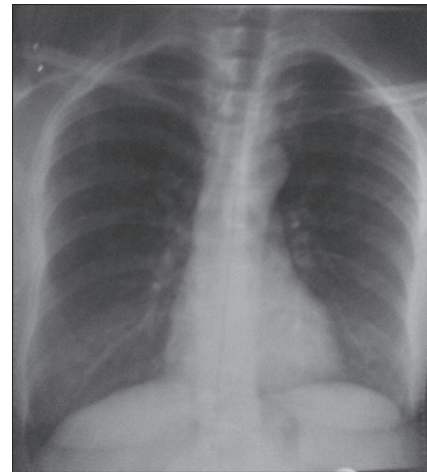


Figure 2: Full expansion of lung

travels through direct transdiaphragmatic passage into the pleural cavity.^[5] In general, the patient with urinothorax have low pH and high LDH levels, resulting in misinterpretation of the effusion being exudative. The average pleural fluid-to-serum creatinine ratio is in the range of 1.09-19.8.^[6] Pleural effusion can occur due to infections, malignancies, and congestive heart failure. Urinothorax is clearly an uncommon cause of pleural effusion.^[7]

Our patient presented with severe respiratory distress after undergoing PCNL. The chest radiograph revealed a massive pleural effusion and thoracentesis led to high suspicion of urinothorax due to a distinctive urine smell. An ICD was put under ultrasonographic guidance due to recurrent effusion. The distinctive urine smell and its subsequent biochemical analysis-with characteristic of transudate except for the high LDH levels-and the pleural fluid-to-serum creatinine ratio of 3.2 confirmed the diagnosis of urinothorax. Renal scintigraphy with technetium-99 m DTPA, technetium 99 m ethylene dicycysteine or with technetium 99 m mercaptoacetyltryglycerine-3 can demonstrate any extravasation of urine from the region of the kidney or ureter.^[5,8] Due to hemodynamic instability our patient could not be subjected to further investigation. The fluid in urinothorax is usually straw-colored with a distinctive ammoniacal smell. In the majority of cases, the fluid is transudative according to Light's criteria, with biochemical features of low glucose, low protein, and low pH, but elevated LDH levels.^[9,10] The most important biochemical parameter is the pleural fluid creatinine-to-serum creatinine ratio which is >1 and mostly >10.^[3] Urinothorax should be included in the differential diagnosis of pleural effusion in patients with a recent urinary tract disorder even with features of pleural exudate.^[11] The correction of the underlying cause

usually leads to resolution of urinorhax; however, in the present case, despite the pleural drainage with a thoracostomy tube, repeated collection occurred due to the unnoticed slippage of the ureteric catheter that lead to oliguria and rise in blood urea and serum creatinine levels. Insertion of a DJ stent allowed the resolution of the problem and complete lung reexpansion.

Conclusion

The physicians should include urinorhax in the differential diagnosis of pleural effusions, particularly in patients that underwent kidney or ureteral surgical procedures such as extracorporeal shock wave lithotripsy, PCNL, or ureterorenoscopy. As most of the cases can be managed only with therapeutic thoracocentesis and resolution of the underlying problem, aggressive chest tube drainage of voluminous effusion with respiratory failure is only rarely needed.

References

1. Gurtner B. Urine in the wrong place: Urothorax. *Schweiz Rundsch Med Prax* 1994;83:30-5.

2. Corriere JN Jr, Miller WT, Murphy JJ. Hydronephrosis as a cause of pleural effusion. *Radiology* 1968;90:79-84.

3. Handa A, Agarwal R, Aggarwal AN. Urinorhax: An unusual cause of pleural effusion. *Singapore Med J* 2007;48:e289-92.

4. Garcia-Pachon E, Romero S. Urinorhax: A new approach. *Curr Opin Pulm Med* 2006;12:259-63.

5. Bhattacharya A, Venkataramarao SH, Kumar S, Mittal BR. Urinorhax demonstrated on 99mTc ethylene dieysteine renal scintigraphy. *Nephrol Dial Transplant* 2007;22:1782-3.

6. Garcia-Pachon E, Padilla-Navas I. Urinorhax: Case report and review of the literature with emphasis on biochemical diagnosis. *Respiration* 2004;71:533-6.

7. Doerr CH, Miller DL, Ryu JH. Chylothorax. *Semin Respir Crit Care Med* 2001;22:617-26.

8. Jelic S, Sampogna RV. Detection of unrecognized urinorhax with renal scintigraphy. *Kidney Int* 2009;76:353.

9. Tortora A, Casciani E, Kharrub Z, Gualdi G. Urinorhax: An unexpected cause of severe dyspnea. *Emerg Radiol* 2006;12:189-91.

10. Light RW, Macgregor MI, Luchsinger PC, Ball WC Jr. Pleural effusions: The diagnostic separation of transudates and exudates. *Ann Intern Med* 1972;77:507-13.

11. Mora RB, Silvente CM, Nieto JM, Cuervo MA. Urinorhax: Presentation of a new case as pleural exudate. *South Med J* 2010;103:931-3.

How to cite this article: Chandra A, Pathak A, Kapur A, Russia N, Bhasin N. Urinorhax: A rare cause of severe respiratory distress. *Indian J Crit Care Med* 2014;18:320-2.

Source of Support: Nil, **Conflict of Interest:** None declared.

Author Help: Reference checking facility

The manuscript system (www.journalonweb.com) allows the authors to check and verify the accuracy and style of references. The tool checks the references with PubMed as per a predefined style. Authors are encouraged to use this facility, before submitting articles to the journal.

- The style as well as bibliographic elements should be 100% accurate, to help get the references verified from the system. Even a single spelling error or addition of issue number/month of publication will lead to an error when verifying the reference.
- Example of a correct style
Sheahan P, O'leary G, Lee G, Fitzgibbon J. Cystic cervical metastases: Incidence and diagnosis using fine needle aspiration biopsy. *Otolaryngol Head Neck Surg* 2002;127:294-8.
- Only the references from journals indexed in PubMed will be checked.
- Enter each reference in new line, without a serial number.
- Add up to a maximum of 15 references at a time.
- If the reference is correct for its bibliographic elements and punctuations, it will be shown as CORRECT and a link to the correct article in PubMed will be given.
- If any of the bibliographic elements are missing, incorrect or extra (such as issue number), it will be shown as INCORRECT and link to possible articles in PubMed will be given.