

ATRT of lateral ventricle in a child: A Rare Tumor at a Very Rare Location

Abstract

Atypical teratoid/rhabdoid tumors (AT/RTs) of infancy are highly malignant central nervous system neoplasms that are most commonly seen during the first 2 years of life with limited therapeutic options. To date, only two cases have been described in the lateral ventricle. A 4-year-old boy presented with a 4-month history of increased intracranial pressure. Cerebral magnetic resonance imaging (MRI) revealed a huge intraventricular tumor, occupying the entire temporal horn and the body of the left lateral ventricle. The boy was operated through a left temporal transventricular approach with gross total removal of the lesion. The histopathological diagnosis was an AT/RT. The infant underwent adjuvant chemotherapy and radiation therapy. The 1-year MRI of control showed a local recurrence of the tumor. Then after, Gamma Knife radiosurgery was performed because of the small volume and the deep location of the lesion. At the 3-month follow-up, the MRI showed a significant growth of the tumor volume, and the child was given additional adjuvant chemotherapy. Unfortunately, he died 9 months later. AT/RT of the lateral ventricle is a very rare tumor in children, associated with a poor prognosis in spite of multimodal treatment. Gamma knife surgery (GKS) was rarely reported as a treatment modality of AT/RT. The aim of this work is to discuss about the rarity of this tumor and the best treatment strategy to improve prognosis.

Keywords: Atypical teratoid/rhabdoid tumor, children, lateral ventricle, radiosurgery, surgery

Introduction

Atypical teratoid/rhabdoid tumor(AT/RT) is a rare, highly aggressive tumor of embryonic origin, comprising approximately 3% of pediatric brain tumors and 10% of central nervous system (CNS) tumors in infants, with technical difficulties in total excision.^[1]

Overall, these tumors are usually seen in the cerebellum or the cerebrum, with an extremely rare incidence in the lateral ventricle. To date, only two cases were reported in the pediatric population.^[2,3] Their characteristics of fast growth, speedy mortal development, young age at diagnosis, and propensity to disseminate through the cerebrospinal fluid pathways all contribute to the poor prognosis characterizing these tumors.^[4,5]

Herein, we report a lateral ventricle AT/RT in a child. The aim is to highlight the radiological features of this rare tumor and to underline the difficulties faced in its management and surgical decision-making. Currently, there are no guidelines about the optimal management of AT/RT. However,

This is an open access journal, and articles are distributed under the terms of the Creative Commons Attribution-NonCommercial-ShareAlike 4.0 License, which allows others to remix, tweak, and build upon the work non-commercially, as long as appropriate credit is given and the new creations are licensed under the identical terms.

For reprints contact: reprints@medknow.com

multimodal treatment including surgery, chemotherapy, and radiation therapy is advocated. Nowadays, stereotactic radiosurgery (SRS) could represent a safe and effective treatment option for AT/RT, which aims to prolong survival and improve the quality of life of patients.

Case Report/Case Description

A 4-year-old boy, with an unremarkable past medical history, presented at our department complaining of 4-month history of increased intracranial pressure, without associated motor deficit, seizures, sensory loss, or fever.

On examination, the patient was fully conscious; pupils were equal and reactive to light bilaterally. The patient has had a normal tone and brisk deep tendon reflexes with no neurological deficit. Moreover, there was bilateral papilledema with no other cranial nerve involvement. Cerebral magnetic resonance imaging (MRI) revealed a huge intraventricular tumor, occupying the entire temporal horn and the body of the left lateral ventricle. This lobulated mass lesion (measuring approximately 48 × mm 47 mm × 57 mm), with heterogeneous

How to cite this article: Lakhdar F, Benzagmout M, Arkha Y, Chakour K, Chaoui ME. ATRT of lateral ventricle in a child: A rare tumor at a very rare location. *Asian J Neurosurg* 2020;15:225-9.

Submission: 05-05-2019 **Accepted:** 17-09-2019
Published: 25-02-2020

**Fayçal Lakhdar,
Mohammed
Benzagmout,
Yasser Arkha¹,
Khalid Chakour,
Mohammed El Faiz
Chaoui**

*Department of Neurosurgery,
Hassan II Hospital, University
Sidi Mohammed Ben
Abdellah, Fez, ¹Department
of Neurosurgery, Hopital
des Spécialités, University
Mohammed V of Medecine,
Rabat, Morocco*

Address for correspondence:

*Prof. Fayçal Lakhdar,
10, Rue Oulad Jerrar Souissi,
Rabat, BP 10100, Morocco.
E-mail: lakhdar.faycal@gmail.
com*

Access this article online

Website: www.asianjns.org

DOI: 10.4103/ajns.AJNS_128_19

Quick Response Code:



signal intensity, necrotic area, and contrast enhancement, was involving the inner wall of the lateral ventricle and extending to the mesiotemporal lobe [Figure 1].

The tumor was totally removed through a transtemporal transventricular approach. Intraoperatively, the lesion was soft, pink–gray in color, containing fleshy masses, and areas of hemorrhage and necrosis.

The histological study revealed sheets and clusters of undifferentiated small cells and rhabdoid cells, along with a mixture of epithelial components. There were areas showing typical rhabdoid cells with intracytoplasmic eosinophilic inclusions. Immunohistochemistry showed the loss of expression of nuclear integrase interactor 1 (INI1). Furthermore, both vimentin and epithelial membrane antigen (EMA) were positive [Figure 2].

The patient recovered well postoperatively without new neurological deficits. Cerebral MRI of control, performed 6 months later, showed no visible remaining tumor [Figure 3]. In addition, chest and abdominal computed tomography scan was negative for tumor, as was the whole-body bone scan, leaving the brain as the lone site of the disease. Spinal MRI was also negative for drop metastasis.

After the surgical resection, the patient received adjuvant radiotherapy (36 Gy/20 fractions/4 weeks) to the entire neuraxis associated to local boost (20 Gy/10 fractions/2 weeks) and four cycles of chemotherapy (cisplatin, cyclophosphamide, and vincristine). At the 1-year follow-up, the child was neurologically intact and meeting normal developmental milestones.

However, 1-year follow-up cerebral MRI showed local recurrence of the tumor [Figure 4a]. Radiosurgery gamma knife (GKS) was decided because of the small volume and the deep location of the lesion. The volumes of buds were, respectively, 2.1 cm³, 467 mm³, and 155 mm³; the treatment dose was 20 Gy at 50% isodose. Six months after GKS, the clinical outcome was good, and cerebral MRI demonstrates a significant reduction of the tumor [Figure 4b].

At the 9-month follow-up GKS, the MRI showed a massive growth of the tumor volume, and the child was referred for additional adjuvant chemotherapy [Figure 4c]. Unfortunately, he died 11 months after GKS, 23 months after tumor relevance.

Discussion

CNS AT/RT was first defined as a distinct clinical entity in 1987.^[1] However, it was recognized as embryonal Grade IV neoplasm by the World Health Organization in 1993 (14) and distinguished from primitive neuroectodermal tumors by Rorke *et al.* in 1996.^[6] Over the past few years, AT/RT has been increasingly recognized as an important tumor type in infants and children.^[7]

AT/RT accounts for 1%–2% of overall pediatric CNS tumors^[8] and constitutes as many as 20% of all embryonal tumors. Approximately 70% of all cases arise in infants younger than 1 year of age and over 90% of cases

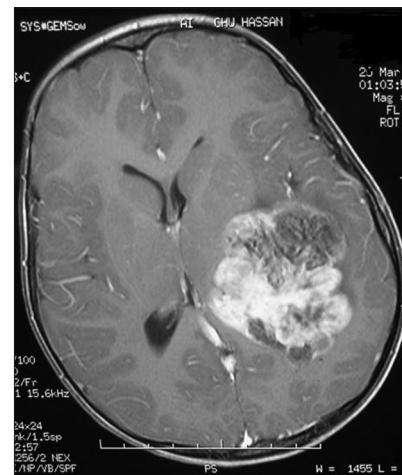


Figure 1: Axial cerebral magnetic resonance imaging in T1-weighted sequences with gadolinium showing a huge lesion of the left lateral ventricle with heterogeneous enhancement and a significant mass effect to the midline

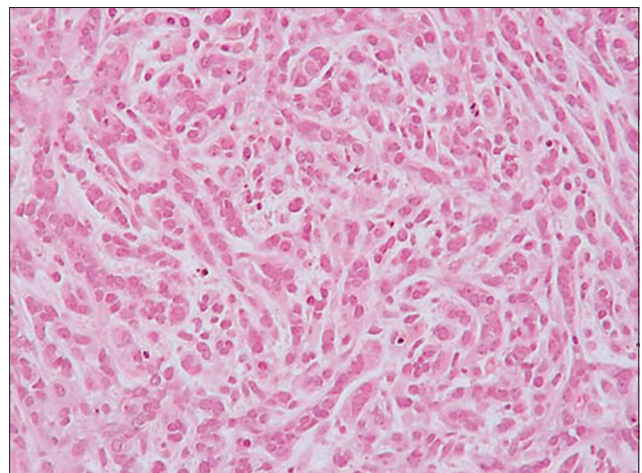


Figure 2: Hypercellular neoplasm with nuclear pleomorphism (hematoxylin and eosin) and loss of nuclear integrase interactor 1 immunostaining

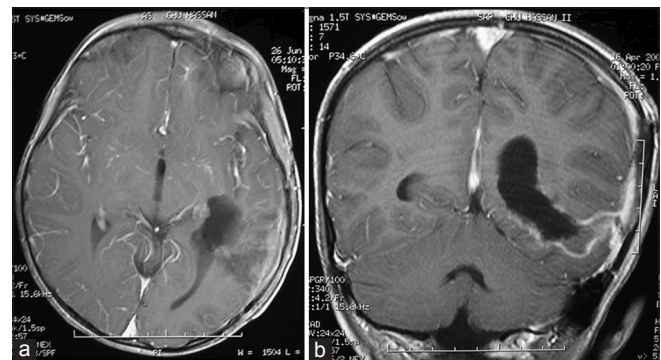


Figure 3: Contrast weighted T1 cerebral magnetic resonance imaging of control in axial (a) and coronal (b) view showing complete resection of the lesion with no residual tumor

occur before 3 years of age. In addition, CNS AT/RT is predominantly seen in males, with a male-to-female ratio of 2.7:1.^[9,10] Most reports suggest that the majority of AT/RT arise in the posterior fossa, with only about 40% of cases located in the cerebrum.^[11] Furthermore, according to the previous reports, the most common location of AT/RT was the cerebellum, comprising up to 73% of cases in children under the age of 3 years,^[1,12,13] and the less common site of this tumor within the CNS is the spinal cord.^[9] In contrast, some recent studies have demonstrated that supratentorial AT/RT is slightly more frequent, with a ratio of supratentorial to infratentorial tumors of 1.3:1.^[10,14]

In the supratentorial region, AT/RTs have been reported either in the cerebral cortex, the suprasellar area, and pineal region;^[13,15,16] those originating in the suprasellar compartment and pineal region might involve the ventricular system by direct extension. The pure intraventricular location of this tumor is very rare. To the best of our knowledge, only two pediatric cases of lateral ventricle AT/RT have been described in the literature.^[2,3] Indeed, Donovan *et al.* have reported the first AT/RT of the velum interpositum involving the lateral ventricle^[7] and the second one which looks strongly at our reported case.^[3] This uncommon location is challenging because of difficulties in surgical access and control of tumor vasculature and bleeding.

Overall, patients with AT/RT present with a short clinical history ranging from days to weeks with a median duration of 0.75 months.^[14] Our patient had a 4-month history of intracranial hypertension which might be explained by the ventricular location of the lesion.

Cerebral MRI is the imaging modality of choice for the diagnosis. On T1-weighted sequences, the tumor appears isointense containing hyperintense areas due to intratumoral bleeding. However, the tumor is heterogeneous on T2-weighted sequences, with a combination of hypointense to hyperintense areas, indicating a mixture of necrosis, hemorrhage, and cystic changes. Biswas *et al.*^[2] found cystic changes and calcification in 73.3% and 40% of AT/RT tumors, respectively. In addition, MR spectroscopy of AT/RT typically shows elevated levels of choline and decreased N-acetylaspartate. In our case, the enhanced T1 images showed heterogeneous enhancement of the tumor with intratumoral necrosis. Imaging characteristics are helpful in determining the differential diagnosis of common pediatric intraventricular tumors: choroid plexus tumors (papillomas and carcinomas) and subependymal giant cell, primitive neuroectoderm tumor or craniopharyngioma.

The pathogenesis of AT/RTs is not clearly understood, but a pluripotent cell with the ability to diverge into epithelial/mesenchymal cells has been suggested. Histologically, a subset of tumor cells demonstrated rhabdoid morphology with eccentric nuclei, including

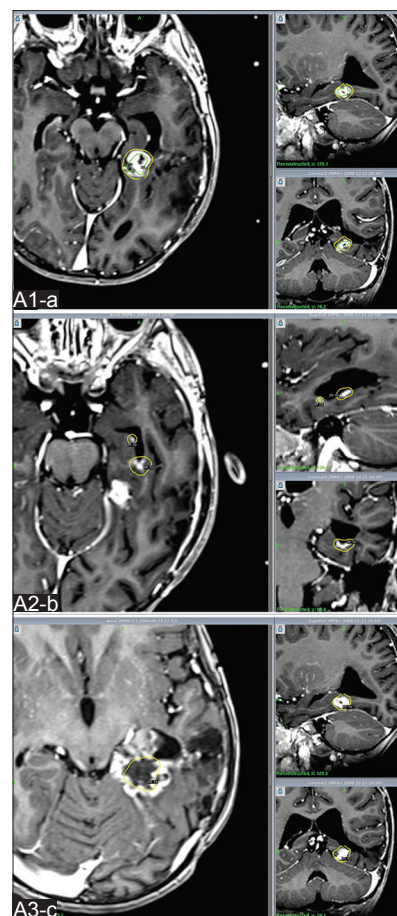


Figure 4: Gamma Knife radiosurgery for recurrent atypical teratoid rhabdoid tumor. (A1-a) Postoperative imaging follow-up at 12 months showing a local recurrence of the tumor and the treatment GKS. (A2-b) A 6-month follow-up after GKS showing significant reduction of the tumor. (A3-c) A 12-month follow-up magnetic resonance imaging demonstrating a new relapse of the tumor

features of neuroectodermal and mesenchymal cells displaced by abundant eosinophilic cytoplasm with eccentric nuclei.^[6]

Currently, the most definitive diagnosis of AT/RTs is made by demonstrating the inactivation or deletion of SMARCB1/INI and loss of expression in tumor cell nuclei, along with focal positivity for EMA and smooth muscle actin, through immunohistochemistry or fluorescence in situ hybridization.^[17] Recent molecular studies have revealed that in most AT/RTs, the INI1 (hSNF5/SMARCB1) gene is located in chromosome band 22q11.2;^[1,18] the presence of the characteristic loss of INI1 immunoreactivity is crucial to the diagnosis.^[3]

To date, no specific guidelines have been established in the management of AT/RTs. However, a multimodal approach including gross surgical resection coupled with focal RT associated or not to concurrent combined modality treatment (CMT) tended to improve the global prognosis of these lesions. Total resection remains often difficult owing to the large size of the tumor, surrounding infiltration of the brain structures, and young age at diagnosis. Studies

by Biswas *et al.*^[2] and Lafay-Cousin *et al.*^[15] demonstrated significant improvement in the overall survival rate after gross total resection, as was performed in our case, compared with subtotal/near-total resection.

In addition, postoperative local RT with 54 Gy in 1.8 Gy daily fractions to the tumor bed with 1-cm safety margins is a tolerable treatment for patients with cerebral AT/RT. However, combined treatment including focal craniospinal radiation with/without concurrent CMT tended to do better globally in relative terms.^[8,19]

Indeed, aggressive CMT regimens have been described in the literature with wide-ranging agents such as methotrexate solely or high-dose chemotherapy (HDC) combining diverse agents such as cyclophosphamide/topotecan, carboplatin/thiotepa, or cyclophosphamide/carboplatin/thiotepa.^[20] Moreover, neoadjuvant CMT has been shown to decrease intraoperative blood loss and tumor size; conversely, it increases fibrosis of the tumor as well as collagenization of blood vessels.^[21,22] Recently, Casaos *et al.* establish that ribavirin is effective against AT/RT by decreasing tumoral cell growth and dissemination and could represent a new therapeutic option for children with this deadly disease.^[5] In addition, intrathecal chemotherapy can also be pursued in young children (<3 years old) or those with contraindications to radiotherapy. However, it is not as effective as CMT/RT combination.^[14]

Nowadays, GKS seems to be a safe and effective treatment for AT/RT, even in the pediatric population.^[23,24] In fact, Spina *et al.* results^[22] are encouraging in terms of local control, even if they did not demonstrate that GKS is effective in controlling the systemic disease. Indeed, SRS can be used in case of recurrence or small and deep-seated AT/RT lesions; it can be used also as a salvage modality in previously irradiated tumors and may provide a radiobiologic advantage. Hirth *et al.*^[12] reported a patient who survived 6 years after receiving a multimodal treatment regimen of adjuvant CMT and radiosurgery.^[17] Nevertheless, further studies are needed to demonstrate the efficiency of radiosurgery in managing AT/RT in the multimodal approach.

The median survival for AT/RT in infants is 6–10 months,^[2,4,19] but long-term survival is possible in some cases with aggressive adjuvant therapy.^[2,14,15,24,25,26] In our case, multimodal treatment including GKS has allowed a longer survival (23 months). Although numerous researchers suggested that gross total surgical resection associated to radiation and/or CMT were positive factors for better survival,^[11,27] some reports showed that upfront radiation therapy did not confer survival benefits, and that HDC was more strongly associated with survival benefits than conventional therapy.^[28] Finally, it is worthwhile to note that all of the aforementioned strategies have demonstrated marginal success in increasing patient survival, but the overall prognosis of AT/RTs remains poor.

Conclusion

Despite multimodal treatment strategies, AT/RT of the lateral ventricle in children remains extremely malignant with a very high rate of morbidity and mortality, elucidating the poor prognosis in most cases. Given its rarity and dismal outcome, this enigmatic tumor should be kept in mind in the differential diagnosis of malignant brain tumors, especially in childhood.

Declaration of patient consent

The authors certify that they have obtained all appropriate patient consent forms. In the form the patient(s) has/have given his/her/their consent for his/her/their images and other clinical information to be reported in the journal. The patients understand that their names and initials will not be published and due efforts will be made to conceal their identity, but anonymity cannot be guaranteed.

Financial support and sponsorship

Nil.

Conflicts of interest

There are no conflicts of interest.

References

- Bhattacharjee M, Hicks J, Langford L, Dauser R, Strother D, Chintagumpala M, *et al.* Central nervous system atypical teratoid/rhabdoid tumors of infancy and childhood. *Ultrastruct Pathol* 1997;21:369-78.
- Biswas A, Julka PK, Bakhshi S, Suri A, Rath GK. Intracranial atypical teratoid rhabdoid tumor: Current management and a single institute experience of 15 patients from North India. *Acta Neurochir (Wien)* 2015;157:589-96.
- Burger PC, Yu IT, Tihan T, Friedman HS, Strother DR, Kepner JL, *et al.* Atypical teratoid/rhabdoid tumor of the central nervous system: A highly malignant tumor of infancy and childhood frequently mistaken for medulloblastoma: A Pediatric Oncology Group Study. *Am J Surg Pathol* 1998;22:1083-92.
- Buscariollo DL, Park HS, Roberts KB, Yu JB. Survival outcomes in atypical teratoid rhabdoid tuAq1mor for patients undergoing radiotherapy in a surveillance, epidemiology, and end results analysis. *Cancer* 2012;118:4212-9.
- Casaos J, Huq S, Lott T, Felder R, Choi J, Gorelick N, *et al.* Ribavirin as a potential therapeutic for atypical teratoid/rhabdoid tumors. *Oncotarget* 2018;9:8054-67.
- Rorke LB, Packer RJ, Biegel JA. Central nervous system atypical teratoid/rhabdoid tumors of infancy and childhood: Definition of an entity. *J Neurosurg* 1996;85:56-65.
- Donovan DJ, Smith AB, Petermann GW. Atypical teratoid/rhabdoid tumor of the velum interpositum presenting as a spontaneous intraventricular hemorrhage in an infant: Case report with long-term survival. *Pediatr Neurosurg* 2006;42:187-92.
- Elsayad K, Kriz J, Samhoury L, Haverkamp U, Straeter R, Stummer W, *et al.* Long-term survival following additive radiotherapy in patients with atypical teratoid rhabdoid tumors. *Strahlenther Onkol* 2016;192:569-81.
- Ginn KF, Gajjar A. Atypical teratoid rhabdoid tumor: Current therapy and future directions. *Front Oncol* 2012;2:114.
- Hilden JM, Meerbaum S, Burger P, Finlay J, Janss A,

- Scheithauer BW, *et al.* Central nervous system atypical teratoid/rhabdoid tumor: Results of therapy in children enrolled in a registry. *J Clin Oncol* 2004;22:2877-84.
11. Hilden JM, Watterson J, Longee DC, Moertel CL, Dunn ME, Kurtzberg J, *et al.* Central nervous system atypical teratoid tumor/rhabdoid tumor: Response to intensive therapy and review of the literature. *J Neurooncol* 1998;40:265-75.
 12. Hirth A, Pedersen PH, Wester K, Mörk S, Helgestad J. Cerebral atypical teratoid/rhabdoid tumor of infancy: Long-term survival after multimodal treatment, also including triple intrathecal chemotherapy and gamma knife radiosurgery – Case report. *Pediatr Hematol Oncol* 2003;20:327-32.
 13. Karnes PS, Tran TN, Cui MY, Bogenmann E, Shimada H, Ying KL. Establishment of a rhabdoid tumor cell line with a specific chromosomal abnormality, 46,XY,t(11;22)(p15.5;q11.23). *Cancer Genet Cytogenet* 1991;56:31-8.
 14. Kleihues P, Louis DN, Scheithauer BW, Rorke LB, Reifenberger G, Burger PC, *et al.* The WHO classification of tumors of the nervous system. *J Neuropathol Exp Neurol* 2002;61:215-25.
 15. Lafay-Cousin L, Hawkins C, Carret AS, Johnston D, Zelcer S, Wilson B, *et al.* Central nervous system atypical teratoid rhabdoid tumours: The Canadian paediatric brain tumour consortium experience. *Eur J Cancer* 2012;48:353-9.
 16. Li F, Gui Q, Piao Y. Primary supratentorial atypical teratoid/rhabdoid tumor in children: A report of two cases. *J Child Neurol* 2013;28:399-403.
 17. Raisanen J, Biegel JA, Hatanpaa KJ, Judkins A, White CL, Perry A. Chromosome 22q deletions in atypical teratoid/rhabdoid tumors in adults. *Brain Pathol* 2005;15:23-8.
 18. Ren YM, Wu X, You C, Zhang YK, Li Q, Ju Y. Multimodal treatments combined with gamma knife surgery for primary atypical teratoid/rhabdoid tumor of the central nervous system: A single-institute experience of 18 patients. *Childs Nerv Syst* 2018;34:627-38.
 19. Fleming AJ, Hukin J, Rassekh R, Fryer C, Kim J, Stemmer-Rachamimov A, *et al.* Atypical Teratoid Rhabdoid Tumors (ATRTs): The British Columbia's children's hospital's experience, 1986-2006. *Brain Pathol* 2012;22:625-35.
 20. Severino M, Schwartz ES, Thurnher MM, Rydland J, Nikas I, Rossi A, *et al.* Congenital tumors of the central nervous system. *Neuroradiology* 2010;52:531-48.
 21. Ostrom QT, de Blank PM, Kruchko C, Petersen CM, Liao P, Finlay JL, *et al.* Alex's lemonade stand foundation infant and childhood primary brain and central nervous system tumors diagnosed in the United States in 2007-2011. *Neuro Oncol* 2015;16 Suppl 10:x1-36.
 22. Spina A, Gagliardi F, Boari N, Bailo M, Mortini P. Does stereotactic radiosurgery positively impact the local control of atypical teratoid rhabdoid tumors? *World Neurosurg* 2017;104:612-8.
 23. Tekautz TM, Fuller CE, Blaney S, Fouladi M, Broniscer A, Merchant TE, *et al.* Atypical teratoid/rhabdoid tumors (ATRT): Improved survival in children 3 years of age and older with radiation therapy and high-dose alkylator-based chemotherapy. *J Clin Oncol* 2005;23:1491-9.
 24. Thatikunta M, Mutchnick I, Elster J, Thompson MP, Huang MA, Spalding AC, *et al.* Neoadjuvant chemotherapy for atypical teratoid rhabdoid tumors: Case report. *J Neurosurg Pediatr* 2017;19:546-52.
 25. von Hoff K, Hinkes B, Dannenmann-Stern E, von Bueren AO, Warmuth-Metz M, Soerensen N, *et al.* Frequency, risk-factors and survival of children with atypical teratoid rhabdoid tumors (AT/RT) of the CNS diagnosed between 1988 and 2004, and registered to the German HIT database. *Pediatr Blood Cancer* 2011;57:978-85.
 26. Wang RF, Guan WB, Yan Y, Jiang B, Ma J, Jiang MW, *et al.* Atypical teratoid/rhabdoid tumours: Clinic pathological characteristics, prognostic factors and outcomes of 22 children from 2010 to 2015 in China. *Pathology* 2016;48:555-63.
 27. Wu WW, Bi WL, Kang YJ, Ramkissoon SH, Prasad S, Shih HA, *et al.* Adult atypical teratoid/Rhabdoid tumors. *World Neurosurg* 2016;85:197-204.
 28. Schrey D, Carceller Lechón F, Malietzis G, Moreno L, Dufour C, Chi S, *et al.* Multimodal therapy in children and adolescents with newly diagnosed atypical teratoid rhabdoid tumor: Individual pooled data analysis and review of the literature. *J Neurooncol* 2016;126:81-90.