



Contents lists available at ScienceDirect

## Journal of Traditional and Complementary Medicine

journal homepage: <http://www.elsevier.com/locate/jtcme>

## Original article

## Tongue color changes within a menstrual cycle in eumenorrheic women

Shu-Feng Hsieh<sup>a</sup>, Li-Ling Shen<sup>b</sup>, Shan-Yu Su<sup>b, c, \*</sup><sup>a</sup> Department of Traditional Chinese Medicine, Kaohsiung Veterans General Hospital, Kaohsiung 81362, Taiwan<sup>b</sup> Department of Chinese Medicine, China Medical University Hospital, Taichung 40447, Taiwan<sup>c</sup> School of Post-Baccalaureate Chinese Medicine, College of Chinese Medicine, China Medical University, Taichung 40402, Taiwan

## ARTICLE INFO

## Article history:

Received 22 May 2015

Received in revised form

30 June 2015

Accepted 14 July 2015

Available online 20 August 2015

## Keywords:

Tongue inspection

RGB model

CMYK model

Lab model

HSB model

Menstrual cycle

## ABSTRACT

Tongue color (舌色 shé sè) has been used to diagnose abnormal body conditions for thousands of years in traditional Chinese Medicine (中醫 zhōng yī). However, it is not clear whether tongue color alters with physiological changes within a normal menstrual cycle (月經周期 yuè jīng zhōu qī). This study investigated difference in tongue color between the follicular phase and luteal phase in eumenorrheic women. Tongue surface photographs were taken in the follicular phase and the luteal phase of thirty-two volunteers with biphasic basal body temperature. Color values on five areas of the tongue surface were examined and comparisons of color values were made between the two phases according to the red–green–blue (RGB), hue–saturation–brightness (HSB), luminance–a–b (Lab), and cyan–magenta–yellow–black (CMYK) models. Based on the RGB model, the values of green and blue in the tip area were larger in the follicular phase than both in the luteal phase. The values of magenta and yellow based in the CMYK model were smaller in the tip area in the follicular phase than that in the luteal phase. The saturation in the tip area was smaller in the follicular phase than that in the luteal phase. Based on the Lab model, b value in the middle area was smaller in the follicular phase than that in the luteal phase. The data revealed that tongue color varied within a eumenorrheic menstrual cycle, suggesting that tongue color differences between the follicular and luteal phases need to be considered while practicing tongue diagnosis (舌診 shé zhēn) or performing clinical studies among childbearing women.

Copyright © 2016, Center for Food and Biomolecules, National Taiwan University. Production and hosting by Elsevier Taiwan LLC. This is an open access article under the CC BY-NC-ND license (<http://creativecommons.org/licenses/by-nc-nd/4.0/>).

## 1. Introduction

Tongue diagnosis (舌診 shé zhēn) is one of “the four diagnostic methods in traditional Chinese Medicine (中醫四診 zhōng yī sì zhēn)”, which is an important subdivision of contemporary complementary and alternative medicine (CAM; 補充與替代醫學 bǔ chōng yǔ tì dài yī xué) in the world.<sup>1</sup> According to the textbook of

TCM, tongue color (舌色 shé sè) is a crucial component in the tongue diagnostic method, and is used traditionally to diagnose the imbalance of “Yin and Yang (陰陽 yīn yáng)”.<sup>2</sup> From the point of view of modern medicine, tongue color is dependent on microcirculation, which is changed with body temperature, hormones, and hemodynamic parameters.<sup>3,4</sup> It has been reported that tongue color changes in several diseases, such as anemia,<sup>5</sup> appendicitis,<sup>6</sup> and immune hepatic injury.<sup>4</sup> Tongue color is also used to categorize subgroups of diseases to predict the effectiveness of Chinese medicine and conventional western medicine.<sup>7,8</sup> However, those studies on women of childbearing (分娩 fēn miǎn) age did not consider the effect of menstrual cycle (月經周期 yuè jīng zhōu qī) on tongue color, because the difference in tongue color between phases in a menstrual cycle has not been clarified.

Physiological parameters change within a eumenorrheic menstrual cycle in healthy women. First of all, the concentration of estradiol is high while progesterone is relatively low in the late follicular phase and the concentrations of both estradiol and

*Abbreviations:* B (in HSB), brightness; B (in RGB), blue; BBT, basal body temperature; CMYK, cyan–magenta–yellow–black; C, cyan; E2, estradiol; G, green; HSB, hue–saturation–brightness; H, hue; K, black; L, luminance; Lab, luminance–a–b; M, magenta; R, red; RGB, red–green–blue; S, saturation; TCM, traditional Chinese Medicine; Y, yellow.

\* Corresponding author. Department of Chinese Medicine, China Medical University Hospital, No. 2 Yuh-Der Road, Taichung 40447, Taiwan. Tel.: +886 4 22052121x1675; fax: +886 4 22365141.

E-mail address: [shanyusu@yahoo.com.tw](mailto:shanyusu@yahoo.com.tw) (S.-Y. Su).

Peer review under responsibility of The Center for Food and Biomolecules, National Taiwan University.

<http://dx.doi.org/10.1016/j.jtcme.2015.07.004>

2225–4110/Copyright © 2016, Center for Food and Biomolecules, National Taiwan University. Production and hosting by Elsevier Taiwan LLC. This is an open access article under the CC BY-NC-ND license (<http://creativecommons.org/licenses/by-nc-nd/4.0/>).

progesterone are high in the luteal phase.<sup>9</sup> Secondly, the high concentration of progesterone in the luteal phase induces hypothalamus thermogenic effect and elevates the basal body temperature (BBT) by about 0.22 °C compared with that in the follicular phase.<sup>10</sup> Thirdly, in terms of hemodynamic parameters, the plasma volume, heart rate, and cardiac output are larger in the luteal phase than those in the follicular phase.<sup>11,12</sup> Fourthly, the sympathetic baroreflex sensitivity is greater during the middle luteal phase than the early follicular phase.<sup>13</sup> Fifthly, under static exercise, changes of muscle sympathetic nerve activity are greater in the menstrual phase than that in the follicular phase.<sup>14</sup> The above mentioned physiological variations from the follicular to the luteal phases within a menstrual cycle could also be detected by measuring biological information. In studies which detecting heart rate variability, the total power and high frequency spectral component have been reported higher in the luteal phase than both in the follicular phase.<sup>15,16</sup> Pulse waveform analysis also has revealed that the magnitude of the main wave, dicrotic wave, and systolic area of the radial pulse waveforms are greater in the luteal phase than those in the follicular phase.<sup>17</sup> However, no reports have been published regarding differences of tongue color between phases in a menstrual cycle.

Based on the above-mentioned changes in physiological parameters within a menstrual cycle, we speculated that tongue color alters with phases in a normal menstrual cycle. In this study, tongue images of eumenorrheic women were taken in the follicular phase and luteal phase. Tongue color in five areas of the tongue was compared between the two phases based on the RGB (red–green–blue), HSB (hue–saturation–brightness), Lab (luminance-a-b), and CMYK (cyan–magenta–yellow–black) models, those are commonly used in technology of color analysis. This study provided evidence for the effect of physiological phases of menstrual cycle on tongue color in eumenorrheic women.

## 2. Materials and methods

### 2.1. Subjects

Subjects were recruited through an advertisement at the China Medical University Hospital (CMUH) between March 2009 and January 2010. All subjects received a full explanation of the study and signed an informed consent. The enrolled subjects met the following criteria: (1) eumenorrheic healthy women with regular, predictable menstrual cycles (月經周期 *yuè jīng zhōu qī*) ranging from 28 to 35 days; (2) age from 18 to 40 years; (3) no oral contraceptive use within the last 6 months; (4) no history of alcohol, drug abuse, or smoking. Exclusion criteria are: (1) active heart disease, liver disease, kidney disease, or thyroid disease; (2) any chronic disease which needs medication; and (3) psychiatric disorders. This study was approved by the institutional review board of the CMUH (DMR97-IRB-241).

### 2.2. Tongue photographs

Subjects were asked to measure BBT every morning and provided their BBT chart to ensure that the studied cycle was a biphasic menstrual cycle and the tongue images were taken in the correct phases. Tongue images representing the follicular phase were taken on the 12th or 13th day of the menstrual cycle, and that representing the luteal phase were taken on the 26th or 27th day of the cycle.<sup>18</sup> All the images were taken before breakfast in the morning during nine to twelve o'clock by a charge-coupled device Nikon E2 (Nikon, Tokyo, Japan) with a lens of Micro-Nikkor 10.5 mm/2.8D (Nikon, Tokyo, Japan). After a 20 min' rest, images were taken in a standardized shady studio, which was surrounded by focusing

cloth, under a cold light supplied by a source of Raiser Repro-Belichtungseinrichtung RB 5000. The camera-to-object distance was set to be 50 cm. A shutter speed of 1/125 s was used. The photographs were taken immediately after subjects protruded their tongues forward and downward. The room temperature of the studio was set at  $21 \pm 1$  °C.

### 2.3. Tongue color (舌色 *shé sè*) measurement

Tongue surface was divided into five areas as tongue tip, middle, left lateral, right lateral, and root (Fig. 1).<sup>19</sup> Tongue tip was defined as the anterior one-fifth of the tongue, tongue root was defined as the posterior one-fifth of the tongue, tongue lateral was defined as the lateral one-fifth of the tongue on both sides, and tongue middle was defined as the area between the tongue tip, tongue root, and tongue lateral areas. The color values of R, G, and B in the RGB model, that of H, S, and B in the HSB model, that of L, a, and b in the Lab model, and that of C, M, Y, and K in the CMYK model were measured using Photoshop software (Adobe Systems Incorporated, San Jose, America). For each area, color values were measured at three randomly selected points. The color value of a certain area was the average value of these three randomly selected measurements.

### 2.4. Statistical analysis

Statistical analyses were performed using the SPSS 18.0 statistical software package. Individual variables were examined by percentage, mean and standard error of the mean (SEM). Differences in color parameters between the follicular and luteal phases were compared by paired *t*-test. A two-tailed *p*-value of less than 0.05 was considered to be statistically significant.

## 3. Result

### 3.1. Subjects

A total of 32 volunteers have participated in this study. All these subjects were identified to have biphasic menstrual cycle (月經周期 *yuè jīng zhōu qī*) according to their BBT charts. The mean age of the subjects was  $25.7 \pm 0.8$  years old. They had a mean body height of

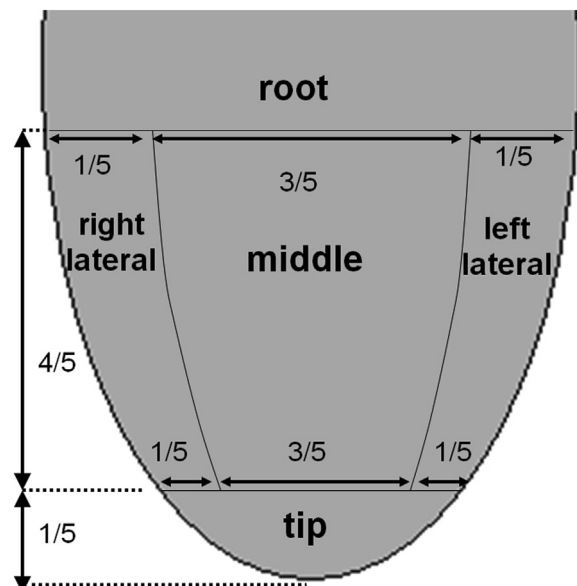


Fig. 1. Five areas of the tongue surface.

159.4 ± 0.9 cm, a mean weight of 51.5 ± 1.1 kg, a mean menstruation interval of 30.0 ± 0.4 days, and a mean duration of 5.9 ± 0.2 days. Current chronic diseases and past diseases of these subjects are shown in Table 1.

### 3.2. Comparison of tongue color (舌色 *shé sè*) between the follicular and luteal phases using the RGB model

Figure 2 shows the representative tongue surface photographs taken from one of the subjects in the follicular and luteal phases. Using the RGB model, after analyzing color values of the 32 subjects, the G value in the tip area was significantly larger in the follicular phase than that in the luteal phase (97.3 ± 1.5 versus 93.7 ± 2.0,  $p = 0.030$ ). The B value in the tip in the follicular phase is also significantly larger than that in the luteal phase (81.4 ± 1.2 versus 77.8 ± 1.7,  $p = 0.011$ ). There were no differences between the two phases in the R value in the tip area. There were also no differences between the two phases in the R, G, and B values in the left lateral area, right lateral area, middle area and root area (Table 2).

### 3.3. Comparison of tongue color between the follicular and luteal phases using the CMYK model

The M value in the follicular phase was smaller than that in the luteal phase in the tip area (61.2 ± 0.7 versus 62.9 ± 0.9,  $p = 0.029$ ). The Y value in the follicular phase was smaller than that in the luteal phase in the tip area (65.3 ± 0.4 versus 66.6 ± 0.6,  $p = 0.005$ ). There were no differences in C and K values in the tip area between the follicular phase and the luteal phase. There were also no significant differences in C, M, Y and K values in the left lateral area, right lateral area, middle area and root area between the follicular and luteal phases (Table 3).

### 3.4. Comparison of tongue color between the follicular and luteal phases using the HSB model

The S value in the tip was significantly smaller in the follicular phase than that in the luteal phase (43.7 ± 0.6 versus 45.8 ± 0.8,  $p = 0.006$ ). There were no significant differences in H and B values

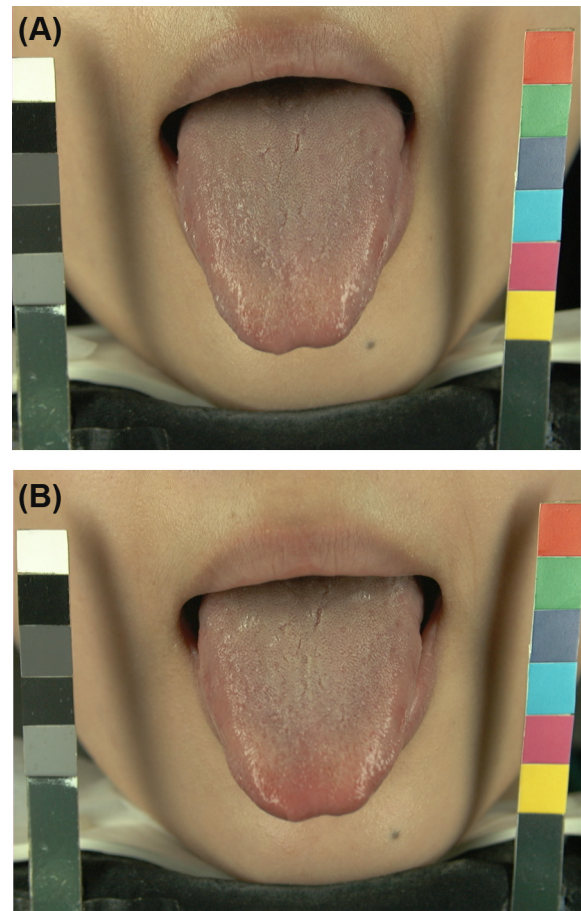


Fig. 2. Representative photographs of tongue in the follicular phase (A) and luteal phase (B).

in the tip area between the two phases. There were also no significant differences in H, S and B values between the follicular and luteal phases in the left lateral area, right lateral area, middle area and root area (Table 4).

**Table 1**  
Characteristics of the 32 eumenorrhic women.

Characteristics	Number (%)
Age (year)	
<25	13 (40.7%)
25–29	13 (40.6%)
30–40	6 (18.8%)
Mean ± SD	25.7 ± 0.8
Education	
High school or below	11 (34.4%)
College or university	21 (62.5%)
Graduate school or above	1 (3.1%)
Current illness	
Yes	13 (40.6%)
Allergic symptoms	9 (28.1%)
Chronic diarrhea	1 (3.1%)
Hemorrhoid	1 (3.1%)
Chronic headache	2 (6.3%)
No	19 (59.4%)
Past diseases	
Yes	3 (9.3%)
Thyroid disease	1 (3.1%)
Cerebral disease	1 (3.1%)
Renal disease	1 (3.1%)
No	29 (90.6%)
Body height (cm)/weight (kg)	159.4 ± 0.9/51.5 ± 1.1
Menstruation interval/duration (day)	30.0 ± 0.4/5.9 ± 0.2

Data were represented by mean ± standard error of the mean.

**Table 2**  
Difference in red (R), green (G), and blue (B) values between the follicular and luteal phases.

		Follicular	Luteal	P value
Tip	R	144.3 ± 1.4	142.5 ± 1.8	0.221
	G	97.3 ± 1.5	93.7 ± 2.0	0.030*
	B	81.4 ± 1.2	77.8 ± 1.7	0.011*
Left lateral	R	143.8 ± 1.5	143.0 ± 1.6	0.592
	G	107.1 ± 1.6	105.5 ± 2.0	0.316
	B	87.8 ± 1.2	87.0 ± 1.6	0.462
Right lateral	R	148.4 ± 9.1	146.4 ± 10.4	0.217
	G	109.1 ± 10.6	106.1 ± 11.3	0.109
	B	89.8 ± 8.6	87.5 ± 9.0	0.153
Middle	R	151.6 ± 1.7	150.3 ± 1.8	0.519
	G	119.6 ± 2.5	118.7 ± 2.3	0.730
	B	99.5 ± 2.0	99.8 ± 1.7	0.816
Root	R	103.4 ± 3.9	102.3 ± 3.4	0.688
	G	83.7 ± 3.8	82.1 ± 3.3	0.600
	B	66.2 ± 3.4	65.4 ± 3.0	0.800

Data were represented by the mean ± standard error of the mean. \* $p < 0.05$  refers to differences between the follicular and luteal phases.

**Table 3**

Difference in the value of cyan (C), magenta (M), yellow (Y), and black (K) between the follicular and luteal phases.

		Follicular	Luteal	P value
Tip	C	36.8 ± 0.3	36.6 ± 0.4	0.567
	M	61.2 ± 0.7	62.9 ± 0.9	0.029*
	Y	65.3 ± 0.4	66.6 ± 0.6	0.005**
	K	20.3 ± 0.7	21.7 ± 1.0	0.082
Left lateral	C	42.3 ± 3.3	39.0 ± 0.4	0.324
	M	55.3 ± 0.7	56.0 ± 0.8	0.309
	Y	63.8 ± 0.5	63.9 ± 0.5	0.681
Right lateral	K	17.7 ± 0.7	18.3 ± 0.9	0.413
	C	37.4 ± 0.4	37.7 ± 0.4	0.501
	M	55.5 ± 0.8	56.5 ± 0.8	0.197
Middle	Y	63.1 ± 0.5	63.5 ± 0.5	0.470
	K	16.3 ± 0.8	17.5 ± 0.9	0.175
	C	38.3 ± 0.4	38.7 ± 0.4	0.422
Root	M	50.2 ± 1.1	50.3 ± 0.9	0.876
	Y	59.5 ± 0.8	59.4 ± 0.5	0.898
	K	13.5 ± 1.3	13.0 ± 0.9	0.729
	C	49.3 ± 0.7	49.4 ± 0.6	0.677
	M	57.0 ± 1.0	57.6 ± 0.9	0.445
	Y	69.4 ± 0.9	69.3 ± 0.9	0.946
	K	35.9 ± 2.4	36.6 ± 2.1	0.687

Data were represented by the mean ± standard error of the mean. \* $p < 0.05$  and \*\* $p < 0.01$  refer to differences between the follicular and luteal phases.

### 3.5. Comparison of tongue color between the follicular and luteal phases using the Lab model

Based on the Lab model, the b value was found larger in the follicular phase than that in the luteal phase in the middle area of tongue surface ( $16.4 \pm 0.4$  versus  $15.5 \pm 0.4$ ,  $p = 0.003$ ). No difference could be found in L value and a value in the middle area between the two phases. There were also no differences in L, a, and b value values of the Lab model in the tip area, the left lateral area, right lateral area and root area between the follicular and luteal phases (Table 5).

## 4. Discussion

The present study was the first to assess tongue color (舌色 shé sè) changes within a menstrual cycle (月經周期 yuè jīng zhōu qī) in eumenorrheic women, and revealed that the difference between the follicular and luteal phases existed in the tip area and the middle area. In the tip area of the tongue, high B and G values in the RGB model, high S value in the HSB model, and low M and Y values

**Table 4**

Difference in the values of hue (H), saturation (S), and brightness (B) between the follicular phase and luteal phase.

		Follicular	Luteal	P value
Tip	H	15.5 ± 0.5	14.8 ± 0.6	0.165
	S	43.7 ± 0.6	45.8 ± 0.8	0.006**
	Br	56.5 ± 0.5	56.0 ± 0.7	0.373
Left lateral	H	20.7 ± 0.6	20.1 ± 0.7	0.346
	S	38.8 ± 0.6	39.3 ± 0.8	0.346
	Br	56.4 ± 0.6	56.1 ± 0.6	0.571
Right lateral	H	19.8 ± 0.5	19.2 ± 0.6	0.259
	S	39.6 ± 0.5	40.2 ± 0.7	0.387
	Br	58.2 ± 0.6	57.3 ± 0.7	0.152
Middle	H	23.6 ± 0.9	22.7 ± 0.9	0.286
	S	34.9 ± 0.8	33.8 ± 0.6	0.176
	Br	59.5 ± 0.6	59.0 ± 0.7	0.455
Root	H	28.7 ± 0.8	27.5 ± 0.8	0.224
	S	37.3 ± 1.3	37.0 ± 1.1	0.837
	Br	40.6 ± 1.5	40.3 ± 1.3	0.746

Data were represented by the mean ± standard error of the mean. \*\* $p < 0.01$  refers to differences between the follicular and luteal phases.

**Table 5**

Difference in the values of luminosity (L), a, and b between the follicular and luteal phases.

		Follicular	Luteal	P value
Tip	L	46.0 ± 0.6	45.0 ± 0.7	0.092
	a	19.9 ± 1.7	19.2 ± 0.6	0.679
	b	17.5 ± 0.3	17.8 ± 0.4	0.428
Left lateral	L	48.7 ± 0.6	48.1 ± 0.7	0.325
	a	13.2 ± 0.4	13.6 ± 0.5	0.305
Right lateral	b	16.9 ± 0.3	16.7 ± 0.3	0.598
	L	49.7 ± 0.7	48.7 ± 0.7	0.155
	a	14.2 ± 0.5	14.8 ± 0.5	0.259
Middle	b	17.4 ± 0.2	17.3 ± 0.3	0.649
	L	52.6 ± 1.0	52.6 ± 0.8	0.947
	a	10.8 ± 0.6	10.8 ± 0.5	0.910
Root	b	16.4 ± 0.4	15.5 ± 0.4	0.003**
	L	37.1 ± 1.6	36.6 ± 1.4	0.669
	a	6.5 ± 0.4	6.8 ± 0.4	0.455
	b	13.7 ± 0.3	13.3 ± 0.3	0.390

Data were represented by the mean ± standard error of the mean. \*\* $p < 0.01$  refers to differences between the follicular and luteal phases.

in CMYK model were detected in the follicular phase. In the middle area of the tongue, the differences between the two phases only could be detected by the Lab model. High b value in the middle area was revealed in the follicular phase when compared with that in the luteal phase.

Four color models were used in this study, including RGB, CMYK, HSB, and Lab models. Both the RGB model and CMYK model describe color by combining color elements. The difference between the two models is that the RGB model is an additive color system, in which red, green, and blue light are added together in various way to produce broad array of color values from 0 to 255, while the CMYK model is a subtractive color system, in which cyan, magenta, yellow, and black pigments are mixed to generate color value range from 0 to 100<sup>20</sup>. The use of RGB model to study tongue images can be traced back to 1985, and since then this method has made the tongue diagnosis (舌診 shé zhěn) objective and reproducible.<sup>19</sup> HSB (also called HSL-luminance) model, which has been used together with the RGB model in several tongue color studies, provides a method of determining color based on hue, saturation, and brightness.<sup>19</sup> The Lab model is a device independent color model, which expresses a color as luminance, a value, and b value. Luminance is the amount of light intensity, the component ranges from -120 to +120 (from green to red), and b component also ranges from -120 to 120 (from blue to yellow).<sup>21</sup>

Most of the color value differences between the follicular phase and luteal phase were observed in the tip area of the tongue. The low B and G values of the RGB model in the luteal phase in the tip area indicated that the intensities of the blue light and green light were weaker in the luteal phase than that in the follicular phase in this area. Based on the CMYK model, the M value and Y value were higher in the luteal phase than those in the follicular phase, suggesting that the magenta and yellow pigments were more intensive in luteal phase than that in the follicular phase. The high intensity of magenta and yellow pigments, and the low intensity of green and blue lights in the luteal phase might be the cause of the red-looking color in the tip area in the luteal phase. The higher S value in the tongue tip area in the luteal phase also reflected the high pigmentation of magenta and yellow colors. Since the tongue tip is the area that is hardly covered by tongue coating, the image color of the tongue tip directly reveals the color of the tongue body.<sup>22</sup> Therefore, the tongue tip area is considered suitable for the observation of microcirculation of the tongue body.<sup>23</sup> In this study, the color differences in the tongue tip area might reflect the color differences of tongue body between the two phases.

A normal tongue body is pink, which is the color of the blood flow-rich submucosa and muscle layers penetrating out through the translucent mucosa layer.<sup>24</sup> The tongue color becomes pale while the vessels atrophy, the blood volume drops, or the hemoglobin level decreases. In contrast, the tongue becomes redder than normal when temperature elevates, the blood flow increases, or the vessels dilate.<sup>25</sup> The decrease of blue and green colors, the increase of magenta and yellow colors, and the high saturation in the luteal phase implied that a redder tongue in the luteal phase than that in the follicular phase could be detected by color models. The change of physiological conditions, including the elevation of body temperature, plasma volume, heart rate, and cardiac output, as well as vasodilatation in the luteal phase,<sup>11,12</sup> might be responsible for the changes in tongue color in the luteal phase.

Only one color value, which was the b value in the Lab model, differed in the middle area of the tongue between the follicular and luteal phases. The b value is significantly larger in the follicular phase than that in the luteal phase. Since tongue coating occupies most of the surface in the middle area of the tongue, the color value in this area reflects the color of tongue coating.<sup>22</sup> The higher b value in the follicular phase than that in the luteal phase indicated that the tongue coating was yellower in the follicular phase than in the luteal phase. The tongue coating is generated from a mix of bacteria and food residue with the prolonged cuticle of over-keratinized epithelium of tongue mucosa and papilla.<sup>5</sup> We proposed that the yellow color of the tongue coating in the luteal phase was from the sulfur compounds, whose concentrations in the oral cavity are higher in the luteal phase than that in the follicular phase.<sup>26</sup> Many of those sulfur compounds, such as dimethyl disulfide, dimethyl trisulfide, and 2,4-dithiapentane,<sup>27</sup> are yellowish in color.

According to the diagnostic principle of TCM (中醫 zhōng yī), red and yellow tongue colors indicate yang patterns, while green and blue tongue colors indicate “Yin (陰 yīn)” patterns.<sup>1</sup> The color change between phases might reflect the “Yang (陽 yáng)” pattern in the luteal phase, comparing to the pattern in the follicular phase. The yang pattern in the luteal phase is a physiological condition in women with normal menstrual cycle.<sup>28</sup> Since the measurable physiological color differences exist in healthy eumenorrheic women, the result of the present study suggested that tongue color differences between the follicular and luteal phases need to be considered either in clinical practice or in studies on tongue color with female subjects.

Tongue image analysis is convenient and inexpensive, however, the first limitation of this study was that this method could only measure the color on the very surface of the tongue. When the tongue is covered by the tongue coating, the color underneath the coating could not be analyzed. The second limitation of this study was its sample size. As this study was an exploratory study and it was the first to assess this topic in the field of tongue diagnosis, it did not include large number of subjects. In our future work, further large studies are required to confirm the results revealed by the present study, and moreover, to observe physiological changes underneath the tongue coating, methods such microcirculation detection will be adopted.

## 5. Conclusion

Our study was the first to reveal that the tongue color (舌色 shé sè) changes within a eumenorrheic menstrual cycle (月經周期 yuè jīng zhōu qī). The green and blue color values of the tongue body were lower, but the magenta and yellow color values, as well as the saturation were higher in the luteal phase than those in the follicular phase. Furthermore, the b value of the tongue coating was higher in the follicular phase than that in the luteal phase.

Moreover, this study suggested that tongue color differences between the follicular and luteal phases need to be considered in studies on tongue diagnosis (舌診 shé zhěn) when study subjects are eumenorrheic women.

## Author disclosure statement

No competing financial interests exist.

## Conflict of interests

The authors declare that they have no conflict of interests.

## Acknowledgments

This study was supported by grants from the China Medical University Hospital, Taiwan (DMR-102-002).

## References

1. Maciocia G. *Diagnosis in Chinese Medicine*. Edingburgh: Churchill Livingstone; 2004.
2. Yi Q. *Traditional Chinese Medicine Diagnosis Study Guide*. Seattle, WA, USA: Eastland Press; 2008.
3. Kai Z, Jian H, Fan W, Jin Z, Boli Z. Experimental study on characteristic of bioheat transfer and numerical simulation for the temperature fields in transverse and longitudinal sections of pig tongue. *J Therm Biol*. 2005;30:1–6.
4. Liu WL, Zhang HY, Che NC, Tang ZQ, Gao LY. Changes of color and blood flow of the tongue in the mini-swine of immune hepatic injury. *J Tradit Chin Med*. 2010;30:265–271.
5. Joseph BK, Savage NW. Tongue pathology. *Clin Dermatol*. 2000;18:613–618.
6. Pang B, Zhang D, Wang K. Tongue image analysis for appendicitis diagnosis. *Inf Sci*. 2005;175:160–176.
7. Wang HH, Pan CH, Wu PP, Luo SF, Lin HJ, Wu CH. Alteration of the tongue manifestation reflects clinical outcomes of peptic ulcer disease. *J Altern Complement Med*. 2012;18:1038–1044.
8. Jiang M, Zha Q, Lu C, He Y, Lu A. Association between tongue appearance in Traditional Chinese Medicine and effective response in treatment of rheumatoid arthritis. *Complement Ther Med*. 2011;19:115–121.
9. Sherman BM, Korenman SG. Hormonal characteristics of the human menstrual cycle throughout reproductive life. *J Clin Invest*. 1975;55:699–706.
10. Fortner KB, Szymanski LM, Fox HE, Wallach EE. *The Johns Hopkins Manual of Gynecology and Obstetrics*. 3rd ed. Lippincott Williams & Wilkins; 2007.
11. Spaanderman ME, Van Beek E, Ekhart TH, et al. Changes in hemodynamic parameters and volume homeostasis with the menstrual cycle among women with a history of preeclampsia. *Am J Obstet Gynecol*. 2000;182:1127–1134.
12. Chapman AB, Zamudio S, Woodmansee W, et al. Systemic and renal hemodynamic changes in the luteal phase of the menstrual cycle mimic early pregnancy. *Am J Physiol*. 1997;273:F777–F782.
13. Minson CT, Halliwill JR, Young TM, Joyner MJ. Influence of the menstrual cycle on sympathetic activity, baroreflex sensitivity, and vascular transduction in young women. *Circulation*. 2000;101:862–868.
14. Ettinger SM, Silber DH, Gray KS, et al. Effects of the ovarian cycle on sympathetic neural outflow during static exercise. *J Appl Physiol*. 1998;85:2075–2081.
15. Princi T, Parco S, Accardo A, Radillo O, De Seta F, Guaschino S. Parametric evaluation of heart rate variability during the menstrual cycle in young women. *Biomed Sci Instrum*. 2005;41:340–345.
16. Sato N, Miyake S, Akarsu J, Kumashiro M. Power spectral analysis of heart rate variability in health young women during the normal menstrual cycle. *Psychosom Med*. 1995;57:331–335.
17. Su SY, Wei CC, Hsieh CL, et al. Influence of menstrual cycle on pulse pressure waveforms measured from the radial artery in biphasic healthy women. *J Altern Complement Med*. 2009;15:645–652.
18. Hirshoren N, Tzoran I, Makrienko I, et al. Menstrual cycle effects on the neurohumoral and autonomic nervous systems regulating the cardiovascular system. *J Clin Endocrinol Metab*. 2002;87:1569–1575.
19. Chiu CC. A novel approach based on computerized image analysis for traditional Chinese medical diagnosis of the tongue. *Comput Methods Programs Biomed*. 2000;61:77–89.
20. Sanchez-Cuevas MC, Aguilar-Ponce RM, Tecpanecatli-Xihuitl JL. A comparison of color models for color face segmentation. *Procedia Technol*. 2013;7:134–141.
21. Sharifzadeh S, Clemmensen LH, Borggaard C, Støier S, Ersbøll BK. Supervised feature selection for linear and non-linear regression of L\*a\*b\* color from multispectral images of meat. *Eng Appl Artif Intell*. 2014;27:211–227.

22. Kim J, Han G-J, Choi B-H, et al. Development of differential criteria on tongue coating thickness in tongue diagnosis. *Complement Ther Med*. 2012;20: 316–322.
23. Heckmann SM, Heckmann JG, Hilz MJ, et al. Oral mucosal blood flow in patients with burning mouth syndrome. *Pain*. 2001;90:281–286.
24. Deng T. *Practical Diagnosis in Traditional Chinese Medicine*. Edinburgh: Churchill Livingstone; 1999.
25. Kai Z, Jian H, Zhaolu W, Fan W, Meng Z, Liyuan K. Experimental research and numerical calculation of bio-heat transfer in tongue. *J Therm Biol*. 2004;29: 271–276.
26. Calil CM, Lima PO, Bernardes CF, Groppo FC, Bado F, Marcondes FK. Influence of gender and menstrual cycle on volatile sulphur compounds production. *Arch Oral Biol*. 2008;53:1107–1112.
27. Guichard H, Bonnarme P. Development and validation of a plate technique for screening of microorganisms that produce volatile sulfur compounds. *Anal Biochem*. 2005;338:299–305.
28. Maciocia G. *Obstetrics and Gynecology in Chinese Medicine*. 2nd ed. China: Churchill Livingstone; 2011.