



Case report

Acute kidney injury leading to the diagnosis of sporadic testicular Burkitt's lymphoma: A case report

Sanda Mrabet^{*}, Yosr Chaabouni, Mohamed Ben Hmida

Department of Nephrology, Dialysis, and Transplantation, Hedi Chaker University Hospital, Sfax, Tunisia



ARTICLE INFO

Keywords:

Burkitt lymphoma
Testis
Neoplasm
Acute kidney injury
Case report

A B S T R A C T

Introduction: Burkitt's lymphoma of the testis (TBL) is a rare and extremely aggressive malignant usually diagnosed in front of a testicular mass. We report an exceptional case of a TBL revealed by an Acute Kidney Injury (AKI) of functional origin in a Tunisian man.

Presentation of case: A 53-year-old patient, known to smoke and drug addict, presented uncontrollable vomiting responsible for extracellular dehydration. Biology showed AKI and radiological explorations revealed compression of the stomach and the right urinary tract by a retro-peritoneal mass continuing with the right testicle. The testicular biopsy with immunohistochemical study concluded with a testicular Burkitt's lymphoma. After correction of hydro-electrolyte disorders with normalization of serum creatinine, the patient was transferred to oncology for chemotherapy. Unfortunately, he refused treatment.

Discussion: The high aggressiveness of TBL would explain the significant, and surprising intra-abdominal tumoral extension with compression of the stomach leading to the functional AKI observed in the reported case.

Conclusion: A testicular mass is a usual circumstance for the discovery of a primary tumor of the testicle. In the case of TBL, the rapid tumor growth associated with a diagnostic delay can lead to an impressive extra gonadal extension.

1. Introduction

Burkitt's lymphoma is an uncommon form of non-Hodgkin lymphoma in adults and represents less than 5 % of lymphoma cases [1]. It presents three clinical variants: Epstein-Barr virus endemic, sporadic, and immunodeficiency-associated types [1].

In sporadic Burkitt lymphoma, testicular involvement is observed in only about 6 % of the cases [2]. Primary TBL usually presents with testicular swelling and other anatomical sites are often involved, which testifies to its highly invasive nature [3–5].

We report the exceptional case of a sporadic TBL discovered in front of a functional AKI secondary to a surprising intra-abdominal tumor extension. The Tunisian man was managed in a university hospital and the work has been reported in line with the SCARE criteria [6].

2. Case presentation

A 53-year-old jobless man, known to smoke and drug addict (cannabis, heroin, trihexyphenidyl), presented to the emergency room

of the university hospital of Sfax, Tunisia for uncontrollable vomiting. The biological discovery of AKI indicated his hospitalization in the Nephrology department. At admission, the patient complained of asthenia and reported significant weight loss. The clinical examination noted signs of extracellular dehydration, normal blood pressure, a hard, painless epigastric mass, and a right testicular swelling. Diuresis was 1 l/24 h.

Laboratory investigation revealed an AKI with a serum creatinine at 249 $\mu\text{mol/l}$ (normal range 40–115 $\mu\text{mol/l}$), metabolic alkalosis with reserves at 39 mmol/l (normal range 22–30 mmol/l), Hypochloremia at 84 mmol/l (normal range 101–111 mmol/l), and hypokalemia at 2.8 mmol/l (normal range 3.5–5.5 mmol/l) with high kaliuresis at 133 mmol/24 h (normal range 40–100 mmol/l). HIV serology was negative.

Abdominal ultrasound showed a poorly limited 9 × 10 cm epigastric mass, poorly vascularized, heterogeneous, and hyperechogenic. It was coming into contact with the spine, the lower pole of the right kidney, and was responsible for dilation of the right urinary tract, and of the antro-pyloric with significant distension of the stomach.

Thoracic abdomen pelvic scanner (Figs. 1 & 2) found a large

^{*} Corresponding author.

E-mail addresses: mrabet1sanda@gmail.com (S. Mrabet), mohamed.benhmida@rns.tn (M.B. Hmida).

<https://doi.org/10.1016/j.ijscr.2022.107471>

Received 1 July 2022; Received in revised form 29 July 2022; Accepted 30 July 2022

Available online 2 August 2022

2210-2612/© 2022 Published by Elsevier Ltd on behalf of IJS Publishing Group Ltd. This is an open access article under the CC BY-NC-ND license (<http://creativecommons.org/licenses/by-nc-nd/4.0/>).

retroperitoneal, and pre-vertebral unique mass, encompassing the inferior vena cava and aorta and infiltrating the right peri-kidney and the right psoas muscle. It was plunging into the pelvis, and spinning into the right bursa. There were no adenopathies or other intra-abdominal masses.

Ultrasonography of the scrotum revealed a large mass taking up all the right testicle with capsular rupture, and extension at the level of the cord evoking primarily testicular lymphoma.

The patient underwent a testicular biopsy. The pathological examination showed proliferation in diffuse layers of large and medium-sized cells with cytoplasm sparse and with a hyperchromatic nucleus sometimes nucleolated (Fig. 3). In the immunohistochemical study, tumor cells were positive for CD10 and CD20 and 100 % of the cells had expressed Ki67 (Fig. 4).

Based on the radiological appearance of the testicular mass infiltrating the spermatic cord and extending intra-abdominal and on the results of the testicular biopsy, we retained the diagnosis of a primary TBL with intra-abdominal extension.

Resting the stomach with intravenous infusion and parenteral nutrition allowed cessation of vomiting with correction of hydro-electrolyte disorders and normalization of renal function. The patient was then transferred to oncology for chemotherapy. Unfortunately, he refused treatment.

3. Discussion

AKI is common in patients with known hematological malignancies. In the case of lymphoma infiltration, AKI might be caused by a tumor product or by cancer treatment, as many chemotherapeutic agents are nephrotoxic [7].

In the reported case, the AKI was not secondary to lymphomatous infiltration of the kidney nor of drug origin. It was the consequence of tumoral compression, non-Hodgkin lymphomatous in nature as determined by histology, of the stomach and kidney. AKI was therefore the circumstance of discovery of that extra-renal non-Hodgkin lymphoma. This one was still undiagnosed and untreated.

The functional mechanism due to digestive losses secondary to gastric compression would explain AKI since the obstacle to the urinary tract was unilateral. Indeed, the restoration of a normal volume allowed the normalization of renal function.

The mass responsible for the renal and gastric compression did not arise from any intra-abdominal organ and continued to the right testicle.

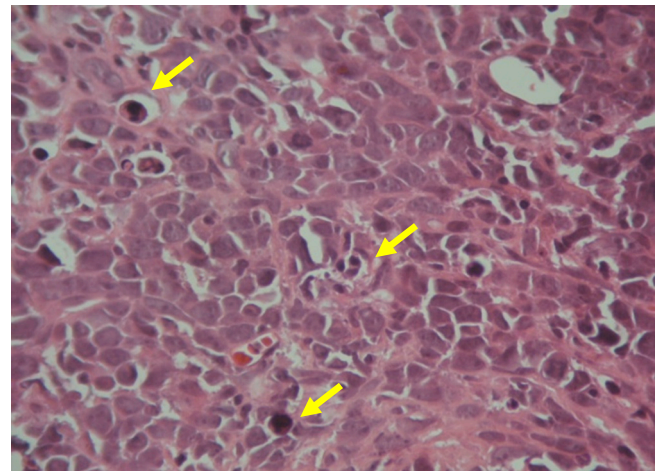


Fig. 3. Dense proliferation of large and medium-sized cells with numerous mitosis (arrows) (H&E \times 1000).

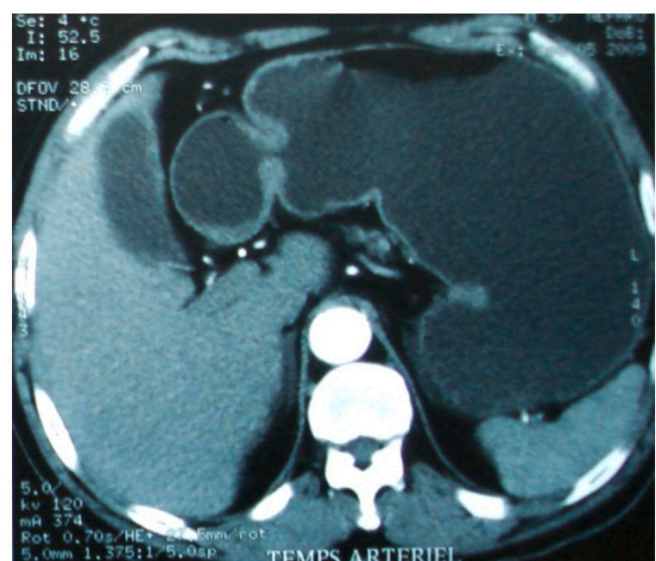
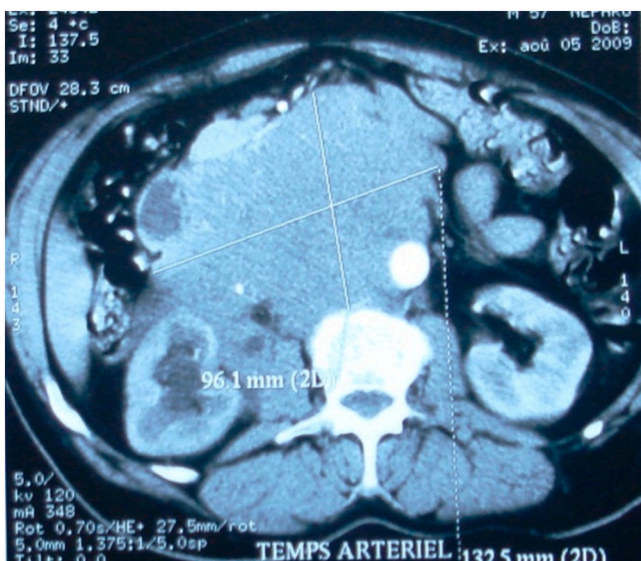
It was therefore a primary testicular non-Hodgkin lymphoma with spectacular intra-abdominal expansion, which constitutes this case's originality.

Referring to the literature, non-Hodgkin Lymphoma is extranodal in 25 % of cases. Very rare is to find lymphoma in the kidney, prostate, urinary bladder, and ureter. Testicular lymphoma is about 5 % of testis malignancies. Primary forms are usually "diffuse large B cell", a high-grade histotype; metastatic ones often show Burkitt cells [8]. Herein, it was a primary TBL.

In the endemic countries, Burkitt's lymphoma is the leading cause of death from testicular tumors and is seen in the young subject. However in countries not endemic, notably Tunisia, where the sporadic form is predominant, its location in the testis is exceptional, only 4 cases have been reported, and affects especially males over the age of 50 [9,10].

The high aggressiveness of Burkitt's lymphoma [5] would explain the significant, and surprising intra-abdominal tumoral extension observed in the reported case.

The social profile of the patient characterized by precariousness, and drug addiction would explain the delay in diagnosis and the refusal of care.



Figs. 1 & 2. Thoraco-abdomino-pelvic scanner: Voluminous retroperitoneal pre-vertebral mass encompassing the inferior vena cava and the aorta, infiltrating the right perineum, the right psoas muscle + significant distention of the stomach.

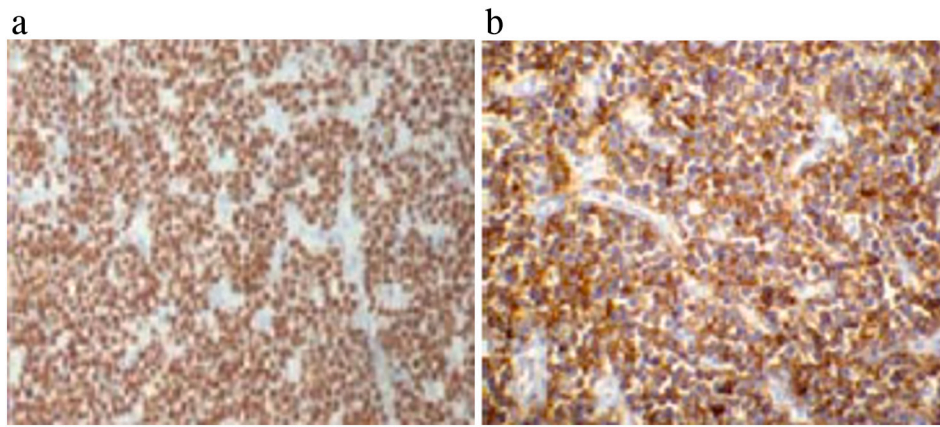


Fig. 4. Intense and diffuse immunostaining of tumor cells for Ki67 (A) and for CD20 (B).

4. Conclusion

The reported case supports the highly aggressive nature the Burkitt's lymphoma. Rapid tumor growth can be responsible for an important intra-abdominal tumoral extension and diagnostic delay can lead to surprising discovery circumstances.

Abbreviations

AKI Acute Kidney Injury
TBL Burkitt's lymphoma of the testis

Funding

This research did not receive any specific grant from funding agencies in the public, commercial, or not-for-profit sectors.

Ethical approval

Given the nature of the article, a case report, no ethical approval was required.

Consent

Written informed consent was obtained from the patient for publication of this case and accompanying images. A copy of the written consent is available for review by the Editor-in-Chief of this journal on request.

Author contribution

Sanda Mrabet: Writing - review & editing.
 Yosr Chaabouni: Writing - original draft.
 Mohamed BenHmida: Supervision; Reviewing and editing.

Registration of research studies

This does not apply as it is a case report of a patient who has given written consent and has been de-identified. It is therefore not prospective research involving human participants.

Guarantor

Dr. Sanda Mrabet.

Provenance and peer review

Editorially reviewed, not externally peer-reviewed.

Declaration of competing interest

The authors have no conflict of interest to declare.

References

- [1] H. Satishchandra, A.S. Sridhar, B.P. Pooja, Imaging of Burkitt's lymphoma-abdominal manifestations, *J. Cancer Res. Ther.* 9 (1) (2013 Jan-Mar) 128–130, <https://doi.org/10.4103/0973-1482.110383>. PMID: 23575094.
- [2] Y.S. Kwon, F. Munshi, N.R. Patel, V. Serei, N. Patel, R.A. Drachtman, J.G. Barone, An isolated testicular relapse of Burkitt's lymphoma, *Glob. Pediatr. Health* 6 (2019 Aug 30), 2333794X19872427, <https://doi.org/10.1177/2333794X19872427>. PMID: 31516915; PMCID: PMC6719464.
- [3] M.P. Leonard, P.N. Schlegel, A. Crovatto, J.P. Gearhart, Burkitt's lymphoma of the testis: an unusual scrotal mass in childhood. *J. Urol.* 1990 Jan;143(1):104-6. doi: 10.1016/s0022-5347(17)39880-4. PMID: 2294235. [5] Couper G, Anderson DN, Youngson GG. Burkitt's tumour of the testicle: an unusual presentation of a lymphomatous process in childhood, *Br. J. Urol.* 74 (1994) 124–125.
- [4] M. Root, T.Y. Wang, H. Hescocock, M. Parker, P. Hudson, L. Balducci, Burkitt's lymphoma of the testicle: report of 2 cases occurring in elderly patients, *J. Urol.* 144 (5) (1990 Nov) 1239–1241, [https://doi.org/10.1016/s0022-5347\(17\)39705-7](https://doi.org/10.1016/s0022-5347(17)39705-7). PMID: 2231906.
- [5] E.M. Molyneux, R. Rochford, B. Griffin, R. Newton, G. Jackson, G. Menon, C. J. Harrison, T. Israels, S. Bailey, Burkitt's lymphoma, *Lancet* 379 (9822) (2012 Mar 31) 1234–1244, [https://doi.org/10.1016/S0140-6736\(11\)61177-X](https://doi.org/10.1016/S0140-6736(11)61177-X). Epub 2012 Feb 13 PMID: 22333947.
- [6] R.A. Agha, T. Franchi, C. Sohrabi, G. Mathew, for the SCARE Group, The SCARE 2020 guideline: updating consensus Surgical CASE REport (SCARE) guidelines, *Int. J. Surg.* 84 (2020) 226–230.
- [7] F. Bridoux, P. Cockwell, I. Glezerman, V. Gutgarts, J.J. Hogan, K.D. Jhaveri, F. Joly, S.H. Nasr, D. Sawinski, N. Leung, Kidney injury and disease in patients with haematological malignancies, *Nat. Rev. Nephrol.* 17 (6) (2021 Jun) 386–401, <https://doi.org/10.1038/s41581-021-00405-7>. Epub 2021 Mar 30 PMID: 33785910.
- [8] Q. Wang, D. Zheng, D. Chai, S. Wu, X. Wang, S. Chen, L. Wu, R. Cao, Y. Tao, Primary testicular diffuse large B-cell lymphoma: case series, *Medicine (Baltimore)* 99 (12) (2020 Mar), e19463, <https://doi.org/10.1097/MD.00000000000019463>. PMID: 32195944; PMCID: PMC7220436.
- [9] N. Abid, A. Khabir, G. Marrakchi, M. Chouki, T. Boudawara, Burkitt's lymphoma of the testicle: report of two cases, *J.Afr.Cancer* 5 (2013) 114–117.
- [10] M. Yahia, I. M'sakni, B. Laabidi, F. Bougrine, A. Bouziani, Primitive Burkitt lymphoma in testis in non-endemic area: a report of a case, *Tunis Med.* 96 (5) (2018 May) 324–325. PMID: 30430511.