



# Nerve root transfer from C4 to C5 in brachial plexus injuries. Anatomical study and description of the surgical technique\*

## *Transferência nervosa da raiz de C4 para C5 em lesões do plexo braquial. Estudo anatômico e descrição de técnica cirúrgica*

Gabriel Vique Valeriano<sup>1</sup> Yussef Ali Abdouni<sup>1</sup> Antonio Carlos Da Costa<sup>1</sup>

<sup>1</sup> Hand Surgery and Microsurgery Group. Orthopedics and Traumatology Department, Santa Casa de São Paulo (DOT/ISCMSP), São Paulo, SP, Brazil

Address for correspondence Gabriel Vique Valeriano, Rua Martinico Prado, 284, apto 53, Vila Buarque, São Paulo, SP, Brazil (e-mail: gviquev@hotmail.com).

Rev Bras Ortop 2022;57(3):443–448.

### Abstract

**Objective** This is an anatomical study of C4 and C5 roots for nerve transfers in upper brachial plexus injuries, with surgical technique demonstration.

**Methods** Fifteen brachial plexuses from both male and female cadavers were dissected. Morphological features of C4 and C5 roots were recorded and analyzed, followed by a neurotization simulation.

**Results** In all dissections, C4 and C5 roots morphological features allowed their mobilization and neurotization with no need for a nerve graft. The surgical technique spared important regional nerve branches.

**Conclusion** Based on these data, we conclude that C4-C5 nerve transfers are feasible and result in no additional neurological deficit in upper brachial plexus injuries.

### Keywords

- ▶ Brachial plexus
- ▶ Cervical plexus
- ▶ Nerve transfer
- ▶ Spinal nerve roots

### Resumo

**Objetivo** Estudo anatômico das raízes usadas na transferência nervosa de C4 para C5 nas lesões altas do plexo braquial, demonstrando a técnica cirúrgica.

**Métodos** Dissecção de 15 plexos braquiais de ambos sexos, registro e análise das características morfológicas das raízes de C4 e C5 e simulação de neurotização.

**Resultados:** As características morfológicas encontradas nas raízes de C4 e C5 em todas as dissecções permitiram a mobilização das mesmas e realizar uma neurotização

\* Study performed at the Orthopedics and Traumatology Department, Hospital da Irmandade da Santa Casa da Misericórdia de São Paulo (DOT/ISCMSP), São Paulo, SP, Brazil.

received  
June 17, 2020  
accepted  
October 14, 2020  
published online  
March 31, 2021

DOI <https://doi.org/10.1055/s-0040-1722575>.  
ISSN 0102-3616.

© 2021. Sociedade Brasileira de Ortopedia e Traumatologia. All rights reserved.  
This is an open access article published by Thieme under the terms of the Creative Commons Attribution-NonDerivative-NonCommercial-License, permitting copying and reproduction so long as the original work is given appropriate credit. Contents may not be used for commercial purposes, or adapted, remixed, transformed or built upon. (<https://creativecommons.org/licenses/by-nc-nd/4.0/>)  
Thieme Revinter Publicações Ltda., Rua do Matoso 170, Rio de Janeiro, RJ, CEP 20270-135, Brazil

**Palavras-chave**

- ▶ Plexo braquial
- ▶ Plexo cervical
- ▶ Transferência de nervo
- ▶ Raízes nervosas espinhais

sem a necessidade de usar enxerto nervoso, a técnica cirúrgica permitiu preservar ramos nervosos importantes na região abordada.

**Conclusão** Baseado nos dados encontrados no presente estudo podemos concluir que é possível realizar a transferência entre C4 e C5 sem provocar déficit neurológico adicional nas lesões altas de plexo braquial.

**Introduction**

Brachial plexus injuries represent 10% to 20% of peripheral nervous system injuries and are mostly caused by high-energy trauma.<sup>1</sup> They often affect young, economically active people, resulting in important limitations in daily living and professional activities.<sup>2-5</sup>

According to lesion level, they are commonly classified as upper injuries, affecting C5-C6 or C5-C6-C7 roots, lower injuries, affecting C8-T1 roots, or complete injuries.<sup>6</sup> Kaiser et al.<sup>7</sup> reported that a prevalence of complete injuries of 53%, followed by upper plexus injuries, with 39%, and lower plexus injuries, with 6%. The severity of these injuries ranges from neuropraxia, usually with spontaneous resolution, to complete avulsion, with no potential for recovery.<sup>8</sup>

For some authors, such as Verdins and Kapickis,<sup>9</sup> upper trunk involvement (C5-C6) results in significant disability, with loss of shoulder function (abduction and external rotation), elbow flexion and forearm supination.

Strategies for brachial plexus repair include surgical exploration followed by reconstruction using nerve grafting or nerve transfer. Graft reconstruction is reserved to post-ganglionic lesions. Since pre-ganglionic lesions with root avulsion have no proximal stumps available for graft repair, the surgical approach is based on nerve transfers.<sup>3,8,10,11</sup>

Options for nerve transfer are scarce in cases with upper trunk roots avulsion, including accessory, phrenic and intercostal nerves. According to Abdouni et al.<sup>12</sup> and Malessy et al.,<sup>13</sup> accessory nerve transfer to the suprascapular nerve, a very common procedure for brachial plexus reconstruction, has some limitations described in the literature.

In 1991, Yamada et al.<sup>14-16</sup> described C3-C4 root transfer for upper trunk (C5 and C6) avulsions reconstruction using a nerve graft. In an anatomical study, Yang et al.<sup>17</sup> coapted the avulsed portion of C5 to C4 root using a laminectomy and intracanal dissection to approach the affected region. The advantage of this transfer would be the reactivation of the scapular-humeral muscles contraction, leading shoulder movements (external rotation and abduction) return with a single neurotization.

This study aimed to evaluate the anatomical features of brachial and cervical plexus roots to demonstrate the feasibility of performing a C4-C5 nerve root transfer with no need for a nerve graft.

**Materials and Methods**

Cadaveric brachial plexuses were analyzed using microsurgical dissection of to identify and characterize the C4, C5 and C6 cervical nerves. Fifteen plexuses from 10 cadavers were

dissected; eight plexuses were from male cadavers and seven were from female cadavers. Anthropometric data, such as gender, ethnicity, age, weight, and height, were recorded.

Cadavers with known neuromuscular disease, other injuries or previous procedures at the dissection site were excluded.

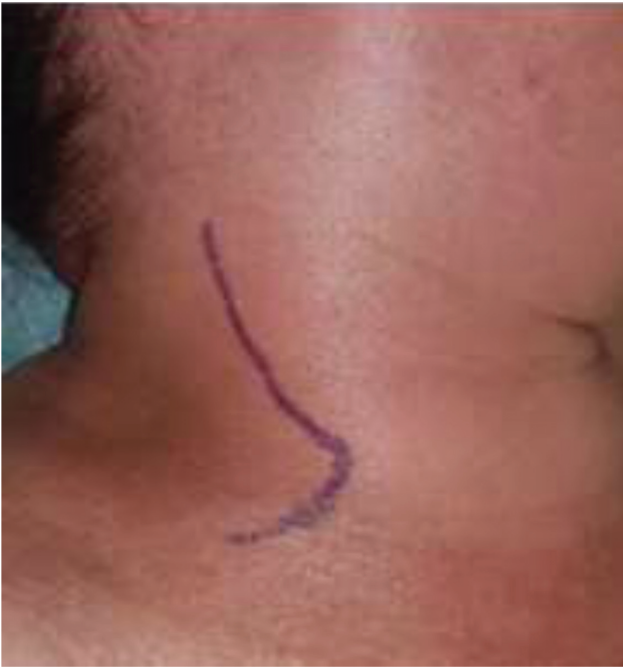All dissections were performed by the same researcher aided by a surgical magnifying glass with a 3.5-fold magnification capacity. Anatomical parameters from the C4, C5 and C6 cervical roots, including length, direction, and distance between them, were recorded. Measurements were obtained with a millimeter tape and a digital caliper.

**Dissection**

After placing an interscapular cushion, a path parallel to the posterior border of the sternocleidomastoid muscle, with approximately 8 cm in length, was created in its middle third (nervous point) with supraclavicular extension (▶ **Figure 1**). Dissection reached the subcutaneous tissue, platysma muscle and deep fascia. The external jugular vein was found at the subcutaneous layer, descending superficially to the sternocleidomastoid muscle. The posterior jugular vein draining into the external jugular vein was also found in this region and it was ligated to facilitate the approach to deep structures. The sternocleidomastoid muscle and the external jugular vein were folded anteromedially, exposing the upper trunk (formed by C5 and C6) located between the anterior and middle scalene muscles. Immediately above C5 root, C4 root was identified in a more superficial plane (▶ **Figure 2a**). Branches for the phrenic nerve (located on the anterior face of the anterior scalene) and the dorsal scapular nerve were identified emerging from the C5 root. Branches for the phrenic nerve, scalene muscles, levator scapulae muscle and accessory nerve communicating branches were also identified emerging from C4.

Next, nerve length and diameter, in addition to the distance separating both nerves after their exit from the intervertebral foramen, were measured. An important parameter for these measurements was the phrenic nerve origin in C4 and C5. Finally, a transfer between both roots was simulated (▶ **Figura 2b**), sectioning the distal portion of C4 root at the phrenic nerve emergence point, taking care to include in it the largest number of branches that would innervate the scalene and levator scapulae muscles to increase the amount of motor fibers for neurotization. The origin of the phrenic nerve at C5 root may be released to facilitate its mobilization.

Measurements were made with a Digimess 150 mm quadridimensional digital caliper.



**Fig. 1** Right lateral cervical region and schematic representation of the approach used in this study.

## Results

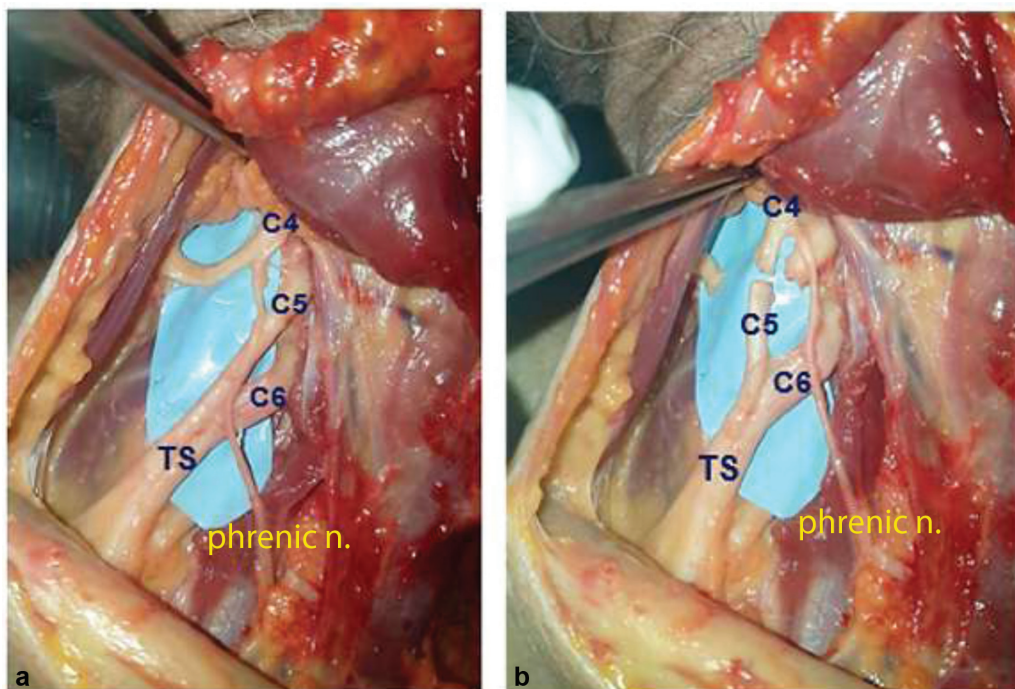
► **Table 1** shows anthropometric data from the dissected cadavers. Average age was 62 years old, ranging from 38 to 86 years old. Maximum height was 182 cm, whereas minimum height was 152 cm; average height was 167 cm.

► **Table 2** shows C4 and C5 roots measurements. An important parameter in dissection was the phrenic nerve origin point in these two roots, as well as the interval between them. If C4 root were intact, the origin of the phrenic nerve was respected, and only the segment immediately distal to it was considered useful for mobilization and neurotization. C5 root was measured in its whole length, both before and after phrenic nerve emergence, and its entire length was deemed useful for mobilization and neurotization.

Cases 6 and 7 had the shortest distance between roots at the vertebral foramen level (9 mm), and the smaller difference in length between C4 and C5 roots (12 mm). Cases 4, 12 and 13 had a greater distance between C4 and C5 roots (11 mm), but the length difference between roots remained greater in all cases (16, 14 and 13 mm). This difference in length between roots allowed for a tension-free suture.

## Discussion

The anatomical features from cervical and brachial plexuses at the cervical region are known, as well as the distribution of their different branches to the neck and upper limb.<sup>18</sup> For the cervical plexus, C4 root presents a wide distribution at the cervical region, with a sensitive portion innervating the supraclavicular area skin via supraclavicular nerves (with the contribution of C3). Its motor portion contributes to the innervation of different muscles, especially cervical and appendicular muscles; its most important branch is the phrenic nerve, formed by contributions from C3, C4 and C5, and responsible for the motor innervation to the diaphragm. C4 root also provides branches for pre-vertebral muscles (longus colli and longus capitis muscles), for the scalene and levator scapulae muscles, and communicating



**Fig. 2** Dissection of the right brachial plexus. Demonstration of C4, C5, and C6 roots, upper trunk (TS) and phrenic nerve origin (a). C4 section distal to the phrenic nerve emergence and simulation of neurotization with C5 root, which was also sectioned (b).

**Table 1** Anthropometric data

| #             | Age (years) | Side  | Gender | Height (cm) | Weight (kg) |
|---------------|-------------|-------|--------|-------------|-------------|
| 1             | 52          | Right | Male   | 167         | 61          |
| 2             | 42          | Right | Male   | 182         | 76          |
| 3             | 66          | Left  | Male   | 175         | 74          |
| 4             | 58          | Right | Male   | 175         | 86          |
| 5             | 72          | Left  | Female | 164         | 68          |
| 6             | 86          | Right | Female | 163         | 55          |
| 7             | 86          | Left  | Female | 163         | 55          |
| 8             | 85          | Right | Female | 157         | 42          |
| 9             | 85          | Left  | Female | 157         | 42          |
| 10            | 38          | Right | Female | 160         | 62          |
| 11            | 38          | Left  | Female | 160         | 62          |
| 12            | 47          | Right | Male   | 176         | 78          |
| 13            | 47          | Left  | Male   | 176         | 78          |
| 14            | 62          | Right | Male   | 168         | 70          |
| 15            | 62          | Left  | Male   | 168         | 70          |
| mean value    | 61.7        |       |        | 167.4       | 65.3        |
| maximum value | 86          |       |        | 182         | 86          |
| minimum value | 38          |       |        | 157         | 42          |

branches for the accessory nerve to innervates the trapezius muscle.<sup>19</sup> These muscles do not receive exclusive C4 innervation: the adjacent roots of the cervical plexus also contribute to their innervation. Due to these multiple innervations, a C4 root section would cause minimum to no neurological deficit, except for the branch for the phrenic nerve, since C4 contributes with the largest amount of motor fibers to its formation compared to C3 and C5. This branch is spared by the technique we propose.

At the brachial plexus, the fibers coming from C5 innervate the shoulder, and their injury causes a sensitive deficit in the lateral region of the shoulder, in addition to external rotation and abduction deficits. Branches originating from the proximal portion of C5 (dorsal scapular nerve and contributions to the phrenic and long thoracic nerves) are considered compromised by C5 avulsion; therefore, they were sectioned to facilitate root mobilization.

Today, most neurotization procedures for shoulder movements reactivation include an accessory nerve transfer to the suprascapular nerve to stabilize the shoulder and provide some external rotation, and the transfer of a radial nerve branch innervating the triceps muscle for the axillary nerve, reactivating deltoid contraction to resume shoulder abduction. Abdouni et al.<sup>12</sup> demonstrated that isolated accessory nerve neurotization often has frustrating outcomes for shoulder function. In addition, the accessory nerve transfer prevents its future use in a free muscle flap neurotization. On the other hand, the axillary nerve neurotization

**Table 2** Nerve roots morphological characteristics

| #             | C4 length after phrenic nerve origin (mm) | C5 length after phrenic nerve origin (mm) | C5 length before phrenic nerve origin (mm) | C5 total length (mm) | C6 length (mm) | Space (Interval) between C4-C5 (mm) | Difference between C4 and C5 length (mm) |
|---------------|---|---|--|----------------------|----------------|-------------------------------------|--|
| 1             | 13  | 19  | 10   | 29                   | 18             | 10                                  | 16                                       |
| 2             | 14  | 18  | 8  | 26                   | 19             | 10                                  | 12                                       |
| 3             | 13  | 20  | 7  | 27                   | 18             | 10                                  | 14                                       |
| 4             | 11  | 20  | 7  | 27                   | 20             | 11                                  | 16                                       |
| 5             | 11  | 23  | 5  | 28                   | 15             | 9                                   | 17                                       |
| 6             | 13  | 18  | 7  | 25                   | 16             | 9                                   | 12                                       |
| 7             | 12  | 18  | 6  | 24                   | 15             | 9                                   | 12                                       |
| 8             | 13  | 21  | 7  | 28                   | 17             | 9                                   | 15                                       |
| 9             | 12  | 21  | 8  | 29                   | 18             | 9                                   | 17                                       |
| 10            | 12  | 19  | 8  | 27                   | 18             | 10                                  | 15                                       |
| 11            | 11  | 19  | 7  | 26                   | 17             | 10                                  | 15                                       |
| 12            | 14  | 20  | 8  | 28                   | 18             | 11                                  | 14                                       |
| 13            | 15  | 20  | 8  | 28                   | 19             | 11                                  | 13                                       |
| 14            | 12  | 18  | 9  | 27                   | 17             | 10                                  | 15                                       |
| 15            | 13  | 18  | 8  | 26                   | 16             | 10                                  | 13                                       |
| mean value    | 12.6                                      | 19.5                                      | 7.5  | 27.0                 | 17.4           | 9.9                                 | 14.4                                     |
| maximum value | 15  | 23  | 10   | 33                   | 20             | 11                                  | 17                                       |
| minimum value | 11  | 18  | 5  | 23                   | 15             | 9                                   | 12                                       |

requires an intact radial nerve, and it is restricted to upper (C5-C6) brachial plexus injuries.

Yamada et al.<sup>14-16</sup> described the C3-C4 root transfer for upper trunk (C5 and C6) avulsions reconstruction but the proposed technique required the interposition of a nerve graft for roots connection; this procedure increased the path for nerve regeneration, and graft placement resulted in a two-fold increase in suture. In an anatomical study, Tsai et al.<sup>6</sup> were able to coaptate the avulsed portion of C5 to C4 root with no need for a nerve graft; however, this procedure required a laminectomy and intracanal dissection, increasing its technical difficulty and resulting in higher morbidity.

Considering the virtually parallel path between C4 and C5 roots, the greater length of C5 compared to C4 associated with roots mobilization allows to cover the gap between these roots with no need for a nerve graft. For instance, at the first case, the space between roots (at the vertebral foramina level) requiring coverage was 10 mm and the difference between the length of C4 (after phrenic nerve emergence) and the total length of C5 was 16 mm, i.e., more than enough to cover the gap and perform a free-tension neurotization. In all cases, total C5 length was greater than C4 length and proved to be sufficient to cover the gap between roots and to perform neurotization without tension. In this study, we mobilized C5 to reach C4, and measurements were made from the vertebral foramen. In avulsion injuries, the available C5 length is likely to be even greater, even though the avulsed proximal segment requires resection.

Although neurotization of sensory and motor elements of the cervical plexus to repair brachial plexus injuries has been described for a long time,<sup>20</sup> C3 and C4 motor branches are usually very thin, with few nerve fibers, and not providing good outcomes in previous publications.

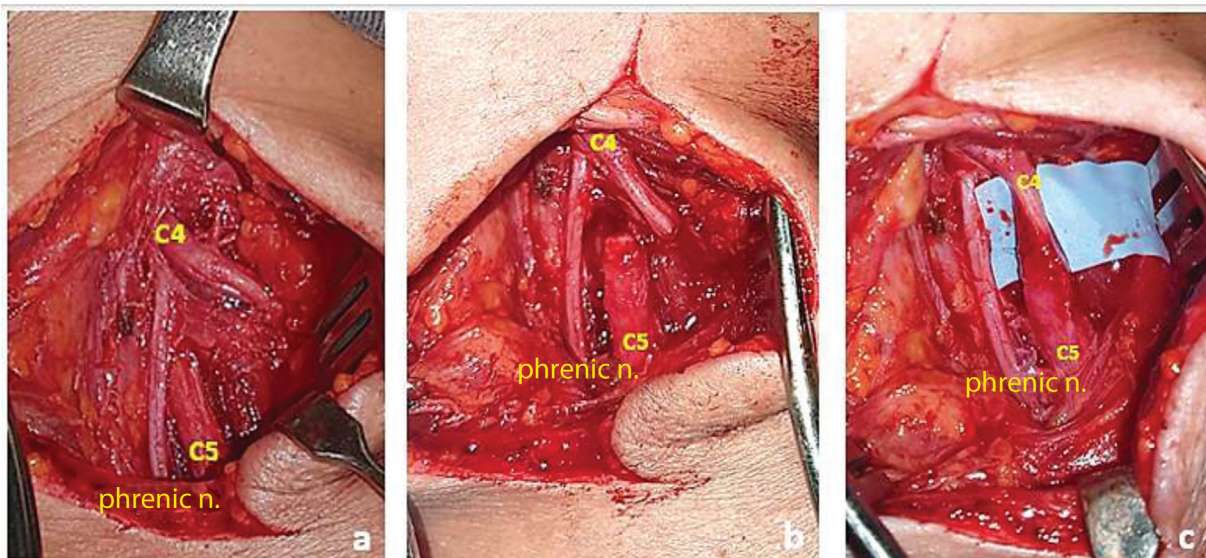
This technique aimed to include a greater amount of motor fibers in the neurotization, taking the C4 root along with motor fibers for the scalene, rhomboid, levator scapulae and trapezius muscles (communicating branches for the spinal accessory nerve).<sup>18,21,22</sup>

We recently operated on three patients with upper preganglionic injuries confirmed by magnetic resonance imaging (MRI) scans. Two of these subjects had a C5-C6-C7 lesion, with no possibility of radial nerve branch transfer to the axillary nerve, whereas the third patient had a C5-C6 lesion. In addition to C4-C5 neurotization (► **Figure 3**), we also performed the Oberlin procedure for biceps brachii reinnervation. In all cases, direct suture was feasible, with no nerve graft, and no deficit related to C4 root sacrifice was observed postoperatively. These outcomes are encouraging, although preliminary, since the time of postoperative follow-up ranges from 4 to 6 months. Our aim is to carry out a larger series of cases and wait for clinical outcomes to report them later.

This technique will allow shoulder musculature reinnervation to recover shoulder external rotation and abduction with a single neurotization, thus reducing the surgical time and postoperative morbidity. The accessory nerve is spared, and it can be used, if required, for another neurotization, as in gracilis free functional transfer. In addition, this technique may assist in the treatment of total, complex brachial plexus injuries.

## Conclusions

Simulated C4-C5 transfers were possible in all dissections using direct suture, with no tension. The technique proved to be safe but required a trained team and an experienced surgeon with extensive knowledge in regional anatomy.



**Fig. 3** Intraoperative images of the left cervical region. Dissection showing C4 and C5 roots and the phrenic nerve. (a). C4 root sectioned distal to the phrenic nerve origin and C5 root sectioned immediately after its exit from the intervertebral foramen (b). Neuroorrhaphy between C4 and C5 sparing the phrenic nerve (c).

**Financial Support**

There was no financial support from public, commercial, or non-profit sources.

**Conflict of Interests**

The authors declare no conflict of interests.

**References**

- 1 Flores LP. Estudo epidemiológico das lesões traumáticas de plexo braquial em adultos. *Arq Neuropsiquiatr* 2006;64(01):88–94
- 2 Mello Júnior JS, Souza TCR, Andrade FG, et al. Perfil Epidemiológico de Pacientes com Lesão Traumática do Plexo Braquial avaliados em um Hospital Universitário no Rio de Janeiro. *Rev Bras Neurol* 2012;48(03):5–8
- 3 Rezende MR, Rabelo NTA, Silveira Júnior CC, Petersen PA, De Paula EJJ, Mattar Júnior R. Resultado na neurotização do nervo ulnar para o músculo bíceps braquial na lesão do plexo braquial. *Acta Ortop Bras* 2012;20(06):317–323
- 4 Sedain G, Sharma MS, Sharma BS, Mahapatra AK. Outcome after delayed Oberlin transfer in brachial plexus injury. *Neurosurgery* 2011;69(04):822–827, discussion 827–828
- 5 Venkatramani H, Bhardwaj P, Faruquee SR, Sabapathy SR. Functional outcome of nerve transfer for restoration of shoulder and elbow function in upper brachial plexus injury. *J Brachial Plex Peripher Nerve Inj* 2008;3:15
- 6 Tsai YJ, Su FC, Hsiao CK, Tu YK. Comparison of objective muscle strength in C5-C6 and C5-C7 brachial plexus injury patients after double nerve transfer. *Microsurgery* 2015;35(02):107–114
- 7 Kaiser R, Waldauf P, Ullas G, Krajcovic A. Epidemiology, etiology, and types of severe adult brachial plexus injuries requiring surgical repair: systematic review and meta-analysis. *Neurosurg Rev* 2020;43(02):443–452
- 8 Ali ZS, Heuer GG, Faught RW, et al. Upper brachial plexus injury in adults: comparative effectiveness of different repair techniques. *J Neurosurg* 2015;122(01):195–201
- 9 Verdins K, Kapickis M. Oberlin's Transfer: Long Term Outcomes. *J Hand Surg Asian Pac Vol* 2018;23(02):176–180
- 10 Bertelli JA, Ghizoni MF. Reconstruction of C5 and C6 brachial plexus avulsion injury by multiple nerve transfers: spinal accessory to suprascapular, ulnar fascicles to biceps branch, and triceps long or lateral head branch to axillary nerve. *J Hand Surg Am* 2004;29(01):131–139
- 11 Liverneaux PA, Diaz LC, Beaulieu JY, Durand S, Oberlin C. Preliminary results of double nerve transfer to restore elbow flexion in upper type brachial plexus palsies. *Plast Reconstr Surg* 2006;117(03):915–919
- 12 Abdouni YA, Checoli GF, Salles HC, da Costa AC, Chakkour I, Fucc PMMB. Assessment of the results of accessory to suprascapular nerve transfer. *Acta Ortop Bras* 2018;26(05):332–334
- 13 Malessy MJ, de Ruiter GC, de Boer KS, Thomeer RT. Evaluation of suprascapular nerve neurotization after nerve graft or transfer in the treatment of brachial plexus traction lesions. *J Neurosurg* 2004;101(03):377–389
- 14 Yamada S, Peterson GW, Soloniuk DS, Will AD. Coaptation of the anterior rami of C-3 and C-4 to the upper trunk of the brachial plexus for cervical nerve root avulsion. *J Neurosurg* 1991;74(02):171–177
- 15 Yamada S, Lonser RR, Iacono RP, Morenski JD, Bailey L. Bypass coaptation procedures for cervical nerve root avulsion. *Neurosurgery* 1996;38(06):1145–1151, discussion 1151–1152
- 16 Yamada S, Lonser RR, Colohan AR, Yamada SM, Won DJ. Bypass coaptation for cervical root avulsion: indications for optimal outcome. *Neurosurgery* 2009;65(4, Suppl):A203–A211
- 17 Yang KX, Zhang SH, Ge DW, Sui T, Chen HT, Cao XJ. A novel extradural nerve transfer technique by coaptation of C4 to C5 and C7 to C6 for treating isolated upper trunk avulsion of the brachial plexus. *J Biomed Res* 2018;32(04):298–304
- 18 Netter FH. *Atlas of human anatomy*. 6th ed. Philadelphia: Elsevier; 2014
- 19 Ferrao A, Megali R, Papais RM. Surgical anatomy of the spinal accessory nerve: how to avoid injuries to the posterior cervical triangle during surgical procedures. *Rev Bras Cir Plást* 2009;24(04):400–413
- 20 Brunelli G. Neurotization of avulsed roots of the brachial plexus by means of anterior nerves of the cervical plexus. *Int J Microsurg* 1980;55:529–531
- 21 Tubbs RS, Shoja Mohamm Adali M, Loukas M, et al. Study of the cervical plexus innervation of the trapezius muscle. *J Neurosurg Spine* 2011;14:626–629
- 22 Gavid M, Mayaud A, Timochenko A, Asanau A, Prades JM. Topographical and functional anatomy of trapezius muscle innervation by spinal accessory nerve and C2 to C4 nerves of cervical plexus. *Surg Radiol Anat* 2016;38(08):917–922