

# Clinical, Genetic, and Outcome Characteristics of Pediatric Patients with Primary Hemophagocytic Lymphohistiocytosis

Serdar Nepesov<sup>1</sup>, Yöntem Yaman<sup>2</sup>, Murat Elli<sup>2</sup>, Nihan Bayram<sup>2</sup>, Kürşat Özdiği<sup>3</sup>, Ayça Kırıkım<sup>4</sup>, Deniz Çakır<sup>5</sup>, Betül Kılıç<sup>6</sup>, Kürşad Aydın<sup>6</sup>, Akif Ayaz<sup>7</sup>, Leyla Telhan<sup>8</sup>, Sema Anak<sup>2</sup>

<sup>1</sup>Department of Pediatric Allergy and Immunology, İstanbul Medipol University, Faculty of Medicine, İstanbul, Turkey

<sup>2</sup>Department of Pediatric Hematology and Oncology, İstanbul Medipol University, Faculty of Medicine, İstanbul, Turkey

<sup>3</sup>Department of Pediatric Bone Marrow Transplant Unit, İstanbul Medipol University, Faculty of Medicine, İstanbul, Turkey

<sup>4</sup>Department of Pediatric Allergy and Immunology, İstanbul University, Cerrahpaşa Medical Faculty, İstanbul, Turkey

<sup>5</sup>Department of Pediatric Infectious Diseases, Ümraniye Training and Research Hospital, University of Health Science, İstanbul, Turkey

<sup>6</sup>Department of Pediatric Neurology, İstanbul Medipol University, Faculty of Medicine, İstanbul, Turkey

<sup>7</sup>Department of Medical Genetics, İstanbul Medipol University, Faculty of Medicine, İstanbul, Turkey

<sup>8</sup>Department of Pediatric Intensive Care, İstanbul Medipol University, Faculty of Medicine, İstanbul, Turkey

## What is already known on this topic?

- Primary hemophagocytic lymphohistiocytosis is a life-threatening multi-organ disease, and fever may be the first and only symptom in the vast majority of patients. The main aim of treatment is to reduce excessive inflammation with standard treatment protocol for hemophagocytic lymphohistiocytosis 2004 and provide the disease remission with hematopoietic stem cell transplantation.

## What this study adds on this topic?

- In our pediatric primary hemophagocytic lymphohistiocytosis (HLH), 44% of patients presented neurological findings which point to the importance of neurologic findings in diagnosing primary HLH. In cohort 1, resistant patients benefited from anti-thymocyte globulin-combined regimen, which highlights the significance of considering alternative regimens in unresponsive patients.

### Corresponding author:

Serdar Nepesov

✉dr\_nepesov@hotmail.com

Received: November 1, 2021

Accepted: January 19, 2022

Content of this journal is licensed under a Creative Commons Attribution-NonCommercial 4.0 International License.



## ABSTRACT

**Objective:** In this study, we sought to describe the clinical, laboratory, and genetic characteristics of patients diagnosed with primary hemophagocytic lymphohistiocytosis. Thus, we aimed to evaluate the early diagnosis and appropriate treatment options for pediatric hemophagocytic lymphohistiocytosis patients.

**Materials and Methods:** Medical records of 9 patients diagnosed with primary hemophagocytic lymphohistiocytosis between November 2013 and December 2019 were analyzed retrospectively. Clinical, genetic, and laboratory characteristics, family histories, initial complaints, physical examination findings, age at diagnosis, treatment choices, and clinical follow-up of all patients were investigated.

**Results:** The mean age at diagnosis was 11 months (range: 1.5 months to 17 years). Genetic analysis was performed in all patients, and a disease-related mutation was detected in 8 (89%) of them. Among clinical features, 6 (66%) patients had fever, 5 (56%) had splenomegaly, 4 (44%) had lymphadenopathy, 4 (44%) had skin rash, and 4 (44%) had neurological findings. Hemophagocytosis was observed in the bone marrow samples of 6 (66%) patients. Disease remission was achieved in 7 (78%) patients. Hematopoietic stem cell transplantation was performed in 7 (78%) patients.

**Conclusion:** Hemophagocytic lymphohistiocytosis may present with different clinical symptoms that can cause a significant diagnostic delay. The only curative treatment option in primary hemophagocytic lymphohistiocytosis patients is hematopoietic stem cell transplantation. The chemotherapy should be started as early as possible, in order to achieve a disease remission. Patients should be referred to the appropriate bone marrow transplant center for hematopoietic stem cell transplantation as soon as they reach the disease remission.

**Keywords:** Genetic analysis, children, primary hemophagocytic lymphohistiocytosis

## INTRODUCTION

Hemophagocytic lymphohistiocytosis (HLH) is a life-threatening disease characterized by systemic inflammation and multi-organ failure as a result of excessive activation of the immune system.<sup>1</sup> There are 2 forms of the disease: primary (familial) and secondary HLH. Primary HLH is an autosomal recessive disorder caused by certain genetic mutations such as Perforin, Munc13-4, Syntaxin 11, and Munc18 genes. Additionally, it could be associated with

**Cite this article as:** Nepesov S, Yaman Y, Elli M, et al. Clinical, genetic, and outcome characteristics of pediatric patients with primary hemophagocytic lymphohistiocytosis. *Turk Arch Pediatri.* 2022;57(4):398-405.

different immunodeficiency conditions such as Griscelli syndrome type 2, Chediak-Higashi syndrome type 1, Hermansky-Pudlak syndrome type 2, and X-linked lymphoproliferative disease types 1 and 2.<sup>2</sup> Although the majority of familial HLH cases are diagnosed during the first year of life,<sup>3,4</sup> late-onset cases in adolescence or adulthood have been reported, as well.<sup>5,6</sup> The secondary form of the disease can be seen at all ages. In secondary HLH, the most common triggering factors are infections, especially viral agents, different rheumatological diseases, and malignancies.<sup>7</sup>

Hepatitis, splenomegaly, and cytopenia are the main findings of primary HLH, present in the majority of patients at the time of diagnosis.<sup>8</sup> The central nervous system (CNS) is one of the important organs involved in primary HLH. It could be seen at any time during the clinical follow-up.<sup>9</sup> Isolated CNS involvement can be seen, even in the lack of systemic findings.<sup>10</sup> Bicytopenia or pancytopenia, especially thrombocytopenia, is present at the onset of the disease. Hypertriglyceridemia, hypofibrinogenemia, increased ferritin, hyponatremia, and low protein/albumin ratio are other common findings.<sup>4</sup> In the past 20 years, pHLH is a fatal disease, and the mean survival is reported as 2 months in untreated cases.<sup>11</sup> Currently, the treatment that provides a cure in primary HLH is allogeneic hematopoietic stem cell transplantation (HSCT) after the patient has achieved remission with anti-inflammatory therapy.<sup>12</sup>

In this study, it was aimed to define the clinical, laboratory, and genetic findings of patients diagnosed with familial HLH. Thus, it was aimed to make a contribution to the early identification and timely treatment of the disease.

## MATERIALS AND METHODS

### Study Population

Data of primary HLH patients in the pediatric hematology unit between November 2013 and December 2019 were retrospectively analyzed by examining the patient files and electronic recording systems.

The diagnosis of 8 of 9 patients was made according to the hemophagocytic lymphohistiocytosis 2004 (HLH-2004) diagnostic criteria set by the International Histiocyte Society.<sup>6</sup> The diagnostic criteria used are shown in Table 1. One patient was diagnosed as a result of genetic examination due to the death of a sibling.

### Collected Data

Demographic information of patients, age at diagnosis, family history, initial complaints, examination findings, laboratory examinations (blood count, ferritin, liver function tests, lipid profile, infection serologies, bone marrow aspiration, and cerebrospinal fluid evaluations), cranial imaging, genetic examinations, and treatment options were recorded. Natural killer (NK) cell activity and dissolved CD25 (sCD25) level were studied only in 1 patient.

### Statistical Analysis

The Statistical Package for Social Sciences version 20.0 software (IBM Corp.; Armonk, NY, USA) was used for statistical analysis. A descriptive statistical test has been performed.

**Table 1.** Hemophagocytic lymphohistiocytosis (HLH) 2004 diagnostic criteria (6).

1. Molecular diagnosis associated with HLH or
2. HLH diagnostic criteria (mandatory 5 out of 8 criteria)
a. Fever (>7 days, >38.5°C)
b. Splenomegaly
c. Cytopenia (affecting 2 or more series in the peripheral blood)
I. Hemoglobin <9 g/dL (in infants younger than 4 weeks: Hgb <10 g/dL)
II. Platelet (<100 × 10 <sup>9</sup> /L)
III. Neutrophil (<1.0 × 10 <sup>9</sup> /L)
d. Hypertriglyceridemia and/or hypofibrinogenemia
i. Fasting triglyceride level ≥3 mmol/L or ≥265 mg/dL
ii. Fibrinogen ≤1.5 g/L
e. Hemophagocytosis in the bone marrow, spleen or lymph nodes
f. Malignant diseases should be ruled out
New diagnostic criteria
g. Low or no NK cell activity
h. Ferritin ≥500 µg/L 8
i. Soluble CD25 (soluble IL2 receptor) ≥2400 U/MI

Numerical data were expressed as mean ± standard deviation and categorical data as frequency (n) and percentage (%).

### Ethical Approval

The study was carried out in accordance with the principles of the Declaration of Helsinki. Approval for the study was obtained from the ethical committee of Istanbul Medipol (April 2020, Decision number: 16412). Written informed consent was obtained from the parents of all patients.

## RESULTS

Nine patients from 8 families were included in the study. The median age at diagnosis was 11 months (1.5 months to 17 years). Five patients (56%) were female and 4 were male (44%). There was consanguinity among the parents of 6 (67%) patients, a history of sibling death in 4 (44%) patients, and a history of recurrent miscarriage in the mothers of 2 (22%) patients. The demographic and clinical characteristics of the patients are summarized in Table 2.

Genetic analysis was performed on all the patients, and positive mutations were detected in 8 (89%) of them. In 1 (11%) patient, there was no recorded mutation. This patient had a history of consanguineous marriage and was accepted as primary HLH because the disease relapsed during treatment. Recorded mutations were *UNC13D* in 3, *SH2D1A* in 2, and *PRF1*, *RAB27C*, and *LYST* mutations in 1 patient, respectively.

While 8 of the 9 patients included in the study had symptoms, 1 patient was asymptomatic, and a diagnosis of primary HLH was based on the family screening due to the index case. At the time of diagnosis, 5 (56%) of the patients had fever, 5 (56%) had splenomegaly, 4 (44%) had lymphadenopathy, 4 (44%) had skin rash, and 4 (44%) had neurological findings. The laboratory characteristics of the cases in terms of HLH criteria at the time of diagnosis are summarized in Table 3.

Of the 4 (44%) patients with neurological findings, 2 (22%) had convulsions, 1 (11%) had ataxia, and 1 (11%) had headache

**Table 2.** Demographic and Clinical Features of Primary Hemophagocytic Lymphohistiocytosis Patients

Patients (N = 9)	P1	P2	P3	P4	P5	P6	P7*	P8*	P9
FHL subtype	FHL1	CHS1	FHL3	FHL3	FHL2	FHL3	XLP1	XLP1	GS2
Gender	Female	Male	Female	Female	Male	Female	Male	Male	Female
Age at diagnosis	36 months	1.5 months	1.5 months	5 months	22 months	3 months	11 months	18 months	17 years
Consanguinity	Yes	Yes	Yes	Yes	Yes	No	No	No	Yes
Sibling death	No	Yes	Yes	No	Yes	No	Yes	No	No
Neurologic alteration	No	No	No	No	Yes	No	Yes	Yes	Yes
Cutaneous rash	Yes	No	No	Yes	No	No	Yes	No	Yes
PICU	No	No	No	No	Yes	No	Yes	Yes	Yes
Treatment	HSCT	HSCT	HSCT	HSCT	NR	HSCT	HSCT	NR	HSCT
Outcome	Alive	Alive	Alive	Alive	Died	Alive	Alive	Died	Alive
Age at the study or age of death	10 years	1 year 6 months	2 years 7 months	5 years	1 year 10 months	1 year	3 years	1 year 6 months	17 years 6 months

\*P7 and P8 are brothers.

FHL, familial hemophagocytic lymphohistiocytosis; CHS1, Chediak-Higashi syndrome type1; XLP1, X-linked lymphoproliferative disease type 1; GS2, Griscelli syndrome type 2; PICU, pediatric intensive care unit; HSCT, hematopoietic stem cell transplantation; NR, no remission.

and dizziness. The analysis of the cerebrospinal fluid (CSF) of these patients revealed high protein level and pleocytosis. Two patients had isolated CNS involvement. Epstein-Bar virus (EBV) was detected in the polymerase chain reaction of CSF of 2 patients. Before diagnosis, 2 patients were followed up for acute disseminated encephalomyelitis and 1 for encephalitis.

Cerebral and cerebellar white matter and asymmetrical hyperintense lesions in the brain stem were seen on T2-weighted and FLAIR (Fluid attenuated inversion recovery) images in 3 of 4 patients with neurological symptoms. Three of these patients had significant patchy contrast enhancement, 2 patients had corpus callosum and thalamus involvement. These lesions, which were defined in the cerebral white matter, brain stem, and basal ganglia, had an edematous appearance with a mass effect (Figures 1 and 2). Limited diffusion restriction was observed on diffusion-weighted images. Only mild cerebral atrophy was detected in 1 patient, and no white matter and brain stem involvement or contrast enhancement was observed in the brain magnetic resonance imaging (MRI) of this patient.

Bone marrow examination was performed in 8 patients, while hemophagocytosis was observed in 6 of them.

Eight of the 9 patients were treated with the HLH-2004 protocol.<sup>6</sup> Intravenous immunoglobulin was given to 4 (44%) patients as supportive treatment. Anti-CD20 (rituximab) was used in 2 (22%) patients with EBV infection. In addition, rabbit-derived anti-thymocyte globulin (ATG) was given additionally to 3 patients who did not achieve remission or who relapsed while receiving the HLH-2004 protocol. While remission was achieved in 6 patients in total, 2 patients died despite all treatments. Central nervous system involvement was also present in 2 patients who died.

Hematopoietic stem cell transplantation was performed in 7 of 9 patients. Four of the donors were perfectly matched siblings and the other 3 were completely matched unrelated donors (MUD). All patients were given a myeloablative and low-toxicity priming regimen (treosulfan 14 mg/m<sup>2</sup>/day for patients over

1 year old, 12 mg/m<sup>2</sup>/day for patients under 1 year old, for 3 days; fludarabine 30 mg/m<sup>2</sup>/day for 5 days and ATG 10 mg/kg/day for 3 days). Engraftment was performed in all patients. Patients who have undergone HSCT are all in remission and 5 of them are still being followed at our clinic as full chimeric. The median follow-up period of the patients was 24 months (7-66 months). The overall survival probability of the patients was calculated as 78%.

## DISCUSSION

Hemophagocytic lymphohistiocytosis is a severe, potentially fatal multisystemic disease characterized by the overactivation of the immune system. Early diagnosis and early initiation of treatment are very important in order to prevent life-threatening complications.

Although the incidence of primary HLH varies, it is reported to be approximately 1.2/1 000 000 under the age of 15.<sup>13</sup> Due to the high rate of consanguineous marriages in Turkey, the incidence was reported as 1/1400 in the study conducted by Gürgey et al.<sup>14</sup>

In our study, 67% of the patients had consanguinity between the parents. In other studies, among HLH patients in Turkey, the rates of consanguineous marriages were reported as 70% and 100%.<sup>15,16</sup> These rates are higher in studies than those reported in studies from other countries.<sup>17,18</sup>

Primary HLH is mostly diagnosed under 1 year of age.<sup>7,8</sup> In our data, the median age of diagnosis was 11 months and 55% of them were diagnosed under 1 year of age. One of our patients (P9) was diagnosed with primary HLH (GS2) during adolescence. In the literature, cases with late disease onset have been sporadically reported.<sup>19,20</sup> Primary HLH may very rarely occur in the intrauterine period and cause hydrops fetalis.<sup>21,22</sup> In our 2 patients (P5 and P6), the mother had a history of hydrops fetalis and abortion in the last trimester, and no etiology was found to explain the situation. In the sibling genetic analyses of these patients, *PRF1* mutations were found in 1 patient and *UNC13D* mutations in the other.

**Table 3.** Laboratory Findings of the Primary Hemophagocytic Lymphohistiocytosis Patients at Diagnosis

Patients (N = 8)	P1	P2	P3	P4	P5	P6	P7	P8	P9
Gene	Unknown	LYST	UNC13D	UNC13D	PRF1	UNC13D	SH2D1A	SH2D1A	RAB27
Mutation	Not done	Homozygous	Homozygous	Homozygous	Compound heterozygous	Compound heterozygous	Deletion	Deletion	Homozygous
Hemoglobin (g/dL)	7.8	10.7	8.8	7.8	10.5	9.8	8.6	9.7	9.4
Platelets (cells/mm <sup>3</sup> )	24 000	406 000	110 000	89 000	240 000	180 000	88 000	526 000	45 000
ANC (cells/mm <sup>3</sup> )	100	410	840	860	2470	970	1127	9000	2160
Triglycerides (mg/dL)	706	150	310	370	156	280	202	457	210
Fibrinogen (mg/dL)	80	170	141	111	195	104	148	238	180
Ferritin (µg/L)	1100	150	3019	2001	181	1300	9840	1326	236
AST (U/L)	418	36	214	270	45	98	576	142	80
ALT (U/L)	256	17	238	310	46	110	310	300	88
LDH (U/L)	745	167	426	440	180	240	577	426	182
Albumin (g/dL)	2.6	4.5	3.6	2.6	3.4	3.6	2.7	3.2	3.1
Hemophagocytosis in bone marrow	Yes	Not done	Yes	Yes	No	Yes	Yes	Yes	No
Associated infections	No	No	No	No	No	No	EBV	EBV	No
Protein in CSF	No	Not done	No	No	Yes	No	Yes	Yes	Yes

ANC, absolute neutrophil counts; EBV, Epstein-Barr virus; CSF, cerebrospinal fluid; AST, aspartate aminotransferase; ALT, alanine transaminase; LDH, lactate dehydrogenase.

In the study by Allen et al<sup>5</sup>, primary HLH diagnosis made by genetic examination was reported in 4 asymptomatic patients with a history of sibling death. In our case, 1 (P2) patient was asymptomatic at the time of diagnosis and primary HLH (GHS 1) was diagnosed by genetic examination due to a history of sibling death. In patients diagnosed with primary HLH, sibling and family inquiries and genetic examination in suspicious cases lead to early diagnosis and timely initiation of treatment.

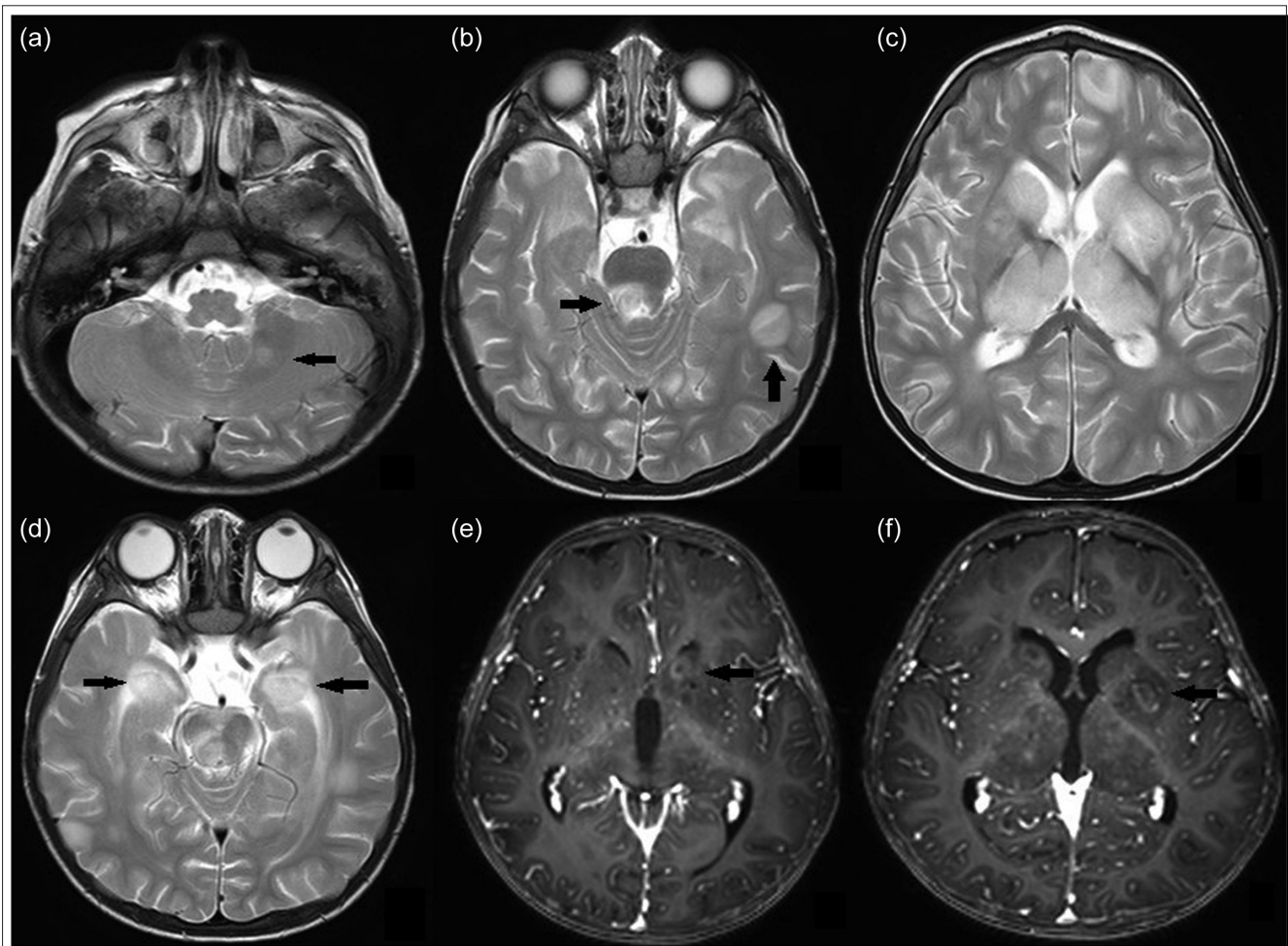
Although a variety of symptoms may occur, fever may be the first and only symptom in most patients with primary HLH. In our study, fever was the most common symptom, and it was present in 6 (66%) of the patients. Primary HLH should always be kept in mind in cases with fever of unknown origin and appropriate investigations should be conducted.

Neurological symptoms may be the initial feature of the disease in approximately 20% of patients, and CNS is one of the most important systems involved.<sup>15,23,24</sup> In different studies, the rate of CNS involvement has been reported as 10-70%.<sup>24-26</sup> Symptoms are variable, including headache, cranial nerve palsy, hemiparesis, ataxia, and convulsions. Central nervous system involvement may be very common in children with HLH.<sup>27,28</sup> Brain MRI findings are similar to those seen in most of the white matter disorders, but HLH is often fatal if left untreated, so it should be kept in mind until it is excluded.<sup>29</sup> In pediatric patients with unexplained neurological findings and a consanguineous history, the possibility of primary HLH should be considered, and CSF examination, neuroradiological imaging, and genetic examination should be performed. In addition, new diagnostic criteria should be defined for patients with isolated CNS involvement. Our 4 (44%) (P5, P7, P8, and P9) patients had CNS symptoms such as altered consciousness, ataxia, headache, restlessness, and convulsions, and all of them had CSF findings of proteinuria and pleocytosis (Figures 1 and 2). Two of these patients (P5 and P9) presented with isolated CNS involvement, and genetic analysis revealed PRF1 (P5) in 1 patient and GS2 (P9) mutation in the other patient.

The data on the incidence of neuroradiological abnormalities in HLH are limited, but we know that approximately one-third of brain computed tomography and MRI images have pathological findings. Abnormal imaging features have been reported even in patients with HLH without CSF abnormalities and neurological symptoms.<sup>30</sup> Brain MRI findings include foci of white matter with high T2 signal intensity, variable nodular or ring-shaped focal lesions in cortical and subcortical regions, leptomeningeal enhancement, and cerebral volume loss that can lead to enlarged ventricles and significant extra-axial fluid.<sup>31</sup> T2 hyperintensity of white matter is thought to be a result of the irregular distribution of histiocytes infiltrating brain tissue. Contrast enhancement is a demonstration of inflammation along the cranial nerves or spinal roots.<sup>32</sup> Diffusion-weighted images can be helpful in diagnosis. Diffusion restriction represents active inflammation in the brain as a result of an abnormal immune response that crosses the blood-brain barrier.<sup>33</sup>

In primary HLH patients, varying rates of cytopenia, splenomegaly, hypertriglyceridemia, hemophagocytosis, elevated ferritin, and decreased or absent NK are observed. Anemia and





**Figure 1** . (Patient 8) T2-weighted images: asymmetrical hyperintense lesions in the cerebellar white matter (A), supratentorial gray and white matter junctions (B), brain stem (B and D), bilateral caudate nucleus and thalamus (C), and amygdala (D) with a weak contrast (D, E, and F).

thrombocytopenia are the most common hematologic findings,<sup>34</sup> which was consistent with our findings.

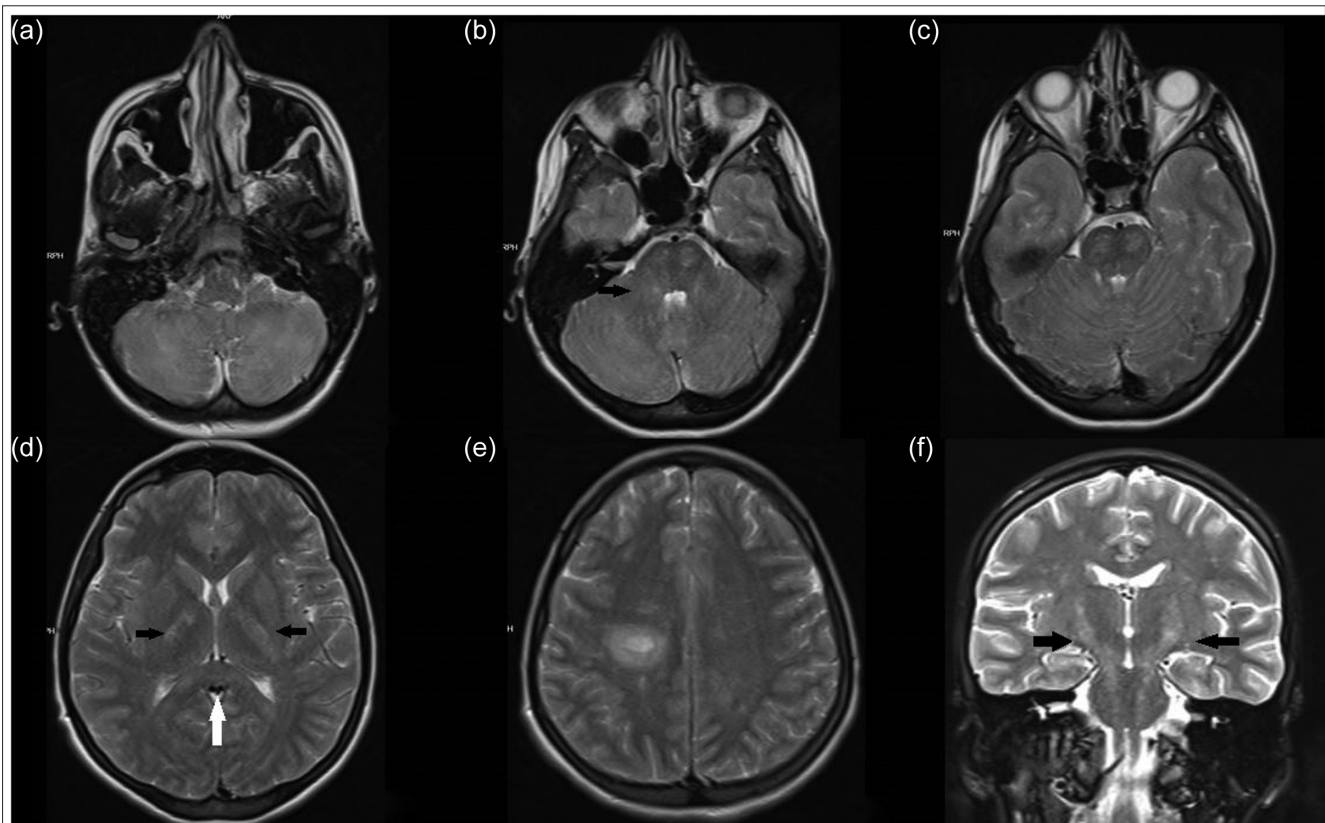
Serum ferritin level above 500 µg/L is an important laboratory finding for diagnosis, but it should be kept in mind that patients can also be diagnosed with normal ferritin levels.<sup>35</sup> In our study, ferritin levels were normal in 3 patients.

The agents most associated with HLH are herpesviruses, especially EBV infection which can trigger any form of primary HLH and X-linked lymphoproliferative disease.<sup>36,37</sup> In our series, in 2 (P7 and P8) siblings with neurological findings (Figure 1), X-linked lymphoproliferative type 1 disease due to *SH2D1A* mutation was detected in a genetic examination performed following the detection of EBV infection in CSF examination. Consequently, it is recommended to examine the cases with EBV infection in terms of primary HLH.

Untreated pHLH is a fatal condition with an average survival of about 2 months. The aim of treatment is to reduce excessive inflammation and provide the remission with HSCT.<sup>38</sup> In EBV-associated pHLH patients, rituximab can be used to eliminate EBV-activated B lymphocytes.<sup>39</sup> In our series, the HLH-2004 protocol was applied to 8 symptomatic patients.

Intravenous immunoglobulin was used as supportive treatment in 4 patients, and an anti-CD20 antibody (rituximab) was used in addition to treatment in 2 patients with EBV infection. Despite these treatments, remission could not be achieved in 3 patients with CNS involvement and ATG (10 mg/kg/day for 3 days) was added to the treatment. Remission was achieved with ATG in 1 of these 3 patients, and HSCT was performed from the MUD 20 days later. In the literature, it has been reported that remission was achieved in 73% of pediatric HLH patients treated with ATG.<sup>40,41</sup> In other words, the ATG option should be kept in mind to achieve remission in resistant patients who were previously treated according to the HLH-2004 protocol.

Coronavirus disease-2019 (COVID-19), caused by severe acute respiratory syndrome coronavirus 2, is typically presented by fever, cough, shortness of breath, myalgia, and fatigue.<sup>42</sup> However, a significant proportion of cases develop severe/critical manifestations with persistent fever, cytopenia, and laboratory abnormalities consistent with hyperinflammation (hyperferritinemia, hypertriglyceridemia, and hypofibrinogenemia). Several studies have shown that the hyperinflammatory syndrome in severe COVID-19 is due to the overactivation of monocytes/macrophages leading to increased secretion of proinflammatory cytokines resulting



**Figure 2.** (Patient 9) T2-weighted images: cerebellar white matter (A), hyperintense lesion with irregular borders with prominent mass effect on the right cerebellar peduncle (B, black arrow), asymmetrical patchy lesions in the mesencephalon level (C), internal capsule posterior legs (D, black arrows), periventricular area (D), corpus callosum splenium (D), white arrow), prominent tumefactive character on the right at the centrum semiovale level (E), along the pyramidal tract (F), hyperintense lesions (E).

in uncontrolled cytokine storm.<sup>43</sup> The clinical and laboratory similarity in severe COVID-19 and HLH has caused scientific controversy. While some authors recommend that all patients with severe COVID-19 should be screened for HLH,<sup>43</sup> others argue that many of these patients develop acute respiratory distress syndrome, which resembles features of lung-centered, localized HLH rather than a systemic macrophage activation.<sup>44</sup> Therefore, some authors propose a specific terminology and classification that may help identify patients at high risk for severe COVID-19.<sup>45</sup>

## CONCLUSION

Primary HLH is a potentially fatal disease that can appear at any time during childhood with most patients showing symptoms in early childhood. Hematopoietic stem cell transplantation is the only curative treatment option. Genetic examination should be performed in patients who are thought to have primary HLH. A suitable donor should be sought as early as possible for patients with a confirmed diagnosis, and HSCT should be performed as soon as the patients reach remission.

**Ethics Committee Approval:** This study was approved by Ethics committee of İstanbul Medipol University, (Approval No: 16412).

**Informed Consent:** Written informed consent was obtained from the patients who agreed to take part in the study.

**Peer-review:** Externally peer-reviewed.

**Author Contributions:** Concept- X.X., X.X.; Design - X.X., X.X.; Supervision - X.X., X.X.; Funding -X.X., X.X.; Materials - X.X., X.X.; Data Collection and/or Processing -X.X., X.X.; Analysis and/or Interpretation - X.X., X.X.; Literature Review -X.X., X.X.; Writing - X.X., X.X.; Critical Review - X.X., X.X.

**Declaration of Interests:** The authors have no conflict of interest to declare.

**Funding:** The authors declared that this study has received no financial support.

## REFERENCES

- Hayden A, Park S, Giustini D, Lee AY, Chen LY. Hemophagocytic syndromes (HPSs) including hemophagocytic lymphohistiocytosis (HLH) in adults: a systematic scoping review. *Blood Rev.* 2016;30(6):411-420. [CrossRef]
- Filipovich A, McClain K, Grom A. Histiocytic disorders: recent insights into pathophysiology and practical guidelines. *Biol Blood Marrow Transplant.* 2010;16(1):S82-S89. [CrossRef]
- Janka GE. Familial hemophagocytic lymphohistiocytosis. *Eur J Pediatr.* 1983;140(3):221-230. [CrossRef]
- Aricò M, Janka G, Fischer A, et al. Hemophagocytic lymphohistiocytosis. Report of 122 children from the International Registry. FHL Study Group of the Histiocyte Society. *Leukemia.* 1996;10(2):197-203.

5. Allen M, De Fusco C, Legrand F, et al. Familial hemophagocytic lymphohistiocytosis: how late can the onset be? *Haematologica*. 2001;86(5):499-503.
6. Henter JI, Horne A, Aricó M, et al. HLH-2004: diagnostic and therapeutic guidelines for hemophagocytic lymphohistiocytosis. *Pediatr Blood Cancer*. 2007;48(2):124-131. [CrossRef]
7. Filipovich AH. Hemophagocytic lymphohistiocytosis (HLH) and related disorders. *Hematology Am Soc Hematol Educ Program*. 2009;1:127-131. [CrossRef]
8. Gholam C, Grigoriadou S, Gilmour KC, Gaspar HB. Familial haemophagocytic lymphohistiocytosis: advances in the genetic basis, diagnosis and management. *Clin Exp Immunol*. 2011;163(3):271-283. [CrossRef]
9. Haddad E, Sulis ML, Jabado N, Blanche S, Fischer A, Tardieu M. Frequency and severity of central nervous system lesions in hemophagocytic lymphohistiocytosis. *Blood*. 1997;89(3):794-800. [CrossRef]
10. Puliyeel MM, Rose W, Kumar S, Moses PD, Gibikote S. Prolonged neurologic course of familial hemophagocytic lymphohistiocytosis. *Pediatr Neurol*. 2009;41(3):207-210. [CrossRef]
11. Henter JI, Elinder G, Söder O, Ost A. Incidence in Sweden and clinical features of familial hemophagocytic lymphohistiocytosis. *Acta Paediatr Scand*. 1991;80(4):428-435. [CrossRef]
12. Nespoli L, Locatelli F, Bonetti F, et al. Familial haemophagocytic lymphohistiocytosis treated with allogeneic bone marrow transplantation. *Bone Marrow Transplant*. 1991;7(suppl 3):139-142.
13. Niece JA, Rogers ZR, Ahmad N, Langevin AM, McClain KL. Hemophagocytic lymphohistiocytosis in Texas: observations on ethnicity and race. *Pediatr Blood Cancer*. 2010;54(3):424-428. [CrossRef]
14. Gürgey A, Göğüş S, Ozyürek E, et al. Primary hemophagocytic lymphohistiocytosis in Turkish children. *Pediatr Hematol Oncol*. 2003;20(5):367-371. [CrossRef]
15. Beken B. *The Evaluation of Hemophagocytic Lymphohistiocytosis Patients Followed in Hacettepe University İhsan Doğramacı Children's Hospital*. Ankara: Hacettepe University; 2013.
16. Fişgın T, Patiroğlu T, Özdemir A, et al. Clinical and laboratory data of primary hemophagocytic lymphohistiocytosis: a retrospective review of the Turkish Histiocyte Study Group. *Turk J Haematol*. 2010;27(4):257-262. [CrossRef]
17. Horne A, Trottestam H, Aricó M, et al. Frequency and spectrum of central nervous system involvement in 193 children with haemophagocytic lymphohistiocytosis. *Br J Haematol*. 2008;140(3):327-335. [CrossRef]
18. Ishii E, Ohga S, Tanimura M, et al. Clinical and epidemiologic studies of familial hemophagocytic lymphohistiocytosis in Japan. Japan LCH Study Group. *Med Pediatr Oncol*. 1998;30(5):276-283. [CrossRef]
19. Sieni E, Cetica V, Piccin A, et al. Familial hemophagocytic lymphohistiocytosis may present during adulthood: clinical and genetic features of a small series. *PLOS ONE*. 2012;7(9):e44649. [CrossRef]
20. Henkes M, Finke J, Warnatz K, et al. Late-onset hemophagocytic lymphohistiocytosis (HLH) in an adult female with Griscelli syndrome type 2 (GS2). *Ann Hematol*. 2015;94(6):1057-1060. [CrossRef]
21. Shah AJ, Kapoor N, Cooper RM, et al. Pre- and post-natal treatment of hemophagocytic lymphohistiocytosis. *Pediatr Blood Cancer*. 2009;52(1):139-142. [CrossRef]
22. Bechara E, Djoud F, de Saint Basile G, Bertrand Y, Pondarré C. Hemophagocytic lymphohistiocytosis with Munc13-4 mutation: a cause of recurrent fatal hydrops fetalis. *Pediatrics*. 2011;128(1):e251-e254. [CrossRef]
23. Gurgey A, Aytac S, Balta G, Oguz KK, Gumruk F. Central nervous system involvement in Turkish children with primary hemophagocytic lymphohistiocytosis. *J Child Neurol*. 2008;23(11):1293-1299. [CrossRef]
24. Gokce M, Balta G, Unal S, Oguz K, Cetin M, Gumruk F. Spinal cord involvement in a child with familial hemophagocytic lymphohistiocytosis. *J Pediatr Neurosci*. 2012;7(3):194-196. [CrossRef]
25. Zhao YZ, Cheng H, Ding CH, et al. Neurological abnormality could be the first and only symptom of familial hemophagocytic lymphohistiocytosis: report of two families. *Chin Med J (Engl)*. 2018;131(24):3004-3006. [CrossRef]
26. Janka GE, Schneider EM. Modern management of children with haemophagocytic lymphohistiocytosis. *Br J Haematol*. 2004;124(1):4-14. [CrossRef]
27. Chung TW. CNS involvement in hemophagocytic lymphohistiocytosis: CT and MR findings. *Korean J Radiol*. 2007;8(1):78-81. [CrossRef]
28. Cai G, Wang Y, Liu X, Han Y, Wang Z. Central nervous system involvement in adults with haemophagocytic lymphohistiocytosis: a single-center study. *Ann Hematol*. 2017;96(8):1279-1285. [CrossRef]
29. Benson LA, Li H, Henderson LA, et al. Pediatric CNS-isolated hemophagocytic lymphohistiocytosis. *Neurol Neuroimmunol Neuroinflamm*. 2019;6(3):e560. [CrossRef]
30. Janka GE. Hemophagocytic syndromes. *Blood Rev*. 2007;21(5):245-253. [CrossRef]
31. Fitzgerald NE, MacClain KL. Imaging characteristics of hemophagocytic lymphohistiocytosis. *Pediatr Radiol*. 2003;33(6):392-401. [CrossRef]
32. Chiapparini L, Uziel G, Vallinoto C, et al. Hemophagocytic lymphohistiocytosis with neurological presentation: MRI findings and a nearly miss diagnosis. *Neurol Sci*. 2011;32(3):473-477. [CrossRef]
33. Yang S, Zhang L, Jia C, Ma H, Henter JI, Shen K. Frequency and development of CNS involvement in Chinese children with hemophagocytic lymphohistiocytosis. *Pediatr Blood Cancer*. 2010;54(3):408-415. [CrossRef]
34. Palazzi DL, McClain KL, Kaplan SL. Hemophagocytic syndrome in children: an important diagnostic consideration in fever of unknown origin. *Clin Infect Dis*. 2003;36(3):306-312. [CrossRef]
35. McClain KL, Eckstein O. Clinical features and diagnosis of hemophagocytic lymphohistiocytosis 2021. Available at: <https://www.uptodate.com/contents/clinical-features-and-diagnosis-of-hemophagocytic-lymphohistiocytosis>; updated 16/09/2021; cited 2021 January.
36. Marsh RA, Madden L, Kitchen BJ, et al. XIAP deficiency: a unique primary immunodeficiency best classified as X-linked familial hemophagocytic lymphohistiocytosis and not as X-linked lymphoproliferative disease. *Blood*. 2010;116(7):1079-1082. [CrossRef]
37. Lai W, Wang Y, Wang J, Wu L, Jin Z, Wang Z. Epstein-Barr virus-associated hemophagocytic lymphohistiocytosis in adults and adolescents—a life-threatening disease: analysis of 133 cases from a single center. *Hematology*. 2018;23(10):810-816. [CrossRef]
38. Jordan MB, Allen CE, Weitzman S, Filipovich AH, McClain KL. How I treat hemophagocytic lymphohistiocytosis. *Blood*. 2011;118(15):4041-4052. [CrossRef]
39. Trottestam H, Horne A, Aricó M, et al. Chemoimmunotherapy for hemophagocytic lymphohistiocytosis: long-term results of the HLH-94 treatment protocol. *Blood*. 2011;118(17):4577-4584. [CrossRef]
40. Kakinoki Y, Ishio T, Kimura H, et al. Successful salvage treatment with antithymocyte globulin for patients with early-onset hemophagocytic lymphohistiocytosis refractory to steroid and etoposide therapy following allogeneic hematopoietic stem cell transplantation. *Bone Marrow Transplant*. 2020;55(7):1479-1482. [CrossRef]
41. Mahlaoui N, Ouachée-Chardin M, de Saint Basile G, et al. Immunotherapy of familial hemophagocytic lymphohistiocytosis with antithymocyte globulins: a single-center retrospective report of 38 patients. *Pediatrics*. 2007;120(3):e622-e628. [CrossRef]

42. Opoka-Winiarska V, Grywalska E, Roliński J. Could hemophagocytic lymphohistiocytosis be the core issue of severe COVID-19 cases? *BMC Med.* 2020;18(1):214. [\[CrossRef\]](#)
43. Gómez-Rial J, Rivero-Calle I, Salas A, Martínón-Torres F. Role of monocytes/macrophages in Covid-19 pathogenesis: implications for therapy. *Infect Drug Resist.* 2020;13:2485-2493. [\[CrossRef\]](#)
44. Retamozo S, Brito-Zerón P, Sisó-Almirall A, Flores-Chávez A, Soto-Cárdenas MJ, Ramos-Casals M. Haemophagocytic syndrome and COVID-19. *Clin Rheumatol.* 2021;40(4):1233-1244. [\[CrossRef\]](#)
45. Webb BJ, Peltan ID, Jensen P, et al. Clinical criteria for COVID-19-associated hyperinflammatory syndrome: a cohort study. *Lancet Rheumatol.* 2020;2(12):e754-e763. [\[CrossRef\]](#)