

# Poor pathogenetic role of luminal obstruction in the development of appendicitis

## A case report

Francesco Giudici, MD, PhD<sup>a,\*</sup>, Stefano Scaringi, MD<sup>a</sup>, Daniela Zambonin, MD<sup>a</sup>, Costantino Voglino, MD<sup>a</sup>, Luca Messerini, MD<sup>b</sup>, Ferdinando Ficari, MD<sup>a</sup>, Paolo Bechi, MD<sup>a</sup>

### Abstract

**Rationale:** In developed countries, the incidence of acute appendicitis is about 95 cases out of 100,000 per year, being one of the most common urgencies in general surgery worldwide. However, its pathogenesis is still poorly understood. Direct luminal obstruction (by a fecalith, lymphoid hyperplasia, or impacted stool) is reported to be the primary and principal cause of acute appendicitis.

**Patient concerns:** During October 2016 a 58-year-old woman was operated because of a clinical recurrence of Crohn's disease. At surgery, performed through single incision laparoscopy, we observed an exceptional finding.

**Diagnoses:** Despite a previous ileo-cecal resection, the appendix was still present and vascularized by small vessels within the mesoappendix connected to the neo-terminal ileum mesentery; it was about 5 cm long and macroscopically not inflamed even if its base was clearly no longer connected with the cecum.

**Outcomes:** The patient underwent ileo-colic resection with en-bloc removal of the appendix. With a narrow metallic stylet probe we carefully tried to enter the appendix lumen through the opposite side from its fundus but we were not able to enter it before cutting the wall with scissors. Pathological examination confirmed the Crohn's disease recurrence affecting the small bowel and the appendix lumen obstructed in the presence of a fecalith but without any sign of inflammation.

**Lessons:** This finding seems to highlight the poor pathogenetic role of luminal obstruction in the development of acute appendicitis.

**Abbreviations:** MRI = magnetic resonance imaging, SILS = single incision laparoscopic surgery, TNF $\alpha$  Ab = tumor necrosis factor alpha antibodies.

**Keywords:** appendicitis, Crohn's disease, luminal obstruction, pathogenesis, surgery

## 1. Introduction

In developed countries, the incidence of acute appendicitis is 90 to 100 cases per 100,000 individuals per year, and is one of the most common emergencies in general surgery worldwide, with an estimated 7% to 8% lifetime risk reported.<sup>[1,2]</sup>

Despite its frequency, its pathogenesis is still poorly understood. Even the recent literature, reports that direct luminal

obstruction (by a fecalith, lymphoid hyperplasia, or impacted stool) is the primary and principal cause of acute appendicitis.<sup>[2-4]</sup>

We report a unique finding which casts doubt on the real role of luminal obstruction as a pathogenetic cause of acute appendicitis.

## 2. Case report

During October 2016 a 58-year-old woman was referred to the Surgical Unit of the Department of Surgery and Translational Medicine of the University of Florence because of a clinical recurrence of Crohn's disease. The patient had been operated 20 years before in a peripheral surgical center: an open surgery ileo-cecal resection (about 10 cm ileum resected) with hand-sewn end-to-side ileo-colic anastomosis had been performed. The patient has been followed up by gastroenterologists and she was in good clinical condition until 5 years ago, when she started to suffer cyclical obstructive symptoms due to a relapse of her Crohn's disease. Her enteric-magnetic resonance imaging (MRI) scan showed a neo-terminal ileum stricturing recurrence about 1.5 cm long. Biological therapy (anti-TNF $\alpha$  Ab) was started but did not control symptoms and thus surgery was indicated. The patient's written informed consent was obtained before surgery as well as for publication of this report. Ethical approval was not necessary because this manuscript is a de-identified retrospective case report.

Editor: N/A.

Disclosure statement: The authors have nothing to disclose. Ethical Adherence was applied. The authors declare that the manuscript has not been submitted to any other journal.

The authors have no conflicts of interest to disclose.

<sup>a</sup> Department of Surgery and Translational Medicine, Surgical Unit, <sup>b</sup> Department of Experimental and Clinical Medicine, University of Florence, Florence, Italy.

\* Correspondence: Francesco Giudici, Surgery Unit, Department of Surgery and Translational Medicine, University of Florence, Medical School, Largo Brambilla n°3, 50134 Florence, Italy (e-mail: francesco.giudici1@gmail.com).

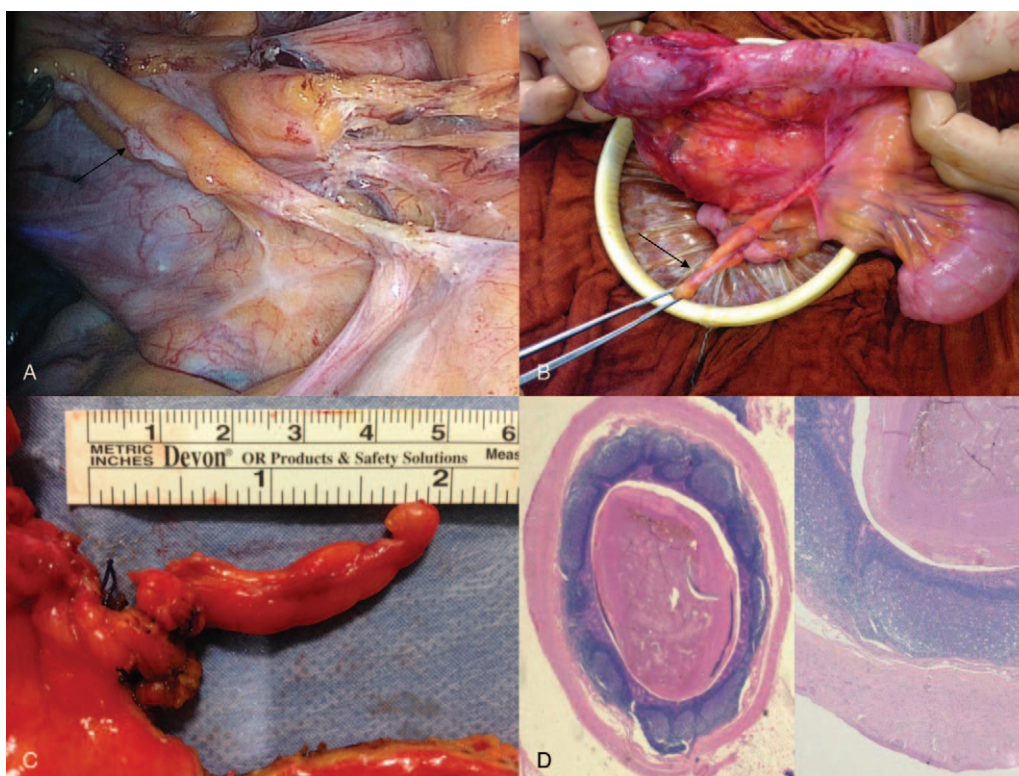
Copyright © 2018 the Author(s). Published by Wolters Kluwer Health, Inc. This is an open access article distributed under the Creative Commons Attribution-NoDerivatives License 4.0, which allows for redistribution, commercial and non-commercial, as long as it is passed along unchanged and in whole, with credit to the author.

Medicine (2018) 97:15(e0381)

Received: 18 December 2017 / Received in final form: 20 March 2018 /

Accepted: 21 March 2018

<http://dx.doi.org/10.1097/MD.000000000010381>



**Figure 1.** Intraoperative picture: the appendix (arrow) is visible beneath the mobilized ileo-colic anastomosis; macroscopically the appendix is not inflamed and vascularized by a residual mesoappendix (A). The ileo-colic anastomosis is exteriorized from the periumbelical incision: the appendix is kept by forceps (B). It is about 5 cm long (C). A fecalith is present in the lumen of the appendix but there is no associated inflammation. (D) (Hematoxylin eosin: 4× magnification on the left, 10× magnification on the right).

The patient was operated using single-incision laparoscopic surgery (SILS) to mobilize the right colon and free the right flexure. We observed an exceptional intraoperative finding: the Crohn's disease recurrence interested the neoterminal ileum in a stricturing form which also involved the ileo-colic anastomosis according to preoperative imaging, but surprisingly, the appendix was still present in the operative field, vascularized by small vessels within a mesoappendix connected with the neo-terminal ileum mesentery (Fig. 1A and B). The appendix was about 5 cm long, vital and macroscopically not inflamed even if its base was clearly no longer connected to the cecum which had been resected 20 years earlier (Fig. 1C).

The patient underwent ileo-colic resection (15+7 cm long) with en-bloc removal of the appendix.

With a narrow metallic stylet probe we carefully tried to enter the appendix lumen through the opposite side from its fundus but were not able to enter it without cutting the wall with scissors.

Pathological examination confirmed that the recurrence of Crohn's disease had affected the small bowel and the appendix lumen was obstructed by presence of a fecalith but without any sign of inflammation (Fig. 1D).

### 3. Discussion

Although some cases of recurrent stump appendicitis after appendectomy have been reported,<sup>[5,6]</sup> to the best of our knowledge, this is the first published case of a left in-site appendix after ileo-cecal removal for Crohn's disease. Furthermore, the residual appendix in our patient was not a variably long stump due to an incomplete resection of the base of the appendix,

but a complete appendix about 5 cm long. Apart from the rarity of the case, we believe this intraoperative finding is extremely interesting because it incontrovertibly highlights the poor pathogenetic role of luminal obstruction in the development of appendicitis.

Starting from the first description of appendicitis by Fitz in 1886<sup>[7]</sup> and the first experimental demonstration of the obstructive phenomenon in acute appendicitis pathogenesis by Wangensteen and Dennis in 1939,<sup>[8]</sup> the association between the presence of luminal obstruction (prevalently by fecaliths) and acute appendicitis has been largely reported in literature.<sup>[2-4]</sup> On the basis of other historic findings, even today, all medical textbooks describe the role of fecaliths as an etiopathological factor in developing acute appendicitis.

In 1966 a study conducted in the Canterbury hospital, reported the presence of "calculi" in the specimen analysis of the appendix lumen in 29 out of 1800 patients who had undergone appendectomy for appendicitis. The authors postulated the necessity of performing a prophylactic appendectomy when these appendicoliths are incidentally found.<sup>[9]</sup> Fortunately, this recommended therapy has not been followed by clinicians. In fact, a recent retrospective experience, confirming the presence of incidental appendicoliths in up to 32% of the asymptomatic population, analyzed 111 patients with an incidental diagnosis of appendicolith according to computed tomography. It was found that 100% of study patients been remained asymptomatic at a mean follow-up of  $4.0 \pm 1.7$  years, and the occurrence of acute appendicitis in this group was 0%.<sup>[10]</sup>

Analysis of these retrospective data indicates that patients with occlusion of the appendix lumen by a fecalith do not have an

increased risk of developing appendicitis. Our clinical case report confirms at a longer follow-up what radiologists have reported when analyzing computed tomographic scans: 20 years after the first operation, even in the presence of a completely closed lumen at its base, the appendix wall was free from any sign of either macroscopic or microscopic inflammation. Therefore, we believe the obstruction alone is not enough to cause acute appendicitis, and for the same reason to indicate it as the primary cause of an appendicitis could not be scientifically correct. Furthermore, our evidence shows that the vitality of the appendix can be preserved even in the presence of a narrow peripheral artery.

#### 4. Conclusion

Although traditional medical texts report luminal obstruction of the appendix as the primary cause of acute appendicitis, this fact has been postulated without any scientific objectification. The present clinical report expresses our doubts about the veracity of this historical assertion since the obstructed and well vascularized appendix which we observed was not inflamed. Although luminal obstruction could play a role in acute appendicitis, the development of other factors seems to be necessary to provoke acute inflammation.

#### Author contributions

**Conceptualization:** Francesco Giudici, Costantino Voglino, Luca Messerini.

**Data curation:** Stefano Scaringi, Daniela Zambonin, Costantino Voglino, Luca Messerini.

**Formal analysis:** Stefano Scaringi, Daniela Zambonin, Costantino Voglino, Luca Messerini.

**Investigation:** Francesco Giudici, Stefano Scaringi, Daniela Zambonin, Costantino Voglino, Luca Messerini.

**Methodology:** Francesco Giudici, Stefano Scaringi, Daniela Zambonin, Costantino Voglino.

**Project administration:** Francesco Giudici, Paolo Bechi.

**Supervision:** Francesco Giudici, Costantino Voglino, Ferdinando Ficari, Paolo Bechi.

**Validation:** Francesco Giudici, Stefano Scaringi, Costantino Voglino, Ferdinando Ficari, Paolo Bechi.

**Visualization:** Daniela Zambonin.

**Writing – original draft:** Francesco Giudici, Stefano Scaringi, Luca Messerini.

**Writing – review & editing:** Francesco Giudici, Stefano Scaringi, Daniela Zambonin, Costantino Voglino, Ferdinando Ficari, Paolo Bechi.

#### References

- [1] Stewart B, Khanduri P, McCord C, et al. Global disease burden of conditions requiring emergency surgery. *Br J Surg* 2014;101:e9–22.
- [2] Bhangu A, Søreide K, Di Saverio S, et al. Acute appendicitis: modern understanding of pathogenesis, diagnosis, and management. *Lancet* 2015;26:1278–87.
- [3] Lamps LW. Infectious causes of appendicitis. *Infect Dis Clin North Am* 2010;24:995–1018.
- [4] Dzabic M, Bostrom L, Rahbar A. High prevalence of an active cytomegalovirus infection in the appendix of immunocompetent patients with acute appendicitis. *Inflamm Bowel Dis* 2008;14:236–41.
- [5] Truty MJ, Stulak JM, Utter PA, et al. Appendicitis after appendectomy. *Arch Surg* 2008;143:413–5.
- [6] Liang MK, Lo HG, Marks JL. Stump appendicitis: a comprehensive review of literature. *Am Surg* 2006;72:162–6.
- [7] Fitz RH. Perforating inflammation of the vermiform appendix. *Am J Med Sci* 1986;92:321–46.
- [8] Wangenstein OH, Dennis C. Experimental proof of the obstructive origin of appendicitis in man. *Ann Surg* 1939;110:629–47.
- [9] Forbes GB, Lloyd-Davies RW. Calculous disease of the vermiform appendix. *Gut* 1966;7:583–92.
- [10] Khan MS, Chaudhry MBH, Shahzad N, et al. Risk of appendicitis in patients with incidentally discovered appendicoliths. *J Surg Res* 2018;221:84–7.