

Value of combined detection of serum carcino-embryonic antigen, carbohydrate antigen 19-9 and cyclooxygenase-2 in the diagnosis of colorectal cancer

WEILI YANG, YONGSHENG LUO, SHUANGCHENG HU, YING LI and QING LIU

Department of Gastroenterology, The Second People's Hospital of Shenzhen,
Shenzhen, Guangdong 518000, P.R. China

Received October 31, 2017; Accepted May 18, 2018

DOI: 10.3892/ol.2018.8792

Abstract. The aim of the present study was to investigate the value of combined detection of serum carcino-embryonic antigen (CEA), carbohydrate antigen (CA) 19-9 and cyclooxygenase-2 (COX-2) in the diagnosis of colorectal cancer. A total of 50 patients with colorectal cancer were selected as Group A and 50 healthy subjects as the control group. A sample of 2 ml fasting venous blood was drawn from patients in each group, and serum CEA, CA19-9 and COX-2 were detected using electrochemiluminescence analyzer and ELISA. Receiver operating characteristic curve analysis was performed on analyze the sensitivity and specificity of diagnostic methods for colorectal cancer patients at different stages. The expression levels of CEA, CA199 and COX-2 in the cancer patients group were significantly higher than those in the healthy group ($P < 0.05$). The coincidence rates of CEA, CA199, COX-2 and combined detection were 56.0, 64.0, 62.0 and 88.0%, respectively. The coincidence rate of combined detection was significantly higher than that of diagnosis using a single factor ($P < 0.05$). Sensitivity of combined detection of colorectal cancer patients with stage I, II, III and IV were 82.9, 85.3, 86.4 and 88.7%, respectively. The specificities were 65.3, 68.7, 57.8 and 58.6%, respectively. Thus, CEA, CA199 and COX-2 in serum are highly expressed in colorectal cancer patients, and may useful as effective indicators for the early diagnosis of colorectal cancer.

Introduction

Colorectal cancer refers to the cancer from the dentate line to the rectosigmoid junction, which is one of the most common

malignant tumors of the digestive tract (1). With the fast-paced development of society and the increase in life pressure, the incidence rate of colorectal cancer has been increased year by year. Colorectal cancer often occurs in patients aged above 46 years old, whose incidence rate in young people has shown an increasing trend in recent years (2,3). Colorectal cancer in early stage has no obvious symptoms, so most of patients have been in the advanced stage diagnosed with the survival rate below 28% because they do not pay much attention to it in early stage (4).

At present, serum carcino-embryonic antigen (CEA), carbohydrate antigen (CA) 19-9 and cyclooxygenase-2 (COX-2) are the most commonly-used indexes in the clinical diagnosis of colorectal cancer, but they are all non-specific antigens. The accuracy and sensitivity of diagnosis based on a single indicator are usually unsatisfactory. Therefore, combined detection is usually in clinical studies to improve the diagnostic accuracy of the tumor. Handy (5) reported that the combination of CEA, CA199 and COX-2 can significantly improve the accuracy of the diagnosis of gastric cancer with high accuracy. Therefore, we assumed that the combination of CEA, CA199 and COX-2 may also increase the diagnostic sensitivity and specificity for colorectal cancer, which has not been reported by previous studies. Therefore, our study aimed to investigate the diagnostic value of the combination of CEA, CA199 and COX-2 for colorectal cancer.

Materials and methods

Objects of study. A total of 50 patients with colorectal cancer admitted to our hospital from August 2013 to August 2016 were selected to serve as cancer group. Those patients included 32 males and 18 females, with an average of 52.8 ± 1.8 years. According to the guideline of staging of colorectal cancer in the United States in 2010, there were 12 cases in stage I, 15 cases in stage II, 13 cases in stage III and 10 cases in stage IV. As the same this 50 healthy people were also selected to serve as control group. Control group included 31 males and 19 females, with an average of 51.3 ± 2.7 years.

Inclusion and exclusion criteria. Inclusion criteria: Patients aged from 40 to 60 years; patients with colorectal cancer

Correspondence to: Dr Qing Liu, Department of Gastroenterology, The Second People's Hospital of Shenzhen, 27 Zhongkang Road, Shangmeilin, Shenzhen, Guangdong 518000, P.R. China
E-mail: qup9mh@163.com

Key words: serum carcino-embryonic antigen, carbohydrate antigen 19-9, cyclooxygenase-2, rectal cancer, diagnostic value

Table I. Clinical data of patients with colorectal cancer and those with benign lesions.

Characteristics	Patients with colorectal cancer [n (%)]	Patient with benign lesion [n (%)]	P-value
Sex			0.446
Male	32 (64.0)	31 (62.0)	
Female	18 (36.0)	19 (38.0)	
Age, years			0.328
<40	29 (58.0)	30 (60.0)	
≥40	21 (42.0)	20 (40.0)	
Tumor size, mm			0.201
<8	26 (52.0)	17 (34.0)	
≥8	24 (48.0)	33 (66.0)	
Smoking			0.285
Yes	28 (56.0)	39 (78.0)	
No	16 (44.0)	11 (22.0)	
Drinking			0.364
Yes	21 (42.0)	17 (34.0)	
No	29 (58.0)	33 (66.0)	
Sleep			0.276
Early	26 (52.0)	30 (60.0)	
Late	24 (48.0)	20 (40.0)	
Exercise			0.288
Yes	22 (44.0)	32 (64.0)	
No	28 (56.0)	18 (36.0)	
Taste preference			0.316
Light	18 (36.0)	21 (42.0)	
Greasy	32 (64.0)	29 (58.0)	
TNM staging			0.168
Stages I and II	39 (78.0)	48 (96.0)	
Stages III and IV	11 (22.0)	2 (4.0)	
Pathological staging			0.207
Stages I and II	36 (0.72)	50 (100.0)	
Stages III and IV	14 (0.28)	0	

related pathological conditions confirmed by pathological examination; patients received no surgical operations, chemotherapy, hormones and other treatment before admission; patients with complete clinical data. Exclusion criteria: patients with other vital organs disease; patients with inflammation; patients with a history of other types of tumors; pregnant women; patients with autoimmune diseases; dipsopathy and crapulent patients. The present study was approved by the Ethics Committee of the Second People's Hospital of Shenzhen (Shenzhen, China). All patients signed written informed consent.

Methods. A total of 2 ml fasting venous blood was drawn from patients in each group using the pro-coagulation tube, placed at room temperature for 1 h and centrifuged at 3,000 x g for 5 min using a centrifugal machine. The supernatant was taken and divided into two pieces. Serum CEA and CA19-9 in one

piece were detected and analysed using the full-automatic chemiluminescence immunoassay analyzer (Shanghai Honglian Medical Tech Co., Ltd., Shanghai, China) and its supporting reagents; CEA >5 U/ml and CA19-9 >37 U/ml indicted the positive results. COX-2 in the other piece was detected via enzyme-linked immunosorbent assay (ELISA) using the ELISA kit (Thermo Fisher Scientific, Inc., Waltham, MA, USA) and its supporting reagents. Patients with positive CEA, CA19-9 and COX-2 were diagnosed as positive. According to Ng *et al* (6), the cut-off level of COX-2 was set as 52.00 ng/ml.

Statistical analyses. SPSS 22.0 software (IBM Corp., Armonk, NY USA) was used to analyze the data. Count data were expressed as rate. Measurement data were expressed as the mean ± standard deviation, t-test was used to compare the data between groups, and analysis of variance with a

Table II. Comparisons of expression levels of serum CEA, CA19-9 and COX-2.

Group	Case (n)	CEA (ng/ml)	CA19-9 (U/ml)	COX-2 (ng/ml)
Group A	50	36.44±12.26 ^a	51.73±21.81 ^a	47.06±11.06 ^a
Control group	50	2.13±0.76	12.91±8.03	7.87±5.19
P-value	-	0.019	0.032	0.012

The results are presented as the mean ± standard deviation. ^aP<0.05 vs. control. CEA, carcino-embryonic antigen; CA19-9, carbohydrate antigen 19-9; COX-2, cyclooxygenase-2.

Table III. Positive rates of serum CEA, CA19-9 and COX-2.

Group	Cases (n)	CEA [n (%)]	CA19-9 [n (%)]	COX-2 [n (%)]	Combined detection [n (%)]
Group A	50	28 (56.0) ^{a,b}	32 (64.0) ^{a,b}	21 (62.0) ^{a,b}	44 (88.0) ^c
Group B	50	5 (10.0)	4 (8.0)	3 (6.0)	6 (12.0)
Control group	50	2 (4.0)	2 (4.0)	0 (0.0)	3 (6.0)
P-value	-	0.023	0.012	0.028	0.036

^aP<0.05 vs. control; ^bP<0.05 vs. Group B; ^cP<0.05 vs. single detection. CEA, carcino-embryonic antigen; CA19-9, carbohydrate antigen 19-9; COX-2, cyclooxygenase-2.

Table IV. Serum levels of CEA, CA19-9 and COX-2 in different pathological stages of tumor patients.

Group	Case (n)	CEA [n (%)]	CA19-9 [n (%)]	COX-2 [n (%)]	Combined detection [n (%)]
Group A	50	28 (56.0) ^{a,b}	32 (64.0) ^{a,b}	21 (62.0) ^{a,b}	44 (88.0) ^a
Control group	50	2 (4.0)	2 (4.0)	0	3 (6.0)
P-value	-	0.023	0.012	0.028	0.036

^aP<0.05 vs. control; ^bP<0.05 vs. combined detection. CEA, carcino-embryonic antigen; CA19-9, carbohydrate antigen 19-9; COX-2, cyclooxygenase-2.

Student-Newman-Keuls post hoc test was used for comparisons among multiple groups. P<0.05 was considered to indicate a statistically significant difference.

Results

Clinical data of patients. There was no significant difference (P>0.05) between patients with colorectal cancer and healthy physical examination patients in sex, age, smoking habit, alcoholism, sleep, exercise, taste preference, residence and ethnic composition (Table I).

Expression levels of serum CEA, CA19-9 and COX-2. Levels of CEA, CA199 and COX-2 in cancer patients were 36.44±12.26 (ng/ml), 51.73±21.81 (U/ml) and 47.06±11.06 (ng/ml), respectively. Levels of CEA, CA199 and COX-2 in healthy controls were 2.13±0.76 (ng/ml), 12.91±8.03 (U/ml) and 7.87±5.19 (ng/ml), respectively. Significant differences were found between two groups (P<0.05). Levels of CEA, CA199 and COX-2 were increased with increased pathological

stages. Significant differences were found among stage I, II and III. No significant differences were found between stage III and IV (Tables II and III).

Positive rates of serum CEA, CA19-9 and COX-2. The number of positive patients in serum CEA, CA199, COX-2 and combined detection were 28, 32, 21 and 44, respectively. Diagnostic coincidence rates were 56.0, 64.0, 62.0 and 88.0%, respectively. In the healthy group, positive patients in serum CEA, CA199, COX-2 and combined detection were 2, 2, 0 and 3, respectively. Combined detection identified 9 patients in stage I, 11 in stage II, 8 in stage III and 6 in stage IV. The diagnostic coincidence rates were 75.0, 73.3, 72.7 and 60.0%, respectively (Table IV and Fig. 1).

Efficiency evaluation of serum CEA, CA19-9 and COX-2 in diagnosis of colorectal cancer. Sensitivities of CEA, CA199 and COX-2 in the detection of colorectal cancer stage I, II, III and IV were 82.9, 85.3, 86.4 and 88.7%, respectively. The specificities were 65.3, 68.7, 57.8 and 58.6%, respectively.

Table V. Efficiency of serum CEA, CA19-9 and COX-2 in the diagnosis of rectal cancer.

Factor	Sensitivity (%)	Specificity (%)	Accuracy (%)
CEA	41.8	60.7	80.3
CA19-9	55.6	93.5	75.8
COX-2	43.3	91.5	77.6
Combined detection	90.1	89.9	92.3
P-value	0.015	0.072	0.043

CEA, carcino-embryonic antigen; CA19-9, carbohydrate antigen 19-9; COX-2, cyclooxygenase-2.

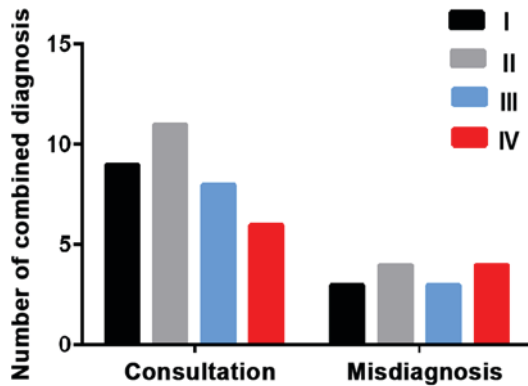


Figure 1. Diagnostic coincidence rates of serum carcino-embryonic antigen, carbohydrate antigen 19-9 and cyclooxygenase-2 in colorectal cancer. There were 9 patients in stage I, 11 in stage II, 8 in stage III and 6 in stage IV were detected and the diagnostic coincidence rates were 75.0, 73.3, 72.7 and 60.0%, respectively.

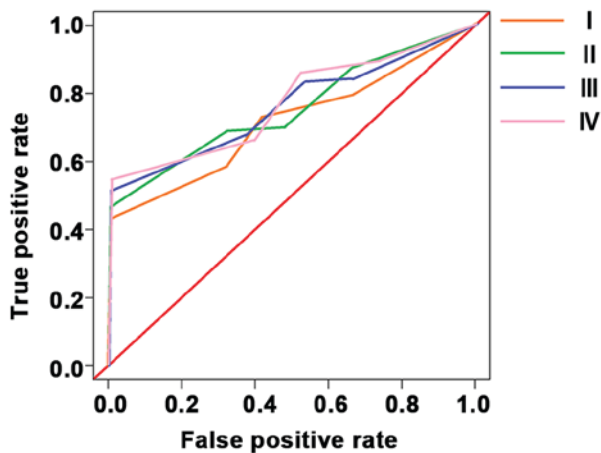


Figure 2. Receiver operating characteristic curve analysis of serum carcino-embryonic antigen, carbohydrate antigen 19-9 and cyclooxygenase-2 in the diagnosis of colorectal cancer.

95% confidence intervals were 0.48-0.93, 0.26-0.89, 1.04-1.77, 0.51-0.98 respectively (Table V and Fig. 2).

Discussion

The incidence rate of colorectal cancer, one of the most common malignant tumors in the digestive tract, has been constantly increased in recent years. According to the report

of Siu *et al* (7), colorectal cancer will take the place of lung cancer and gastric cancer and become the malignant tumor with the highest incidence rate in the world within the next three years. If there are timely detection and treatment in the early stage of colorectal cancer, no great damage will be caused to the patients. But the early symptoms are very unobvious, so they will be ignored easily, and the treatment will become increasingly more difficult with the proliferation and metastasis of cancer cells (8). At present, the colorectal cancer is often diagnosed using the high expression and abnormality of CEA and other tumor markers combined with medical imaging techniques (9). This study aimed to study the value of combined detection of CEA, CA19-9 and COX-2 in the diagnosis of colorectal cancer, so as to provide a diagnostic method with higher accuracy and specificity and simple detection means for the clinical treatment of colorectal cancer in the future.

This study detected the expression of CEA, CA199 and COX-2 in patients with colorectal cancer and healthy people, and the expression levels of CEA, CA199 and COX-2 in patients with colorectal cancer were significantly higher than those in healthy people. Compared with diagnosis based on single indicator, the combined detection significantly improved the accuracy. Compared with diagnosis based on single indicator, sensitivity and specificity of combined detection were increased for stage I and II but reduced for stage III and IV, indicating that CEA, CA199 and COX-2 can be used for the early diagnosis of colorectal cancer.

In this study, the expression levels and positive rates of CEA, CA19-9 and COX-2 in patients with colorectal cancer and benign lesions and healthy people were detected. The clinical data were compared between patients with colorectal cancer and benign lesion. The results showed that the patient's gender, age, tumor size, smoking, drinking, sleep, exercise, taste preference, TNM staging and pathological staging had no effects on the detection of three indexes. The expression levels of CEA, CA19-9 and COX-2 in patients with colorectal cancer were significantly higher than those in the other two groups. The combined detection had a statistically significant difference compared with single detection, indicating that the combined detection of CEA, CA19-9 and COX-2 can be clinically applied in the diagnosis of rectal cancer. The comparisons of sensitivity, specificity and accuracy in each group showed that there was no obvious difference in the specificity between combined detection and single detection, but the combined detection

greatly improved the sensitivity and accuracy, suggesting that the combined detection of CEA, CA19-9 and COX-2 in the diagnosis of colorectal cancer can compensate for the shortcomings of single detection and improve the diagnosis accuracy.

In the early stage of tumor occurrence and development, the accurate diagnosis via imaging is more difficult, and the tumor markers are abnormally expressed in the blood in different degrees, which is an index for the early detection of tumor occurrence and development (10,11). However, the abnormality of one single marker cannot provide highly accurate information about the occurrence of tumor, so the combined detection of two or more tumor markers is commonly applied in the clinical diagnosis of the presence or abnormality of tumor (12). CEA is a kind of cytoplasmic glycoprotein that is highly expressed in most cancerous tissues, as well as the most commonly-used tumor marker with a low specificity (13,14). Therefore, the clinical detection with CEA as a tumor marker is often combined with other tumor markers, so as to improve the positive detection rate of cancer (15). CA19-9 is a kind of protein produced by rectal cells that belongs to the oligosaccharide-associated antigen, which is highly expressed in pancreatic cancer and malignant tumors of digestive tract (16,17). COX is divided into COX-1 structural type and COX-2 induced type. COX-1 is involved in a variety of pathological and physiological functions, which is expressed stably in most tissues and cells (18). COX-2 is seldom expressed in normal tissues and cells, but its expression will be stimulated by tumor promoters (19). Xiao *et al* (20) studies showed that COX-2 is involved in tumor formation and development through inhibiting cell death and promoting cell growth. According to the results of this study, COX-2 was highly expressed in 62.0% patients with colorectal cancer, and 6.0% patients with benign lesions, but it was not expressed in healthy subjects. The results indicated that the high expression of COX-2 occurs in early stage of rectal cancer, and participates in the development of cancer. According to the study of Wang *et al* (21) on the protein expression of COX-2 in colorectal cancer, combined with the experimental results, it was found that COX-2 high expression is significantly correlated with the malignant feature of rectal cancer, which can be used as a new target for the diagnosis, treatment and prevention of colorectal cancer in the future. For colorectal cancer patients in stage III and IV, distant tumor cells and lymph node metastasis can cause more significant increase in levels of cancer markers. In this experiment, there was no significant difference in the expression levels of CEA, CA199 and COX-2 between stage III and stage IV patients, suggesting that the expression of cancer markers had reached the critical value, so the increase was not significant, resulting in decreased decreased and specificity of combined detection for colorectal cancer at stages III and IV.

There are still some shortcomings in this experiment due to the limited experimental conditions. For example, sample size was small, and the expression of CEA, CA199 and COX-2 may be affected by ages or genders. We will conduct a longer period of follow-up investigation to further verify the conclusion.

In conclusion, serum CEA, CA199 and COX-2 were highly expressed in colorectal cancer, and can be used as an effective indicator for the early diagnosis of colorectal cancer.

Acknowledgements

Not applicable.

Funding

No funding was received.

Availability of data and materials

The datasets used and/or analyzed during the present study are available from the corresponding author on reasonable request.

Authors' contributions

WY and QL conceived and designed the study. WY, YoL and SH were responsible for the collection and analysis of the patient data. YiL performed ELISA. All authors read and approved the final manuscript.

Ethics approval and consent to participate

The present study was approved by the Ethics Committee of the Second People's Hospital of Shenzhen (Shenzhen, China). Written informed consent was obtained from all participants.

Consent for publication

Not applicable.

Competing interests

The authors declare that they have no competing interests.

References

1. Siegel RL, Miller KD, Fedewa SA, Ahnen DJ, Meester RGS, Barzi A and Jemal A: Colorectal cancer statistics, 2017. *CA Cancer J Clin* 67: 177-193, 2017.
2. Arnold M, Sierra MS, Laversanne M, Soerjomataram I, Jemal A and Bray F: Global patterns and trends in colorectal cancer incidence and mortality. *Gut* 66: 683-691, 2017.
3. Sung JJ, Ng SC, Chan FK, Chiu HM, Kim HS, Matsuda T, Ng SS, Lau JY, Zheng S, Adler S, *et al*: An updated Asia Pacific Consensus Recommendations on colorectal cancer screening. *Gut* 64: 121-132, 2015.
4. Liu S, Zheng R, Zhang M, Zhang S, Sun X and Chen W: Incidence and mortality of colorectal cancer in China, 2011. *Chin J Cancer Res* 27: 22-28, 2015.
5. Handy B: The clinical utility of tumor markers. *Lab Med* 40: 99-104, 2009.
6. Ng K, Meyerhardt JA, Chan AT, Sato K, Chan JA, Niedzwiecki D, Saltz LB, Mayer RJ, Benson AB III, Schaefer PL, *et al*: Aspirin and COX-2 inhibitor use in patients with stage III colon cancer. *J Natl Cancer Inst* 107: 345, 2014.
7. Siu AL: US Preventive Services Task Force (USPSTF), Bibbins-Domingo K, Grossman DC, Baumann LC, Davidson KW, Ebell M, Garcia FA, Gillman M, Herzstein J, *et al*: Screening for colorectal cancer: US preventive services task force recommendation statement. *JAMA* 315: 380-387, 2016.
8. Wang S, Xiang J, Li Z, Lu S, Hu J, Gao X, Yu L, Wang L, Wang J, Wu Y, *et al*: A plasma microRNA panel for early detection of colorectal cancer. *Int J Cancer* 136: 152-161, 2015.
9. Castells A: Colorectal cancer screening. *Gastroenterol Hepatol* 38 (Suppl 1): S64-S70, 2015.
10. De Rosa M, Pace U, Rega D, Costabile V, Duraturo F, Izzo P and Delrio P: Genetics, diagnosis and management of colorectal cancer (Review). *Oncol Rep* 34: 1087-1096, 2015.

11. Siegel RL, Miller KD and Jemal A: Cancer statistics, 2016. *CA Cancer J Clin* 66: 7-30, 2016.
12. Schreuders EH, Ruco A, Rabeneck L, Schoen RE, Sung JJ, Young GP and Kuipers EJ: Colorectal cancer screening: A global overview of existing programmes. *Gut* 64: 1637-1649, 2015.
13. Bacac M, Fauti T, Sam J, Colombetti S, Weinzierl T, Ouaret D, Bodmer W, Lehmann S, Hofer T, Hosse RJ, *et al*: A novel carcinoembryonic antigen T-cell bispecific antibody (CEA TCB) for the treatment of solid tumors. *Clin Cancer Res* 22: 3286-3297, 2016.
14. Chen X, Wang X, He H, Liu Z, Hu JF and Li W: Combination of circulating tumor cells with serum carcinoembryonic antigen enhances clinical prediction of non-small cell lung cancer. *PLoS One* 10: e0126276, 2015.
15. Huang C, Zhan T, Liu Y, Li Q, Wu H, Ji D and Li Y: Glycomic profiling of carcinoembryonic antigen isolated from human tumor tissue. *Clin Proteomics* 12: 17, 2015.
16. Wu XY and Huang XE: Clinical application of serum tumor abnormal protein (TAP) in colorectal cancer patients. *Asian Pac J Cancer Prev* 16: 3425-3428, 2015.
17. Liu J and Huang XE: Clinical application of serum tumor abnormal protein from patients with gastric cancer. *Asian Pac J Cancer Prev* 16: 4041-4044, 2015.
18. Kumar V, Al-Abbasi FA, Verma A, Mujeeb M and Anwar F: Umbelliferone β -D-galactopyranoside exerts an anti-inflammatory effect by attenuating COX-1 and COX-2. *Toxicol Res* 4: 1072-1084, 2015.
19. Liu B, Qu L and Yan S: Cyclooxygenase-2 promotes tumor growth and suppresses tumor immunity. *Cancer Cell Int* 15: 106, 2015.
20. Xiao Y, Wang J, Qin Y, Xuan Y, Jia Y, Hu W, Yu W, Dai M, Li Z, Yi C, *et al*: Ku80 cooperates with CBP to promote COX-2 expression and tumor growth. *Oncotarget* 6: 8046-8061, 2015.
21. Wang JY, Sun J, Huang MY, Wang YS, Hou MF, Sun Y, He H, Krishna N, Chiu SJ, Lin S, *et al*: STIM1 overexpression promotes colorectal cancer progression, cell motility and COX-2 expression. *Oncogene* 34: 4358-4367, 2015.



This work is licensed under a Creative Commons Attribution-NonCommercial-NoDerivatives 4.0 International (CC BY-NC-ND 4.0) License.