


Severe and Progressive Cellulitis Caused by *Serratia marcescens* Following a Dog Scratch

Journal of Investigative Medicine High Impact Case Reports
Volume 7: 1–6
© 2019 American Federation for Medical Research
DOI: 10.1177/2324709619832330
journals.sagepub.com/home/hic


Deeti J. Pithadia, BS¹, Erena N. Weathers, BS¹, Rhonda E. Colombo, MD², and Stephanie L. Baer, MD^{1,3}

Abstract

Soft tissue infections occur in over 30% of patients with chemotherapy-induced neutropenia. Gram-positive bacterial infections predominate early in neutropenia, and likelihood of infection by resistant bacteria and fungi increases with prolonged neutropenia. Prior infections and exposures influence the risk of rare pathogens. A 55-year-old woman with chemotherapy-induced neutropenia was scratched on her forearm by a dog. She cleaned the wound with isopropanol and was treated empirically with amoxicillin-clavulanate. Over the next 4 days, she developed fever along with erythema, edema, and mild tenderness of the forearm without purulence or crepitus. She was hospitalized and received empiric treatment with intravenous vancomycin, piperacillin-tazobactam, tobramycin, and voriconazole. Despite therapy, her fevers persisted and the cellulitis progressed for over a week. After 10 days of hospitalization, her neutrophil count began to recover and a bulla developed at the wound site. Culture of the bullous fluid grew *Serratia marcescens*, and antibiotics were switched to cefepime based on susceptibility. She defervesced and showed substantial improvement of cellulitis within 48 hours and was discharged on oral ciprofloxacin. *Serratia marcescens* skin infections are rare, and this may be the first report of *Serratia* cellulitis associated with trauma from dog contact. This case highlights the need to consider unusual pathogens based on exposure history and immune status and to obtain cultures from fluid collections or tissue in cases of treatment-resistant soft tissue infections.

Keywords

Serratia marcescens, cellulitis, dog scratch, skin infection, immunocompromised

Introduction

Skin and soft tissue infections comprise approximately 30% of infections in patients with chemotherapy-induced neutropenia.¹ Gram-positive and antibiotic-susceptible gram-negative bacterial infections predominate in patients who are neutropenic for less than 7 days. The risk of infection by resistant bacteria, yeasts, and molds increases with prolonged neutropenia.² Gram-positive cutaneous infections generally begin as focal regions of tenderness progressing to cellulitis, while gram-negative skin infections have diverse presentations including cellulitis, erythematous maculopapular lesions, and nodules.³ Past infections and exposures influence the risk of rare pathogens causing infection in immunocompromised patients.

We report a case of severe and progressive cellulitis following a dog scratch on the forearm of a patient who was profoundly neutropenic following chemotherapy.

Case

A 55-year-old Caucasian female receiving chemotherapy for primary central nervous system lymphoma was scratched by a dog on her right forearm. She cleaned the wound with isopropanol and presented to the emergency department at a community hospital. She was discharged on oral amoxicillin-clavulanate, which she took as prescribed. Three days

¹Medical College of Georgia, Augusta University, Augusta, GA, USA

²Madigan Army Medical Center, Joint Base Lewis-McChord, WA, USA

³Charlie Norwood Veterans Affairs Medical Center, Augusta, GA, USA

Received January 5, 2019. Revised January 7, 2019. Accepted January 13, 2019.

Corresponding Author:

Stephanie L. Baer, MD, Charlie Norwood VA Medical Center, 1 Freedom Way (235), Augusta, GA 30904, USA.
Email: stephanie.baer@va.gov



later, she was seen in oncology clinic for scheduled follow-up and was noted to have erythema surrounding the scratch site. The wound contacted tap water in the shower, but she denied other environmental exposures. Over the next 24 hours, she developed a fever and increased erythema, edema, and tenderness around the scratch site. She was subsequently admitted to our medical center.

Her history was significant for primary central nervous system lymphoma diagnosed 6 months prior. She completed consolidation chemotherapy 3 days prior to the dog scratch; a right-sided chest port remained in place. She had no prior history of immunocompromised state. She had no prior skin infections, significant trauma, or surgeries to the affected arm. She smoked 1 pack daily for many years but quit following her cancer diagnosis. The dog was up-to-date on vaccinations. Her outpatient medications included prophylactic acyclovir, fluconazole, and trimethoprim/sulfamethoxazole per standard chemotherapy protocol.

On admission to our medical center, she denied purulence, drainage, crepitus, or significant pain at the scratch site. She denied chest pain, dyspnea, abdominal pain, nausea, vomiting, diarrhea, or dysuria. She had a fever of 39.3°C and tachycardia at 110 beats per minute. Her respiratory rate, blood pressure, and oxygen saturation were within normal limits. She was awake, alert, and fully oriented. Her cardiac, pulmonary, and abdominal examinations were unremarkable. There was no erythema, purulence, or tenderness around her right-sided chest port. A 10-cm, well-circumscribed patch of erythema with a 1-cm central, darkly pigmented crust was present on her right forearm. The erythema had expanded from its earlier size denoted by an outline drawn 3 days earlier. The region was warm and mildly tender. She had 2+ radial and brachial pulses bilaterally and 5/5 motor strength of the bilateral upper extremities. No pain on flexion or extension of elbows, wrists, or fingers. Sensation was unaffected throughout the right upper extremity. Her laboratory findings were significant for undetectable white blood cell count. Hemoglobin was 11.7 g/dL, hematocrit was 34.0%, and platelet count was 19 000/mm³.

Amoxicillin/clavulanate was discontinued, and vancomycin intravenous (IV) and piperacillin/tazobactam IV were begun at admission. Cultures of blood from her chest port and urine were found to grow *Pseudomonas aeruginosa* with identical susceptibilities, including to piperacillin/tazobactam and cefepime. Culture of blood taken at the same time from a peripheral site was negative, and all subsequent blood cultures during hospitalization were negative. Despite the empiric broad-spectrum antibiotic therapy, the cellulitis worsened. The borders of erythema became more sharply demarcated by hospital day 5 (Figure 1), and the patient experienced daily fevers with maximum temperature of 39.2°C. Clindamycin IV was added for its antitoxin effect on day 5. By hospital day 7, the erythematous patch became less well-circumscribed (Figure 2), and she developed increased pain and decreased strength (4/5)

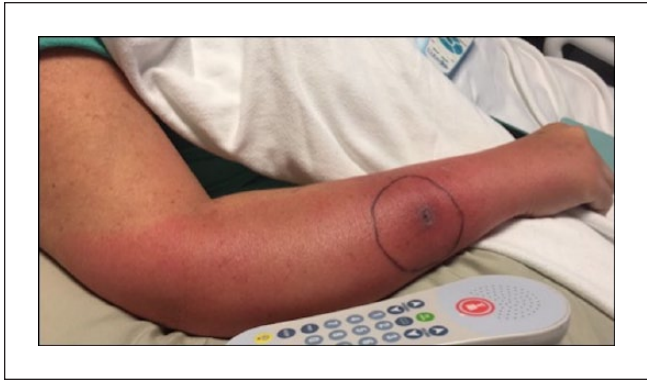

Figure 1. Appearance of patient's arm on day 5 of hospitalization. The ulcerated region was the location of the dog scratch, and the drawn circle denoted the borders of erythema marked 3 days following the incident and 1 day prior to hospitalization. Borders of erythema were sharply demarcated, and edema was mild.

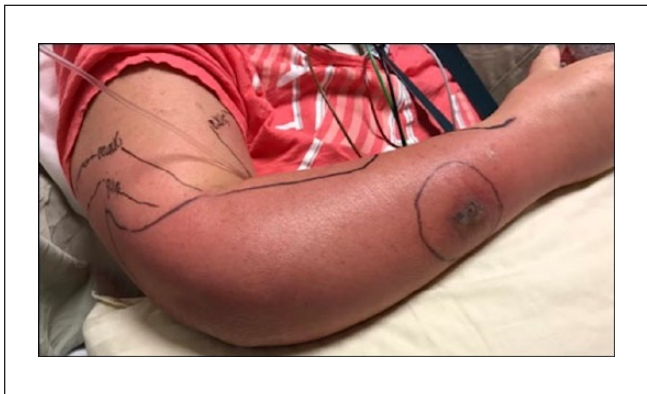

Figure 2. Appearance of patient's arm on day 7 of hospitalization. Borders of erythema became less poorly demarcated and spread into the arm and medial forearm. The edema had extended into the hand and digits.

on flexion of the right wrist and digits. Ultrasound of the right arm showed soft tissue edema. Subsequent magnetic resonance imaging showed an elbow joint effusion and myositis without pyomyositis or abscess (Figure 3). Voriconazole IV was added on day 7 for empiric antifungal coverage. The patient's chest port was removed on day 8 of hospitalization and was culture-negative.

On hospital day 10, the patient's leukocyte count recovered to 3400/mm³ (neutrophils 2800/mm³, lymphocytes 400/mm³, monocytes 200/mm³) and a bulla developed adjacent to the site of the dog scratch. Serous fluid from the bulla was drained using sterile technique and grew *Serratia marcescens* on culture. Cefepime IV was initiated based on susceptibility results, and piperacillin/tazobactam and voriconazole were discontinued. She defervesced and experienced substantial improvement in the cellulitis over 48 hours. The patient was discharged home after 15 days of hospitalization

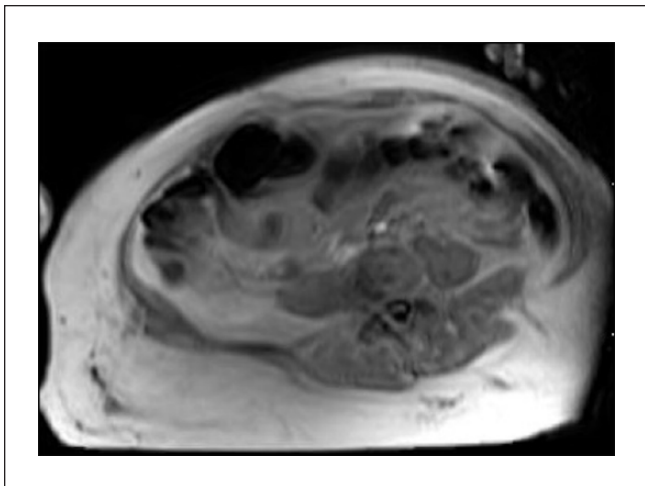


Figure 3. Magnetic resonance imaging study of right forearm on day 9 of hospitalization, ordered due to concern for compartment syndrome. The study demonstrated diffuse soft tissue cellulitis without abscess as well as myositis without pyomyositis.

on oral ciprofloxacin to complete a 14-day course of targeted antibiotic therapy. She was advised to keep her arm elevated to promote drainage of edema.

At follow-up, the patient continued to be afebrile after completing her antibiotic course. She received wound care at a community hospital. The wound healed completely within 2 months.

Discussion

Cellulitis is infection of the dermis and subcutaneous fat most frequently caused by introduction of *Streptococcus* or *Staphylococcus* species into the skin through abrasions.⁴ Cellulitis secondary to traumatic contact, including scratches and bites, by domestic mammals is most commonly due to *Pasteurella multocida*.^{5,6} In patients with contaminated water exposure, *Aeromonas hydrophila*, *Vibrio vulnificus*, and *Pseudomonas aeruginosa* have been reported as culprits.^{7,8} *Pseudomonas aeruginosa* also is a common cause of skin infections and osteomyelitis in individuals suffering from puncture wounds.⁹

Due to the patient's history of a penetrating wound with subsequent tap water contact in the setting of neutropenia, the eschar-like lesion on the arm resembling ecthyma gangrenosum, and the blood and urine culture results, *Pseudomonas aeruginosa* was initially believed to be the cause of cellulitis. Failure to respond to piperacillin/tazobactam, despite in vitro susceptibility, prompted further investigation. Although bullous cellulitis secondary to gram-negative septicemia is rare, *Pseudomonas aeruginosa*, which classically presents in the skin as ecthyma gangrenosum, has been documented as a cause in numerous case reports.¹⁰

Serratia marcescens is a gram-negative, motile, facultative anaerobic *Bacillus* that is pervasive in soil, water, and other damp environments. Prior to the mid-to-late 20th century, *Serratia marcescens* was not considered to be a human pathogen¹¹; since then, our understanding of its potential as a pathogen has transformed significantly. It is now known to be associated with opportunistic nosocomial infections such as catheter-associated urinary tract infections, ventilator-associated pneumonia, and central line-associated bacteremia.¹¹ *Serratia* may also cause severe infections following penetrating trauma, such as endocarditis following IV drug use,¹² meningitis following spinal anesthesia,¹³ and spinal epidural abscess following acupuncture.¹⁴

Serratia skin and soft tissue infections are uncommon, and most cases occur in immunocompromised patients. Presentations include isolated plaques,¹⁵ bullous cellulitis,¹⁶ papillovesicular eruptions,¹⁷ abscesses,^{18,19} nodules,^{20,21} granulomatous lesions,^{22,23} and necrotizing cellulitis.²⁴ Cases have been reported in the extremities of patients with uncontrolled diabetes²⁵ and end-stage renal disease,²⁶ as well as those who have undergone splenectomy²⁷ and chemotherapy.¹⁷ Infections associated with immunocompromised state frequently disseminate and lead to life-threatening sepsis. In healthy, immunocompetent patients, *Serratia* skin and soft tissue infections are generally localized and associated with direct trauma or chronic vascular disease. Infections in patients with venous insufficiency have presented as nodules, purulent ulcers, and cellulitis.^{18,20,21,28}

To better understand the risk factors and potential etiologies for infection in our patient, we conducted a review of reported cases of *Serratia marcescens* skin and soft tissue infections associated with inoculation injury or trauma (Table 1). Twenty-five individual patient cases were found. Skin and soft tissue manifestations included cellulitis (11 cases), necrotizing fasciitis (6 cases), cellulitis progressing to necrotizing fasciitis (3 cases), abscesses (2 cases), ulcers (2 cases), and inflamed nodule (1 case). Thirteen cases were reported in immunocompetent patients, 11 were in immunocompromised patients, and 1 did not specify. Two cases were in patients who were immunocompromised from chemotherapy.

Five of the reports were associated with bite trauma, including 3 iguana bites,^{16,29} 1 snake bite,³⁰ 1 human bite,³¹ and 1 insect bite.³² One case followed exposure to leeches.³³ Six of the cases had preceding accidental trauma or burns.³³⁻³⁵ Three of the cases involved outdoor contact, including scrapes by rocks, bushes,³⁶ and a rose thorn.³⁷ One case of an abscess caused by a tattoo was reported.³⁸ There are 12 reports of occurrences subsequent to iatrogenic trauma, including 5 that occurred after surgery.^{25,33,39-41} Other iatrogenic-associated cases followed skin or muscle biopsies,⁴²⁻⁴⁴ IV catheter placement,^{45,46} arteriovenous fistula,²⁶ and dermal filler injection.⁴⁷ One patient was described to have "minor trauma" of unspecified origin.⁴⁸ Most of these infections were managed successfully with antibiotics or surgical debridement, though 4 were fatal.

Table 1. Cases of *Serratia marcescens* Skin and Soft Tissue Infections Following External Trauma.

Case	Patient Demographic	Preceding Traumatic Insult	Distribution	Immunocompromised	Skin/Soft Tissue Manifestation	Management	Outcome
Brenner and Lookingbill ⁴⁵	51-year-old male	Intravenous catheter placement	Thigh	No	Cellulitis	Nafcillin, gentamicin	Death from hepatic and renal failure 7 days after catheter placement
Bornstein et al ²⁶	37-year-old female	Hemodialysis, fistula-site needle penetration	Axilla, breast, thorax	Yes; end-stage renal disease	Cellulitis	Surgical debridement, amikacin, ciprofloxacin	Resolution
Bonner and Mehar ⁴⁴	60-year-old male	Muscle and nerve biopsy	Foot	No	Cellulitis	Cefoxitin	Resolution
Cooper et al ²⁵	69-year-old female	Ingrown toenail surgery	Foot	Yes; type 2 diabetes mellitus	Bullous cellulitis	Amputation	Resolution
Pereira et al ³³	21-year-old female	Finger amputations caused by steel door; reconstructive surgery; leech application	Third and fourth digits on hand	No	Cellulitis	Amputation of reconstructed fingertip, ciprofloxacin	Resolution
Hsieh and Bahl ²⁹	8-year-old male	Iguana bite	Index finger	No	Cellulitis	Incision and drainage, ampicillin/sulbactam, gentamicin, amoxicillin/clavulanate	Resolution
Huang et al ⁴³	40-year-old male	Skin biopsy	Foot	Yes; prednisolone therapy for systemic lupus erythematosus	Necrotizing fasciitis	Surgical debridement, ceftazidime	Resolution
Curtis et al ³⁴	51-year-old male	Scraping legs on rocks while fishing in river	Leg	Yes; end-stage renal disease	Necrotizing fasciitis	Surgical debridement, vancomycin, ciprofloxacin, clindamycin, aztreonam	Resolution
Grim et al ¹⁶	54-year-old male	Iguana bite	Posterior calf	No	Bullous cellulitis	Trimethoprim/sulfamethoxazole	Resolution
Grim et al ¹⁶	25-year-old male	Iguana bite	Ankle	No	Bullous cellulitis	Trimethoprim/sulfamethoxazole	Resolution
Motsisi ³¹	37-year-old male	Human bite	Forearm	No	Necrotizing fasciitis	Surgical debridement	Death 2 days after admission
Park and Seo ⁴⁷	62-year-old female	Dermal filler injection	Upper face	No	Inflamed nodule	Trimethoprim/sulfamethoxazole	Resolution
Prelog et al ¹⁶	15-year-old female	Venous access port implantation	Axilla	Yes; active chemotherapy for acute lymphoblastic leukemia	Necrotizing fasciitis	Surgical debridement	Resolution
Subramani et al ³⁰	50-year-old female	Snake bite	Hand	No	Bullous cellulitis and necrotizing fasciitis	Surgical debridement, ciprofloxacin, piperacillin/tazobactam	Resolution
Sharma et al ³²	11-month-old female	Insect bite	Upper chest	No	Abscess followed by ulceration	Ceftazidime, amikacin, amoxicillin/clavulanate	Resolution
Vano-Galvan et al ⁴⁸	57-year-old female	Minor trauma of unspecified origin	Thigh	Yes; chemotherapy for chronic lymphocytic leukemia, type 2 diabetes mellitus	Bullous cellulitis and necrotizing fasciitis	Linezolid, piperacillin/tazobactam	Death 2 hours after presentation
García et al ³⁸	32-year-old male	Tattoo	Elbow	No	Abscess	Incision and drainage, ertapenem, ciprofloxacin	Resolution
Lakhani et al ⁴¹	51-year-old female	Bifemoral bypass and left distal femoral aneurysm repair surgeries	Abdomen and groin	Yes; type 2 diabetes mellitus	Necrotizing fasciitis	Ciprofloxacin	Resolution
Majumdar and Crum-Cianflone ⁴²	54-year-old female	Skin biopsy	Leg	Yes; end-stage renal disease, type 2 diabetes mellitus	Bullous cellulitis and necrotizing fasciitis	Surgical debridement, vancomycin, piperacillin/tazobactam, levofloxacin, clindamycin	Resolution
Roth ³⁹	54-year-old female	Transobturator sling surgery	Thigh	Not specified	Cellulitis	Surgical debridement, ciprofloxacin	Resolution
Hagiya et al ³⁶	64-year-old male	Untreated burn	Leg	Yes; liver cirrhosis	Necrotizing fasciitis	Penicillin G, meropenem, clindamycin	Death from septic shock 25 hours after presentation
Kyvernitakis et al ⁴⁰	71-year-old female	Mastectomy and sentinel node biopsy	Breast	No	Cellulitis with underlying seroma	Aspiration, ciprofloxacin	Resolution
Veraldi and Nazzaro ³⁷	75-year-old male	Scratch from bush	Leg	No	Ulcer	Ceftriaxone	Resolution
Veraldi and Nazzaro ³⁷	75-year-old female	Scratch from rose thorn	Leg	Yes; type 1 diabetes mellitus	Ulcer	Levofloxacin	Resolution
Marin et al ³⁵	50-year-old male	Dropping of piece of drywall to affected area	Foot	Yes; type 2 diabetes mellitus	Bullous cellulitis, liquefactive necrosis, necrotic eschar	Incision and drainage; discharged against medical advice before antibiotic treatment	Lost to follow-up

Based on our review, this may be the first report of *Serratia marcescens* skin infection associated with traumatic break in the skin caused by a dog scratch. The source of *Serratia* in our patient is unclear, but it may have been introduced into the wound by the dog scratch, while cleaning the wound with contaminated isopropanol, or while taking a shower. Risk factors included her profoundly neutropenic state on presentation and her exposure to prophylactic antibiotics during and after chemotherapy. Her chest port, which was located on the same side as her affected arm, was also considered a potential nidus for infection leading to secondary cellulitis. This is less likely given the absence of *Serratia* bacteremia and negative culture of port following removal.

Conclusion

We report a case of *Serratia marcescens* cellulitis following a dog scratch in a neutropenic patient. This case highlights the need for clinicians to consider unusual pathogens based on exposure history in cases of treatment-resistant soft tissue infections in immunocompromised patients. It also emphasizes the importance of obtaining cultures from drainable lesions or tissue to establish a microbiologic diagnosis and allow for targeted therapy.

Authors' Note

This work was presented at the previously presented at the American Federation for Medical Research Southern Regional Meeting (February 2018, New Orleans, LA) and previously published in abstract form (*J Investig Med*. 2018;66(2):467). The contents of this article do not represent the views of the Department of Veterans Affairs or the US government.

Declaration of Conflicting Interests

The author(s) declared no potential conflicts of interest with respect to the research, authorship, and/or publication of this article.

Funding

The author(s) received no financial support for the research, authorship, and/or publication of this article.

Ethics Approval

Our institution does not require ethical approval for reporting individual cases or case series.

Informed Consent

Verbal informed consent was obtained from the patient(s) for their anonymized information to be published in this article.

References

1. Elting LS, Rubenstein EB, Rolston KV, Bodey GP. Outcomes of bacteremia in patients with cancer and neutropenia: observations from two decades of epidemiological and clinical trials. *Clin Infect Dis*. 1997;25:247-259.
2. Neshor L, Rolston KV. The current spectrum of infection in cancer patients with chemotherapy related neutropenia. *Infection*. 2014;42:5-13.
3. Wu DC, Chan WW, Metelitsa AI, Fiorillo L, Lin AN. Pseudomonas skin infection: clinical features, epidemiology, and management. *Am J Clin Dermatol*. 2011;12:157-169.
4. Stevens DL, Bryant AE. Impetigo, erysipelas, and cellulitis. In: Ferretti JJ, Stevens DL and Fischetti VA eds. *Streptococcus pyogenes: Basic Biology to Clinical Manifestations*. Oklahoma City, OK: University of Oklahoma Health Sciences Center; 2016.
5. Talan DA, Citron DM, Abrahamian FM, Moran GJ, Goldstein EJ. Bacteriologic analysis of infected dog and cat bites. Emergency Medicine Animal Bite Infection Study Group. *N Engl J Med*. 1999;340:85-92.
6. Westling K, Farra A, Cars B, et al. Cat bite wound infections: a prospective clinical and microbiological study at three emergency wards in Stockholm, Sweden. *J Infect*. 2006;53:403-407.
7. Oliver JD. Wound infections caused by *Vibrio vulnificus* and other marine bacteria. *Epidemiol Infect*. 2005;13:383-391.
8. Mena KD, Gerba CP. Risk assessment of *Pseudomonas aeruginosa* in water. *Rev Environ Contam Toxicol*. 2009;201:71-115.
9. Marcantonio YC, Kulkarni PA, Sachs S, Ting K, Lee J, Mendoza D. Disseminated *Pasteurella multocida* infection: cellulitis, osteomyelitis, and myositis. *IDCases*. 2017;10:68-70.
10. Fleming MG, Milburn PB, Prose NS. *Pseudomonas septiemia* with nodules and bullae. *Pediatr Dermatol*. 1987;4:18-20.
11. Mahlen SD. *Serratia* infections: from military experiments to current practice. *Clin Microbiol Rev*. 2011;24:755-791.
12. Mills J, Drew D. *Serratia marcescens* endocarditis: a regional illness associated with intravenous drug abuse. *Ann Intern Med*. 1976;84:29-35.
13. Yang CW, Hsu SN, Liu JS, Huang DY. *Serratia marcescens* spinal epidural abscess formation following acupuncture. *Intern Med*. 2014;53:1665-1668.
14. Ersoz G, Uguz M, Aslan G, Horasan ES, Kaya A. Outbreak of meningitis due to *Serratia marcescens* after spinal anaesthesia. *J Hosp Infect*. 2014;87:122-125.
15. Yoshida R, Takae Y, Fujio Y, Tanaka M, Ohyama M. Cutaneous *Serratia marcescens* infection on the face of a healthy female. *J Eur Acad Dermatol Venereol*. 2009;23:1213-1215.
16. Grim KD, Doherty C, Rosen T. *Serratia marcescens* bullous cellulitis after iguana bites. *J Am Acad Dermatol*. 2010;62:1076-1076.
17. Bahadir A, Erduran E. *Serratia marcescens* infection presenting with papillovesicular rash similar to varicella zoster infection: a case report. *North Clin Istanbul*. 2015;2:55-58.
18. Langrock ML, Linde HJ, Landthaler M, Karrer S. Leg ulcers and abscesses caused by *Serratia marcescens*. *Eur J Dermatol*. 2008;18:705-707.
19. Friedman ND, Peterson NB, Sumner WT, Alexander BD. Spontaneous dermal abscesses and ulcers as a result of *Serratia marcescens*. *J Am Acad Dermatol*. 2003;49(2 suppl case reports):S193-S194.
20. João AM, Serrano PN, Cachão MP, Bártole EA, Brandão FM. Recurrent *Serratia marcescens* cutaneous infection mani-

- festing as painful nodules and ulcers. *J Am Acad Dermatol*. 2008;58(2 suppl):S55-S57.
21. Nieves DS, James WD. Painful red nodules of the legs: a manifestation of chronic infection with gram-negative organisms. *J Am Acad Dermatol*. 1999;41(2 pt 2):319-321.
 22. Epstein E, Carson TE. *Serratia* granuloma. *JAMA*. 1973;223:670-671.
 23. García FR, Paz RC, González RS, et al. Cutaneous infection caused by *Serratia marcescens* in a child. *J Am Acad Dermatol*. 2006;55:357-358.
 24. Bachmeyer C, Sanguina M, Turc Y, Reynaert G, Blum L. Necrotizing fasciitis due to *Serratia marcescens*. *Clin Exp Dermatol*. 2004;29:673-674.
 25. Cooper CL, Wiseman M, Brunham R. Bullous cellulitis caused by *Serratia marcescens*. *Int J Infect Dis*. 1998;3:36-38.
 26. Bornstein PF, Ditto AM, Noskin GA. *Serratia marcescens* cellulitis in a patient on hemodialysis. *Am J Nephrol*. 1992;12:374-376.
 27. Fournier JB, Dabiri G, Thomas V, Skowron G, Carson P, Falanga V. *Serratia marcescens* bullous cellulitis in a splenectomized patient: a case report and review of the literature. *Int J Low Extrem Wounds*. 2016;15:161-168.
 28. Bogaert MA, Hogan DJ, Miller AE Jr. *Serratia* cellulitis and secondary infection of leg ulcers by *Serratia*. *J Am Acad Dermatol*. 1991;25:565.
 29. Hsieh S, Bahl FE. *Serratia marcescens* cellulitis following an iguana bite. *Clin Infect Dis*. 1999;28:1181-1182.
 30. Subramani P, Narasimhamurthy GB, Ashokan B, Madappa BP. *Serratia marcescens*: an unusual pathogen associated with snakebite cellulitis. *J Infect Dev Ctries*. 2013;7:152-154.
 31. Motsitsi NS. Fatal necrotizing fasciitis following human bite of the forearm. *J Hand Surg Eur Vol*. 2011;36:605.
 32. Sharma V, Angrup A, Verma S, Singh D, Kanga A. Community-acquired cutaneous ulcer in a child caused by *Serratia marcescens*. *JMM Case Rep*. 2014;1:e003228.
 33. Pereira JA, Greig JR, Liddy H, Ion L, Moss AL. Leech-borne *Serratia marcescens* infection following complex hand injury. *Br J Plast Surg*. 1998;51:640-641.
 34. Curtis CE, Chock S, Henderson T, Holman MJ. A fatal case of necrotizing fasciitis caused by *Serratia marcescens*. *Am Surg*. 2005;71:228-230.
 35. Marin L, Rowan R, Mantilla A, Olupona B, Macintyre A. Lower-extremity infections caused by *Serratia marcescens*: a report of three cases and a literature review. *J Am Podiatr Med Assoc*. 2017;107:231-239.
 36. Hagiya H, Ojima M, Yoshida T, et al. Necrotizing soft tissue infection caused by *Serratia marcescens*: a case report and literature review. *J Infect Chemother*. 2016;22:335-338.
 37. Veraldi S, Nazzaro G. Skin ulcers caused by *Serratia marcescens*: three cases and a review of the literature. *Eur J Dermatol*. 2016;26:373-376.
 38. García JD, Jiménez JV, Sánchez VZ, Ruipérez LC, Pomer AB. Skin abscess due to *Serratia marcescens* in an immunocompetent patient after receiving a tattoo. *Case Rep Infect Dis*. 2015;2015:626917.
 39. Roth TM. *Serratia marcescens* infection after transobturator sling without associated mesh exposure. *Female Pelvic Med Reconstr Surg*. 2015;21:e19-e20.
 40. Kyvernitakis A, Azzi J, Kontoyiannis DP. Mixed mycobacterium avium-intracellulare and *Serratia marcescens* cellulitis of the breast in an HIV-negative patient with breast cancer: a case report. *Cureus*. 2016;8:e634.
 41. Lakhani NA, Narsinghani U, Kumar R. Necrotizing fasciitis of the abdominal wall caused by *Serratia marcescens*. *Infect Dis Rep*. 2015;7:5774.
 42. Majumdar R, Crum-Cianflone NF. Necrotizing fasciitis due to *Serratia marcescens*: case report and review of the literature. *Infection*. 2016;44:371-377.
 43. Huang JW, Fang CT, Hung KY, Hsueh PR, Chang SC, Tsai TJ. Necrotizing fasciitis caused by *Serratia marcescens* in two patients receiving corticosteroid therapy. *J Formos Med Assoc*. 1999;98:851-854.
 44. Bonner MJ, Meharg JG Jr. Primary cellulitis due to *Serratia marcescens*. *JAMA*. 1983;250:2348-2349.
 45. Brenner DE, Lookingbill DP. *Serratia marcescens* cellulitis. *Arch Dermatol*. 1977;113:1599-1600.
 46. Prelog T, Jereb M, Cuček I, Jazbec J. Necrotizing fasciitis caused by *Serratia marcescens* after venous access port implantation in a child with acute lymphoblastic leukemia. *J Pediatr Hematol Oncol*. 2012;34:e246-e248.
 47. Park KY, Seo SJ. Cutaneous *Serratia marcescens* infection in an immunocompetent patient after filler injection. *Acta Derm Venereol*. 2013;93:191-192.
 48. Vano-Galvan S, Álvarez-Twose I, Moreno-Martín P, Jaén P. Fulminant necrotizing fasciitis caused by *Serratia marcescens* in an immunosuppressed host. *Int J Dermatol*. 2014;53:e57-e58.