

CASE REPORT

Case of impacted subglottic metallic foreign body removal without tracheostomy through an endotracheal tube

Minju Kim  | Haechan Park | Seong Keun Kwon

Department of Otorhinolaryngology - Head and Neck Surgery, Seoul National University Hospital, Seoul National University College of Medicine, Seoul, Korea

Correspondence

Seong Keun Kwon, Department of Otorhinolaryngology - Head and Neck Surgery, Seoul National University Hospital, 101 Daehak-ro, Jongno-gu, Seoul, Korea.
Email: otolarynx@daum.net

Abstract

A foreign body in the upper airway can cause serious morbidity and mortality, especially in pediatric patients. This case report describes an innovative way to remove an impacted foreign body distal to the vocal folds through an endotracheal tube without tracheostomy.

KEYWORDS

airway foreign body, foreign body removal, pediatric airway

1 | INTRODUCTION

An airway foreign body in pediatric patients can cause serious complications.¹ Therefore, a diagnosis of foreign body should be considered along with radiological and endoscopic examination in all pediatric patients presenting with wheezing, stridor, or dyspnea, even if the initial swallowing event was not witnessed by the parents.²

A diagnosis of airway foreign body can be confirmed by imaging, including simple chest and C-spine X-rays or computed tomography (CT). Prompt removal by pediatric airway specialists should be planned, but removal can sometimes be hazardous. The introduction of ventilating bronchoscopy has allowed more effective management of pediatric respiratory tract foreign bodies. However, in cases with foreign bodies larger than the diameter of the rigid bronchoscope, tracheostomy or other novel approaches may be required. Here, we present a case of upper airway foreign body impacted under the glottis, which was removed using an endotracheal tube.

2 | CASE REPORT

A 12-year-old boy patient with autism spectrum disorder visited the emergency department after 5 days of wheezing sound and subjective dyspnea. CT performed at another hospital showed a metallic foreign body measuring about 2.0 cm, presumably a paperclip, in the subglottis and proximal trachea at the C5–6 level, with no definite evidence of upper airway perforation. (Figures 1 and 2) The patient was referred to the Otorhinolaryngology Department, and an emergency operation to remove the airway foreign body was planned.

Intubation was impossible due to the impacted subglottic foreign body. Therefore, general anesthesia was induced utilizing a high-flow nasal cannula (flow 60 L/min, FiO₂ 1.0) system to support the patient's self-ventilation. The protruding and bent portion of the metallic foreign body impacted the soft tissue of glottis and subglottis, and removal with optical forceps failed. After placing a size 6 rigid bronchoscope (10339A; Karl Storz), removal of the foreign body via the bronchoscope lumen was attempted, but the diameter of the largest pediatric bronchoscope was

This is an open access article under the terms of the Creative Commons Attribution-NonCommercial-NoDerivs License, which permits use and distribution in any medium, provided the original work is properly cited, the use is non-commercial and no modifications or adaptations are made.

© 2022 The Authors. *Clinical Case Reports* published by John Wiley & Sons Ltd.

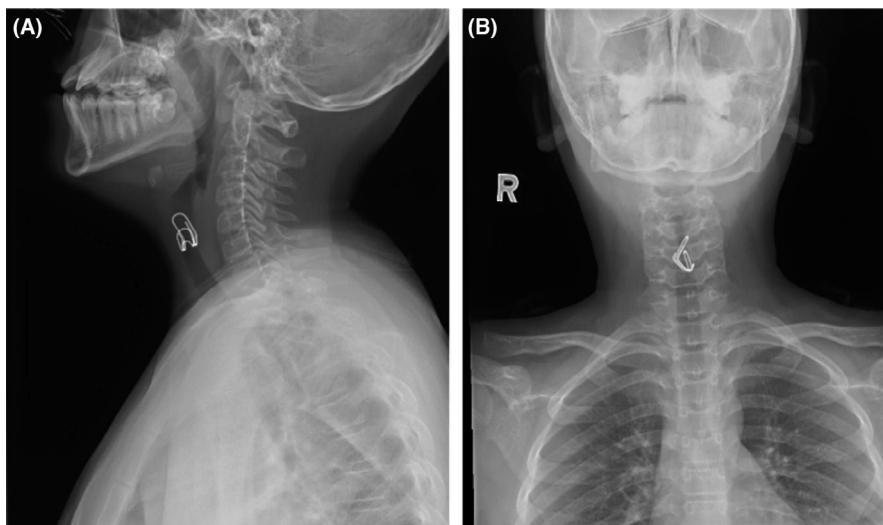


FIGURE 1 C-spine X-rays. (A) Lateral view. (B) A-P view

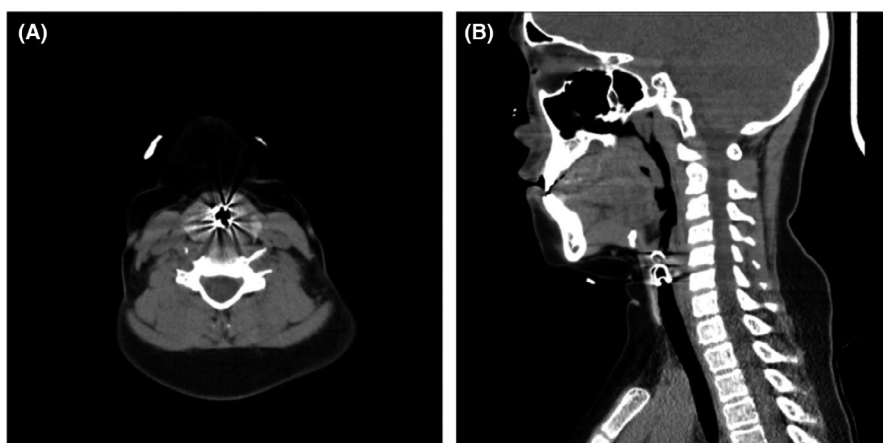


FIGURE 2 Neck CT. (A) Axial view and (B) sagittal view of the aspirated foreign body

not large enough for the object to pass. Next, intubation with an endotracheal tube (ID 7.5 mm), which was large for the patient's airway, was very gently performed by the attending surgeon. The endotracheal tube was carefully advanced, and the foreign body was successfully displaced into the tube lumen. The endotracheal tube and the foreign body were then removed together. (Figure 3) There was no evidence of active bleeding or perforation after successful removal of the foreign body, but due to upper airway mucosal edema, re-intubation was performed by the anesthesiologist, and the patient was transferred to the pediatric intensive care unit (ICU) for ventilator care. Intravenous steroid, antibiotics, and proton pump inhibitor were given.

The patient was observed overnight in the ICU with endotracheal intubation to prevent dyspnea occurring due to the vocal fold edema. Extubating was performed the day after the surgery, and the patient was transferred to a general ward. Vital signs were stable, and the patient did not show any signs of dyspnea. The patient was then discharged home 3 days after the surgery.

Antibiotics, steroid, and proton pump inhibitor were prescribed. Follow-up was done at the outpatient clinic 2 weeks after the surgery. The patient's symptoms, including hoarseness and laryngoscopy findings, were clearly improved.

3 | DISCUSSION

Foreign body aspiration, especially in pediatric patients, can be potentially lethal due to the nature and location of the foreign body or the patient's comorbidities.³ Aspirated objects are usually food materials,¹ but sometimes metal objects are involved, such as orthodontic brackets, paperclips, and pins with pointed portions. Any foreign body must be removed in a way that minimizes damage.

This case demonstrated that the removal of a subglottic foreign body is possible without tracheostomy by utilizing a flexible endotracheal tube. Generally, tracheostomy is indicated in cases in which subglottic foreign bodies

FIGURE 3 (A) Foreign body was identified via suspension laryngoscope. Foreign body removal was attempted with optical forceps (Karl Storz), but the metal foreign body was stuck in the vocal fold and removal failed. (B) The foreign body was relocated distally to the trachea. (C) Removal via the lumen of a rigid bronchoscope was attempted, but this failed due to the size limit of the bronchoscope. (D) Next, an endotracheal tube was inserted with the guidance of the rigid bronchoscope, and the foreign body was introduced into the endotracheal tube using optical forceps. The endotracheal tube and the foreign body were then removed together. (E, F) Endoscopic view after foreign body removal


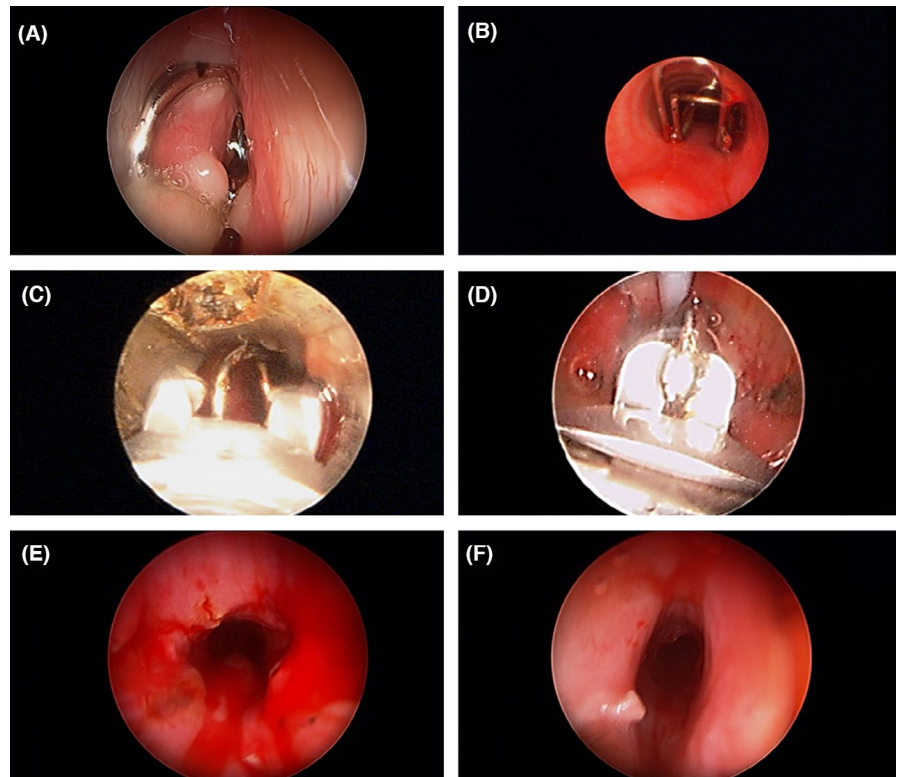


FIGURE 4 Removed foreign body (2 × 1 cm)

cannot pass the glottis due to the size or shape of the foreign body, or if foreign bodies have been in place for a long time.⁴ The subglottic area is the narrowest part of the pediatric airway, and foreign bodies can cause airway edema, which further decreases the diameter of the airway.⁵

We removed the foreign body from the airway via endotracheal tube insertion to reduce the mucosal damage by encasing the foreign body within the lumen of the tube. For this case, we chose an endotracheal tube instead of

a rigid bronchoscope due to the limited diameter of the latter. (Figures 4 and 5) The use of adult-sized rigid bronchoscopes to remove large subglottic foreign bodies in pediatric patients may cause mucosal breakage or damage to the glottis and subglottis. The endotracheal tube may be used as a conduit for the insertion of a flexible bronchoscope, and grasping forceps can then be introduced via the side channel of the bronchoscope. However, as observed in this case, large airway foreign bodies generally require




FIGURE 5 (A) Foreign body could not pass into the lumen of the rigid laryngoscope (10339A; Karl Storz). (B) However, it could be mobilized via endotracheal tube (ID 7.5 mm) insertion

more power to remove than can be provided by grasping forceps in a flexible bronchoscope.

4 | CONCLUSION

An endotracheal tube can be used to remove the impacted subglottic foreign bodies to minimize damage to the surrounding airway tissue and avoid tracheostomy. For the management of pediatric foreign body aspiration, the endotracheal tube can be used in addition to the standard ventilating bronchoscopy techniques.

ACKNOWLEDGEMENTS

None.

CONFLICTS OF INTEREST

None to declare.

AUTHOR CONTRIBUTION

Minju Kim performed data curation, original draft preparation, and reviewed and edited the manuscript. Haechan Park involved in data curation. Seong Keun Kwon reviewed and edited the manuscript and supervised the study.

ETHICAL APPROVAL

The Institutional Review Board of Seoul National University Hospital approved this study (IRB No. #H-2201-142-1294).

CONSENT

Written informed consent was obtained from the patient's legal guardian to publish this report in accordance with the journal's patient consent policy.

ORCID

Minju Kim  <https://orcid.org/0000-0003-4612-7624>

REFERENCES

- Blazer S, Naveh Y, Friedman A. Foreign body in the airway. A review of 200 cases. *Am J Dis Child*. 1980;134(1):68-71.
- Mu L, He P, Sun D. The causes and complications of late diagnosis of foreign body aspiration in children. Report of 210 cases. *Arch Otolaryngol Head Neck Surg*. 1991;117(8):876-879.
- Johnson K, Linnaus M, Notrica D. Airway foreign bodies in pediatric patients: anatomic location of foreign body affects complications and outcomes. *Pediatr Surg Int*. 2017;33(1):59-64.
- Singh JK, Vasudevan V, Bharadwaj N, Narasimhan KL. Role of tracheostomy in the management of foreign body airway obstruction in children. *Singapore Med J*. 2009;50(9):871-874.
- Fraga JC, Neto AM, Seitz E, Schopf L. Bronchoscopy and tracheotomy removal of bronchial foreign body. *J Pediatr Surg*. 2002;37(8):1239-1240.

How to cite this article: Kim M, Park H, Kwon SK. Case of impacted subglottic metallic foreign body removal without tracheostomy through an endotracheal tube. *Clin Case Rep*. 2022;10:e05770. doi:[10.1002/ccr3.5770](https://doi.org/10.1002/ccr3.5770)