

Andrology and fertility

## Successful testicular sperm extraction in infertile male with non-obstructive azoospermia presented with bilateral atrophic testis: A case report

Ricky Adriansjah<sup>\*</sup>, Christopher Kusumajaya, Zola Wijayanti

Urology Department, Hasan Sadikin Academic Medical Center, Faculty of Medicine Universitas Padjajaran, Bandung, Indonesia



## ARTICLE INFO

## Keywords:

Micro-TESE  
Nonobstructive azoospermia  
Small testis  
Spermatozoa

## ABSTRACT

Approximately 50% of men with NOA have minimal sperm production within their dysfunctional testes. Studies shown poor correlations between testicular size and sperm retrieval rates. A 34 years old man with NOA and bilateral testicular atrophic had a successful sperm extraction using mTESE from his 2.1 cc right testicle. Lower testicular volumes significantly decrease sperm retrieval rate in mTESE. However, we described a successful mTESE in atrophic testis. Therefore, small testicular volume does not affect the successful rate of mTESE and should not be a contraindication.

## Introduction

Azoospermia is identified in approximately 1% of all men and in 15% of infertile males.<sup>1</sup> It is divided into obstructive and non-obstructive azoospermia (NOA). NOA is a challenging condition to diagnose and manage. Microdissection testicular sperm extraction (mTESE) has become a recognized and effective procedure to isolate sperm for intracytoplasmic sperm injection (ICSI), with reported of 60% successful rate.<sup>2</sup>

mTESE was first described by Schlegel in 1999 as an advanced microsurgical treatment to retrieve sperm from men with NOA.<sup>3</sup> Several factors have been evaluated and reported for predicting sperm retrieval (SR) rates, including FSH and testicular volume. Men with NOA usually have smaller testicles. Studies to date have only shown poor correlations between testicular size and SR rates.<sup>2</sup> Letterie M et al. reported a failed testicular sperm extraction in 2 cc testes.<sup>4</sup> Here we present a case of 34 years old male infertility who had NOA with bilateral atrophic testes, whose sperm were successfully extracted using mTESE method.

## Case presentation

A 34 years old man presented to our outpatient clinic with inability to impregnate his 32 years old healthy wife. They have been married for 5 years, copulate regularly without using any protection. No prior history of trauma, drugs, or delayed onset of puberty. On further anamnesis, patient had history of mumps when he was a child.

No remarkable findings were seen on general physical examination,

the patient has a normal stature with no signs of gynecomastia and anosmia. Upon testicular palpation, we found small bilateral testicular volume. No tenderness on palpation, and no mass were found on both testicles. Testicular ultrasound indicated small bilateral testicular volume, with dimensions of 2.19 × 1.39 × 1.32 cm (2,1 cc) of right testicle, and 1.85 × 1.31 × 1.19 (1.5 cc) of left testicle (Figs. 1 and 2).

The clinical, routine blood and urine examinations were within normal limits. Laboratory evaluation from his previous check up indicated an elevated FSH (26.05 mIU/ml), normal LH (9.03 mIU/ml), and a decreased testosterone level (1.5 ng/ml). He was then administered a Gonadotropin hormone injection, 6500 IU three times a week. After the therapy, FSH level was dropped to normal level (7.47 mIU/ml), and his testosterone level increased to within normal limit (3.06 ng/ml). Sperm analysis indicated azoospermia. We then diagnosed this patient with NOA, and planned for mTESE procedure.

The surgery was done under general anesthesia, and sperm retrieval was successfully done using mTESE method from right testicle (Fig. 3). The sperm was extracted and prepped for ICSI. No serious problems occurred during the post-operative period, the patient was discharge the day after the operation. At follow-up over a week period, the patient's course was uneventful.

## Discussion

Schoor et al. study concluded men with FSH 7.6 mIU/ml. or greater, or testicular long axis 4.6 cm. or less may be considered to have NOA. mTESE is considered to be the gold standard surgical procedure for

<sup>\*</sup> Corresponding author. Jl. Pasteur No. 38, Bandung, West Java, Indonesia.  
E-mail address: [radriansjah@gmail.com](mailto:radriansjah@gmail.com) (R. Adriansjah).

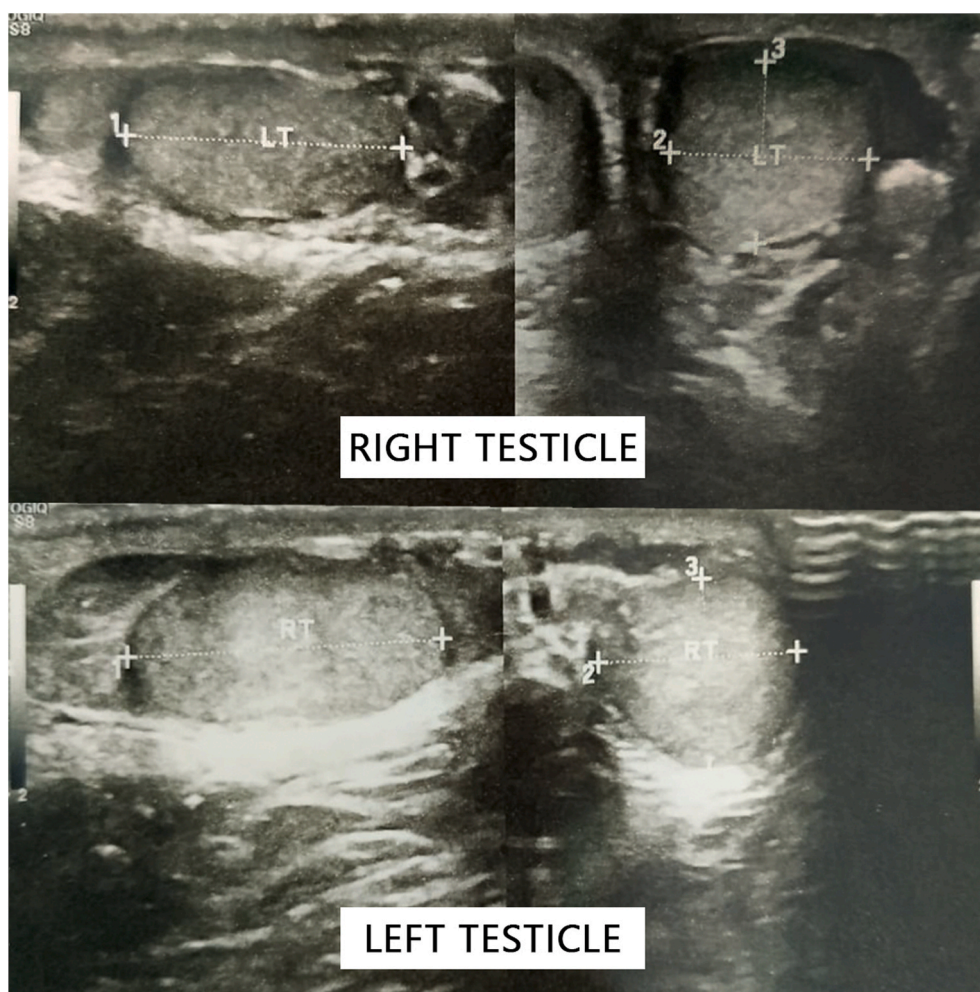


Fig. 1. Ultrasound examination of right and left testicles.

sperm retrieval in NOA patients.<sup>3</sup> Studies documented that mTESE is 1.5-fold more effective than random multiple-biopsy TESE, which is 2-fold more effective than testicular aspiration. There are some indicators that might be predictive for successful SR, one of them is testicular size. Testicular volume is an indirect measure of spermatogenic activity; however, according to the 2019 guidelines of European Association of Urology no testicular volume cut-off value has been estimated for successful sperm harvesting.<sup>5</sup> Older man also have lower SR rate, it is possible that as they age, men with NOA lose some focal areas of spermatogenesis and may have less spermatozoa maturation, decreasing the chance of finding sperm. Sperm were retrieved successfully in 81.8% of those younger than 30 years and only 33.3% of those older than 30 years.<sup>2</sup>

In a previous study, spermatozoa were obtained in 44% of patients with normal testicular volumes and 25% patients with small testicular volumes. In another study, SR rate was found to be 20.8% for testicular volumes under 5 ml and 58.2% for testicular volumes higher than 16 ml.<sup>5</sup> Kizilkan et al. study showed higher testicular volumes were found to increase sperm retrieval in mTESE, and volumes above 11 ml were significantly associated with successful results.<sup>3</sup> Marconi et al. reported that men with a testicular volume of less than 8 ml and FSH greater than 12.4 IU had an approximately 30% chance of testicular SR by mTESE. In a study of 106 men. Similarly, in a study of 85 men with NOA, Ziaee et al. observed that those with successful SR had testes that were larger than those of men with unsuccessful retrieval (average 17.5 vs 5.7 ml). These studies provide evidence that smaller testicle size is associated with a decreased chance of SR.<sup>2</sup>

## Conclusion

It was previously assumed that patients with significantly reduced testicular size would have a decreased chance of SR with mTESE. In our case, we described a successful mTESE of a 34 years old man with a testicular volume of 2 ml. Therefore, small testicular volume does not affect the successful rate of mTESE and severe testicular atrophy should not be a contraindication to mTESE. Further studies are needed to determine the inclusion criteria for successful mTESE.

## Source of support

None.

## Declaration

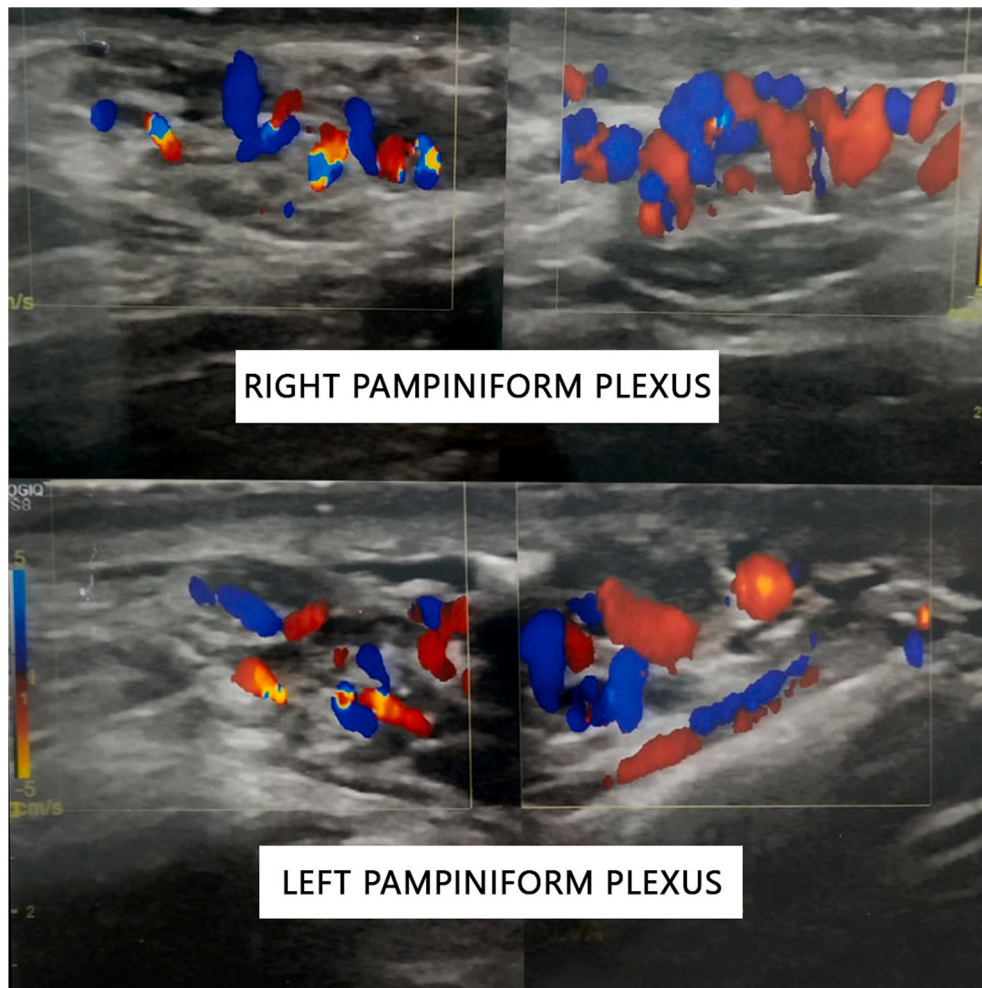
I confirm that I have prepared a separate document containing ALL of the below declarations which I will subsequently upload under the 'Declarations' file type when submitting my manuscript.

## Declaration of competing interestCOI

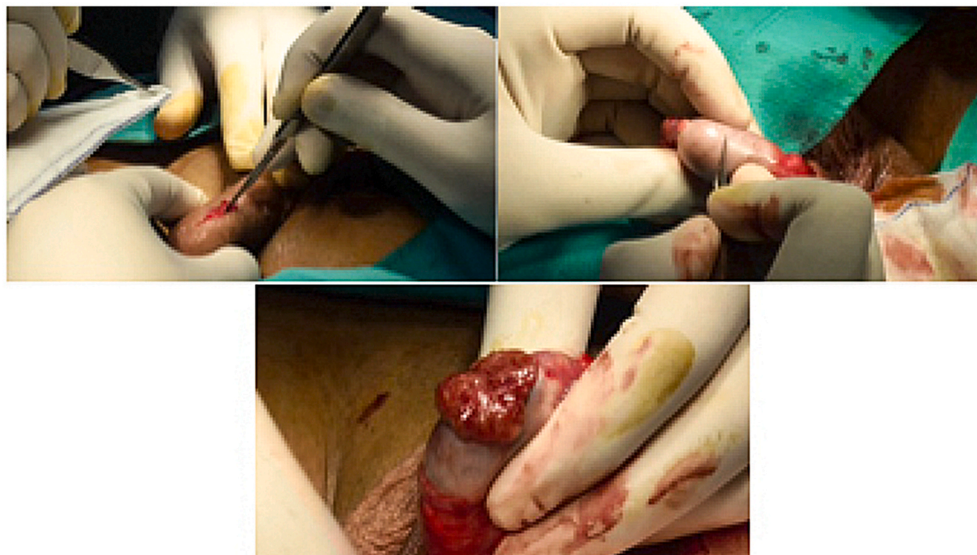
The authors declares that there is no conflict of interest.

## Ethical approval

Ethics permission was obtained from the Health Research Ethics



**Fig. 2.** Color Doppler examination of right and left pampiniform plexus. (For interpretation of the references to colour in this figure legend, the reader is referred to the Web version of this article.)



**Fig. 3.** Intraoperative procedure.

Committee and the Director of Human Resources and Education at Hasan Sadikin Academic Medical Center – Indonesia.

#### Informed consent

Written informed consent was obtained from the patient(s) for their anonymized information to be published in this article.

#### Guarantor

Ricky Adriansjah.

#### Contributorship

Not Applicable.

#### Acknowledgements

None.

#### References

1. Cocuzza M, Alvarenga C, Pagani R. The epidemiology and etiology of azoospermia. *Clinics*. 2013;68:15–26.
2. Bryson CF, Ramasamy R, Sheehan M, Palermo GD, Rosenwaks Z, Schlegel PN. Severe testicular atrophy does not affect the success of microdissection testicular sperm extraction. *J Urol*. 2014;191(1):175–178.
3. Kizilkan Y, Toksoz S, Turunc T, Ozkardes H. Parameters predicting sperm retrieval rates during microscopic testicular sperm extraction in nonobstructive azoospermia. *Andrologia*. 2019;51(11), e13441.
4. Letterie M, Kennedy JL, McClure RD. A case report: non-obstructive azoospermia and normal phenotype in a thirty-eight year old male with a rare klinefelter's syndrome genotype. *Ann Clin Case Rep Reprod Med*.3.
5. Ozer C, Caglar Aytac P, Goren M, Toksoz S, Gul U, Turunc T. Sperm retrieval by microdissection testicular sperm extraction and intracytoplasmic sperm injection outcomes in nonobstructive azoospermic patients with Klinefelter syndrome. *Andrologia*. 2018;50(4), e12983.