

# Hypolacrimia and Alacrimia as Diagnostic Features for Genetic or Congenital Conditions

Marjolaine Willems,<sup>1,2</sup> Constance F. Wells,<sup>2</sup> Christine Coubes,<sup>2</sup> Marie Pequignot,<sup>1</sup> Alison Kuony,<sup>1,3</sup> and Frederic Michon<sup>1</sup>

<sup>1</sup>Institute for Neurosciences of Montpellier, University of Montpellier, INSERM, Montpellier, France

<sup>2</sup>Medical Genetic Department for Rare Diseases and Personalized Medicine, Reference Center AD SOOR, AnDDI-RARE, Montpellier University Hospital Center, Montpellier, France

<sup>3</sup>Université Paris Cité, CNRS, Institut Jacques Monod, Paris, France

Correspondence: Frederic Michon, Institute for Neurosciences of Montpellier, University of Montpellier, INSERM, Montpellier, France; [frederic.michon@inserm.fr](mailto:frederic.michon@inserm.fr).

**Received:** April 24, 2022

**Accepted:** July 7, 2022

**Published:** August 4, 2022

Citation: Willems M, Wells CF, Coubes C, Pequignot M, Kuony A, Michon F. Hypolacrimia and Alacrimia as diagnostic features for genetic or congenital conditions. *Invest Ophthalmol Vis Sci.* 2022;63(9):3. <https://doi.org/10.1167/iovs.63.9.3>

As part of the lacrimal apparatus, the lacrimal gland participates in the maintenance of a healthy eye surface by producing the aqueous part of the tear film. Alacrimia and hypolacrimia, which are relatively rare during childhood or young adulthood, have their origin in a number of mechanisms which include agenesis, aplasia, hypoplasia, or incorrect maturation of the gland. Moreover, impaired innervation of the gland and/or the cornea and alterations of protein secretion pathways can lead to a defective tear film. In most conditions leading to alacrimia or hypolacrimia, however, the altered tear film is only one of numerous defects that arise and therefore is commonly disregarded. Here, we have systematically reviewed all of those genetic conditions or congenital disorders that have alacrimia or hypolacrimia as a feature. Where it is known, we describe the mechanism of the defect in question. It has been possible to clearly establish the physiopathology of only a minority of these conditions. As hypolacrimia and alacrimia are rare features, this review could be used as a tool in clinical genetics to perform a quick diagnosis, necessary for appropriate care and counseling.

**Keywords:** alacrimia, hypolacrimia, tear film, lacrimal gland, genetic disorders

The human eye is a complex structure, composed of an anterior and a posterior segment. The anterior eye segment is comprised of the cornea, iris, ciliary body, and lens. The anterior chamber, limited anteriorly by the cornea and posteriorly by the iris, contains the aqueous humor. The cornea is the avascular transparent tissue in contact with the external environment and covered by the tear film. Together with the lens, they form a single optical element that is instrumental in focusing light onto the retina. The posterior eye segment is composed of the vitreous humor, choroid, retina, and optic nerve.<sup>1</sup>

The tear film, covering the eye surface, is composed of three layers—namely, the lipid, aqueous, and mucous layers. These three different layers are produced respectively by the meibomian glands, the lacrimal glands (LGs), and the goblet cells scattered on the conjunctival epithelium.<sup>2</sup> As the cornea is avascular, the LG supplies the necessary growth factors and cytokines for corneal maturation and homeostasis, as well as antibacterial and antiviral factors.<sup>3</sup> Any defects in tear film quality will deteriorate corneal physiology, which ultimately can lead to opacification and white blindness.<sup>4–7</sup>

In humans, the LG is a tubulo-acinar gland formed of two lobes—the palpebral lobe and the orbital lobe, which are anatomically close to each other. Each lobe is divided into lobules, separated from each other by a loose connective tissue made of extracellular matrix, nerves, and blood vessels. The secreted liquid is delivered on the eye surface through six to 12 lacrimal ducts. Along with the main LG,

its accessory glands, the glands of Wolfring and Krause, are localized, respectively, in the palpebral conjunctiva and in the conjunctival fornix. These glands are structurally and functionally similar to the main LGs and secrete about 10% of the tear volume.<sup>8</sup>

In humans, the LG and the lacrimal outflow pathway develop from the surface ectoderm between 5 and 7 weeks of gestation. Lacrimal gland ducts are formed at 12 weeks of gestation. Despite LGs being fully formed at birth, the mature excretory functions are only acquired postnatally, during the first 6 weeks of life.<sup>9</sup> The mature LG is formed of three distinct cell types—acinar, myoepithelial and ductal compartments—and each has a role in the production, modification, and excretion of the fluids, respectively. Pyramid-shaped cells surrounding a central lumen form an acinus. The acini produce around 80% of the LG tear volume and secrete most of the proteins, electrolytes, water, and other constituents composing the aqueous part of the tear film.<sup>10</sup> Myoepithelial cells are stellate and multiprocessed cells with contractile functions, located around the acini. They maintain acinar integrity, secrete the basal membrane components, and participate in acinar production excretion via their contraction.<sup>11</sup> LG fluid is modified and secreted by ducts. Ductal cells are water permeable and exhibit ion channels, which act upon LG fluid osmolarity. After its secretion, the lacrimal fluid is distributed over the ocular surface through eyelid movements and the presence of a tear meniscus. Overall, the lacrimal apparatus produces tears that are drained into the conjunctival sac via the puncta.<sup>12</sup>

TABLE. Summary of Different Conditions Classified by Origin of Lacrimal Defects

Origin of Lacrimal Defect	Syndrome	MIM #	Inheritance Pattern	Gene	Main Additional Features
LG aplasia/hypoplasia	Hemifacial microsomia	164210	?	—	Hemifacial microsomia
	Absence of LG <sup>+/-</sup> with lipoma		?	—	+/- Lipoma
	LADD	149730	AD	<i>FGFR2, FGFR3, FGF10</i>	Hypoplasia/aplasia of salivary glands, dental anomalies, ear malformations, hearing loss, digital anomalies
	ALSG	180920	AD	<i>FGF10</i>	Hypoplasia/aplasia of salivary glands
	Frontonasal dysplasia 2 syndrome	613451	AR	<i>ALX4</i>	Skull defects, encephalocele, wide nasal bridge, notched nares, depressed nasal tip, hypertelorism, alopecia
LG abnormal maturation	PCWH	609136	AD (de novo)	<i>SOX10</i>	Hirschsprung disease, deafness, iris heterochromia, hypomelanin skin patches, neurologic involvement
	BPES	110100	AD	<i>FOXL2</i>	Ptosis, epicanthus inversus and telecanthus, premature ovarian failure
	XLHED	305100	XL	<i>EDA</i>	Congenital defect of ectodermal structures (hair, teeth, nails, or sweat glands)
	EEC	604292	AD	<i>TP63</i>	Ectodermal defects, cleft lip/palate and ectrodactyly
Abnormal nerve function, congenital	Congenital aplasia of cranial nerves				Depending on the involvement of other cranial nerves
Abnormal nerve function, acquired	APECED (autoimmune)	240300	AR	<i>AIRE</i>	Mucocutaneous candidiasis, hypoparathyroidism, Addison's disease, cataract
	Triple A syndrome	231550	AR	<i>AAAS</i>	Achalasia, adrenal insufficiency with isolated glucocorticoid deficiency, achalasia, autonomic dysfunction, neurodegeneration
	AAMR	615510	AR	<i>GMPPA</i>	Achalasia, developmental delay, gait disturbance, anisocoria, hearing and visual deficits
	HSAN3	223900	AR	<i>ELP1</i>	Gastrointestinal dysfunction, seizures, gait abnormalities, kyphoscoliosis, absence of fungiform tongue papillae, insensitivity to pain and temperature, dysautonomia
	HSAN6	614653	AR	<i>DST</i>	Hypotonia, respiratory distress, absent deep tendon reflexes, autonomic instability, insensitivity to pain, peripheral sensory neuropathy, ulceration of the soles and palms
	HSAN1B	608088	AD	?: linked to 3p22-24 locus	Chronic severe cough, gastroesophageal reflux, axonal sensory neuropathy
	Fabry disease	301500	XL	<i>GLA</i>	Angiokeratoma, cornea verticillata, acroparesthesia, progressive kidney disease, progressive hypertrophic cardiomyopathy, coronary and cerebrovascular disease
	SGS	269150	AD (de novo)	<i>SETBP1</i>	Midfacial retraction, kidney and urinary malformations, multiple skeletal abnormalities, severe neurodevelopmental trouble, neurodegenerative process
	Possible defect of lacrimal secretory function	N-glycanase deficiency	615273	AR	<i>NGLY1</i>
Unknown mechanism	BBSOAS	615722	AD (de novo)	<i>NR2F1</i>	Optic atrophy and intellectual disability, severe neurodevelopmental trouble, deafness
	Limb-girdle muscular dystrophy type 2S	615356	AR	<i>TRAPPC11</i>	Achalasia, hyperkeratosis, psychomotor retardation with intellectual disability, epilepsy, muscular weakness and dystrophy, gait abnormalities, hypotrophy, scoliosis
	Inherited isolated AR alacrimia	601549	AR	?	—
	Isolated AD alacrimia	103420	AD	?	—

AD, autosomal dominant; AR, autosomal recessive; XL, X-linked.

Sensory and parasympathetic innervation of the LG is provided by the lacrimal nerve.<sup>13</sup> It is one of the branches of the ophthalmic nerve (V1). The latter is one of the three divisions of the trigeminal nerve. The lacrimal nerve passes through the superior part of the orbit to innervate the LG.

Dry eye disease can be categorized into either evaporative dry eye, linked to meibomian gland deficiencies, or aqueous deficient dry eye, linked to LG deficiencies. Alacrimia, the total absence of tears, is relatively rare during childhood or young adulthood and becomes more frequent in the elderly population, being present in 15% of seniors above 65 years of age.<sup>14</sup> The relevant processes at work in the elderly may be variable and include neurologic, immunologic, and iatrogenic processes.<sup>15</sup>

Hypolacrimia or alacrimia could be due to several mechanisms. First, agenesis, aplasia, or hypoplasia of the gland generates an insufficiency of tear production. Second, defective maturation of the gland, despite anatomical integrity, leads to abnormal tear production. Third, tear production relies on the integrity of the proteins involved in the secretory lacrimal system. Last, innervation or nerve degeneration affecting LG afferent or efferent nerve transmission may be implicated.

We have attempted here to review systematically all genetic conditions and congenital disorders that include alacrimia or hypolacrimia as a feature. Where known, we have described the pathophysiological mechanism of the lacrimal defect and the consequences of the molecular defect

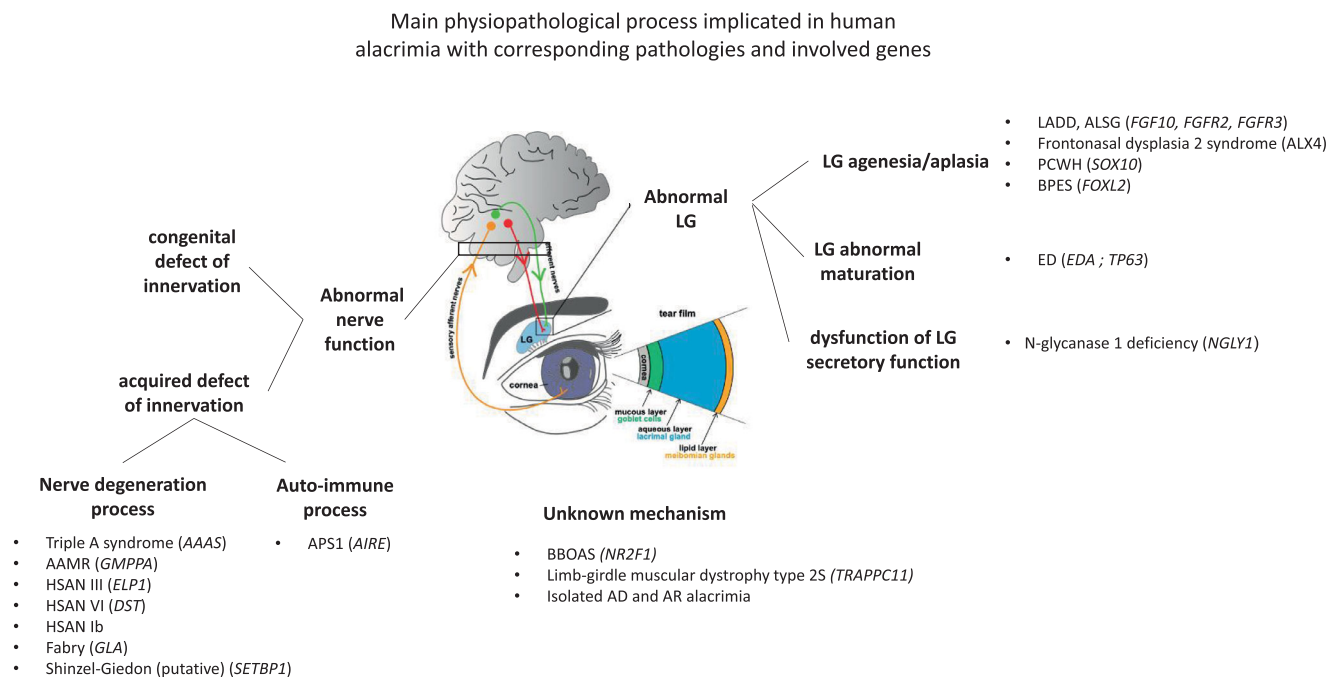


FIGURE. Main pathophysiological processes involved in human hypolacrimia or alacrimia with corresponding anatomical defects, pathology names, and genes identified.

of the gene involved at cellular, tissue, and organismal levels. We believe this will advance understanding of the physiological development of the lacrimal apparatus and provide a diagnostic tool for a better care of the patients (Table, Fig.).

### ANATOMIC ANOMALY: LG APLASIA OR HYPOPLASIA ASSOCIATED WITH SECRETION DEFECTS

The first reported case of a congenital lack of lacrimal secretion was described by Morton in 1884.<sup>16</sup> A boy had hemifacial microsomia, with a right microphthalmia and a less developed right malar bone. He had never shed tears from the right eye. The LG could not be felt on either side, but the hypothesis was that the LG was congenitally absent only on the right side. In 1928, Ishikawa mentioned a 4-year-old boy with alacrimia and postulated that his condition could be explained by congenital hypoplasia of the LG. Sánchez Sevilla et al.<sup>17</sup> reported a case of documented congenital absence of the LG combined with lipoma responsible for unilateral congenital alacrimia. Isolated bilateral LG agenesis was more recently reported by Alwohaib et al.<sup>18</sup> in two unrelated 5-year-old children, one boy and one girl, confirmed by magnetic resonance imaging (MRI). No genetic investigation was performed in these isolated cases, and there was no familial history or information about possible consanguinity in them. Although these cases had no known causes, LG anatomic anomaly has since been reported as being associated with specific syndromes.

Bilateral dacryoceles with punctal and canalicular agenesis and alacrimia form part of the lacrimoauriculardentodigital syndrome (LADD) or Levy-Hollister syndrome (MIM #149730).<sup>19</sup> LADD is an extremely rare autosomal dominant disorder. It results from heterozygous pathogenic variations in the tyrosine kinase domains of one of the three

genes encoding either for the fibroblast growth factor (FGF) receptors *FGFR2* or *FGFR3* or for *FGF10*, an *FGFR2* ligand.

Patients affected with LADD have varying degrees of hypoplasia/aplasia of the salivary glands, which can be responsible for xerostomia, dental cavities, dysphagia, dental anomalies (i.e., hypoplastic enamel, hypodontia, oligodontia, and microdontia). Furthermore, they exhibit inner and outer ear malformations, possible hearing loss, and digital anomalies including aplasia, hypoplasia, syndactyly, clinodactyly, or finger duplications.<sup>20</sup>

Moreover, the ophthalmic involvement in this syndrome is extremely common and presents variable degrees of hypoplasia/aplasia of the lacrimal glands and ducts. It is characterized by a combination of agenesis of the lacrimal puncta, nasolacrimal duct obstruction, and deficiency of tear production. Patients with alacrimia and lacrimal puncta agenesis have no epiphora nor dacryocystitis. In the absence of LGs and normal puncta and nasolacrimal ducts, patients exhibit severe dry eye. The association of LG agenesis, dacryocystocele, and an abnormal lacrimal system is highly suggestive of LADD, even in the absence of other typical symptoms of the syndrome.<sup>19</sup>

Other cases with milder symptoms have been reported which could be associated with mild or rare forms of LADD. Kapoor et al.<sup>21</sup> reported bilateral congenital alacrimia in a patient with giant dacryoceles with punctal and canalicular agenesis. The patient did not have any other abnormality; he did not have dry mouth, ruling out a diagnosis of aplasia of major salivary glands. A report speculated that this case could represent a very mild form of LADD, with only lacrimal expression. Recently, Gupta et al.<sup>22</sup> reported a bilateral congenital dacryoceles with punctal atresia and LG agenesis in a 19-year-old woman and concluded that this represents a rare form of lacrimal outflow dysgenesis. This may consist of a mild, ocular variant of LADD, without any other system involvement. In both cases, the genetic origin of this

anomaly remains speculative, as no molecular investigation was performed.

Pathogenic variations in *FGF10* can also result in aplasia of the lacrimal and salivary glands (ALSG; MIM #180920), an allelic disorder. Affected individuals may suffer from aplasia or hypoplasia of the lacrimal, parotid, submandibular, and sublingual glands and from an absence of the lacrimal puncta.<sup>23</sup> Such individuals are often misdiagnosed with the more prevalent disorder known as Sjögren syndrome, an autoimmune condition characterized by keratoconjunctivitis sicca and xerostomia.

The targeted disruption of individual FGF or FGFR genes (or combinations thereof) in mice, as well as the analysis of disease-causing pathogenic variations in humans, has led to an understanding of the biological roles of individual FGFs and FGFRs. The FGFR family plays crucial roles in many developmental and physiological processes, with a variety of diseases being caused by aberrant signaling induced by FGFs or FGFRs.<sup>24</sup> FGFs have various roles in regulating cell proliferation, migration, and differentiation during development. They usually signal directionally and reciprocally across epithelial-mesenchymal boundaries. Extremely tight regulation of FGF activity and receptor specificity is required to maintain these signaling pathways.

*FGF10* is essential for postnatal life because of its critical role in development of the craniofacial complex, including salivary and lacrimal glands.<sup>25</sup> Notably, it is largely expressed first in mesenchyme and then in epithelial cells in murine salivary glands, in a strictly time-controlled fashion.<sup>26</sup> Makarenkova et al.<sup>25</sup> demonstrated that *FGF10* is an inducer for LG development in mouse embryos.

Shams et al.<sup>27</sup> studied the biological properties of *FGF10* and *FGFR2b* mutants implicated in LADD. They showed that LADD *FGF10* pathogenic variations cause inactivation of *FGF10* and that the tyrosine kinase activity of *FGFR2b* LADD mutants expressed in cultured cells is severely compromised. Although the *FGF10* pathogenic variations cause haploinsufficiency, the *FGFR2b* LADD mutants may exert a dominant negative interfering effect on signaling via normal *FGFR2b*, causing LADD, contrary to the dominant activating effect of *FGFR2* pathogenic variations implicated in craniosynostosis. In a patient with LADD and his mildly affected father, Ryu et al.<sup>19</sup> identified a heterozygous missense variation of *FGFR2*: c.1547C>T (p.Ala516Val); however, the functional consequences of this variation on the protein activity were neither studied nor discussed. The authors considered this variation as probably pathogenic, because the clinical phenotype of LADD was established in this family.

Frontonasal dysplasia 2 syndrome (MIM #613451) is an autosomal recessive disorder arising from biallelic aristaless-like homeobox 4 gene (*ALX4*) loss-of-function pathogenic variations. Patients affected with this syndrome exhibit skull defects, sometimes in combination with encephalocele, wide nasal bridge, notched nares, depressed nasal tip, hypertelorism, and alopecia, sometimes associated with alacrimia.<sup>26</sup>

Garg et al.<sup>28</sup> phenotypically reanalyzed one patient carrying a homozygous c.503delC pathogenic variation in exon 2 of the *ALX4* gene, which resulted in the truncation of the homeobox (HD) and C-terminal OAR domain, previously reported by Kariminejad et al.<sup>29</sup> Since birth, the patient had produced no tears and had experienced multiple episodes of eye infection. An MRI revealed a bilateral absence of LG, confirming a lacrimal aplasia similar to the observed mouse-model phenotype.

*ALX4* encodes a homeodomain transcription factor important for many developmental processes.<sup>30</sup> Homeobox proteins are implicated in early embryonic development. *ALX4* protein is required for development of skull, head, and face. Biallelic pathogenic variations of *ALX4* are thus responsible for defects in skull and face formation.

Garg et al.<sup>28</sup> showed that *ALX4* is required for LG development in mice. In their experiments, inactivation of *Alx4* disrupted *FGF10* expression and downstream FGF signaling, causing failure of LG development. They identified *ALX4* as the key effector of *Shp2* signaling to control the expression of *FGF10* in the periocular mesenchyme. They analyzed *Alx4<sup>4st-J</sup>* mice carrying a frameshift pathogenic variation that removed both the homeodomain and the downstream C-terminal orthopedia, aristaless, and rax (OAR) domain, reproducing the human *ALX4*-related pathology. In homozygous *Alx4<sup>4st-J</sup>* animals, at E14.5, there was a drastic reduction of *FGF10* adjacent to the LG bud, accompanied by a downregulation of FGF target genes ETS variant transcription factor 4 (*Etv4*) and *Etv5* in the LG epithelium. By P1, no LG was detectable. They demonstrated that *ALX4* binds a terrestrially conserved *FGF10* genomic element to regulate its expression in the LG mesenchyme.

PCWH syndrome (peripheral demyelinating neuropathy, central dysmyelination, Waardenburg syndrome, and Hirschsprung disease; MIM #609136), is an autosomal dominant condition that arises from heterozygous SRY-box transcription factor (*SOX10*) pathogenic variations, resulting in a multisystemic disorder.<sup>31</sup>

There is a huge phenotypic heterogeneity in *SOX10*-related disorders, including notably three types of Waardenburg syndrome (WS) including PCWH syndrome, as well as Hirschsprung disease, Kallman syndrome, and nonsyndromic deafness.<sup>30</sup> WS is characterized by the association of deafness and pigmentation anomalies of the skin and eyes, with variable penetrance and expressivity.<sup>32</sup> In type 2, there is no other associated feature, whereas type 4 includes Hirschsprung disease. Patients with PCWH have Hirschsprung disease, deafness, iris heterochromia, hypomelanin skin patches, and neurologic involvement with possible nystagmus, myoclonus, cerebellar ataxia, spasticity, hyporeflexia, arthrogryposis, distal muscle wasting, and severe intellectual disability. Touraine et al.<sup>33</sup> reported alacrimia as a feature in the first reported patients with PCWH. Alacrimia, as well as asialia, was first related to dysautonomia. Elmaleh-Berges et al.<sup>34</sup> retrospectively reviewed imaging studies from 14 WS probands whose subjects all had different pathogenic variations in the *SOX10* gene, including two patients with WS2, six with WS4, and six with PCWH. Hypoplastic or absent LGs were incidentally identified in 65% and 14% of these patients, respectively. This abnormality was associated with aplasia of the parotid glands in some patients and was present in patients with all types of *SOX10*-related Waardenburg, except WS2.<sup>35</sup> However, clinically relevant alacrimia was reported only in patients with PCWH and not in patients with other types of WS.

*SOX10* belongs to the *SOX* family of transcription factors, which are involved in multiple developmental processes, such as neurogenesis and neural crest development, where they control stemness, cell fate, and differentiation.<sup>36,37</sup> The *SOX10* transcription factor is indeed a characteristic marker for migratory multipotent neural crest progenitors, as well as for various neural crest derivatives. *SOX10* also plays a role during differentiation of myelinating Schwann cells and

oligodendrocyte, by inducing stage-restricted transcriptional regulators.<sup>38,39</sup>

There is a large proportion of truncating pathogenic variations in PCWH that are located in the C-terminal part, responsible for an escape from non-sense-mediated RNA decay. A few non-stop pathogenic variations have been described, notably one that generates a specific inframe new C-terminus with the loss of normal termination. Functional studies performed in mouse models have implicated a gain-of-function deleterious effect.<sup>40</sup>

Blepharophimosis, ptosis, and epicanthus inversus syndrome (BPES; MIM #110100) is an autosomal dominant condition linked to loss of function of the *FOXL2* gene. Patients with BPES exhibit the association of ptosis, epicanthus inversus, and telecanthus. Women sometimes exhibit premature ovarian failure. Hypolacrimia and alacrimia are often incorrectly evaluated due to eyelid malformation but have been reported in association with hypoplasia or aplasia of the LG. In a series of 21 patients reported by Duarte et al.,<sup>41</sup> MRI evaluation showed a lack of LG in 52.3%; of these cases, 80% had a bilateral absence of LG. Of the cases exhibiting LGs, 33% showed a reduced LG volume. There was a clear association between these radiologic findings and tear hyposecretion, diagnosed by Schirmer's test, which might be complicated with keratopathy.

Human forkhead box L2 (*FOXL2*) codes 376 amino acids, including a 110-amino acid DNA-binding forkhead domain (FHD) and a polyalanine tract of 14 residues (poly-Ala).<sup>42</sup> It belongs to the winged helix/forkhead transcription factor family. *FOXL2* is a nuclear protein specifically expressed in the mesenchyme of developing eyelids and in fetal and adult ovarian follicular cells.<sup>43</sup> Pathogenic variants in *FOXL2* generate a change in DNA binding and transactivation capacity, causing an abnormal localization of the protein. Some missense variants lead to the mislocation and intranuclear aggregation of the *FOXL2* protein, whereas non-sense variants are usually associated with protein retention in the cytoplasm. Expansions of the polyalanine tract also cause mislocation from the nucleus to the cytoplasm and aggregation of the protein.<sup>44</sup> Such changes affect the interaction of *FOXL2* with target promoters, thus leading to decreased expression of several genes involved in stress response, including apoptosis, transcriptional regulation, mediation of inflammation, cholesterol metabolism, and reactive oxygen species detoxification.

## ABNORMAL MATURATION OF THE LG

Abnormal maturation is defined by anatomical presence and normal volume of the LG but abnormal differentiation resulting in defective tear production.

Ectodermal dysplasia (ED) represents a diverse group of inherited disorders characterized by a congenital defect in two or more ectodermal structures, which derive from embryonic ectoderm, such as hair, teeth, nails, sweat glands, mammary glands, external ear, melanocytes, cornea, conjunctiva, and lacrimal apparatus. All of these can be variably involved.<sup>45</sup>

There is within ED a huge variability in genetic causes and clinical phenotypes. Wright et al.<sup>45</sup> classified the different conditions according to the molecular pathways involved: ectodysplasin-A (EDA)/nuclear factor-kappa B (NF- $\kappa$ B), tumor protein (TP) 63, and structure group. Abnormalities of tear production were described in hypohidrotic

ectodermal dysplasia linked to the *EDA* gene (EDA/NF- $\kappa$ B pathway group) and in p63-related disorders.

X-linked hypohidrotic ectodermal dysplasia (XLHED; OMIM #305100) is an X-linked recessive condition linked to *EDA*. Dry eye diseases observed in patients with XLHED are linked to LG defects.<sup>46</sup> A loss-of-function variant of the *EDA* gene, which belongs to the tumor necrosis factor (TNF) superfamily, was the first genetic alteration identified as being causative for ED.<sup>47</sup> *EDA* signaling acts principally in a paracrine manner and activates NF- $\kappa$ B during skin appendage formation by triggering the formation of an NF- $\kappa$ B-associated switching defective/sucrose nonfermenting (SWI/SNF, or BAF) complex leading to subsequent gene regulation, initiating a signaling to facilitate transcription during organogenesis.<sup>48</sup> In *Eda*<sup>-/-</sup> mutant mice, also called tabby, atrophied LGs were detected during embryogenesis, and a dry eye phenotype was detected in postnatal stages.<sup>49</sup> However, Grüneberg<sup>49</sup> attributed the related dry eye phenotype observed in patients to an atrophy of the meibomian glands and subsequent accelerated tear film evaporation, without evaluating the effect on LG formation and function of *Eda* pathogenic variation. Kuony et al.<sup>50</sup> characterized the physiological and molecular defects of LG in mice resulting from an *EDA* loss-of-function pathogenic variation. They demonstrated that, despite normal morphology, *Eda*<sup>-/-</sup> LGs exhibited altered terminal differentiation in comparison with control. Their results suggest that *EDA* signaling has little or no impact on LG embryonic morphogenesis but results in impaired LG maturation and defective LG secretory function.

In a dog model of XLHED, caused by a point pathogenic variation in the splice-acceptor site of intron 8 that results in a truncated non-functional protein, Casal et al.<sup>51</sup> found that XLHED dogs produce ~25% less lacrimal fluid than wild-type dogs, which may contribute to frequent neonatal eye infections and keratoconjunctivitis sicca in older affected dogs. They corrected these anomalies by administering recombinant *EDA*. More recently, Schneider et al.<sup>52</sup> reported normal development of human fetuses with *EDA* mutations after injecting in utero a recombinant protein including the receptor-binding domain of *EDA*. They injected this protein intra-amniotically into two affected human twins at 26 and 31 weeks of gestation and into a single affected human fetus at 26 weeks of gestation. They observed a partial correction of teeth and sweating defects and a normalization of the meibomian gland number.

The second group of ED syndromes includes all TP63 pathway syndromes, including five clinically defined different syndromes. These are autosomal dominant disorders arising from *TP63* heterozygous pathogenic variations, which can be associated with ectodermal defects, cleft lip/palate, and ectrodactyly.<sup>53</sup>

The ocular phenotype of patients suffering from ectrodactyly ectodermal dysplasia cleft lip/palate syndrome (EEC) linked to *TP63* (MIM #604292) was studied by Di Iorio et al.,<sup>54</sup> who aimed to determine the pathogenic basis of visual phenotype. Twenty-three patients underwent a full ocular assessment, and all had ocular defects, the most common being an anomaly of the meibomian glands, which was present in all 23 cases (100%). These meibomian gland defects resulted in evaporative dry eye, which was evidenced in all assessed patients by unstable tear film, as measured by the tear film breakup time. The second most common ocular anomalies consisted of lacrimal drainage system defects (absence, occlusion, or stenosis), which were present in 21 of 23 cases (91.3%). Anomalies of tear meniscus height and

tear function index revealed the presence of aqueous tear deficiency in 56.5% of the patients (13/23).

TP63 (also known as p63) is a transcription factor of the p53 family.<sup>55</sup> Multiple isoforms of p63 have been discovered and have diverse functions, including lineage specification, proliferative potential, differentiation, cell death and survival, DNA damage response, and metabolism. It is a key regulator in epithelial and ectodermal structure commitment and development. TP63 is a convergence of numerous signalization pathways and is directly regulated by the wntless-type MMTV integration site family (Wnt)/ $\beta$ -catenin pathway.<sup>56</sup> It is also an important downstream target of Hedgehog signaling.<sup>57</sup> In addition to the role of NF- $\kappa$ B in regulating p63 in response to DNA damage, NF- $\kappa$ B-mediated repression of TP63 also plays a role in epithelial cell differentiation.<sup>58</sup> The tyrosine kinase receptor epidermal growth factor receptor can also induce TP63 expression.<sup>59</sup> TP63 is additionally regulated in a cell-type-specific manner by Notch, which is a key regulator of maintenance and cell fate.<sup>60</sup>

## ABNORMAL NERVE FUNCTION

### Congenital Defects of Innervation

Sjögren and Eriksen<sup>16</sup> were the first to provide a historical review of cases of alacrimia congenita and reported cases associated with cranial nerves aplasia. In 1900, Heubner described a boy, 11 years old with healthy parents, who suffered from double-sided paralysis of the abducent, facial, and hypoglossal nerves, the left side being more affected than the right, with a complete lack of tears. Postmortem examination revealed that the cause was a congenital aplasia of the brain where the nuclei of these nerves lie. Thus, the left hypoglossus, the left facialis, and both abducens nuclei were lacking. In the right hypoglossus and facialis nuclei, the cells were fewer than usual. In 1921, Kayser reported a case of congenital trigeminal paralysis with total lack of tears. In 1931, Lutz suggested that the cause of alacrimia might be anaplasia of the petrosal bone with co-existing aplasia of the nervus petrosus superficialis major.

### Acquired Defects of Innervation

**Autoimmune Process.** Autoimmune polyendocrine syndrome type 1 (APS1), or autoimmune polyendocrinopathy–candidiasis–ectodermal dystrophy (APECED; MIM #240300), is a rare polyendocrinopathy with autosomal recessive inheritance. It results from defects in the human autoimmune regulatory (*AIRE*) gene.

The three major manifestations of APS1 are mucocutaneous candidiasis, hypoparathyroidism, and Addison's disease. Ophthalmic manifestations include keratoconjunctivitis, dry eye, iridocyclitis, and cataract.<sup>61</sup>

APS1-associated keratopathy appears to be an early manifestation, with the age of onset ranging from 2 to 9 years. Most cases have dry eye with a variable degree of pain and photophobia.<sup>62</sup>

The *AIRE* gene encodes a protein, the function of which has been discovered through the generation and study of *Aire* knockout (KO) mice.<sup>63</sup> The broad spectrum of self-antigens expressed by medullary thymic epithelial cells and presented to the developing thymocytes is linked to *AIRE* expression.<sup>64</sup> Chen et al.<sup>64</sup> used a spontaneous mouse model deficient in the *Aire* gene. The mice developed spontaneous,

CD4<sup>+</sup> T-cell-mediated exocrinopathy and aqueous-deficient dry eye, which were associated with a loss of nerves causing innervation of the cornea and LG. Changes in innervation and tear secretion were accompanied by increased proliferation of corneal basal epithelial cells, limbal expansion of keratin 19 (KRT19)<sup>+</sup> progenitor cells, increased vascularization of the peripheral cornea, and reduced nerve function in the LG. In addition, they found extensive loss of muscle, intestine, and stomach expression 1 (MIST1)<sup>+</sup> secretory acinar cells in the *Aire*<sup>-/-</sup> LGs, suggesting that acinar cells are also among the primary targets of the disease. The topical application of ophthalmic steroid enabled the effective restoration of corneal innervation in *Aire*<sup>-/-</sup> mice, demonstrating the link between nerve loss and local inflammation in the dry eye. An *Aire* KO rat model also recapitulated features observed in patients with APECED, including visual features, organ lymphocytic infiltrations, and the production of autoantibodies.<sup>65</sup>

**Nerve Degeneration Process.** Triple A syndrome (MIM #231550) was previously known as 4A syndrome. This syndrome is an autosomal recessive condition arising from biallelic pathogenic variations in the achalasia–addisonianism–alacrimia syndrome (AAAS) gene, whose predicted protein is ALADIN (alacrimia–achalasia–adrenal insufficiency neurologic disorder).<sup>66</sup> Alacrimia is the first and most consistent feature of this syndrome, resulting from a deterioration of the autonomic innervation of the LG rather than an impaired corneal innervation. Other features may appear within a variable time frame. These include achalasia, features of autonomic dysfunction, neurodegeneration, and insensitivity to adrenocorticotrophic hormone, which can result in adrenal insufficiency and isolated glucocorticoid deficiency. In addition to alacrimia, the ophthalmic manifestations include keratoconjunctivitis sicca, corneal melts, LG atrophy, pupillary abnormalities including sluggish pupils, tonic pupils with hypersensitivity to dilute miotics, accommodative dysregulation, amblyopia, and optic atrophy. Lacrimation (both reflex and basal), pupillary miosis, and the process of accommodation are under parasympathetic control.<sup>67</sup> Mullaney et al.<sup>68</sup> studied LG in three patients with triple A syndrome, and, by means of orbital imaging, they observed a reduction in LG size; on LG biopsy, this was associated with a reduced number of serous secreting cells.

Aragona et al.<sup>69</sup> reported the complete ophthalmologic investigation results of an 18-year-old male patient. Using the Schirmer's test of 0 mm/5 minutes in both eyes, they documented his dry eye condition, which was accompanied by tear hyperosmolarity, mild meibomian gland dysfunction, reduced break-up time, mucus filaments in the tear film, and conjunctival epithelium metaplastic changes. Activated keratocytes and a normal nerve pattern were observed. They concluded that the dry eye appeared to arise from a tear aqueous deficiency.

By contrast, Botella García et al.<sup>70</sup> successfully used topical cyclosporine A 0.05% in a patient with hypolacrimia arising from Allgrove syndrome. By inhibiting IL-2 activation of lymphocytes, cyclosporine A produces immunomodulatory and antiinflammatory effects. The authors hypothesized that the patient may suffer from the anatomical underdevelopment of both the main LG and the functional accessory LG of Krause and Wolfring. Cyclosporine A treatment was effective. It decreased the overall inflammation of the ocular surface and recovered goblet cells.

The precise role of Aladin is not understood. It normally localizes to the cytoplasmic face of the nuclear membrane, as part of the nuclear pore complex (NPC), which is involved in nucleocytoplasmic transport. Bitetto et al.<sup>71</sup> explored the consequences of the homozygous *AAAS* pathogenic variation c.464G>A (p.R155H) in the central nervous system tissues and fibroblasts of a patient presenting motor neuron disease, cerebellar ataxia, and autonomic dysfunction. By neuropathological analyses, a significant reduction in the perinuclear expression of Aladin was demonstrated, associated with a severe loss of motor neurons and Purkinje cells.

Alacrimia, achalasia, and mental retardation syndrome (AAMR; MIM #615510) is an autosomal recessive condition caused by biallelic pathogenic variations in the guanosine diphosphate (GDP)-mannose pyrophosphorylase A (*GMPPA*) gene. Alacrimia, achalasia, and developmental delay occur at birth or in early infancy. Other features can include hypotonia, gait disturbance, anisocoria, and hearing and visual deficits. Although the disorder resembles the triple A syndrome, it never includes adrenal insufficiency. The clinical features of the patients with pathogenic variations indicate that *GMPPA* plays a significant role in neurons, in autonomic nerve fibers and in the innervation of the distal esophageal sphincter and the LG.<sup>72</sup>

GDP-mannose pyrophosphorylase B (*GMPPB*) catalyzes the conversion of mannose-1-phosphate and guanosine-5'-triphosphate (GTP) to GDP-mannose, which is required for glycosylation. Hypoglycosylation of  $\alpha$ -dystroglycan ( $\alpha$ -DG) linked to *GMPPB* defects causes muscle disease.<sup>73</sup>  $\alpha$ -DG belongs to a protein complex that stabilizes myofibers by linking the extracellular matrix with the cytoskeleton.<sup>74</sup> Franzka et al.<sup>75</sup> showed that *Gmppa* KO mice recapitulate cognitive and motor deficits observed in patients with AAMR. *GMPPA* is an allosteric feedback inhibitor of *GMPPB*. *GMPPA* defects generate an enhancement of mannose incorporation into glycoproteins, including  $\alpha$ -DG in mice and men. Thus,  $\alpha$ -DG turnover is increased and  $\alpha$ -DG abundance is decreased.

Marom et al.<sup>76</sup> reported on a consanguineous Israeli Arab family with five males in two interrelated families with intellectual disabilities, alacrimia, achalasia, and mild autonomic dysfunction, naming this the X-linked mental retardation 17 syndrome (MRX17) condition. The phenotype was similar to those described in AAMR. The pedigree was compatible with either X-linked or autosomal recessive inheritance. Linkage to chromosome X was suspected, given that genotyping of affected family members identified a 16.4-Mb continuous segment of identical alleles shared by the patients between markers rs2748314 and rs5906782 on Xp11.23-p21. However, no molecular anomaly has been identified since then, nor has any other family compatible with the X-linked phenotype been described. It is thus probable that MRX17 is not a real clinical entity.

Hereditary sensory and autonomic neuropathy type III (HSAN3; MIM #223900) is an autosomal recessive neurodegenerative disorder linked to the elongator complex protein 1 (*ELP1*) gene, with onset soon after birth and affecting mostly the Ashkenazi Jewish population. Progressive depletion of sensory proprioceptive and autonomic neurons leads to progressive symptoms, including gastrointestinal dysfunction, gastroesophageal reflux, vomiting crises, recurrent pneumonia, seizures, gait abnormalities leading to loss of ambulation, kyphoscoliosis, orthostatic hypotension, hypertension crises, absence of fungiform tongue papillae, decreased deep tendon reflexes, defective lacrimation, insen-

sitivity to pain and temperature, and finally death. Only 50% of patients reach 40 years of age.<sup>77</sup>

This neuropathy is caused by a "leaky" mRNA splicing defect that results in reduced levels of the inhibitor of kappa B kinase complex-associated protein (IKBKAP, also referred to as IKAP and ELP1).<sup>78</sup> Homozygous mutant cells express both wild-type and mutant inhibitor of *IKBKAP* mRNA and produce small amounts of full-length functional IKAP, as the pathogenic variation weakens but does not completely abolish the 5' splice site of exon 20.<sup>79</sup> There is a variability of the relative expression of wild-type and mutant *IKBKAP* transcripts between tissues. The lowest levels of wild-type *IKBKAP* mRNA and IKAP are observed in the central and peripheral nervous systems. In vivo studies have highlighted that the loss of IKAP (ELP1) leads to neuronal cell death because of failed tissue innervation rather than abnormal neuronal migration.<sup>80</sup>

HSAN6 (MIM #614653) is an autosomal recessive disease linked to biallelic dystonin (*DST*) pathogenic variations. It was first identified in infants with lethal autonomic sensory neuropathy presenting clinical features similar to familial dysautonomia associated with contractures.<sup>81</sup> Symptoms can begin at birth, during childhood, or during adulthood in milder forms. Patients who present the disease at birth have been reported as having hypotonia, respiratory distress, absent deep tendon reflexes, and autonomic instability including hyperthermia and hypothermia; blood pressure and heart and respiratory rate lability; and alacrimia with corneal injury. In milder forms, clinical features consist predominantly of dysautonomia, insensitivity to pain, and peripheral sensory neuropathy, complicated with ulceration of the skin of the soles and palms.<sup>82-85</sup>

The human *DST* gene has multiple promoters that lead to different isoforms, with a specific tissue and subcellular distribution that has yet to be fully characterized. Dystonin is a large cytoskeleton linker protein.<sup>86</sup> HSAN6 appears to be caused by the disruption of neuronal isoform dystonin-a2. It is speculated that the truncation of pathogenic variations that result in the loss of expression of all neuronal isoforms produces a severe disorder with congenital defects and early lethality, whereas pathogenic variation combinations that partially maintain dystonin protein expression and function will have less severe clinical expression and will generate neuropathies without major reduction of lifespan.<sup>87,88</sup> In vitro studies have shown that dystonin is significantly more abundant in cells of familial dysautonomia patients bearing *IKBKAP* pathogenic variations in comparison with control fibroblasts.<sup>81</sup> This suggests that upregulation of dystonin could be an adaptive cellular response in HSAN3 patients.

Recessive *Dst* pathogenic variations in mice are responsible for dystonia musculorum (*Dst<sup>dt</sup>*), a sensory neuropathy.<sup>89</sup> Affected mice exhibit ataxia, autonomic disturbances, and ultimately death linked to massive degeneration of the sensory neurons in the dorsal root ganglion. The phenotype is partially rescued by restoring the dystonin-a2 expression in neuronal tissues. Recent investigation of *Dst<sup>dt</sup>* sensory neurons revealed an accumulation of autophagosomes, suggesting an autophagy defect.<sup>90</sup> Defects in cell adhesion and migration consequent to Dystonin pathogenic variations may interfere with neurite outgrowth and guidance and could contribute to neurodegeneration by cytoskeletal impairment and consequent axonal transport defects.

Hereditary sensory and autonomic neuropathy type 1B (HSAN1B), with cough and gastroesophageal reflux (MIM #608088), was described in 2002 by Spring et al.<sup>91</sup>

Adult-onset patients suffered from unexplained chronic coughing that could lead to syncopes and gastroesophageal reflux, associated with sensory loss starting with the lower limbs and a loss of tendon reflexes due to axonal neuropathy concerning unmyelinated and myelinated axons. Some patients also suffered from sensorineural hearing loss. In 2005, Spring et al.<sup>92</sup> precisely described the phenotype in 17 affected individuals from two families. Alacrimia, as diagnosed by Schirmer's test, was identified in two individuals of the same family.

In 2003, in a study involving in two families, Kok et al.<sup>93</sup> used genome-wide screening to identify a 3.42-cM interval containing the locus for HSN1B on chromosome 3p22-24. The locus contained 28 mapped genes. Two candidate genes were then discussed: topoisomerase II  $\beta$  (*TOP2B*) and solute-carrier family 4 member 7 (*SLC4A7*). However, these were not taken into consideration in HSN1B in later studies. To our knowledge, the molecular basis of HSN1B remains unknown, with no additional individuals with HSN1B and alacrimia having been reported subsequently.

Fabry disease (FD; MIM #301500) is a treatable multi-system X-linked disease caused by a defect in the alpha-galactosidase A (*GLA*) gene and the consequent accumulation of toxic metabolites such as globotriaosylceramide (Gb3) and globotriaosylsphingosine (lyso-Gb3).<sup>94</sup>

The classic disease manifestations of FD in males include the characteristic angiokeratoma, corneal opacity (cornea verticillata), neuropathic pain (acroparasthesias) due to small-fiber neuropathy, intolerance to heat, inability to sweat, micro-albuminuria, and increased intima media thickness. Later in life, these patients develop progressive kidney disease with progressive renal failure, cardiac symptoms that may include progressive hypertrophic cardiomyopathy, conduction defects and arrhythmia, atrial fibrillation, valvular disease and coronary artery stenosis, and cerebrovascular disease (stroke). In heterozygous FD females, clinical manifestations, which are highly variable, are usually less severe than in heterozygous FD males, and can be restricted to one specific organ.<sup>95</sup>

Ocular signs of FD, including corneal verticillata and corneal dysesthesia resulting from small-fiber neuropathy, are typically among the first symptoms to be identified. Sivley et al.<sup>96</sup> performed a longitudinal study of ocular manifestations in a cohort of 13 patients with FD. Twelve of the 13 patients had evidence of dry eye, nine of whom were symptomatic. They had inflammatory eyelid disease, including blepharitis, as well as meibomian gland dysfunction, superficial punctate keratitis, and excessive watering of the eyes, or some combination of these. Nine of the 12 with dry eye reported symptoms of foreign body sensation, chronic irritation, and/or photophobia. Among them, 89% also had conjunctival lymphangiectasia.

**Putative Neurodegenerative Process.** Schinzel-Giedion syndrome (SGS; MIM #269150) is a rare autosomal dominant condition arising from SET binding protein 1 (*SETBP1*) heterozygous de novo pathogenic variations. This is a multiple congenital malformation syndrome defined by an evocative midfacial retraction, kidney and urinary malformations, and multiple skeletal abnormalities associated with a neurodegenerative process.<sup>97</sup> Minn et al.<sup>98</sup> reported two infant patients with SGS with alacrimia, confirmed by Schirmer's test, and corneal hypoesthesia associated with severe visual impairment. The exact origin of the alacrimia and corneal hypoesthesia has not yet been identified but

could be related to neurodegenerative processes at the level of the atrophic brainstem, in particular the pons.

*SETBP1* pathogenic variations responsible for SGS occur in a four-amino-acid mutational hotspot.<sup>97</sup> These variations result in an increased half-life of the mutated *SETBP1* protein, causing its accumulation and the subsequent inhibition of the protein phosphatase 2A (PP2A) oncosuppressor through the *SETBP1*-*SET*-PP2A axis. *SETBP1* is a DNA-binding protein. *SETBP1* interacts with genomic DNA through its AT-hook domains, forming a multiprotein complex with host cell factor C1 (HCF1), lysine-specific *N*-methyltransferase 2A (KMT2A), plant homeodomain-like finger protein 8 (PHF8), and PHF6. *SETBP1* gene ontology analysis of deregulated *SETBP1* target genes indicates that they are key controllers of visceral organ development and brain morphogenesis. In mouse models, in utero brain electroporation of mutated *SETBP1* impairs neurogenesis and is responsible for a profound delay in neuronal migration.<sup>99</sup>

### POSSIBLE LACRIMAL SECRETORY FUNCTION DEFECT

*N*-glycanase 1 (*NGLY1*) deficiency (MIM #615273), an autosomal recessive congenital disorder of deglycosylation, is caused by pathogenic variations in the *NGLY1* gene. *NGLY1* deficiency is characterized by developmental delay, hypolacrimia or alacrimia, seizure, intellectual disability, movement disorders, and other neurological phenotypes.<sup>100</sup>

The *NGLY1* protein has a pivotal role in endoplasmic reticulum-associated degradation processes, cleaving *N*-glycans from misfolded glycoproteins in the cytosol before they can be degraded by the proteasome. Loss of *NGLY1* leads to accumulation of cytoplasmic ubiquitinated proteins, a marker of misfolded proteins in the neurons of the central nervous system.<sup>101</sup>

Tambe et al.<sup>102</sup> identified a resistance to hypotonic lysis in *Ngly1*-null mouse embryonic fibroblasts, *NGLY1* KO human cells, and patient fibroblasts. *Ngly1*-deficient mouse embryonic fibroblasts swell more slowly and have reduced aquaporin 1 mRNA and protein expression. In *NGLY1*-deficient mouse embryonic fibroblasts, the activating transcription factor 1 (ATF1)/cAMP-response element binding protein (CREB) signaling pathway was disrupted, leading to reduced aquaporin 1 expression. The *aquaporin 1* mRNA level was reduced in patient fibroblasts and *NGLY1* KO cells, thus suggesting that *NGLY1* may regulate the expression of multiple aquaporins.<sup>102</sup> These results led to the identification of a non-enzymatic, regulatory function of *NGLY1* in aquaporin transcription, possibly related to alacrimia and neurological symptoms. Aquaporins are a family of 13-membrane proteins expressed in most exocrine and endocrine secretory glands.<sup>103</sup> Their role is essential in the transport of fluids across the cell plasma membrane. *Aquaporin 5*<sup>-/-</sup> mice have dry eye symptoms and a modified structure of LG epithelial cells.<sup>104</sup>

However, the data currently available are not sufficient to exclude the implication of other mechanisms, such as neural degeneration, in the occurrence of alacrimia in patients with an *NGLY1* deficiency.

### CURRENTLY UNKNOWN MECHANISMS

Bosch-Boonstra-Schaaf optic atrophy syndrome (BBSOAS; MIM #615722) is a rare congenital syndrome arising from



pathogenic de novo variants in the nuclear receptor subfamily 2 group F member 1 (*NR2F1*) gene.<sup>105</sup>

The main features of this syndrome are optic atrophy and intellectual disability. The neurodevelopmental issues are usually severe, with moderate to severe intellectual disability, autistic features, and in certain cases epilepsy. Other features include facial dysmorphism and deafness (20%–40%). Absent or decreased reflex tears are reported in 78% of patients.<sup>106</sup> As with the associated deafness, the exact mechanism of alacrimia in this condition has not yet been investigated, neither in patients nor in mouse models. Cerebral MRIs performed on patients have not focused on LGs. Having noticed that the molecular and cellular mechanisms contributing to visual impairment were still poorly characterized, Jurkute et al.<sup>107</sup> gave a precise report of the ocular phenotype in patients with BBSOAS and in mouse models, but they did not study LG or tear secretions. Regardless, it should be stressed that alacrimia is a clue symptom, and as such can help to diagnose BBOAS in patients with intellectual disability.

NR2F1 belongs to the nuclear hormone receptor family of steroid hormone receptors. Paired box protein 6 (*PAX6*) is a key regulator in LG development in mouse and *NR2F1* loss of function affects *PAX6* expression, suggesting a possible defect of LG development in patients with BBSOAS.<sup>25</sup> Conversely, mitochondrial involvement with secondary complex IV deficiency of the mitochondrial respiratory chain has also been documented in patients with BBOAS.<sup>108</sup> Moreover, NR2F1 strongly affects neurogenesis. Thus, a neurogenic mechanism could also be involved in the pathophysiology of alacrimia in patients with BBOAS.

Pathogenic variations in trafficking protein particle complex subunit 11 (*TRAPPC11*) have been described as causing limb-girdle muscular dystrophy type 2S (MIM #615356).<sup>109</sup> Four patients from two unrelated consanguineous Turkish families described by Koehler et al.<sup>110</sup> exhibited achalasia from childhood, congenital alacrimia, no adrenal insufficiency, hyperkeratosis, psychomotor retardation with intellectual disability, epilepsy, muscular weakness and dystrophy, gait abnormalities, short stature and ponderal hypotrophy, and scoliosis, thus expanding the phenotype of limb-girdle muscular dystrophy type 2S. The authors underlined the similarities with triple A syndrome, consisting of a differential diagnosis, as well as AAMR. Although the mechanism of alacrimia remains unexplained, it should be noted that there was no sign of autonomic dysfunction at the ocular level.

Koehler et al.<sup>110</sup> identified a *TRAPPC11* homozygous splice pathogenic variation (c.1893+3A>G), resulting in a splicing defect in patients. In doing so, they were the first to describe alacrimia as a feature of this defect. The transport protein particle (TRAPP) is a multiprotein complex with several related but compositionally distinct forms, implicated in multiple processes including endoplasmic reticulum to Golgi transport, intra-Golgi and endosome to Golgi transport, and autophagy. *TRAPPC11* belongs to the mammalian TRAPP III complex. Quantification of mRNA and protein suggested that the dysfunction of the protein was due to a very low amount of intact *TRAPPC11* transcript in combination with an aberrant splicing product. *TRAPPC11* protein levels have been associated with hypoglycosylation of lysosomal-associated membrane protein 1 (*LAMP1*), which participates in the maintenance of lysosomal integrity and function. Analysis of fibroblasts from patients revealed delayed exit through the Golgi apparatus of a marker

protein, indicating a defect in secretory trafficking. However, the exact pathophysiology and molecular consequences of *TRAPPC11* defect have not yet been fully characterized.

Both inherited isolated autosomal recessive alacrimia (MIM #601549) and autosomal dominant alacrimia (MIM #103420) have been reported. Hegab and al-Mutawa<sup>111</sup> described three consanguineous cousins with alacrimia, suggesting an autosomal recessive inheritance of a dysfunction of the LG.

Hegab et al.<sup>112</sup> also reported a Kuwaiti Arab family in which the father and one of his two sons had severe hypolacrimation with blotchy staining of the cornea and punctate staining of the interpalpebral bulbar conjunctiva by fluorescein and rose bengal staining, suggesting an autosomal dominant isolated hypolacrimia. The only other recorded pedigree with autosomal dominant transmission is an Irish family, with five affected members from four generations. These differed from the Kuwaiti family in that they also had atopic dermatitis.<sup>113</sup>

## CONCLUSIONS

Hypolacrimia and alacrimia are rare features in which different mechanisms can be involved. For a minority of conditions in which they figure, the pathophysiology is clearly established. However, because LGs have been inadequately studied in human development and childhood physiology, as well as in pathologic situations, most existing explanations remain putative or insufficiently proved. In clinical genetics, hypolacrimia and alacrimia are rarely encountered. Their presence may therefore be useful in supporting a quick diagnosis, leading to the provision of appropriate care and counseling. Their presence may be especially relevant in a number of conditions, including Allgrove syndrome, where hypolacrimia or alacrimia precedes the occurrence of adrenal insufficiency; in *N*-glycanase deficiency, where other symptoms can mimic mitochondriopathy and lead to invasive tests; and in BBOAS, where the association with optic atrophy in the context of intellectual disability appears to be very specific.

This review highlights the need to widen the study of hypolacrimia or alacrimia in patients suffering from these conditions, including the clinical evaluation of lacrimation and, where possible, the study of the pathophysiological mechanisms involved. Tests involved could include the measurement of LG volume by MRI and the measurement of tear secretion by Schirmer's tests. Moreover, animal models exist for some of these pathologies. Lacrimal defect should be studied in these models to clarify the complex pathophysiology involved and to increase awareness of the hitherto disregarded ocular conditions of the above-mentioned pathologies.

## Acknowledgments

Disclosure: **M. Willems**, None; **C.F. Wells**, None; **C. Coubes**, None; **M. Pequignot**, None; **A. Kuony**, None; **F. Michon**, None

## References

1. Hansen JT. *Netter's Clinical Anatomy*. 4th ed. Philadelphia, PA: Elsevier; 2018:630.
2. Zieske J. Corneal development associated with eyelid opening. *Int J Dev Biol*. 2004;48:903–911.

3. Klenkler B, Sheardown H, Jones L. Growth factors in the tear film: role in tissue maintenance, wound healing, and ocular pathology. *Ocul Surf.* 2007;5(3):228–239.
4. Wang MTM, Craig JP. Natural history of dry eye disease: perspectives from inter-ethnic comparison studies. *Ocul Surf.* 2019;17(3):424–433.
5. Tsubota K, Pflugfelder SC, Liu Z, et al. Defining dry eye from a clinical perspective. *Int J Mol Sci.* 2020;21(23):E9271.
6. Kaido M, Matsumoto Y, Shigeno Y, Ishida R, Dogru M, Tsubota K. Corneal fluorescein staining correlates with visual function in dry eye patients. *Invest Ophthalmol Vis Sci.* 2011;52(13):9516–9522.
7. Iwanaga J, Watanabe K, Kusukawa J, et al. A novel treatment for keratitis sicca (dry eye): anatomical feasibility study. *Clin Anat.* 2017;30(6):839–843.
8. Takahashi Y, Watanabe A, Matsuda H, et al. Anatomy of secretory glands in the eyelid and conjunctiva: a photographic review. *Ophthalmic Plast Reconstr Surg.* 2013;29(3):215–219.
9. Paulsen FP, Berry MS. Mucins and TFF peptides of the tear film and lacrimal apparatus. *Prog Histochem Cytochem.* 2006;41(1):1–53.
10. Schechter JE, Warren DW, Mircheff AK. A lacrimal gland is a lacrimal gland, but rodent's and rabbit's are not human. *Ocul Surf.* 2010;8(3):111–134.
11. Makarenkova HP, Dartt DA. Myoepithelial cells: their origin and function in lacrimal gland morphogenesis, homeostasis, and repair. *Curr Mol Biol Rep.* 2015;1(3):115–123.
12. Öрге FH, Boente CS. The lacrimal system. *Pediatr Clin North Am.* 2014;61(3):529–539.
13. Mistry RK, Al Khalili Y. *Neuroanatomy, Infratrochlear Nerve.* Treasure Island, FL: StatPearls Publishing; 2022.
14. Schein OD, Hochberg MC, Muñoz B, et al. Dry eye and dry mouth in the elderly: a population-based assessment. *Arch Intern Med.* 1999;159(12):1359–1363.
15. Ahn JM, Lee SH, Rim THT, et al. Prevalence of and risk factors associated with dry eye: the Korea National Health and Nutrition Examination Survey 2010–2011. *Am J Ophthalmol.* 2014;158(6):1205–1214.e7.
16. Sjögren H, Eriksen A. Alacrimia congenita. *Br J Ophthalmol.* 1950;34(11):691–694.
17. Sánchez Sevilla JL, Rosas Gómez de Salazar J, Concepción Aramendía L, Vivó Devesa C. Congenital unilateral absence of the lacrimal gland combined with lipoma. A rare case of unilateral congenital alacrima. *Arch Soc Esp Ophthalmol (Engl Ed).* 2021;96(1):48–51.
18. Alwohaib M, Schellini SA, Elkhamary SM, Al Shaikh O. Isolated bilateral congenital lacrimal gland agenesis - report of two cases. *Saudi J Ophthalmol.* 2017;31(4):257–259.
19. Ryu YH, Kyun Chae J, Kim JW, Lee S. Lacrimo-auriculo-dento-digital syndrome: a novel mutation in a Korean family and review of literature. *Mol Genet Genomic Med.* 2020;8(10):e1412.
20. Wiedemann HR, Drescher J. LADD syndrome: report of new cases and review of the clinical spectrum. *Eur J Pediatr.* 1986;144(6):579–582.
21. Kapoor AG, Mishra D, Vs V, Ali MJ. Giant dacryocoele in a setting of bilateral congenital alacrimia with punctal and canalicular agenesis. *Ophthalmic Plast Reconstr Surg.* 2019;35(3):e88.
22. Gupta H, Kane S, Balasubramaniam V. Bilateral dacryocoeles associated with bilateral alacrimia with punctal and canalicular agenesis. *Saudi J Ophthalmol.* 2014;28(1):72–75.
23. Scheckenbach K, Balz V, Wagenmann M, Hoffmann TK. An intrinsic alteration of the fibroblast growth factor 10 gene causing ALSG-(aplasia of lacrimal and salivary glands) syndrome. *BMC Med Genet.* 2008;9:114.
24. Prochazkova M, Prochazka J, Marangoni P, Klein OD. Bones, glands, ears and more: the multiple roles of FGF10 in craniofacial development. *Front Genet.* 2018;9:542.
25. Makarenkova HP, Ito M, Govindarajan V, et al. FGF10 is an inducer and Pax6 a competence factor for lacrimal gland development. *Development.* 2000;127(12):2563–2572.
26. Mauduit O, Aure MH, Delcroix V, et al. A mesenchymal to epithelial switch in Fgf10 expression specifies an evolutionary-conserved population of ionocytes in salivary glands. *Cell Rep.* 2022;39(2):110663.
27. Shams I, Rohmann E, Eswarakumar VP, et al. Lacrimo-auriculo-dento-digital syndrome is caused by reduced activity of the fibroblast growth factor 10 (FGF10)-FGF receptor 2 signaling pathway. *Mol Cell Biol.* 2007;27(19):6903–6912.
28. Garg A, Bansal M, Gotoh N, et al. Alx4 relays sequential FGF signaling to induce lacrimal gland morphogenesis. *PLoS Genet.* 2017;13(10):e1007047.
29. Kariminejad A, Bozorgmehr B, Alizadeh H, et al. Skull defects, alopecia, hypertelorism, and notched alae nasi caused by homozygous *ALX4* gene mutation. *Am J Med Genet A.* 2014;164A(5):1322–1327.
30. Bertola DR, Rodrigues MG, Quaio CRDC, Kim CA, Passos-Bueno MR. Vertical transmission of a frontonasal phenotype caused by a novel *ALX4* mutation. *Am J Med Genet A.* 2013;161A(3):600–604.
31. Inoue K, Khajavi M, Ohyama T, et al. Molecular mechanism for distinct neurological phenotypes conveyed by allelic truncating mutations. *Nat Genet.* 2004;36(4):361–369.
32. Pingault V, Zerad L, Bertani-Torres W, Bondurand N. *SOX10*: 20 years of phenotypic plurality and current understanding of its developmental function. *J Med Genet.* 2022;59(2):105–114.
33. Touraine RL, Attié-Bitach T, Manceau E, et al. Neurological phenotype in Waardenburg syndrome type 4 correlates with novel *SOX10* truncating mutations and expression in developing brain. *Am J Hum Genet.* 2000;66(5):1496–1503.
34. Elmaleh-Bergès M, Baumann C, Noël-Pétrouff N, et al. Spectrum of temporal bone abnormalities in patients with Waardenburg syndrome and *SOX10* mutations. *AJNR Am J Neuroradiol.* 2013;34(6):1257–1263.
35. Inoue K, Ohyama T, Sakuragi Y, et al. Translation of *SOX10* 3' untranslated region causes a complex severe neurocristopathy by generation of a deleterious functional domain. *Hum Mol Genet.* 2007;16(24):3037–3046.
36. Schock EN, LaBonne C. Sorting Sox: diverse roles for Sox transcription factors during neural crest and craniofacial development. *Front Physiol.* 2020;11:606889.
37. Kamachi Y, Uchikawa M, Kondoh H. Pairing SOX off: with partners in the regulation of embryonic development. *Trends Genet.* 2000;16(4):182–187.
38. Pingault V, Guiochon-Mantel A, Bondurand N, et al. Peripheral neuropathy with hypomyelination, chronic intestinal pseudo-obstruction and deafness: a developmental “neural crest syndrome” related to a *SOX10* mutation. *Ann Neurol.* 2000;48(4):671–676.
39. Weider M, Wegner M. SoxE factors: transcriptional regulators of neural differentiation and nervous system development. *Semin Cell Dev Biol.* 2017;63:35–42.
40. Ito Y, Inoue N, Inoue YU, et al. Additive dominant effect of a *SOX10* mutation underlies a complex phenotype of PCWH. *Neurobiol Dis.* 2015;80:1–14.
41. Duarte AF, Akaishi PMS, de Molfetta GA, et al. Lacrimal gland involvement in blepharophimosis-ptosis-epicanthus inversus syndrome. *Ophthalmology.* 2017;124(3):399–406.

42. Crisponi L, Deiana M, Loi A, et al. The putative forkhead transcription factor *FOXL2* is mutated in blepharophimosis/ptosis/epicanthus inversus syndrome. *Nat Genet.* 2001;27(2):159–166.
43. Cocquet J, Pailhoux E, Jaubert F, et al. Evolution and expression of *FOXL2*. *J Med Genet.* 2002;39(12):916–921.
44. Verdin H, De Baere E. *FOXL2* impairment in human disease. *Horm Res Paediatr.* 2012;77(1):2–11.
45. Wright JT, Fete M, Schneider H, et al. Ectodermal dysplasias: classification and organization by phenotype, genotype and molecular pathway. *Am J Med Genet A.* 2019;179(3):442–447.
46. Dietz J, Kaercher T, Schneider AT, et al. Early respiratory and ocular involvement in X-linked hypohidrotic ectodermal dysplasia. *Eur J Pediatr.* 2013;172(8):1023–1031.
47. Kere J, Srivastava AK, Montonen O, et al. X-linked anhidrotic (hypohidrotic) ectodermal dysplasia is caused by mutation in a novel transmembrane protein. *Nat Genet.* 1996;13(4):409–416.
48. Sima J, Yan Z, Chen Y, et al. Eda-activated RelB recruits an SWI/SNF (BAF) chromatin-remodeling complex and initiates gene transcription in skin appendage formation. *Proc Natl Acad Sci USA.* 2018;115(32):8173–8178.
49. Grüneberg H. The tabby syndrome in the mouse. *Proc R Soc Lond B Biol Sci.* 1971;179(1055):139–156.
50. Kuony A, Ikkala K, Kalha S, Magalhães AC, Pirttiniemi A, Michon F. Ectodysplasin-A signaling is a key integrator in the lacrimal gland-cornea feedback loop. *Development.* 2019;146(14):dev176693.
51. Casal ML, Lewis JR, Mauldin EA, et al. Significant correction of disease after postnatal administration of recombinant ectodysplasin A in canine X-linked ectodermal dysplasia. *Am J Hum Genet.* 2007;81(5):1050–1056.
52. Schneider H, Faschingbauer F, Schuepbach-Mallepell S, et al. Prenatal correction of X-linked hypohidrotic ectodermal dysplasia. *N Engl J Med.* 2018;378(17):1604–1610.
53. Sutton VR, van Bokhoven H. *TP63*-related disorders. In: Adam MP, Ardinger HH, Pagon RA, et al., eds. *GeneReviews [Internet]*. Seattle, WA: University of Washington; 1993.
54. Di Iorio E, Kaye SB, Ponzin D, et al. Limbal stem cell deficiency and ocular phenotype in ectrodactyly-ectodermal dysplasia-clefting syndrome caused by p63 mutations. *Ophthalmology.* 2012;119(1):74–83.
55. Botchkarev VA, Flores ER. p53/p63/p73 in the epidermis in health and disease. *Cold Spring Harb Perspect Med.* 2014;4(8):a015248.
56. Ferretti E, Li B, Zewdu R, et al. A conserved Pbx-Wnt-p63-Irf6 regulatory module controls face morphogenesis by promoting epithelial apoptosis. *Dev Cell.* 2011;21(4):627–641.
57. Takebe N, Miele L, Harris PJ, et al. Targeting Notch, Hedgehog, and Wnt pathways in cancer stem cells: clinical update. *Nat Rev Clin Oncol.* 2015;12(8):445–464.
58. Wu J, Bergholz J, Lu J, Sonenshein GE, Xiao ZXJ. TAp63 is a transcriptional target of NF- $\kappa$ B. *J Cell Biochem.* 2010;109(4):702–710.
59. Matheny KE, Barbieri CE, Sniezek JC, Arteaga CL, Pietenpol JA. Inhibition of epidermal growth factor receptor signaling decreases p63 expression in head and neck squamous carcinoma cells. *Laryngoscope.* 2003;113(6):936–939.
60. Roemer K. Notch and the p53 clan of transcription factors. *Adv Exp Med Biol.* 2012;727:223–240.
61. Sharafian S, Tavakol M, Gharagozlou M, Parvaneh N. Delay in diagnosis of two siblings with severe ocular problems and autoimmune polyglandular syndrome. *Iran J Allergy Asthma Immunol.* 2020;19(3):313–317.
62. Couturier A, Brézin AP. Ocular manifestations of autoimmune polyendocrinopathy syndrome type 1. *Curr Opin Ophthalmol.* 2016;27(6):505–513.
63. Finnish-German APECED Consortium. An autoimmune disease, APECED, caused by mutations in a novel gene featuring two PHD-type zinc-finger domains. *Nat Genet.* 1997;17(4):399–403.
64. Chen FY, Lee A, Ge S, Nathan S, Knox SM, McNamara NA. Aire-deficient mice provide a model of corneal and lacrimal gland neuropathy in Sjögren's syndrome. *PLoS One.* 2017;12(9):e0184916.
65. Besnard M, Padonou F, Provin N, Giraud M, Guillonnet C. AIRE deficiency, from preclinical models to human APECED disease. *Dis Model Mech.* 2021;14(2):dmm046359.
66. Handschug K, Sperling S, Yoon SJ, Hennig S, Clark AJ, Huebner A. Triple A syndrome is caused by mutations in *AAAS*, a new WD-repeat protein gene. *Hum Mol Genet.* 2001;10(3):283–290.
67. Babu K, Murthy KR, Babu N, Ramesh S. Triple A syndrome with ophthalmic manifestations in two siblings. *Indian J Ophthalmol.* 2007;55(4):304–306.
68. Mullaney PB, Weatherhead R, Millar L, et al. Keratoconjunctivitis sicca associated with achalasia of the cardia, adrenocortical insufficiency, and lacrimal gland degeneration: keratoconjunctivitis sicca secondary to lacrimal gland degeneration may parallel degenerative changes in esophageal and adrenocortical function. *Ophthalmology.* 1998;105(4):643–650.
69. Aragona P, Rania L, Roszkowska AM, et al. 4A syndrome: ocular surface investigation in an Italian young patient. *BMC Ophthalmol.* 2014;14:155.
70. Botella García J, Lázaro-Rodríguez V, de la Paz MF. The use of topical cyclosporine A 0.05% as treatment for primary alacrimia in Allgrove syndrome. *Eur J Ophthalmol.* 2022;32(1):NP9–NP11.
71. Bitetto G, Ronchi D, Bonato S, et al. Loss of the nucleoporin Aladin in central nervous system and fibroblasts of Allgrove syndrome. *Hum Mol Genet.* 2019;28(23):3921–3927.
72. Koehler K, Malik M, Mahmood S, et al. Mutations in *GMPPA* cause a glycosylation disorder characterized by intellectual disability and autonomic dysfunction. *Am J Hum Genet.* 2013;93(4):727–734.
73. Raphael AR, Couthouis J, Sakamuri S, et al. Congenital muscular dystrophy and generalized epilepsy caused by *GMPPB* mutations. *Brain Res.* 2014;1575:66–71.
74. Gioia M, Fasciglione GF, Sbardella D, et al. The enzymatic processing of  $\alpha$ -dystroglycan by MMP-2 is controlled by two anchoring sites distinct from the active site. *PLoS One.* 2018;13(2):e0192651.
75. Franzka P, Henze H, Jung MJ, et al. *GMPPA* defects cause a neuromuscular disorder with  $\alpha$ -dystroglycan hyperglycosylation. *J Clin Invest.* 2021;131(9):139076.
76. Marom D, Albin A, Schwartz C, et al. X-linked mental retardation with alacrima and achalasia–Triple A syndrome or a new syndrome? *Am J Med Genet A.* 2011;155A(8):1959–1963.
77. Bar-Aluma BE. Familial dysautonomia. In: Adam MP, Ardinger HH, Pagon RA, et al., eds. *GeneReviews [Internet]*. Seattle, WA: University of Washington; 1993.
78. Anderson SL, Coli R, Daly IW, et al. Familial dysautonomia is caused by mutations of the *IKAP* gene. *Am J Hum Genet.* 2001;68(3):753–758.
79. Mezey E, Parmalee A, Szalayova I, et al. Of splice and men: what does the distribution of *IKAP* mRNA in the rat tell us about the pathogenesis of familial dysautonomia? *Brain Res.* 2003;983(1–2):209–214.

80. Morini E, Dietrich P, Salani M, et al. Sensory and autonomic deficits in a new humanized mouse model of familial dysautonomia. *Hum Mol Genet.* 2016;25(6):1116–1128.
81. Edvardson S, Cinnamon Y, J alas C, et al. Hereditary sensory autonomic neuropathy caused by a mutation in dystonin. *Ann Neurol.* 2012;71(4):569–572.
82. Manganelli F, Parisi S, Nolano M, et al. Novel mutations in dystonin provide clues to the pathomechanisms of HSAN-VI. *Neurology.* 2017;88(22):2132–2140.
83. Cappuccio G, Pinelli M, Torella A, et al. Expanding the phenotype of DST-related disorder: a case report suggesting a genotype/phenotype correlation. *Am J Med Genet A.* 2017;173(10):2743–2746.
84. Fortugno P, Angelucci F, Cestra G, et al. Recessive mutations in the neuronal isoforms of DST, encoding dystonin, lead to abnormal actin cytoskeleton organization and HSAN type VI. *Hum Mutat.* 2019;40(1):106–114.
85. Jin JY, Wu PF, He JQ, et al. Novel compound heterozygous DST variants causing hereditary sensory and autonomic neuropathies VI in twins of a Chinese family. *Front Genet.* 2020;11:492.
86. Horie M, Yoshioka N, Takebayashi H. BPAG1 in muscles: structure and function in skeletal, cardiac and smooth muscle. *Semin Cell Dev Biol.* 2017;69:26–33.
87. Khalesi R, Harvey N, Garshasbi M, et al. Pathogenic DST sequence variants result in either epidermolysis bullosa simplex (EBS) or hereditary sensory and autonomic neuropathy type 6 (HSAN-VI). *Exp Dermatol.* 2022;31(6):949–955.
88. Lynch-Godrei A, Kothary R. HSAN-VI: a spectrum disorder based on dystonin isoform expression. *Neurol Genet.* 2020;6(1):e389.
89. Yoshioka N, Kabata Y, Kuriyama M, et al. Diverse dystonin gene mutations cause distinct patterns of Dst isoform deficiency and phenotypic heterogeneity in *Dystonia musculorum* mice. *Dis Model Mech.* 2020;13(5):dmm041608.
90. Lynch-Godrei A, Repentigny YD, Ferrier A, Gagnon S, Kothary R. Dystonin loss-of-function leads to impaired autophagosome-endolysosome pathway dynamics. *Biochem Cell Biol.* 2021;99(3):364–373.
91. Spring PJ, Ing AJ, Nicholson GA, et al. Autosomal dominant hereditary sensory neuropathy with gastro-oesophageal reflux and cough: clinical features of a family. *J Neurol Sci.* 2002;199(suppl.):S64.
92. Spring PJ, Kok C, Nicholson GA, et al. Autosomal dominant hereditary sensory neuropathy with chronic cough and gastro-oesophageal reflux: clinical features in two families linked to chromosome 3p22-p24. *Brain J Neurol.* 2005;128(pt 12):2797–2810.
93. Kok C, Kennerson ML, Spring PJ, Ing AJ, Pollard JD, Nicholson GA. A locus for hereditary sensory neuropathy with cough and gastroesophageal reflux on chromosome 3p22-p24. *Am J Hum Genet.* 2003;73(3):632–637.
94. Mehta A, Hughes DA. Fabry disease. In: Adam MP, Ardinger HH, Pagon RA, et al., eds. *GeneReviews [Internet]*. Seattle, WA: University of Washington; 1993.
95. Kok K, Zwiers KC, Boot RG, Overkleeft HS, Aerts JMFG, Artola M. Fabry disease: molecular basis, pathophysiology, diagnostics and potential therapeutic directions. *Biomolecules.* 2021;11(2):271.
96. Sivley MD, Wallace EL, Warnock DG, Benjamin WJ. Conjunctival lymphangiectasia associated with classic Fabry disease. *Br J Ophthalmol.* 2018;102(1):54–58.
97. Hoischen A, van Bon BWM, Gilissen C, et al. *De novo* mutations of *SETBP1* cause Schinzel–Giedion syndrome. *Nat Genet.* 2010;42(6):483–485.
98. Minn D, Christmann D, De Saint-Martin A, et al. Further clinical and sensorial delineation of Schinzel–Giedion syndrome: report of two cases. *Am J Med Genet.* 2002;109(3):211–217.
99. Piazza R, Magistroni V, Redaelli S, et al. SETBP1 induces transcription of a network of development genes by acting as an epigenetic hub. *Nat Commun.* 2018;9(1):2192.
100. Enns GM, Shashi V, Bainbridge M, et al. Mutations in *NGLY1* cause an inherited disorder of the endoplasmic reticulum-associated degradation pathway. *Genet Med.* 2014;16(10):751–758.
101. Asahina M, Fujinawa R, Nakamura S, Yokoyama K, Tozawa R, Suzuki T. *Ngly1*<sup>-/-</sup> rats develop neurodegenerative phenotypes and pathological abnormalities in their peripheral and central nervous systems. *Hum Mol Genet.* 2020;29(10):1635–1647.
102. Tambe MA, Ng BG, Freeze HH. N-glycanase 1 transcriptionally regulates aquaporins independent of its enzymatic activity. *Cell Rep.* 2019;29(13):4620–4631.e4.
103. Delporte C. Aquaporins and gland secretion. *Adv Exp Med Biol.* 2017;969:63–79.
104. Liu Y, Di G, Hu S, et al. Expression profiles of circRNA and mRNA in lacrimal glands of AQP5<sup>-/-</sup> mice with primary dry eye. *Front Physiol.* 2020;11:1010.
105. Bosch DGM, Boonstra FN, Gonzaga-Jauregui C, et al. *NR2F1* mutations cause optic atrophy with intellectual disability. *Am J Hum Genet.* 2014;94(2):303–309.
106. Rech ME, McCarthy JM, Chen CA, et al. Phenotypic expansion of Bosch–Boonstra–Schaaf optic atrophy syndrome and further evidence for genotype–phenotype correlations. *Am J Med Genet A.* 2020;182(6):1426–1437.
107. Jurkute N, Bertacchi M, Arno G, et al. Pathogenic *NR2F1* variants cause a developmental ocular phenotype recapitulated in a mutant mouse model. *Brain Commun.* 2021;3(3):fcab162.
108. Martín-Hernández E, Rodríguez-García ME, Chen CA, et al. Mitochondrial involvement in a Bosch–Boonstra–Schaaf optic atrophy syndrome patient with a novel *de novo NR2F1* gene mutation. *J Hum Genet.* 2018;63(4):525–528.
109. Bögershausen N, Shahrzad N, Chong JX, et al. Recessive *TRAPPC11* mutations cause a disease spectrum of limb girdle muscular dystrophy and myopathy with movement disorder and intellectual disability. *Am J Hum Genet.* 2013;93(1):181–190.
110. Koehler K, Milev MP, Prematilake K, et al. A novel *TRAPPC11* mutation in two Turkish families associated with cerebral atrophy, global retardation, scoliosis, achalasia and alacrima. *J Med Genet.* 2017;54(3):176–185.
111. Hegab SM, al-Mutawa SA. Congenital hereditary autosomal recessive alacrima. *Ophthalmic Genet.* 1996;17(1):35–38.
112. Hegab SM, Sheriff SM, el-Aasar ES, Lashin EA, Phillips CI. Congenital alacrima without associated manifestations (AD). An affected father and son. *Ophthalmic Paediatr Genet.* 1991;12(4):161–163.
113. Mondino BJ, Brown SI. Hereditary congenital alacrima. *Arch Ophthalmol.* 1976;94(9):1478–1484.