

Case Report

Open Access

Hepatitis following famotidine: a case report

Nishant Gupta*, Chirag Patel and Mukta Panda

Address: Department of Internal Medicine, University of Tennessee, College of Medicine, Chattanooga, TN 37403, USA

Email: Nishant Gupta* - ngupta19@aol.com; Chirag Patel - dr.chiragpatel@hotmail.com; Mukta Panda - mukta.panda@erlangier.org

* Corresponding author

Published: 27 January 2009

Received: 24 November 2008

Cases Journal 2009, 2:89 doi:10.1186/1757-1626-2-89

Accepted: 27 January 2009

This article is available from: <http://www.casesjournal.com/content/2/1/89>

© 2009 Gupta et al; licensee BioMed Central Ltd.

This is an Open Access article distributed under the terms of the Creative Commons Attribution License (<http://creativecommons.org/licenses/by/2.0>), which permits unrestricted use, distribution, and reproduction in any medium, provided the original work is properly cited.

Abstract

H₂ receptor antagonists can rarely cause idiosyncratic drug reactions leading to acute hepatitis. Famotidine, however, is considered a relatively safe drug with regards to hepatotoxicity. We report a case of a 47 year old male with a history of hepatitis C who developed acute hepatitis on the third day of hospitalization with a dramatic rise in his liver enzymes from normal values at the time of admission. The acute rise in liver enzymes made us consider an adverse drug reaction and famotidine was discontinued. Subsequently his liver enzymes came back to normal in seven days. Thus, physicians should consider famotidine induced hepatitis as a possible etiology of acute liver dysfunction.

Introduction

Drug-induced hepatic injury is a very common cause of hepatitis in adults. Drug hepatotoxicity is the most common cause of fulminant liver failure in the United States [1]. Hepatotoxicity can occur with many drugs through a variety of mechanisms and can present with an array of clinical presentations ranging from asymptomatic mild biochemical abnormalities to an acute illness that resembles viral hepatitis [2,3]. A variety of drugs like acetaminophen, isoniazid, sulfonamides, methotrexate, methyl dopa etc. are well known to cause liver damage.

Current H₂ receptor antagonists have been very rarely associated with idiosyncratic drug reactions leading to liver failure. In the past, two H₂ receptor antagonists have been withdrawn because of high risk of liver toxicity [4,5]. However liver toxicity has never been shown to be a class effect of H₂ receptor antagonists [6]. Cimetidine and Ranitidine can produce rare idiosyncratic hepatotoxic reactions [6]. Famotidine, however, is considered to be a relatively safe drug with regards to hepatotoxicity [7]. We report a case of acute hepatic failure secondary to the use

of famotidine. To our knowledge, there have only been 4 cases in the English literature where famotidine was responsible for hepatotoxicity [8-10].

Case presentation

A 47 year old male with a past history of asymptomatic chronic Hepatitis C diagnosed 4 years ago, on no home medications, came to the hospital with chief complaints of right upper quadrant abdominal pain and vomiting for one day. His vital signs on admission were stable. On physical examination the abdomen was tender to palpation in right upper quadrant with no palpable organomegaly. He had no stigmata of end stage liver disease. Laboratory data at the time of admission showed WBC 14.5 th/mm³ (normal 4 – 11 th/mm³), Hemoglobin 16 g/dl (normal 14 – 18 gm/dl), Platelets 190 th/mm³ (normal 130 – 400 th/mm³), Total bilirubin 0.7 mg/dl (normal 0.0 – 1 mg/dl), INR 1.4, total protein 5.3 gm/dl (normal 6.3 – 8.2 gm/dl), Albumin 2.6 gm/dl (normal 3.4 – 5 gm/dl), AST 28 U/l (normal 15 – 37 U/l), ALT 52 U/l (normal 30 – 65 U/l), Alkaline phosphatase 99 U/l (normal 50 – 136 U/l) and a Lipase level of 174 U/l (normal 114 – 286 U/l).

l). An ultrasound of the abdomen done at the time of admission showed a stone in the gall bladder neck with pericholecystic fluid consistent with our clinical diagnosis of acute cholecystitis. The patient was admitted to the hospital, started on Morphine, Cefoxitin and Famotidine and subsequently underwent laparoscopic cholecystectomy the next day. Fentanyl, propofol and vecuronium were used for anesthesia. His hospital course was uneventful until the third day when he started complaining of some abdominal pain with a change in urine color. A complete metabolic panel was obtained on the patient at this time which now showed AST 8466 U/l, ALT 4755 U/l, Total bilirubin 2.5 mg/dl, INR 2.4 with a normal alkaline phosphatase. The sudden elevation in liver enzymes within a couple of days of hospitalization made us think of a possible medication induced adverse reaction. The patient's medications at that time were cefoxitin, morphine and famotidine. Famotidine was discontinued at this time and serial measurements of liver enzymes were done. The liver enzymes started improving from the next day and were back to normal within the next 7 days. (Figure 1) No further investigations were done on the patient as the temporal association of the administration of famotidine and elevation in liver enzymes combined with the response demonstrated after discontinuation of famotidine was very significant in this case.

Discussion

H2 receptor antagonists are widely used for the treatment of peptic ulcer and gastroesophageal reflux disease. In addition they are commonly prescribed to hospitalized patients for stress ulcer prevention. In general they are very well tolerated drugs and have very few side effects. They can rarely cause adverse hepatic effects which are mostly asymptomatic [11]. While there has been some data regarding possible idiosyncratic reactions to cimetidine and ranitidine leading to acute liver failure, no such

association has been reported to date with famotidine. In a case-control study done by Garcia et al [6], rare adverse hepatic reactions were seen with the use of ranitidine, cimetidine and omeprazole but not with famotidine. Studies done by Ohnishi [7] and Luyendyk et al [12] have also shown famotidine to be safe with regards to hepatotoxicity.

To our knowledge there have been four cases reported where famotidine was responsible for hepatic failure [8-10]. In the above mentioned four cases, hepatitis was noted after a few weeks of famotidine. Our case is unique in that the adverse reaction was noted within 36 hours after the administration of famotidine.

There have been various studies which have looked at the pharmacokinetics of famotidine following administration to patients with concomitant liver disease including decompensated cirrhosis [7,13,14]. Most of these studies conclude that famotidine clearance is not altered with impairment of hepatic function. However, one study done by Ohnishi et al [15] showed that famotidine clearance was reduced in decompensated cirrhosis. However, that study also showed that famotidine clearance was affected by renal function. Our patient in addition to being Hepatitis C positive had also developed acute kidney injury at the same time with a serum creatinine rising from 0.8 mg/dl to 2.2 mg/dl (GFR 34 ml/min). His creatinine also returned to baseline of 1 mg/dl at 5 days. The exact significance of this impaired renal function on the development of acute hepatitis is unknown at this time but it could potentially have resulted in a decreased clearance of the drug and thus predisposing him to this adverse reaction. Although just a solitary incidence, it might suggest the need for a larger trial looking at the pharmacokinetics of famotidine in patients with combined renal and hepatic dysfunction.

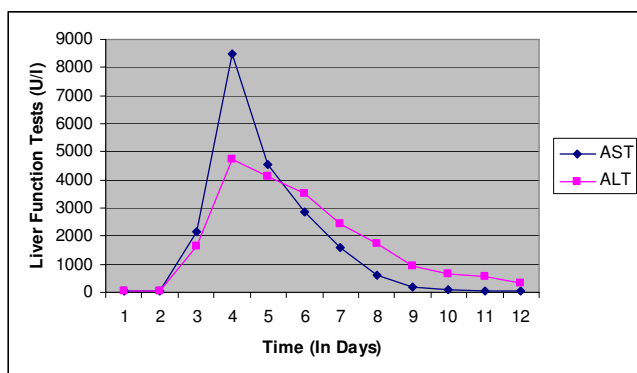


Figure 1
Graph showing the trend of Liver Function tests in our patient. Famotidine was stopped on day 4.

In conclusion, as famotidine is a commonly used medication both for treatment and prophylaxis, physicians need to be aware of the possibility of this severe idiosyncratic reaction leading to development of acute hepatitis following administration of famotidine especially in patients with hepatic or renal dysfunction and should promptly discontinue the drug if famotidine induced liver toxicity is suspected.

Consent

Written informed consent was obtained from the patient for publication of this case report and accompanying images. A copy of the written consent is available for review by the Editor-in-Chief of this journal.

Competing interests

The authors declare that they have no competing interests.

Authors' contributions

NG analyzed the patient data and wrote the manuscript, CP helped in analysis and interpretation of patient data and MP had a major contribution in writing the final manuscript. All authors have read and approved the final manuscript.

References

- Ostapowicz G, Fontana RJ, Schiødt FV, Larson A, Davern TJ, Han SH, McCashland TM, Shakil AO, Hay JE, Hyman L, Crippin JS, Blei AT, Samuel G, Reisch J, Lee WM, U.S. Acute Liver Failure Study Group: **Results of a prospective study of acute liver failure at 17 tertiary care centers in the United States.** *Ann Intern Med* 2002, **137**:947.
- Bissell DM, Gores GJ, Laskin DL, Hoofnagle JH: **Drug-induced liver injury: mechanisms and test systems.** *Hepatology* 2001, **33**:1009.
- Chitturi S, George J: **Hepatotoxicity of commonly used drugs: nonsteroidal anti-inflammatory drugs, antihypertensives, antidiabetic agents, anticonvulsants, lipid-lowering agents, psychotropic drugs.** *Semin Liver Dis* 2002, **22**:169.
- Andrade RJ, Lucena MI, Martin-Vivaldi R, Fernandez MC, Nogueras F, Pelaez G, Gomez-Outes A, Garcia-Escano MD, Bellot V, Hervás A, Cárdenas F, Bermudez F, Romero M, Salmerón J: **Acute liver injury associated with the use of ebrotidine, a new H2-receptor antagonist.** *J Hepatol* 1999, **31**(4):641-6.
- Gasbarrini G, Gentiloni N, Febbraro S, Gasbarrini A, Di Campli C, Cesana M, Miglio F, Miglioli M, Ghinelli F, D'Ambrosi A, Amoroso P, Pacini F, Salvadori G: **Acute liver injury related to the use of niperotidine.** *J Hepatol* 1997, **27**(3):583-6.
- García Rodríguez LA, Wallander MA, Stricker BH: **The risk of acute liver injury associated with cimetidine and other acid-suppressing anti-ulcer drugs.** *Br J Clin Pharmacol* 1997, **43**(2):183-8.
- Ohnishi K: **Effects of hepatic disease on the pharmacokinetics of famotidine and effects of famotidine on hepatic hemodynamics and peptic ulcer.** *Hepatogastroenterology* 1990, **37**(Suppl 1):6-10.
- Jiménez-Sáenz M, Argüelles-Arias F, Herrerías-Gutiérrez JM, Durán-Quintana JA: **Acute cholestatic hepatitis in a child treated with famotidine.** *Am J Gastroenterol* 2000, **95**(12):3665-6.
- Hashimoto F, Davis RL, Egli D: **Hepatitis following treatments with famotidine and then cimetidine.** *Ann Pharmacother* 1994, **28**(1):37-9.
- Sohn JH, Sohn YW, Jeon YC, Han DS, Hahn JS, Choi HS, Park KN, Kee CS: **Three cases of hepatitis related to the use of Famotidine and Ranitidine.** *Korean J Hepatol* 1998, **4**(2):194-199.
- Lipsy RJ, Fennerty B, Fagan TC: **Clinical review of histamine2 receptor antagonists.** *Arch Intern Med* 1990, **150**(4):745-51.
- Luyendyk JP, Lehman-McKeeman LD, Nelson DM, Bhaskaran VM, Reilly TP, Car BD, Cantor GH, Deng X, Maddox JF, Ganey PE, Roth RA: **Coagulation-dependent gene expression and liver injury in rats given lipopolysaccharide with ranitidine but not with famotidine.** *J Pharmacol Exp Ther* 2006, **317**(2):635-43.
- Vinçon G, Baldit C, Couzigou P, Demotes-Mainard F, Elouaer-Blanc L, Bannwarth B, Begaud B: **Pharmacokinetics of famotidine in patients with cirrhosis and ascites.** *Eur J Clin Pharmacol* 1992, **43**(5):559-62.
- Morgan MY, Stambuk D, Cottrell J, Mann SG: **Pharmacokinetics of famotidine in normal subjects and in patients with chronic liver disease.** *Aliment Pharmacol Ther* 1990, **4**(1):83-96.
- Ohnishi K: **Pharmacokinetics of famotidine after intravenous administration in liver disease.** *Am J Gastroenterol* 1991, **86**(1):41-5.

Publish with **BioMed Central** and every scientist can read your work free of charge

"BioMed Central will be the most significant development for disseminating the results of biomedical research in our lifetime."

Sir Paul Nurse, Cancer Research UK

Your research papers will be:

- available free of charge to the entire biomedical community
- peer reviewed and published immediately upon acceptance
- cited in PubMed and archived on PubMed Central
- yours — you keep the copyright

Submit your manuscript here:
http://www.biomedcentral.com/info/publishing_adv.asp

