

2-Chlorodeoxyadenosine treatment for cutaneous T-cell lymphoma

Małgorzata Sokołowska-Wojdyło,
Magdalena Trzeciak, Jadwiga Roszkiewicz
Department of Dermatology,
Venereology and Allergology, Medical
University of Gdańsk, Gdańsk, Poland

Abstract

The primary cutaneous lymphomas are often indolent but difficult to treat. In the early stages psoralen and ultraviolet-A therapy is the standard treatment whereas at the tumor stage chemotherapy (e.g. pegylated doxorubicin) is often used for debulking. The purine analog 2-chlorodeoxyadenosine (2CdA) acts in non-Hodgkin's lymphoma and has been used in our center for the treatment of advanced primary cutaneous T-cell lymphomas (CTCL). Here, we report on the efficacy and side effects of 2CdA in six patients with CTCL. One patient died owing to myelosuppression. Partial responses were seen in four cases but full remission was observed in only one case. We concluded that 2CdA has a limited usefulness in the management of advanced CTCL.

Introduction

A purine analog 2-chlorodeoxyadenosine (2CdA) has been accepted as the treatment of

choice in hairy cell leukemia and low-grade non-Hodgkin's lymphomas. It has also been recommended in stage IV A/B of cutaneous T-cell lymphomas (CTCL), along with chlorambucil, liposomal doxorubicin, CHOP polychemotherapy, denileukin difitox, and others.¹⁻¹¹ The aim of our study was to analyze the efficacy and side effects of 2CdA treatment for CTCL.

Materials and Methods

We treated six CTCL patients (five with *mycosis fungoides*; four in stage IIB, one in IVB, and one with peripheral cutaneous T-cell lymphoma (PTCL), unspecified) with 2CdA (pulses of 0.12 mg/kg/day/5 days).^{10,12,20} The patients failed standard therapies including glucocorticoids, retinoids, methotrexate, radiotherapy, and phototherapy. The efficacy of the treatment was established based on the clinical evaluation of skin lesions and internal involvement.

Results

The patients received 1-8 pulses of 2CdA (Table 1, Figures 1-4). One patient achieved total remission (patient 46/F, Figure 2A and B), lasting six months. Partial remission was achieved in four cases. Progression of the disease during treatment appeared in one case (patient 71/F, Figure 4). One patient died because of myelosuppression and staphylococcal sepsis just after the second pulse with 2CdA (patient 43/F, Figure 1). We tried to avoid the

Correspondence: Jadwiga Roszkiewicz, Department of Dermatology, Venereology and Allergology, Medical University of Gdańsk, 7th Debinki Street, 80-211 Gdańsk, Poland.
E-mail: mwojd@amg.gda.pl

Key words: 2-chlorodeoxyadenosine (2CdA), cutaneous T-cell lymphoma, mycosis fungoides, Sézary syndrome, treatment, side effect.

Received for publication: 17 February 2010.
Revision received: 16 April 2010.
Accepted for publication: 26 July 2010.

This work is licensed under a Creative Commons Attribution 3.0 License (by-nc 3.0).

©Copyright M. Sokołowska-Wojdyło et al., 2010
Licensee PAGEPress, Italy
Dermatology Reports 2010; 2:e12
doi:10.4081/dr.2010.e12

Table 1. Characteristics of the patients.

Age/Gender	Diagnosis and stage ¹	Duration of the disease	Previous treatment
43/F (Fig. 1)	MF IIB	13 mth	Prednison, PUVA, RePUVA cyclofosphamid
46/F (Fig. 2A, B)	MF IVB	31 mth	PUVA
46/F	PTCL	6 mth	Acitretin
65/F (Fig. 3A, B)	MF IIB	6 mth	acitretin, acitretin + MTX
58/M	MF IIB	16 mth	Acitretin, MTX, local electron beam therapy (Department of Radiotherapy)
71/F (Fig. 4A, B)	MF IIB	4 yr	Prednison, MTX, UVB311, acitretin, bexaroten (severe side effects: total skin peeling, bullae, and progression of the disease to MF IV)

MF, *mycosis fungoides*; PTCL, primary cutaneous peripheral T-cell lymphoma.

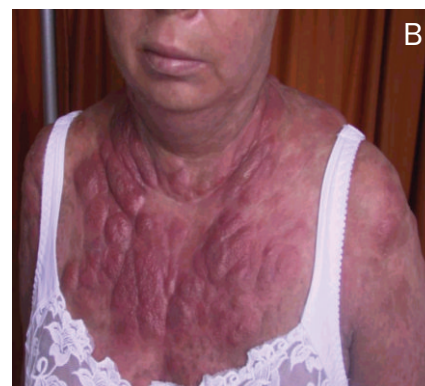
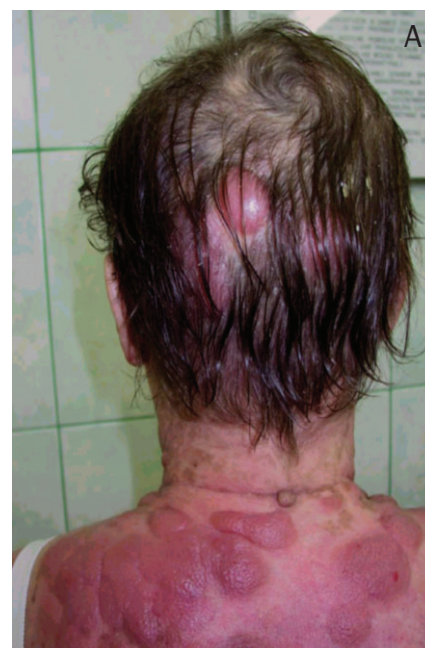
Figure 1. (A and B) Before 2CdA treatment: patient died of *S. aureus* sepsis after the second pulse.

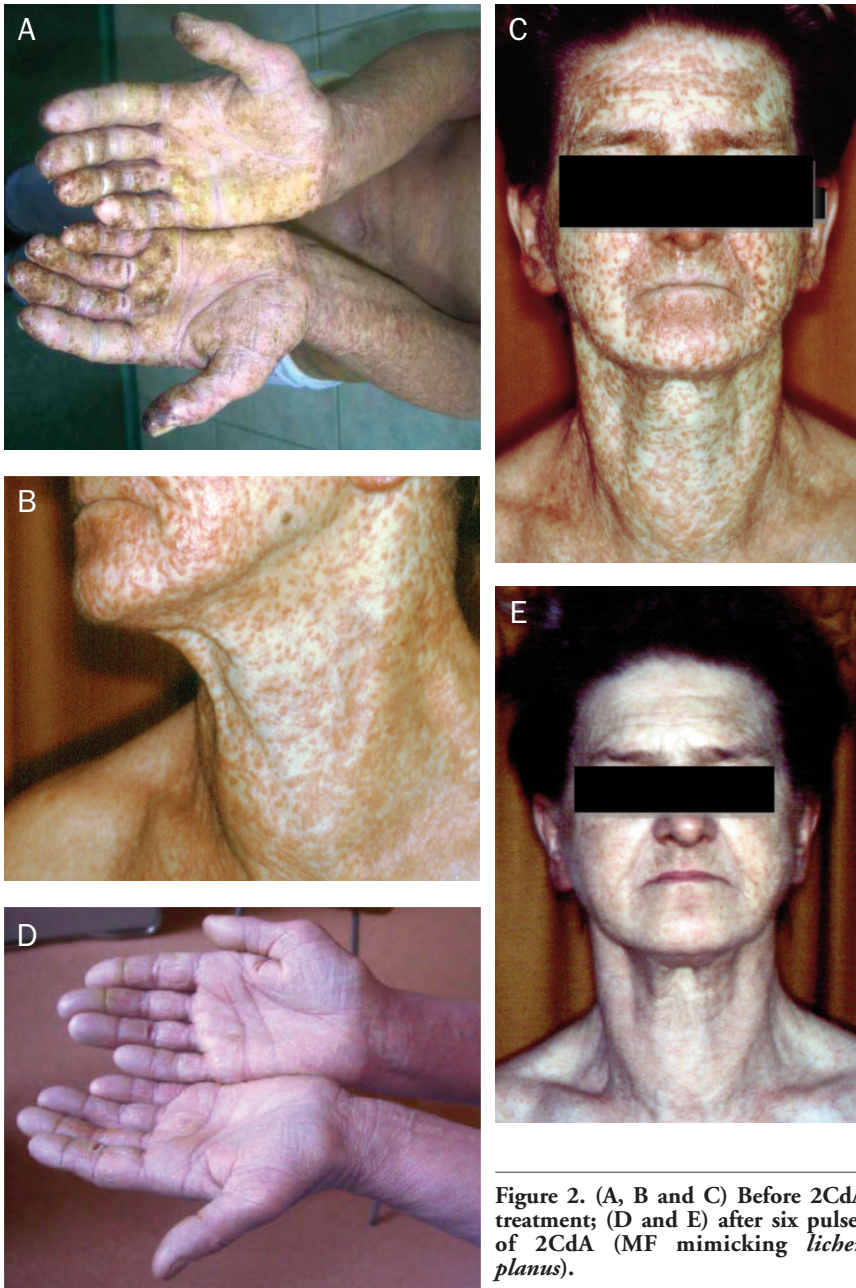


Figure 2. (A, B and C) Before 2CdA treatment; (D and E) after six pulses of 2CdA (MF mimicking *lichen planus*).

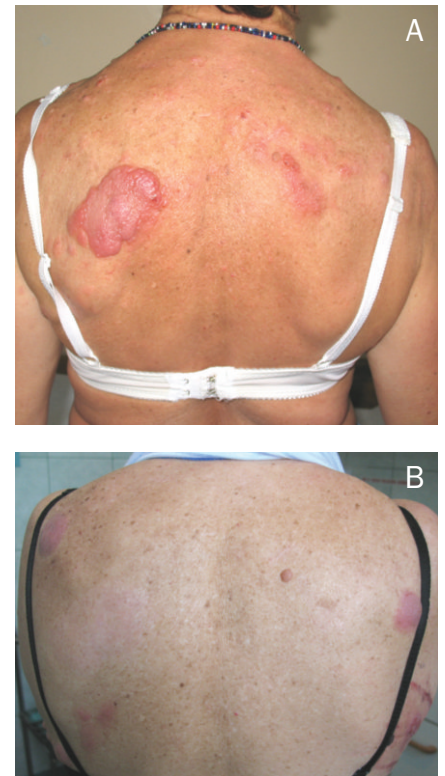


Figure 3. (A) Patient 65/F before 2CdA treatment; and (B) after treatment (remission but new tumors have appeared).

Table 2. Response to 2-chlorodeoxyadenosine.

Patient	No of cycles/dose per cycle (1 cycle = 5 d)	Duration of the cutaneous response	Lymph node status (response)	Outcome
43/K (Fig. 1)	2/0.12 mg/kg (7 mg/d)	No response	Slight	Death because of <i>S. aureus</i> sepsis
46/K (Fig. 2A-E)	8/0.12 mg/kg (7 mg/d)	6 month	Total	Death because of dissemination of MF (6 mth after end of 2CdA)
46/K	3/0.12 mg/kg (8 mg/d)	6 month	Total	Death, metastasis of lymphoma to central nervous system
65/K (Fig. 3A, B)	6/0.12 mg/kg (7 mg/d)	2 weeks	Moderate	Progressive disease
58/M	6/0.12 mg/kg (13 mg/d)	8 month	Not applicable	Progressive disease
71/K (Fig. 4A, B)	1/0.12 mg/kg (7 mg/d)	Progressive disease	Not applicable	Progressive disease

Response: slight, <25%; moderate, 25-50%; significant, 50-75%; total, 100%; PTCL, primary cutaneous peripheral T-cell lymphoma.

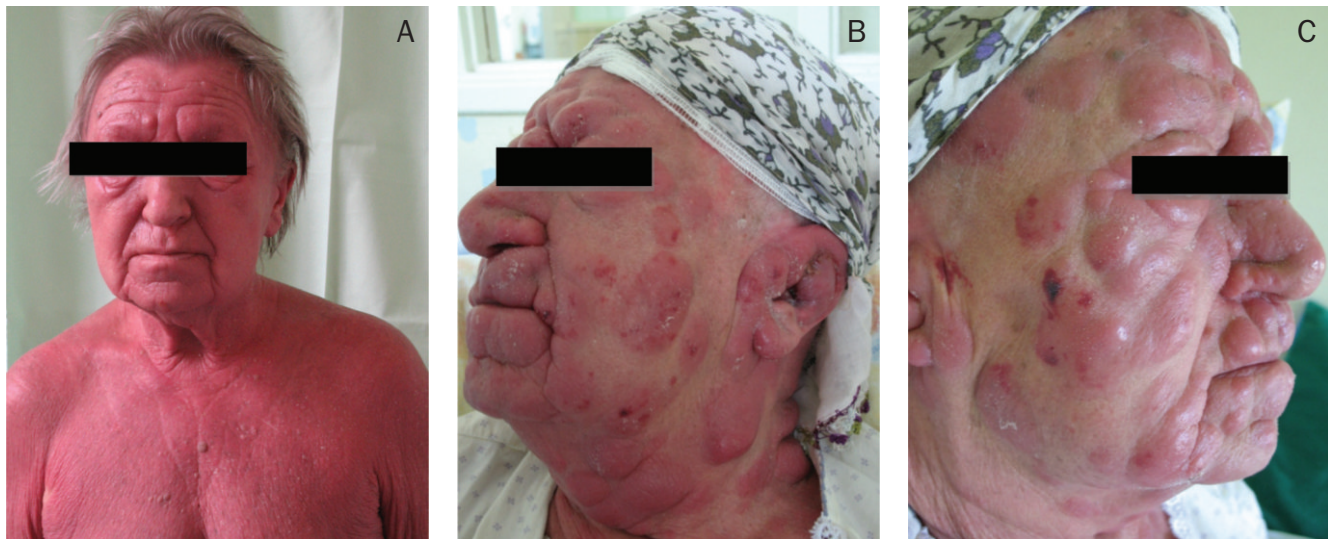

Figure 4. (A) Patient 71/F before 2CdA treatment; and (B, C and D) after one pulse of 2CdA treatment: rapid progression just after the treatment showing *faces leonona*. This was followed by seven pulses of CHOP with only 7-10 days' lasting remission, then by TSEB.

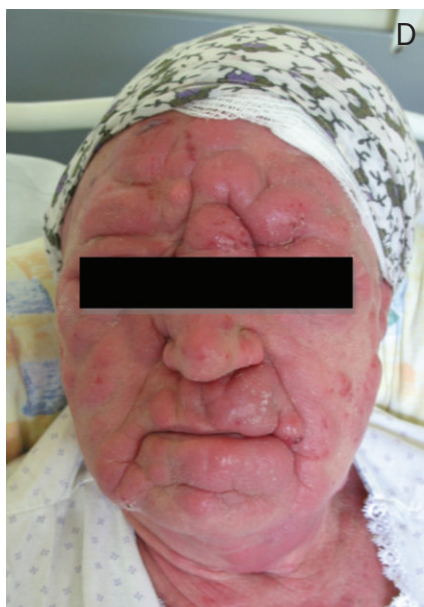

Table 3. Response to 2-chlorodeoxyadenosine in CTCL patients – results from different centers and from the Dermatological Department, Gdansk, Poland.

	Number of patients	Complete (%) remission	Partial remission (%)	No response (%)
Bouwhius <i>et al.</i> , 2002, USA ³	6	13	50	37
Kuzel <i>et al.</i> , 1996, USA ¹²	21	14	14	72
Saven <i>et al.</i> , 1992, Canada ²⁵	16	20	27	47
Rummel <i>et al.</i> , 1998, Germany ²⁰	66	38	ND	ND
Kay <i>et al.</i> , 1992, Canada ⁹	40	20	22.5	57.5
Kong <i>et al.</i> , 1997, USA ¹¹	24	12	12	76
O'Brien <i>et al.</i> , 1994, USA ²³	22	18	23	59
Dept. of Dermatology, Poland (present report)	6	33	50	17

ND, no data.

infections by chemoprophylaxis with co-trimoxazol and acyclovir during and after 2CdA treatment. One patient died because of progression of the lymphoma to the central nervous system a few months after the end of treatment (patient 46/F with PTCL). The other two patients achieved partial remission and required further chemotherapy (Table 2).

Discussion

2CdA therapy was mostly well tolerated in view of the known side effects (Table 4) although one patient died just after the second pulse because of myelosuppression. The observed remissions were short-lasting. Table 3 shows the experience with 2CdA in other

Table 4. Dose-dependent side effects after 2-chlorodeoxyadenosine, based on data in the literature^{8,13,21-23}

Side effect	Time of appearance (*)
Headache (22%, 7% >2 nd week)	Immediate
Erythema (5-27%, 10% >2 nd week)	Early
Nausea (0-28%)	Immediate
Myelosuppression (neutropenia, thrombocytopenia, lymphocytopenia)	Early, distant, late
Cutaneous side effects, including panniculitis (19%)	Immediate
Paraparesis, tetraparesis (rare)	Distant
Hyperuricemia	Immediate
Renal function disturbances (rare)	Early
Fever (46%)	Immediate
Fatigue (45%, 11% >2 nd week)	Immediate

*The time of side effects' appearance: immediate, hours; early, days, weeks; distant, weeks, months; late, months, years.

centers.^{8,13,21,30} Based on these data, we cannot recommend 2CdA as a routine treatment of CTCL. We concluded that 2CdA is moderately effective in CTCL, giving remission in approximately 67% of patients. The remissions are very short and there is a considerable risk of fatal infections owing to immunosuppression.

References

- Baltz JK, Montello MJ. Cladribine for the treatment of hematologic malignancies. *Clin Pharm* 1993;12:805-13.
- Beutler E. Cladribine (2-chlorodeoxyadenosine). *Lancet* 1992;340:952-6.
- Bouwhuis SA, el-Azhary RA, McEvoy MT, et al. Treatment of late-stage of Sézary syndrome with 2-Chlorodeoxyadenosine. *Int J Derm* 2002;41:352-6.
- Dann EJ, Gillis S, Polliack A, et al. Brief report: Tumour lysis syndrome following treatment with 2-chlorodeoxyadenosine for refractory chronic lymphocytic leukemia. *N Engl J Med* 1993;329:1547-8.
- Dimopoulos MA, Kantarjian H, Estey E, et al. Treatment of Waldenstrom macroglobulinemia with 2-chlorodeoxyadenosine. *Ann Int Med* 1993;118:195-8.
- Fabianowska-Majewska K, Wyczechowska D. 2-Chloro-2-deoxyadenosine (2CdA) biochemical aspects of antileukemic efficiency. *Acta Pol Pharm* 1996;53:231-9.
- Goh NS, McDonald CF, Macgregor DP, et al. Successful treatment of Langerhans cell histiocytosis with 2-chlorodeoxyadenosine. *Respirology* 2003;8:91-4.
- Jones GW, Kacinski BM, Wilson LD, et al. Total skin electron radiation in the management of mycosis fungoides: Consensus of the European Organization for Research and Treatment of Cancer (EORTC), Cutaneous Lymphoma Project Group. *J Am Acad Dermatol* 2002;47:364-70.
- Kay AC, Saven A, Carrera CJ, et al. 2-Chlorodeoxyadenosine treatment of low grade lymphomas. *J Clin Oncol* 1992;10:371-7.
- Kaye FJ, Bunn PA. A randomized trial comparing combination electron-beam radiation and chemotherapy with topical therapy in the initial treatment of mycosis fungoides. *N Engl J Med* 1989;321:1784-90.
- Kong LR, Samuelson E, Rosen ST, et al. 2-chlorodeoxyadenosine in cutaneous T-cell lymphoma disorders. *Leuk Lymphoma* 1997;26:89-97.
- Kuzel MT, Hurria A, Samuelson E, et al. Phase II trial of 2-chlorodeoxyadenosine for treatment of cutaneous T-cell lymphoma. *Blood* 1996;87:906-11.
- Larfars G, Uden-Blohme AM, Samuelsson J. Fludarabine as well as 2-chlorodeoxyadenosine can induce eosinophilia during treatment of lymphoid malignancies. *Br J Hematol* 1996;94:709-12.
- [No authors listed] Pentostatin and 2-chlorodeoxyadenosine for hairy-cell leukemia. *Med Lett Drugs Ther* 1992;34:89-90.
- Piro LD. 2-Chlorodeoxyadenosine treatment of lymphoid malignancies. *Blood* 1992;79:843-5.
- Piro LD, Carrera CJ. Lasting remissions in hairy cell leukemia induced by a single infusion of 2-chlorodeoxyadenosine. *N Engl J Med* 1990;322:1117-21.
- Podstawka U, Pałynyczko G, Konopka L, et al. Limfocyty T i komórki NK u pacjentów z przewlekłą białaczką limfatyczną b po leczeniu 2-chlorodeoxyadenozyną (2CdA). *Okol Pol* 2002;5:117-21.
- Robak T. The role of nucleoside analogues in the treatment of chronic lymphocytic leukemia – lessons learned from prospective randomized trials. *Leuk Lymphoma* 2002;43:537-48.
- Robak T, Blonski JZ, Gora-Tybor J, et al. Second malignancies and Richter's syndrome in patients with chronic lymphocytic leukemia treated with cladribine. *Eur J Cancer* 2004;40:383-9.
- Rummel MJ, Chow KU, Jager E, et al. Intermittent 2-hour infusion of cladribine as first-line therapy or in first relapse of progressive advanced low-grade and mantle cell lymphomas. *Leuk Lymphoma* 1999;35:129-38.
- Liliemark J, Albertioni F, Hassan M, et al. On the bioavailability of oral and subcutaneous 2-chlorodeoxyadenosine in humans: Alternative routes of administration. *J Clin Oncol* 1992;10:1514-8.
- Liliemark J, Juliusson G. On the pharmacokinetics of 2-chloro-2'-deoxyadenosine in humans. *Cancer Res* 1991;51:5570-2.
- O'Brien S, Kurzrock R, DuVick M, et al. 2-chlorodeoxyadenosine therapy in patients with T-cell lymphoproliferative disorders. *Blood* 1994;84:733-8.
- Saven A, Piro LD. 2-Chlorodeoxyadenosine: A newer purine analog active in the treatment of indolent lymphoid malignancies. *Ann Intern Med* 1994;120:784-91.
- Saven A, Carrera CJ, Carson DA, et al. 2-Chlorodeoxyadenosine: An active agent in the treatment of cutaneous T-cell lymphoma. *Blood* 1992;80:587-92.
- Trautinger F, Knobler R, Willemze R, et al. EORTC consensus recommendations for the treatment of mycosis fungoides, Sézary syndrom. *Eur J Cancer* 2006;42:1014-30.
- Trautinger F, Schwarzmeier J, Hönigsmann H, et al. Low-dose 2-chlorodeoxyadenosine for the treatment of mycosis fungoides. *Arch Dermatol* 1999;135:1279-80.
- Whittaker SJ, Marsden JR, Spittle M, et al. Joint British Association of Dermatologists and UK Cutaneous Lymphoma Group guidelines for the management of primary cutaneous T-cell lymphomas. *Br J Dermatol* 2003;149:1095-107.
- Zaja F, Fanin R, Silvestro F, et al. Retrospective analysis of 34 cases of hairy cell leukemia treated with INF alpha and/or 2CdA. *Haematologica* 1997;82:468-70.
- Zauchka JM, Lewandowski K, Hellmann A, et al. 2-chlorodeoxyadenosine treatment in the Sézary syndrome. *Blood* 1997;89:1462-4.