

Radiation induced tissue necrosis mimicking orbital apex syndrome

SAGE Open Medical Case Reports
Volume 10: 1–4
© The Author(s) 2022
Article reuse guidelines:
sagepub.com/journals-permissions
DOI: 10.1177/2050313X221123292
journals.sagepub.com/home/sco



Luai Eldweik¹

Abstract

We are reporting a unique case with findings resembling orbital apex syndrome due to radiation-induced ischemic tissue necrosis following the treatment of meningiomatosis. In our patient, radiation injury caused multiple neuropathies including: 2nd, 3rd, 4th, 5th, and 6th neuropathies with oculosympathetic pathway involvement. To our knowledge, our patient has some unique features of complications related to radiation necrosis. Describing this case will help clinicians to have a better understanding of the extent of ocular manifestations secondary to radiation necrosis.

Keywords

Radiation injury, optic neuropathy, multiple cranial neuropathies, orbital apex syndrome, meningiomatosis

Date received: 28 April 2022; accepted: 10 August 2022

Introduction

Due to the proximity of cavernous sinus meningiomas to critical cranial nerve (CN) and vascular structures, complete resection using an endoscopic or transcranial skull base approach comes with high surgical risks. Radiation therapy is an effective treatment after their resection or as an upfront treatment. Radiation necrosis is a late complication of radiation to the brain or surrounding structures.¹ Although this has been considered uncommon, the incidence is increasing with more utilization of stereotactic radiosurgery (SRS) and combined therapies.² This is thought to be probably the result of vascular endothelial damage that leads to focal coagulative necrosis, oligodendrocyte damage and demyelination.^{3,4} We report a 62-year-old woman presenting with a clinical picture resembling unilateral orbital apex syndrome caused by radiation injury following the treatment of multiple meningiomas.

Case report

A 62-year-old female patient with history of bilateral pseudophakia, and right cicatricial ectropion, presented to cornea clinic with a new onset of right eye redness, discomfort and blurred vision for 2 weeks. She has a history of meningiomatosis: Right frontal convexity meningioma resected followed by conventional external beam radiation (total dose of 50.4 Gy), a right parasagittal meningioma, a left temporal lobe meningioma, and a right cavernous sinus meningioma causing

right 6th nerve palsy and right horner's syndrome. A year earlier she underwent gamma knife radiosurgery for the right cavernous sinus meningioma with a total of 25 Gy in 5 fractions. At presentation, visual acuity dropped in the right eye to counting fingers. Slitlamp showed right lagophthalmos, and conjunctival injection with corneal infiltrates. Corneal scraping was performed, and the patient was started empirically on moxifloxacin eyedrops in addition to artificial tears. The cultures came back negative. Two weeks later, the keratoconjunctivitis resolved, however, the vision did not change.

Without a clear explanation for the vision loss, she was referred to the neuro-ophthalmology clinic. On further examination, visual acuity was counting fingers in the right eye and 20/20 in the left eye. She had right blepharoptosis. Pupillary exam showed anisocoria worse in the dark with the right pupil being smaller consistent with right horner's syndrome. On reverse consensual light reflex, a right afferent pupillary defect was noted. With the slit lamp, she had a faint right corneal scarring which did not explain the current vision. Fundus exam showed trace of right optic nerve pallor.

¹Eye Institute, Cleveland Clinic Abu Dhabi, Abu Dhabi, United Arab Emirates

Corresponding Author:

Luai Eldweik, Eye Institute, Cleveland Clinic Abu Dhabi, C7-257 Swing Wing, Cleveland Clinic, Al Maryah Island, Abu Dhabi 112412, United Arab Emirates.

Email: Eldweil@ClevelandClinicAbuDhabi.ae



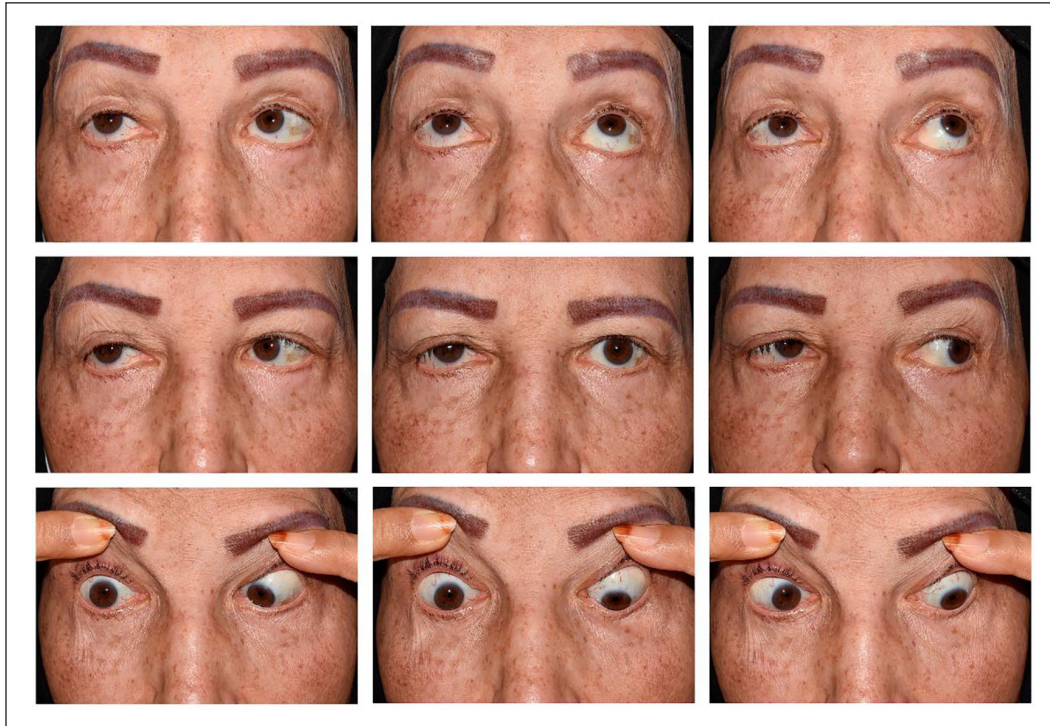


Figure 1. Nine cardinal positions photo showing right blepharoptosis and anisocoria. The right eye motility showed limited adduction, infraduction, abduction, and supraduction; indicating 3rd, 4th, and 6th palsies.

With the use of a cotton tip we found decreased right corneal sensation; sensorimotor testing showed external ophthalmoplegia of the right eye, indicating 3rd, 4th, and 6th right nerves palsies (Figure 1). The left eye examination was normal. Optical coherence tomography (OCT) of the peripapillary nerve fiber layer showed normal thicknesses in both eyes. However, macular ganglion cell layer analysis showed diffuse loss in the right eye. The presence of the afferent pupillary defect along with the early loss of the nerve fibers indicated additional optic neuropathy to the other cranial nerves palsies.

The constellation of clinical findings localized the process to the area of the orbital apex. Therefore, the patient was investigated with a brain and orbital magnetic resonance imaging (MRI) with and without contrast that was done urgently and displayed pre-chiasmatic enhancement of the right optic nerve along with the nerve sheath, and enhancement of the medial border of right temporal lobe on T1 post contrast axial cut (Figure 2(a)), and this is also shown on coronal cut as the optic nerve crosses the optic canal (Figure 2(b)). Diffusion-weighted imaging obtained at the same level showed hypointensity, and corresponding mixed signal intensity on apparent diffusion coefficient images (Figure 2(c)).

With radiation necrosis, infection, inflammation, and tumor recurrence in mind, the patient was admitted for further management. Blood tests (complete blood count, erythrocyte sedimentation rate, C-reactive protein, antinuclear antibody titers, angiotensin-converting enzyme level, QuantiFERON gold,

and IgG-4 serum level) came back unremarkable. Further imaging with MR perfusion showed lower relative cerebral blood volume (rCBV), and fluorodeoxyglucose (FDG)-positron emission tomography (PET) showed reduced uptake of the tracer, which goes in line with radiation necrosis.

Finally, the patient was diagnosed with radiation necrosis in the temporal lobe adjacent the cavernous sinus and therefore the visual symptoms and enhancement on the MRI in the orbital apex region were felt to be due to possibly reversible radiation injury to the right cavernous sinus and optic nerve. Based on that assumption, the patient received bevacizumab, an anti-vascular endothelial growth factor (VEGF) monoclonal antibody, along with high dose steroids followed by gradual taper without a significant response in the vision or ocular motility. Six months later, the visual acuity in the affected eye was light perception, extraocular motility remained the same. A follow-up MRI revealed a marked decrease of the enhancement of the cavernous lesion.

Discussion

Our patient presented with new onset of subacute vision loss, ptosis, and external ophthalmoplegia. Clinical evaluation indicated multiple cranial neuropathies including the right optic nerve, right oculomotor nerve, right trochlear nerve, right V1 V2 branches of the trigeminal nerve, right abducent nerve, and the right oculosympathetic pathway on the right side. This was suggestive of a lesion(s) in the area extending

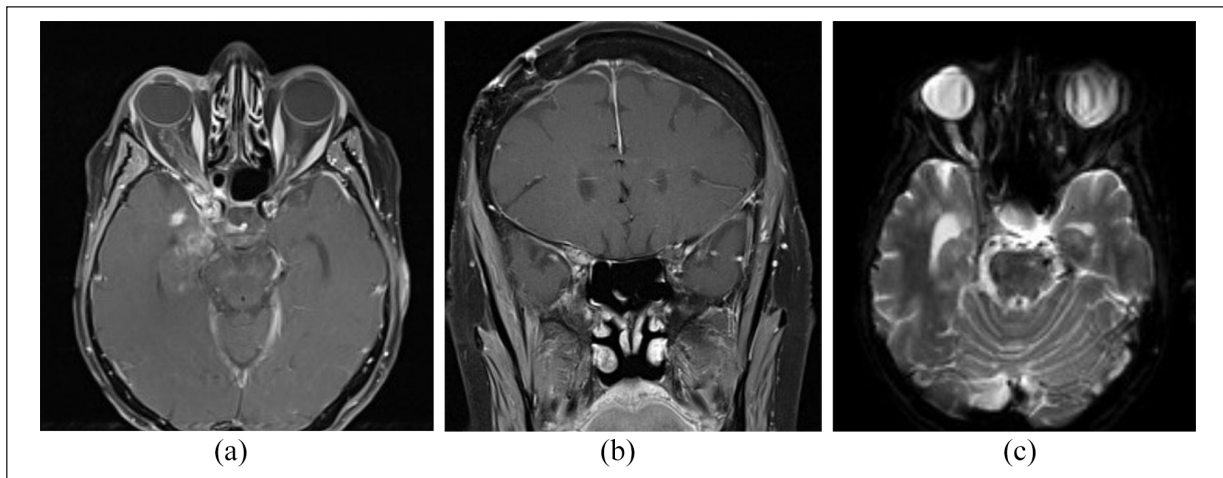


Figure 2. MRI of the brain with contrast. T1 post contrast axial cut (a) shows pre-chiasmatic enhancement of the right optic nerve along with the nerve sheath, and enhancement of the medial border of right temporal lobe. T1 post contrast coronal cut with fat saturation (b) showed enhancement of the right optic nerve as it crosses the optic canal along with patchy enhancement of the temporal lobe. Diffusion weighted imaging (c) demonstrates patches of dark areas in the corresponding enhancing lesions.

from the cavernous sinus to the orbit with the differential diagnoses including tumor recurrence, radiation necrosis, or other inflammatory/infective process. In this case, the distinction between the first two entities was of a critical importance. Biopsy, which is the gold standard, is subject to sampling error. Different non-invasive criteria have been developed to define radiation necrosis.⁵ In our patient, we used perfusion MRI to confirm the diagnosis of tissue necrosis.

Meningiomas located in the region of the skull base require complex combined surgical approaches that have been related to high morbidity. While conventional external beam radiation using radiation therapy (RT) was found to be highly effective following incomplete excision, the reported toxicity ranges from 0% to 24%, including optic neuropathy, brain necrosis, and pituitary deficits.¹ Later, SRS became more extensively employed in the treatment of skull base meningiomas. Complications of SRS can be either transient or permanent complications, with the incidence ranging from 3% to 40%. The rate of permanent morbidity including delayed cranial nerve deficits is around 6%.⁶ Large series of patients was from the study by Morita et al.,⁷ who reviewed 88 patients with skull base meningioma after gamma knife, and found increased risk of trigeminal neuropathy seemed to be associated with doses of more than 19 Gy, and the optic apparatus appeared to tolerate doses greater than 10 Gy. There is a significant difference in sensitivity of the anterior visual pathway to the effect of radiation compared to other cranial nerves. The optic nerve and chiasm are myelinated by oligodendrocytes which are highly radiosensitive. In contrast, ocular motor nerves are myelin free, and their function depends on Schwann cells which are to be more radioresistant.⁸ Multiple risk factors have been identified including the dose, fractions size, treatment

duration, volume treated, chemotherapy, previous radiation, and male sex.⁹ Shaw et al.¹⁰ found a dose increased risk of developing radiation injury in patients with previously irradiated primary tumors. In addition to the high dose of radiation that our patient had received; the large initial size of the tumor, and the advanced age of the patient increased the risks of developing this complication. The management of radiation necrosis also poses many challenges. Options for treatment from conservative to medical management, hyperbaric oxygen, and surgical intervention.¹¹ For our patient, we offered an anti-VEGF monoclonal antibody, and high dose steroids. A follow up visit after 24 weeks failed to show improvement in vision or ocular motility. The OCT of the macular ganglion cell layer changes preceded the loss of the peripapillary nerve fiber. However, radiological monitoring showed interval improvement.

Conclusion

With the increased use of radiotherapy, in the form of SRS, external beam radiation, or combined, more patients are clinically manifesting late complications. Radiation necrosis is prominently hard to diagnose and manage, therefore, risk factor reduction becomes essential during decision making in patients with higher risk of complications, and close observation in patients who received higher dose of radiation to ensure early diagnosis. Ophthalmologists should be aware of the possible complications of radiation therapy to the eye in order to avoid delays in the diagnosis and treatment given that early-delayed reactions that are usually reversible, while late changes are generally not.

Authorship

The author meets the current ICMJE criteria for Authorship

Declaration

I declare full responsibility for the data, images, and interpretation

Declaration of conflicting interests

The author(s) declared no potential conflicts of interest with respect to the research, authorship, and/or publication of this article.

Funding

The author(s) received no financial support for the research, authorship, and/or publication of this article.

Ethical approval

Our institution does not require ethical approval for reporting individual cases or case series.

Informed consent

Written informed consent was obtained from the patient for anonymized patient information to be published in this article.

Patient Consent

Written informed consent was obtained from the patient for anonymized patient information to be published in this article.

ORCID iD

Luai Eldweik  <https://orcid.org/0000-0002-6504-646X>

References

1. Minniti G, Amichetti M and Enrici RM. Radiotherapy and radiosurgery for benign skull base meningiomas. *Radiat Oncol* 2009; 4: 42.
2. Chin LS, Ma L and DiBiase S. Radiation necrosis following gamma knife surgery: a case-controlled comparison of treatment parameters and long-term clinical follow up. *J Neurosurg* 2001; 94(6): 899–904.
3. Calvo W, Hopewell JW, Reinhold HS, et al. Time- and dose-related changes in the white matter of the rat brain after single doses of X rays. *Br J Radiol* 1988; 61(731): 1043–1052.
4. Kurita H, Kawahara N, Asai A, et al. Radiation-induced apoptosis of oligodendrocytes in the adult rat brain. *Neurol Res* 2001; 23(8): 869–874.
5. Chao ST, Ahluwalia MS, Barnett GH, et al. Challenges with the diagnosis and treatment of cerebral radiation necrosis. *Int J Radiat Oncol Biol Phys* 2013; 87(3): 449–457.
6. Kondziolka D, Mathieu D, Lunsford LD, et al. Radiosurgery as definitive management of intracranial meningiomas. *Neurosurgery* 2008; 62(1): 53–58; discussion 58.
7. Morita A, Coffey RJ, Foote RL, et al. Risk of injury to cranial nerves after gamma knife radiosurgery for skull base meningiomas: experience in 88 patients. *J Neurosurg* 1999; 90(1): 42–49.
8. Vaphiades MS, Spencer SA, Riley K, et al. Radiation-induced ocular motor cranial nerve palsies in patients with pituitary tumor. *J Neuroophthalmol* 2011; 31(3): 210–213.
9. Vellayappan B, Tan CL, Yong C, et al. Diagnosis and management of radiation necrosis in patients with brain metastases. *Front Oncol* 2018; 8: 395.
10. Shaw E, Scott C, Souhami L, et al. Single dose radiosurgical treatment of recurrent previously irradiated primary brain tumors and brain metastases: final report of RTOG protocol 90-05. *Int J Radiat Oncol Biol Phys* 2000; 47(2): 291–298.
11. Song YP and Colaco RJ. Radiation necrosis: a growing problem in a case of brain metastases following whole brain radiotherapy and stereotactic radiosurgery. *Cureus* 2018; 10(1): e2037.