

CASE REPORT

Acetaminophen overdose associated with double serum concentration peaks

Cristian Papazoglu, MD, PhD*, Jonathan R. Ang, MD, Michael Mandel, MD, Prasanta Basak, MD, FACP and Stephen Jesmajian, MD, FACP

Department of Internal Medicine, Montefiore New Rochelle Hospital, Albert Einstein College of Medicine, New Rochelle, NY, USA

Acetaminophen is the most commonly used analgesic–antipyretic medication in the United States. Acetaminophen overdose, a frequent cause of drug toxicity, has been recognized as the leading cause of fatal and non-fatal hepatic necrosis. *N*-Acetylcysteine is the recommended antidote for acetaminophen poisoning. Despite evidence on the efficacy of *N*-acetylcysteine for prevention of hepatic injury, controversy persists about the optimal duration of the therapy. Here, we describe the case of a 65-year-old male with acetaminophen overdose and opioid co-ingestion who developed a second peak in acetaminophen serum levels after completing the recommended 21-hour intravenous *N*-acetylcysteine protocol and when the standard criteria for monitoring drug levels was achieved. Prolongation of *N*-acetylcysteine infusion beyond the standard protocol, despite a significant gap in treatment, was critical for successful avoidance of hepatotoxicity. Delay in acetaminophen absorption may be associated with a second peak in serum concentration following an initial declining trend, especially in cases of concomitant ingestion of opioids. In patients with acetaminophen toxicity who co-ingest other medications that may potentially delay gastric emptying or in those with risk factors for delayed absorption of acetaminophen, we recommend close monitoring of aminotransferase enzyme levels, as well as trending acetaminophen concentrations until undetectable before discontinuing the antidote therapy.

Keywords: *acetaminophen toxicity; acetaminophen level; N-acetylcysteine*

*Correspondence to: Cristian Papazoglu, Department of Internal Medicine, Montefiore New Rochelle Hospital, Albert Einstein College of Medicine, 16 Guion Place, New Rochelle, NY 10802, USA, Email: cpapazog@montefiore.org

Received: 31 August 2015; Revised: 9 November 2015; Accepted: 12 November 2015; Published: 11 December 2015

Acetaminophen has become the most widely used analgesic–antipyretic in the United States, since its introduction in 1955. It is a component of innumerable over-the-counter and prescription medications that are used worldwide. Although safe when taken at usual therapeutic doses, acetaminophen overdose is a very common cause of drug toxicity and has been recognized as the most common cause of fatal and non-fatal hepatic necrosis (1).

N-Acetylcysteine (NAC) is an effective antidote for the prevention and treatment of acetaminophen hepatotoxicity (2). There are two FDA-approved regimens for the treatment of acetaminophen poisoning: a 72-hour oral and a 21-hour IV protocol (2, 3). Current literature suggests that there is no significant difference between the rates of hepatotoxicity for oral and IV NAC administration (4). Both routes of administration are acceptable, but IV protocol is preferred in patients with contraindications to oral administration (e.g., vomiting, bowel ileus, or

ingestion of substances that may alter gastric motility). Ideally, NAC treatment should be started within 8 hours of acetaminophen ingestion, or as soon as possible (2, 5). It is recommended that serum acetaminophen levels as well as liver functions be evaluated prior to, during, and at the end of the treatment regimen. If encephalopathy or elevated liver enzymes are present at the end of the 72-hour oral or 21-hour IV protocols, extending the NAC treatment is highly recommended (6, 7). Candidates for extension of NAC therapy include those with massive acetaminophen overdose, concomitant ingestion of other substances, pre-existing liver disease, or patients with evidence of hepatic injury at the end of the recommended NAC therapy (7).

Case report

A 65-year-old male with a history of previous suicide attempts, bipolar disorder, hypertension, and coronary artery disease was found to be drowsy by his family members in the morning of his presentation to the

emergency department (ED). He ingested an unknown number of Percocet (oxycodone 5 mg/acetaminophen 325 mg) and Xanax (alprazolam 1 mg) tablets in an attempted suicide. Two empty bottles of Percocet and Xanax were found in the patient's room. The number of ingested pills and the exact time of ingestion were unknown. He filled both prescriptions 7 days prior to the suicide attempt. His home medications consisted of Xanax 1 mg every 6 hours PRN, Percocet 325 mg/5 mg every 6 hours PRN, carvedilol (Coreg) 6.25 mg two times per day, amlodipine (Norvasc) 10 mg daily, Ibuprofen 600 mg daily PRN, tramadol 50 mg every 6 hours PRN, and zolpidem (Ambien) 10 mg daily at bedtime. No known drug allergies were reported.

Naloxone was given in the ambulance with minimal improvement of his mental status. In the emergency room, the patient was found to be drowsy, unable to follow commands but arousable. Vital signs were temperature 98.8°F, heart rate 94 beats/min, blood pressure 112/88 mmHg, respiratory rate 18/min, and an oxygen saturation of 95% on room air. Pupils were 2 mm in diameter, equal, and reactive to light. A nasogastric tube (NGT) was placed and 1 L of bilious material was evacuated with pill fragments. Patient's mental status continued to deteriorate, and soon, he became unresponsive and bradycardic which warranted endotracheal intubation for airway protection. Urine toxicology was positive for benzodiazepines and opioids. Serum salicylate and ethanol levels were undetectable. The initial acetaminophen level was 75 µg/mL. Poison control center was contacted and the case discussed. The patient was subsequently started on NAC therapy, using the 21-hour IV protocol. Other baseline laboratory results included BUN 18 mg/dL, Cr 1.10 mg/dL, AST 8 IU/L, ALT 11 IU/L, total bilirubin 0.7 mg/dL, alkaline phosphatase 62 IU/L, and INR 0.97.

The patient was admitted to the intensive care unit. Two hours later, acetaminophen level decreased to 72 µg/mL. He continued to remain bradycardic and hypotensive, and

was started on dopamine drip. Acetaminophen level measured 4 hours after admission was 67 µg/mL. His LFTs remained within normal limits. He completed the 21-hour NAC IV therapy with 1-hour loading dose (150 mg/kg/hr NAC), followed by a 4-hour (12.5 mg/kg/hr NAC) and then a 16-hour maintenance infusion (6.25 mg/kg/hr). His mental status slowly improved, vital signs stabilized, vasopressors were discontinued, and he was successfully extubated. At 24 hours from admission, the acetaminophen level was 21 µg/mL, and the NAC protocol was completed.

At 30 hours, patient's NGT was clogged and was removed. Upon inspection of the tube, there appeared to be solid material blocking the lumen which was thought to be medication fragments and a repeat acetaminophen level was immediately done and was found to be 150 µg/mL. After a 6-hour gap from the initial antidote protocol, NAC IV therapy was restarted using the last 16-hour infusion step of the 21-hour protocol. Patient's aminotransferase levels continued to remain normal. By 34 hours, his acetaminophen level was 119 µg/mL, and by 40 hours post-admission, it had trended down to normal/therapeutic level (27 µg/mL). Acetaminophen level became undetectable 90 hours post-admission (Fig. 1). The patient's liver enzymes remained normal throughout his admission. He was later discharged to an inpatient psychiatric facility.

Discussion

NAC is the recommended antidote for acetaminophen poisoning and is given to all patients at significant risk for hepatotoxicity. While there are no randomized, placebo-controlled trials evaluating the efficacy of NAC for the prevention of hepatic injury due to acetaminophen poisoning, several studies have described an extremely low incidence of hepatotoxicity following early NAC administration (3, 8). Additionally, NAC administration following acetaminophen ingestion in patients with evidence of

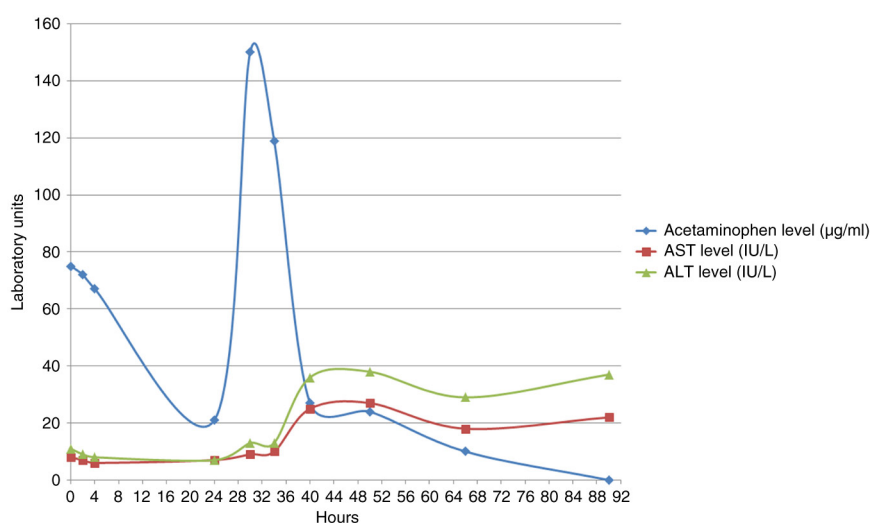


Fig. 1. Variability of the acetaminophen serum concentration and levels of transaminases, during patient's hospitalization.

hepatic failure decreases mortality and improves hepatic and cerebral function (7, 9). Despite evidence on the efficacy of NAC, controversy persists about the optimal duration of the therapy. While the two FDA-approved protocols for the treatment of acetaminophen poisoning are adequate for the vast majority of patients, there are reports indicating that the 21-hour protocol is not long enough in some cases (10, 11). Many authors recommend that therapy be tailored to each patient, using clinical endpoints rather than time, to determine the duration of treatment (11).

There were only two case reports of acetaminophen poisoning associated with double concentration peaks (10, 12). In contrast to previous reports, our patient's clinical course was not complicated by hepatotoxicity. Because our patient was asymptomatic and transaminases were within normal levels at the time of detection of the second acetaminophen peak, the antidotal therapy was prolonged by using the low-dose NAC infusion. Therefore, NAC therapy was extended for another 16 hours past the recommended 21-hour IV protocol and hepatic toxicity was successfully avoided.

Aberrant acetaminophen absorption and/or delayed gastric emptying potentiated by concurrent ingestion of other substances, like opiates, may cause persistently elevated acetaminophen serum levels. Published literature indicates that poisoning with tricyclic antidepressants, acetaminophen, opioid-acetaminophen mixtures, and carbamazepine causes gastric hypomotility and delayed emptying (13). Although acetaminophen is not known to have any inhibitory effect on the gastrointestinal tract, acetaminophen overdose doubled the individual average gastric emptying times (13).

Other theories as to why some patients demonstrate a second peak of serum levels despite no repeated ingestions include excessive solubility, possible medication bezoar formation, individual variations in gastric emptying time, physiologically or chemically altered gastrointestinal motility, and enterohepatic recycling (14–17). These factors imply that potentially toxic amounts of residual acetaminophen can persist after a 21-hour intravenous NAC course. Discontinuation of NAC prior to complete acetaminophen absorption, metabolism, and elimination may result in significant hepatic injury and death.

Based on current recommendations, NAC is indicated in patients with an unknown time of ingestion and a serum acetaminophen concentration $> 10 \mu\text{g/mL}$. Our patient's initial acetaminophen level upon arrival in the ED was $75 \mu\text{g/mL}$ and a second peak of acetaminophen serum level was demonstrated 30 hours after admission. Continuous direct observation (one-to-one suicide precautions) made a second ingestion unlikely in our patient. We hypothesized that delayed gastric emptying due to high doses of acetaminophen along with oxycodone was the cause of the double peak of acetaminophen levels in our patient.

More frequent interval sampling might have uncovered higher values at slightly different times, and the second peak of potentially hepatotoxic residual acetaminophen metabolite might have been discovered earlier. Fortunately, our patient did not have any significant liver damage despite a gap in continuation of NAC.

In patients with acetaminophen toxicity who co-ingest other medications that may potentially delay gastric emptying or in those with risk factors for delayed absorption of acetaminophen, we recommend close monitoring of aminotransferase enzyme levels, as well as trending acetaminophen concentrations until undetectable before discontinuing NAC therapy. High acetaminophen level after 21 hours of NAC treatment, elevated transaminases or symptomatic patient (e.g., right upper quadrant pain, hepatic encephalopathy), require prolongation of the standard recommended time for NAC therapy.

Conclusions

We presented a case of a patient with concomitant acetaminophen and opioid ingestion who developed a rising acetaminophen level after completing IV NAC protocol when the standard 'stop' criteria for monitoring drug levels was achieved. Experimental evidence and case reports have documented delayed absorption following ingestion of extended-release acetaminophen, opioid- or anticholinergic-containing acetaminophen products, or co-ingestants (13). Delay in acetaminophen absorption may be associated with a second peak in acetaminophen concentration following an initial declining trend. We recommend checking acetaminophen serum levels several hours after protocol completion to detect post-treatment rising levels, especially in cases of concomitant ingestion of opioids.

Authors' contributions

CP, JRA, MM, PB, and SJ contributed to conception and design, and drafting and revising of this article; CP acquired and interpreted the data; JRA interpreted the data. Finally, all authors approved the final version.

Conflict of interest and funding

The authors declare that they do not have a conflict of interest.

References

1. Bronstein AC, Spyker DA, Cantilena LR Jr, Green J, Rumack BH, Heard SE. Annual report of the American Association of Poison Control Centers' National Poison Data System (NPDS). *Clin Toxicol* 2007; 45: 815–917.
2. Smilkstein MJ, Knapp GL, Kulig KW, Rumack BH. Efficacy of oral *N*-acetylcysteine in the treatment of acetaminophen overdose. Analysis of the national multicenter study (1976 to 1985). *N Engl J Med* 1988; 319: 1557–62.

3. Prescott LF, Park J, Ballantyne A, Adriaenssens P, Proudfoot AT. Treatment of paracetamol (acetaminophen) poisoning with *N*-acetylcysteine. *Lancet* 1977; 2: 432.
4. Green JL, Heard KJ, Reynolds KM, Albert D. Oral and intravenous acetylcysteine for treatment of acetaminophen toxicity: A systematic review and meta-analysis. *West J Emerg Med* 2013; 14: 218–26.
5. Prescott LF. Treatment of severe acetaminophen poisoning with intravenous acetylcysteine. *Arch Intern Med* 1981; 141: 386.
6. Doyon S, Klein-Schwartz W. Hepatotoxicity despite early administration of intravenous *N*-acetylcysteine for acute acetaminophen overdose. *Acad Emerg Med* 2009; 16: 34.
7. Keays R, Harrison PM, Wendon JA, Forbes A, Gove C, Alexander GJ, et al. Intravenous acetylcysteine in paracetamol-induced fulminant hepatic failure: A prospective controlled trial. *BMJ* 1991; 303: 1026–9.
8. Heard K, Rumack BH, Green JL, Bucher-Bartelson B, Heard S, Bronstein AC, et al. A single-arm clinical trial of a 48-hour intravenous *N*-acetylcysteine protocol for treatment of acetaminophen poisoning. *Clin Toxicol (Phila)* 2014; 52: 512.
9. Harrison PM, Keays R, Bray GP, Alexander GJ, Williams R. Improved outcome of paracetamol-induced fulminant hepatic failure by late administration of acetylcysteine. *Lancet* 1990; 335: 1572.
10. Smith SW, Howland MA, Hoffman RS, Nelson LS. Acetaminophen overdose with altered acetaminophen pharmacokinetics and hepatotoxicity associated with premature cessation of intravenous *N*-acetylcysteine therapy. *Ann Pharmacother* 2008; 42(9): 1333–9.
11. Dart RC, Rumack BH. Patient-tailored acetylcysteine administration. *Ann Emerg Med* 2007; 50: 280.
12. Burda T, Sigg T. Double peak and prolonged absorption after large acetaminophen extended release and diphenhydramine ingestion. *Am J Ther* 2012; 19(2): e101–4.
13. Adams BK, Mann MD, Aboo A, Isaacs S, Evans A. Prolonged gastric emptying half-time and gastric hypomotility after drug overdose. *Am J Emerg Med* 2004; 6: 548–54.
14. Roberts MS, Magnusson BM, Burczynski FJ, Weiss M. Enterohepatic circulation: Physiological, pharmacokinetic and clinical implications. *Clin Pharmacokinet* 2002; 41: 751–90.
15. Young A. Inhibition of gastric emptying. *Adv Pharmacol* 2005; 52: 99–121.
16. Clements JA, Heading RC, Nimmo WS, Prescott LF. Kinetics of acetaminophen absorption and gastric emptying in man. *Clin Pharmacol Ther* 1978; 24: 420–31.
17. Schurizek BA, Kraglund K, Andreasen F, Vinter-Jensen L, Juhl B. Antroduodenal motility and gastric emptying. Gastrointestinal motility and pH following ingestion of paracetamol. *Aliment Pharmacol Ther* 1989; 3: 93–101.