



Case report

Isolated intramaxillary sinus cell causing long-standing facial pain: A case report

Saud Alromaih^{a,1,2}, Nouf Aloraini^{b,3,*}, Saleh Alqaryan^{b,4}, Ibrahim Sumaily^{c,5}^a Department of Otolaryngology – Head & Neck Surgery, King Saud University, Riyadh, Saudi Arabia^b Otolaryngology – Head and Neck Surgery, King Saud University Medical City, Riyadh, Saudi Arabia^c Otolaryngology – Head and Neck Surgery, King Fahad Central Hospital in Jazan, Saudi Arabia

ARTICLE INFO

Keywords:

Paranasal sinuses
Case report
Rhinology
Air cyst
Pneumocoele

ABSTRACT

Introduction: Sinus pneumatization by definition is a cystic enlargement within the paranasal sinuses, and that expansion causes clinical symptoms.

Importance: This case highlights the importance of identifying clinically significant sinus pneumatization and the significant role of surgical treatment.

Case presentation: This case report describes a clinical presentation of intramaxillary sinus cell affecting the patient's quality of life. Despite the rare location of the cyst, it was diagnosed by computed tomography and managed by Functional Endoscopic Sinus surgery (FESS).

Clinical discussion: This case discussion describes the nomenclature, classifications, location and the treatment of sinus pneumatic dilatations.

Conclusion: Our case demonstrates the importance of managing the underlying cause of the patient symptoms by a thorough history and physical examination and it can be confirmed by imaging. Symptomatic maxillary air cysts, albeit controversial in its nomenclature and mechanism, should be addressed surgically as it carries high levels of success.

1. Introduction

Sinus pneumatization, also known as air cyst, is defined as an aerated cystic enlargement within the paranasal sinuses that expands beyond its normal boundaries causing clinical symptoms [1]. The clinical presentation varies depending on which sinus is affected, these symptoms include headache, proptosis, nasal obstruction, Eustachian tube obstruction, sinusitis, facial pain, and pressure [2,3]. This condition is a rare entity when maxillary sinuses are involved with a limited number of reported cases. It mainly affects young men aging between 20 and 40 years but can affect any age or gender. Moreover, the diagnostic method for pneumocoele is conducted via computed tomography (CT) as it can easily confirm the diagnosis [1].

2. Case report

A 50-year-old male presented to the clinic in a tertiary hospital complaining of a long-lasting facial pain, bilateral nasal obstruction associated with intermittent allergic symptoms for which the patient used antihistamines resulting in mild relief. There were no hyposmia, facial asymmetry/swelling, or recurrent acute rhinosinusitis episodes. The Patient was otherwise healthy and not using any medications, family history was negative for similar symptoms. Nasal endoscopic exam revealed deviated nasal septum (DNS), hypertrophied inferior turbinates (HIT), no polyp, or erythema seen. The result of routine laboratory test was normal. CT showed an air cell in the right maxillary sinus associated with a partially calcified polypoidal mucosal thickening. In addition, there was evidence of HIT and DNS mainly on the

* Corresponding author.

E-mail addresses: Salromaih@ksu.edu.sa (S. Alromaih), Naloraini3@gmail.com (N. Aloraini).¹ Guarantor.² Contributions: Concept, Supervision Data Collection, Writing Manuscript Critical Review.³ Contributions: Literature Search, Resources, Data Collection, Writing Manuscript, Critical Review.⁴ Contributions: Literature Search, Data Collection, Writing Manuscript, Critical Review.⁵ Contributions: Concept, Supervision, Critical Review.

right side (Fig. 1–3). On the second visit, his condition was managed medically but the facial pain over the right maxillary sinus persisted. He was then offered and counseled for surgical management, for which he agreed to do. The patient underwent Functional Endoscopic Sinus surgery (FESS), Septoplasty, and partial inferior turbinectomy under general anesthesia, done by the attending rhinologist. The surgery went well and no immediate complications were observed. Postoperative clinic visit showed that the patient was asymptomatic and the facial pain has resolved completely, endoscopic examination showed patent nasal airway, healthy mucosa with no signs of infection. The patient was instructed to come to the clinic if symptoms recurred.

3. Discussion

The size and shape of maxillary sinuses are variable. These parameters depend on developmental factors and influenced by pathological conditions [4]. Air cyst is a benign cystic expansion that is filled with air within the paranasal sinuses. Urken et al. classified sinus pneumatic dilatations into three entities based on symptomatology, radiologic enlargement, and thinning of the sinus walls. Air cyst used by modern authors as an umbrella term encompassing hypersinus, pneumosinus dilatation, and pneumocele, all of which were defined by Urken et al. [5]

Hyperpneumatized sinus is defined as an asymptomatic expansion of air which does not alter the external contour of the containing bone. Pneumosinus dilatans is a symptomatic air-filled expansion beyond the normal anatomical limits with normal cortical thickness. Symptoms of air expansion associated with focal or diffuse bone thinning is termed Pneumocele. These conditions are presented in order of severity and constitute as a spectrum of the same condition [4,5].

Frontal sinus is the most commonly affected sinus followed by ethmoid and sphenoid sinuses [3]. It is rare for the maxillary sinus to be involved. The infraorbital recess followed by the alveolar recess were noted to be a common area for pneumatization to develop, while others reported that the anteromedial wall of the maxillary sinus to be a more common site [6].

Multiple theories of the mechanism of this entity have been reported in the literature including a spontaneously draining mucocele, the presence of a gas-forming microorganism, the presence of a 1-way valve, a congenital malformation, or a hormonal cause [3–5]. However, these theories lack experimental evidence and some of them, such as the hormonal theory, have been disproved [1,3,6]. Facial pain over the maxilla has been described in the literature to be caused by air cysts in the maxilla and is due to the irritation of the trigeminal nerve [7].

Asymptomatic maxillary air cysts should be left untreated. However,

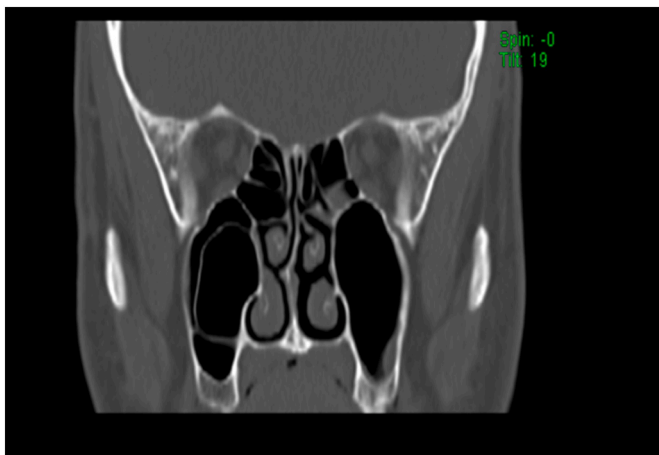

Fig. 1. Coronal section of CT air cell in the right maxillary sinus with evidence of hypertrophied inferior turbinate.

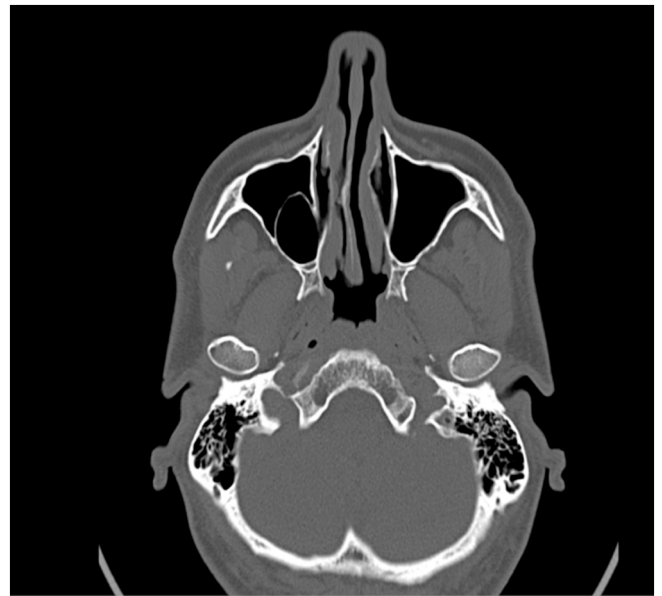

Fig. 2. Axial section of CT air cell in the right maxillary sinus with a deviated nasal septum mainly on the right side.

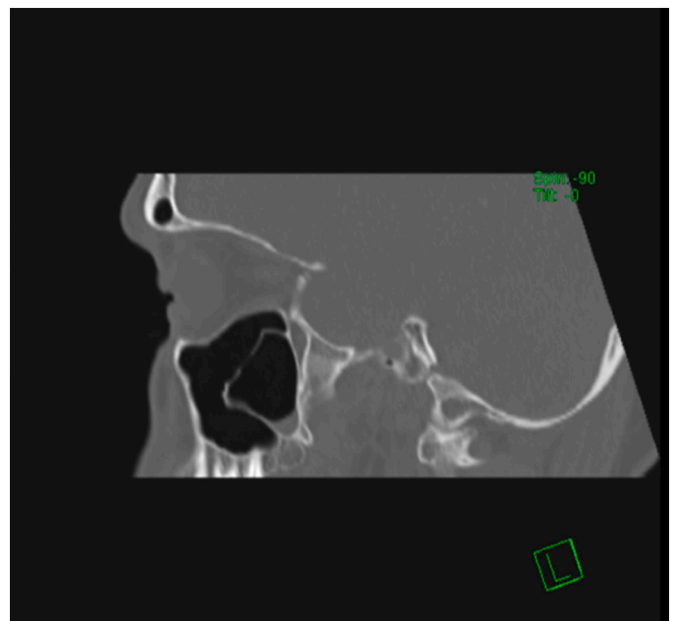


Fig. 3. Sagittal section of CT air cell in the right maxillary sinus associated with a partially calcified polypoidal mucosal thickening.

if maxillary air cysts became symptomatic, surgical intervention is considered the gold standard therapy. The treatment plan should be tailored according to the patient's severity of symptoms, the status of the cortical bone, the size of the sinus, and the co-existence of other nasal conditions such as DNS or HIT. Moreover, one of the most common procedures performed is the creation of a naso-antral window, mainly to equilibrate the intrasinus pressure [8]. Another surgical approach for managing maxillary sinus air cyst is needle puncture. Although this approach can be time-saving, its effect is variable. Our goals of performing FESS, in this case, is to alleviate the facial pain, prevent future complications, and correct his obstructive symptoms [3]. FESS is generally considered a low risk surgery with a rate of 0.5–1% of severe complication and only 5–7% of mild complications [9]. The serious

complications being; cerebrospinal fluid leakage, sever hemorrhage, toxic shock syndrome and orbital injuries [10]. Air cysts have an excellent prognosis with no recurrence that has been reported in treated lesions [5].

4. Conclusion

Our case demonstrates the importance of managing the underlying cause of the patient symptoms which begins with a thorough history and physical examination and can be confirmed by imaging. Symptomatic maxillary air cysts, albeit controversial in its nomenclature and mechanism, should be addressed surgically which commonly results in successful outcomes.

Informed consent

Informed consent was taken from the patient, a written consent stating clear information about case report publication and accompanying image was obtained. The anonymity will be assured by assigning the patient with abbreviation. A copy of the written consent is available upon request. This case report is in line with the SCARE 2020 criteria [11].

Ethical committee approval

Not Applicable.

Source of funding

No funding.

Guarantor

Saud Alromaih MD, MSc, FRCSC.

Provenance and peer review

Not commissioned, externally peer-reviewed.

CRedit authorship contribution statement

Saud Alromaih: concept, supervision, critical review.
 Nouf Aloraini: drafting, literature review, writing.
 Saleh Alqaryan: drafting, writing, review.
 Ibrahim AlSumaily: supervision, critical review.

Declaration of competing interest

We declare that this manuscript is original, has never been published, or under the consideration for publication elsewhere (in part or in whole).

References

- [1] G De Riu A Bay A Tullio Pneumosinus Dilatans Frontal Is: A Case Report.
- [2] M.L. Urken, P.M. Som, W. Lawson, D. Edelstein, A.L. Weber, H.F. Biller, Abnormally large frontal sinus. II. Nomenclature, pathology, and symptoms, *Laryngoscope* 97 (5) (1987) 606–611, <https://doi.org/10.1288/00005537-198705000-00014>.
- [3] M. Mauri, C. Oliveira De Oliveira, G. Franche, Pneumosinus dilatans of the maxillary sinus: case report, *Ann. Otol. Rhinol. Laryngol.* 109 (3) (2000) 278–280, <https://doi.org/10.1177/000348940010900308>.
- [4] F. Tovi, A. Gatot, D.M. Fliss, Air cyst of the maxillary sinus (pneumosinus dilatans, pneumocoele), *J. Laryngol. Otol.* 105 (8) (1991) 673–675, <https://doi.org/10.1017/S0022215100116998>.
- [5] S. Doucette-Preville, A. Tamm, J. Khetani, E. Wright, D. Emery, Maxillary air cyst, *J. Radiol. Case Rep.* 7 (12) (2013) 10–15, <https://doi.org/10.3941/jrcr.v7i12.1542>.
- [6] Ranjan Nayak Kailesh Pujary Balakrishnan Ramaswamy G Mahesh DS Dechu Muddaiah Anterior Pneumatization of the Maxillary Sinus-Presenting as a Facial Swelling. Vol 59.
- [7] I. Braverman, Pneumocele of the maxillary sinus with orbital and trigeminal nerve involvement: case report and review of the literature, *J. Otolaryngol. Head Neck Surg.* 38 (2) (2009), <https://doi.org/10.2310/7070.2009.080048>.
- [8] B.M. Teh, C. Hall, S.W. Chan, Pneumosinus dilatans, pneumocoele or air cyst? A case report and literature review, *J. Laryngol. Otol.* 126 (1) (2012) 88–93, <https://doi.org/10.1017/S0022215111002283>.
- [9] R.K. Weber, W. Hosemann, Comprehensive review on endonasal endoscopic sinus surgery, Dec 22, *GMS Curr. Top Otorhinolaryngol. Head Neck Surg.* 14 (2015) Doc08, <https://pubmed.ncbi.nlm.nih.gov/26770282>.
- [10] S. Suzuki, H. Yasunaga, H. Matsui, K. Fushimi, K. Kondo, T. Yamasoba, Complication rates after functional endoscopic sinus surgery: analysis of 50,734 Japanese patients, *Laryngoscope* 125 (8) (2015) 1785–1791. Aug.
- [11] R.A. Agha, T. Franchi, C. Sohrabi, G. Mathew, A. Kerwan, The SCARE 2020 guideline: updating consensus surgical CAse REport (SCARE) guidelines, *Int. J. Surg.* 84 (2020) 226–230. Dec.