

Laparoscopic-Assisted Transvaginal Approach for Sigmoidectomy and Rectocolpopexy

Jaime E. Sanchez, MD, Sowsan H. Rasheid, MD, Beth R. Krieger, MD,
Jared C. Frattini, MD, Jorge E. Marcet, MD

ABSTRACT

Background and Objectives: Laparoscopic-assisted colonic resection has been well described for multiple surgical indications. This typically requires an abdominal incision for specimen removal that is associated with the majority of postoperative pain. We describe the first laparoscopic-assisted transvaginal approach for sigmoidectomy and rectocolpopexy for the treatment of rectal prolapse.

Methods: Mobilization of the sigmoid colon was performed laparoscopically using a 12-mm vaginal port and 3 additional 5-mm abdominal ports. A laparoscopic stapler was used through the vaginal port to transect the distal sigmoid colon. The specimen was subsequently externalized through the colpotomy to complete the resection and prepare the remaining bowel for intracorporeal, end-to-end, stapled anastomosis. The colpotomy was then repaired, and the colorectal anastomosis and rectocolpopexy were completed laparoscopically.

Results: Sigmoidectomy and rectocolpopexy were successfully performed laparoscopically by using a transvaginal approach without the need for an abdominal incision for specimen removal. The patient had an uncomplicated postoperative course, complained of minimal pain, and was discharged home on postoperative day 3.

Conclusions: Laparoscopic-assisted transvaginal sigmoidectomy and rectocolpopexy is a feasible option that appears to be associated with little incisional pain and rapid recovery.

Key Words: Laparoscopy, Transvaginal, Sigmoidectomy, Rectocolpopexy.

INTRODUCTION

The field of minimally invasive surgery continues to advance rapidly, improving patient comfort, satisfaction, and outcomes. Laparoscopy has become a proven and often preferred method to approach even the most complex operative problems. However, the need to remove resected specimens through an abdominal incision can at times limit the advantages of this modality, especially in regard to postoperative pain and recovery. This dilemma has, in part, prompted further development of techniques, including minilaparoscopy, natural orifice transluminal endoscopic surgery (NOTES), and other less invasive methods of operating and extracting specimens from within the abdominal and pelvic cavities.¹⁻¹²

The transvaginal approach for resection of the uterus has long been used by gynecologists for hysterectomy but of late has been modified by laparoscopic surgeons for the extraction of numerous organs including the gallbladder, appendix, kidney, bladder, and colon.⁴⁻¹⁹ Moreover, both Wilson et al¹⁰ and Franklin et al¹¹ have successfully performed completely laparoscopic right hemicolectomies utilizing intracorporeal anastomosis and transvaginal specimen extraction. Nevertheless, the use of a working vaginal port during laparoscopy to reduce the number and size of abdominal incisions, as well as providing a means of large specimen extraction, has not been commonly described. Tsin et al⁹ reported their 7-year experience using culdolaparoscopy with minilaparoscopy to perform various gynecologic operations, cholecystectomies, and appendectomies with success and few complications. More recently, Lacy et al¹² have applied a similar transvaginal approach to perform a radical resection of the sigmoid colon for adenocarcinoma. Herein, we report the successful use of the laparoscopic-assisted transvaginal approach to sigmoidectomy and rectocolpopexy for treatment of rectal prolapse that highlights the feasibility and versatility of laparoscopic-assisted natural orifice surgery (LANOS).

METHODS

A 63-year-old woman presented with a 7-year history of worsening rectal prolapse associated with increasing pain

Division of Colon and Rectal Surgery, University of South Florida, Tampa, Florida, USA (all authors).

Address correspondence to: Jorge E. Marcet, MD, Department of Surgery, University of South Florida, Tampa General Hospital, Suite F-145, 1 Tampa General Circle, Tampa, Florida 33606, USA.

© 2009 by JLS, *Journal of the Society of Laparoendoscopic Surgeons*. Published by the Society of Laparoendoscopic Surgeons, Inc.

as well as incontinence of flatus and stool. She had previously undergone total abdominal hysterectomy through a Pfannenstiel incision but had no other history of abdominal or pelvic surgery. Complete evaluation demonstrated significant, full-thickness rectal prolapse and an elongated sigmoid colon. The patient was offered a laparoscopic-assisted sigmoidectomy with rectocolpopexy through a novel transvaginal approach as described below.

In the lithotomy position, the abdomen was prepped with a chlorhexidine and isopropyl alcohol solution. The inner thighs, vagina, and perineum were prepped with betadine. A 5-mm trocar was introduced into the peritoneal cavity through the umbilicus and pneumoperitoneum was obtained. Two additional 5-mm ports were placed transabdominally in the right and left lower quadrants to assist with mobilization of the colon and rectum. A 12-mm trocar was also placed transvaginally through the apex of the vagina and was used as a working port to retract the colon and introduce the laparoscopic stapler (**Figure 1A**).

The sigmoid colon and rectum were fully mobilized from peritoneal attachments in a lateral to medial direction. The rectum was further mobilized along the endopelvic fascia to the pelvic floor, and anteriorly away from the vagina as distal as possible. The rectocolpopexy sutures (0 silk) were brought into the pelvis through the vaginal port. They were placed bilaterally, first through the periosteum of the sacral promontory and then through lateral perirectal tissues and the uterosacral ligaments to have a tension-free fixation of the rectum and vagina to the sacrum. Both ends of each suture were then clipped together to hold them in place temporarily and the needles removed.

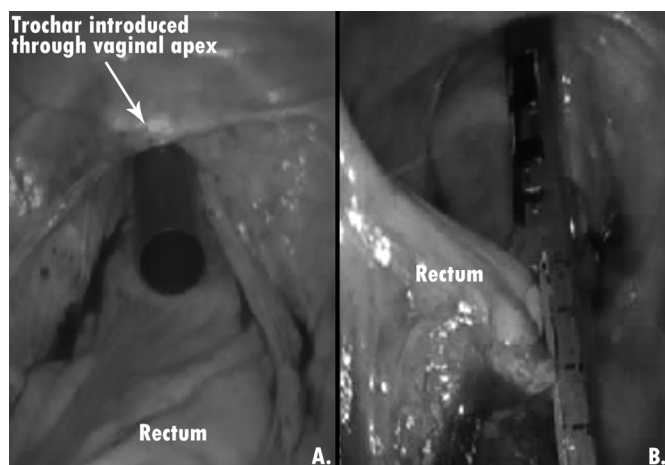


Figure 1. (A) Laparoscopic view of vaginal working port. (B) Transection of rectum with laparoscopic stapler through vaginal working port.

A 5-mm, vessel sealing device (LigaSure, Valleylab, Boulder, CO) was used to divide the mesentery of the sigmoid and rectosigmoid colon, keeping the inferior mesenteric and superior rectal vessels intact. The rectosigmoid was transected by using a laparoscopic stapler (ENDO GIA, Covidien, Mansfield, MA) placed through the vaginal port (**Figure 1B**). A surgical sponge was used to replace the vaginal trocar to retain pneumoperitoneum while extending the colpotomy, as well as to retain distention of the vagina and avoid thermal injury.

The stapled end of the proximal colon was grasped with a long Allis clamp, which was passed transvaginally, and the colon brought into the vagina. The vaginal introitus was then opened with a Parks retractor and the redundant colon externalized (**Figure 2**) and transected. Laparoscopic visualization was maintained throughout this process.

The proximal end of the colon was prepared for intracorporeal reanastomosis by introducing the anvil of a 28-mm, end-to-end anastomosis stapler (EEA, Covidien, Mansfield, MA) and securing it with a 2-0 polypropylene, purse-string suture. The bowel was then returned into the abdomen and the colpotomy closed with running 2-0 polyglactin suture. After pneumoperitoneum was re-established, the EEA stapler was introduced into the rectum and an intracorporeal anastomosis performed. It was then air tested and no leak was evident.

The rectocolpopexy was completed by tying the previously placed sutures intracorporeally. The operation was then concluded following the evacuation of the CO₂ gas from within the peritoneal cavity and the removal of the

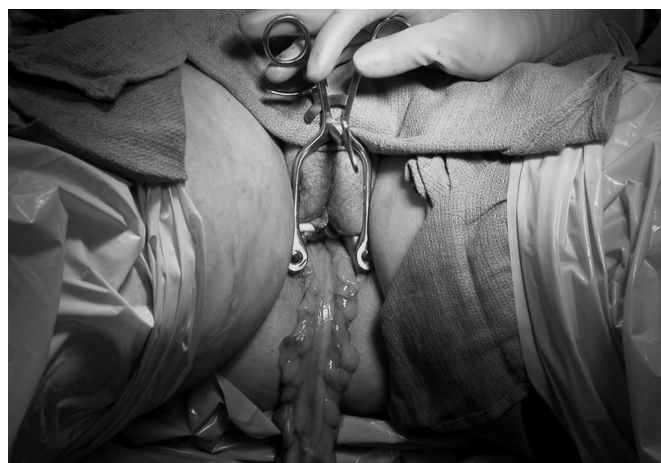

Figure 2. Transvaginal delivery of sigmoid colon for extracorporeal resection.

laparoscopic trocars. A loose packing of gauze, impregnated with sulfanilamide cream, was placed into the vagina at the completion of the case and removed the following day.

RESULTS

We successfully performed a laparoscopic-assisted sigmoidectomy and rectocolpopexy through a transvaginal approach to repair rectal prolapse in a 63-year-old woman. The patient tolerated the procedure well, complained of minimal postoperative pain, and did not require narcotics beyond the day of the operation. She was started on a diet the morning after the operation and was discharged from the hospital on postoperative day 3 following the return of bowel function. At 3-month follow-up, she remained without prolapse and had had no complications.

DISCUSSION

The use of a transvaginal approach to LANOS is now within the reach of the well-trained laparoscopic surgeon. In our experience, total operating time is equivalent to traditional laparoscopic-assisted surgeries, because closure of the colpotomy requires no more time than closure of an abdominal incision. However, from a technical standpoint, it should be noted that the actions performed through the transvaginal port are often mirror imaged when one is working in the pelvis. Nonetheless, we believe that the use of a working transvaginal port only serves to enhance an operator's ability and have not found it to be awkward.

The largest experience of laparoscopic colorectal resections with transvaginal specimen extraction to date has been published by Ghezzi et al.¹³ and Boni et al.¹⁵ They describe their use of this technique in the treatment of endometriosis and indicate that extraction of specimens through the vagina appears to be safe and without increased risk of major complications, such as pelvic infection or vaginal fistula. However, such complications must be anticipated and addressed expeditiously when they do occur. Complications necessitating reoperation, as may occur with anastomotic leak, should be approached in the same manner as following any traditional laparoscopic surgery.

CONCLUSION

In the emerging era of natural orifice surgery, patients are willing to accept novel surgical techniques if they provide

superior outcomes and reduce pain and scarring.^{19,20} The use of a working transvaginal port in LANOS offers a unique solution for applying minimally invasive techniques to operations that require larger instruments and abdominal incisions for specimen removal. As LANOS continues to evolve, the laparoscopic-assisted transvaginal approach to abdominal and pelvic surgery should be further examined as a practical option for the improvement of patient care and satisfaction. To this end, we are currently performing and evaluating laparoscopic-assisted transvaginal colonic resections for various indications in a prospective manner and will continue to report our results.

References:

1. Mamazza J, Schlachta CM, Seshadri PA, Cadeddu MO, Poulin EC. Needlescopic surgery. A logical evolution from conventional laparoscopic surgery. *Surg Endosc.* 2001;15:1208–1212.
2. Alponat A, Cubukcu A, Gonullu N, Canturk Z, Ozbay O. Is minisite cholecystectomy less traumatic? Prospective randomized study comparing minisite and conventional laparoscopic cholecystectomies. *World J Surg.* 2002;26:1437–1440.
3. Santoro E, Agresta F, Veltri S, Mulieri G, Bedin N, Mulieri M. Minilaparoscopic colorectal resection: a preliminary experience and an outcomes comparison with classical laparoscopic colon procedures. *Surg Endosc.* 2007 Oct 18. [Epub ahead of print].
4. Branco Filho AJ, Noda RW, Kondo W, Kawahara N, Rangel M, Branco AW. Initial experience with hybrid transvaginal cholecystectomy. *Gastrointest Endosc.* 2007;66:1245–1248.
5. Ramos AC, Murakami A, Galvao Neto M, et al. NOTES transvaginal video-assisted cholecystectomy: first series. *Endoscopy.* 2008;40:572–575.
6. Zorron R, Filgueiras M, Maggioni LC, Pombo L, Lopes Carvalho G, Lacerda Oliveira A. NOTES. Transvaginal cholecystectomy: report of the first case. *Surg Innov.* 2007;14:279–283.
7. Zorron R, Maggioni LC, Pombo L, Oliveira AL, Carvalho GL, Filgueiras M. NOTES transvaginal cholecystectomy: preliminary clinical application. *Surg Endosc.* 2008;22:542–547.
8. Zorron R, Soldan M, Filgueiras M, Maggioni LC, Pombo L, Oliveira AL. NOTES: transvaginal for cancer diagnostic staging: preliminary clinical application. *Surg Innov.* 2008;15:161–165.
9. Tsin DA, Colombero LT, Lambeck J, Manolas P. Minilaparoscopy-assisted natural orifice surgery. *JLS.* 2007;11:24–29.
10. Wilson JI, Dogiparthi KK, Hebblethwaite N, Clarke MD. Laparoscopic right hemicolectomy with posterior colpotomy for transvaginal specimen retrieval. *Colorectal Dis.* 2007;9:662.
11. Franklin ME Jr., Kelley H, Kelley M, et al. Transvaginal extraction of the specimen after total laparoscopic right hemico-

- lectomy with intracorporeal anastomosis. *Surg Laparosc Endosc Percutan Tech*. 2008;18:294–298.
12. Lacy AM, Delgado S, Rojas OA, Almenara R, Blasi A, Llach J. MA-NOS radical sigmoidectomy: report of a transvaginal resection in the human. *Surg Endosc*. 2008;22:1717–1723.
13. Boni L, Tenconi S, Beretta P, et al. Laparoscopic colorectal resections with transvaginal specimen extraction for severe endometriosis. *Surg Oncol*. 16(suppl 1):S157–S160, 2007.
14. Yuan LH, Chung HJ, Chen KK. Laparoscopic radical cystectomy combined with bilateral nephroureterectomy and specimen extraction through the vagina. *J Chin Med Assoc*. 2007;70:260–261.
15. Ghezzi F, Cromi A, Ciravolo G, Rampinelli F, Braga M, Boni L. A new laparoscopic-transvaginal technique for rectosigmoid resection in patients with endometriosis. *Fertil Steril*. 2007.
16. Zornig C, Mofid H, Emmermann A, Alm M, von Waldenfels HA, Felixmuller C. Scarless cholecystectomy with combined transvaginal and transumbilical approach in a series of 20 patients. *Surg Endosc*. 2008;22(6):1427–1429.
17. Breitenstein S, Dedes KJ, Bramkamp M, Hess T, Decurtins M, Clavien PA. Synchronous laparoscopic sigmoid resection and hysterectomy with transvaginal specimen removal. *J Laparoendosc Adv Surg Tech A*. 2006;16:286–289.
18. Bessler M, Stevens PD, Milone L, Parikh M, Fowler D. Transvaginal laparoscopically assisted endoscopic cholecystectomy: a hybrid approach to natural orifice surgery. *Gastrointest Endosc*. 2007;66:1243–1245.
19. Gill IS, Cherullo EE, Meraney AM, Borsuk F, Murphy DP, Falcone T. Vaginal extraction of the intact specimen following laparoscopic radical nephrectomy. *J Urol*. 2002;167:238–241.
20. Varadarajulu S, Tamhane A, Drelichman ER. Patient perception of natural orifice transluminal endoscopic surgery as a technique for cholecystectomy. *Gastrointest Endosc*. 2008;67:854–860.