

Received: 2016.11.23  
Accepted: 2017.03.15  
Published: 2017.05.22

ISSN 1941-5923  
© Am J Case Rep, 2017; 18: 563-567  
DOI: 10.12659/AJCR.902510

## Normalization of Diffuse ST-Depression with aVR Elevation After Rehydration in a Patient with Severe Aortic Stenosis

Authors' Contribution:  
Study Design A  
Data Collection B  
Statistical Analysis C  
Data Interpretation D  
Manuscript Preparation E  
Literature Search F  
Funds Collection G

ABCDEF 1 **Sachin R. Patel**  
ABDE 1 **Vikas Patel**  
ACDE 2 **Brittany Clark**  
EF 2 **George Rust**

1 Department of Internal Medicine, Florida State University, College of Medicine, Tallahassee, FL, U.S.A.  
2 Department of Clinical Sciences, Florida State University, College of Medicine, Tallahassee, FL, U.S.A.

**Corresponding Author:** Sachin R. Patel, e-mail: [sachin.patel@med.fsu.edu](mailto:sachin.patel@med.fsu.edu) or [sachinpatel18@gmail.com](mailto:sachinpatel18@gmail.com)  
**Conflict of interest:** None declared

**Patient:** Male, 53  
**Final Diagnosis:** Myocardial infarction  
**Symptoms:** Unresponsiveness  
**Medication:** —  
**Clinical Procedure:** Coronary artery bypass graft • intra-aortic balloon pump • aortic valve replacement • left ventricular assist device  
**Specialty:** Cardiology





**Objective:** Unusual clinical course  
**Background:** Isolated ST elevation in lead aVR in combination with global ST depression with normalization after rehydration is a unique electrocardiographic pattern that is associated with a broad range of diagnoses. Its association with left main coronary artery disease and other acute coronary syndromes suggest the need for early and aggressive cardiac evaluation.

**Case Report:** A 53-year-old man presented with altered mental status and loss of consciousness. He was unresponsive, hypotensive, tachycardiac, and diaphoretic. An initial ECG showed diffuse ST depression with isolated ST elevation in lead aVR, and initial troponin levels were negative. After rehydration, a repeat ECG showed sinus rhythm without ischemic changes. An emergent echocardiogram showed severe aortic stenosis and global hypokinesis. Repeat troponin results were elevated. The patient had 2 subsequent cardiac arrests. Emergent cardiac catheterization showed an occluded right coronary artery with collaterals and complete occlusion of the LAD. Urgent intra-aortic balloon pump was placed, followed by coronary artery bypass graft, aortic valve replacement, and a placement of a left ventricular assist device. Despite maximal hemodynamic support, the patient died after cardiac arrest due to massive myocardial infarction.

**Conclusions:** Normalization of diffuse ST depression with isolated aVR ST elevation on electrocardiography with improvement in clinical and hemodynamic status through fluid resuscitation can mask a stuttering myocardial infarction given its association with left main coronary artery disease and partial right coronary artery occlusion.

**MeSH Keywords:** Aortic Stenosis, Subvalvular • Coronary Artery Bypass • Coronary Artery Disease • Electrocardiography • Myocardial Infarction • Shock, Cardiogenic

**Full-text PDF:** <http://www.amjcaserep.com/abstract/index/idArt/902510>

 1399  —  4  12



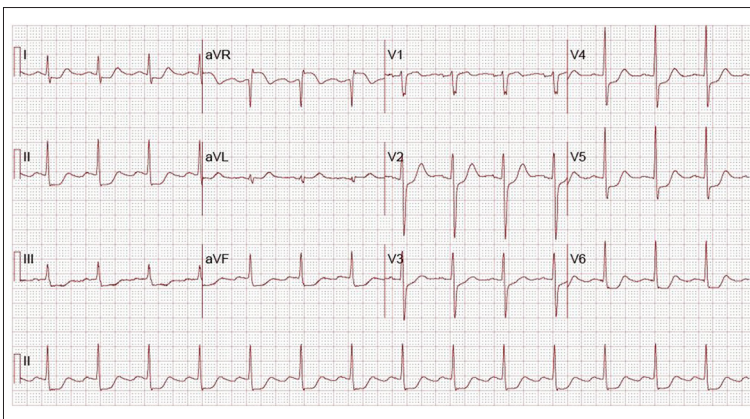
## Background

Electrocardiographic findings of ST elevation in at least 2 leads along with positive cardiac biomarkers and hemodynamic or electrical instability are considered the standard for emergent cardiac catheterizations [1]. While isolated ST elevation in lead aVR has largely been disregarded in the clinical setting, it has been shown to be associated with acute left anterior descending artery occlusion [2,3]. Additionally, when combined with global ST depression across other leads, it has been reported as a “classic” for left main coronary artery disease. Here, we discuss this electrocardiographic finding in a patient who presented with hypotension, loss of consciousness, initial negative troponin levels, and transient resolution of the electrocardiographic pattern after initial resuscitative measures. The patient ultimately died from cardiac arrest due to massive myocardial infarction.

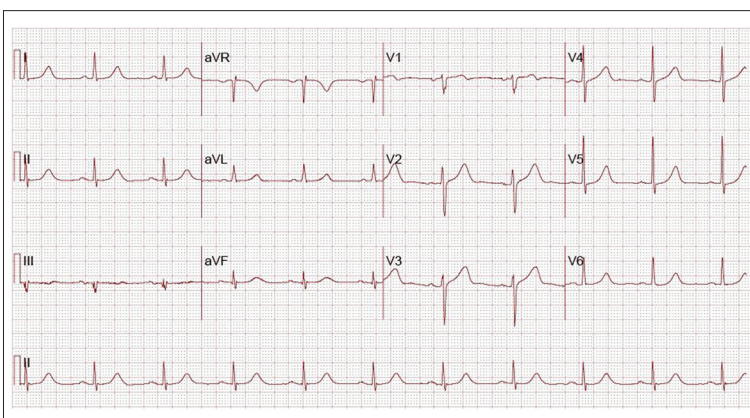
## Case Report

A 53-year-old man with unknown medical history was admitted with an altered mental status and loss of consciousness. On presentation, he was found to be unresponsive, hypotensive,

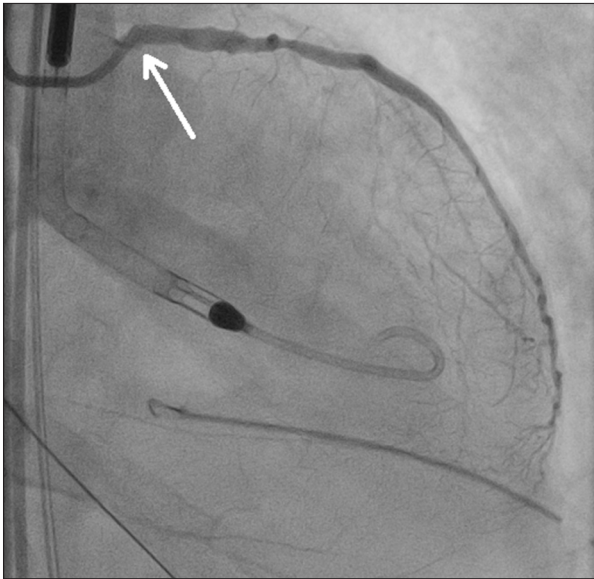
tachycardiac, and diaphoretic. On physical examination, his blood pressure was 78/52 mm/Hg, temperature was 36.3°C, heart rate was 80 beats/min, and respiratory rate was 26 breaths/min with an oxygen saturation of 100% on a nonrebreather mask. He had a weak femoral pulse, cold extremities, a systolic crescendo-decrescendo murmur radiating to the carotids, and bilateral rhonchi in basal lung fields. Laboratory data showed lactic acidosis, and initial troponins were normal. An initial electrocardiogram (ECG) showed diffuse ST depression with isolated ST elevation in lead aVR (Figure 1). Code STEMI was called and supportive care initiated. In addition, the patient received 2 liters of normal saline for initial fluid resuscitation, with improvement in blood pressure. Emergent echocardiography showed severe aortic stenosis with a valve area of 1.0 cm<sup>2</sup> and global hypokinesis with an ejection fraction of 35%. Cardiogenic shock was considered secondary to severe aortic stenosis causing low cardiac output, and it was thought that aggressive fluid resuscitation would improve the isolated ST elevation with diffuse ST depression. A repeat ECG confirmed normal sinus rhythm without ischemic changes (Figure 2). Subsequently, the patient was more alert while on ventilator support without sedation, with improvement in urine output, and he performed well in a spontaneous breath trial. Therefore, emergent cardiac catheterization was delayed.



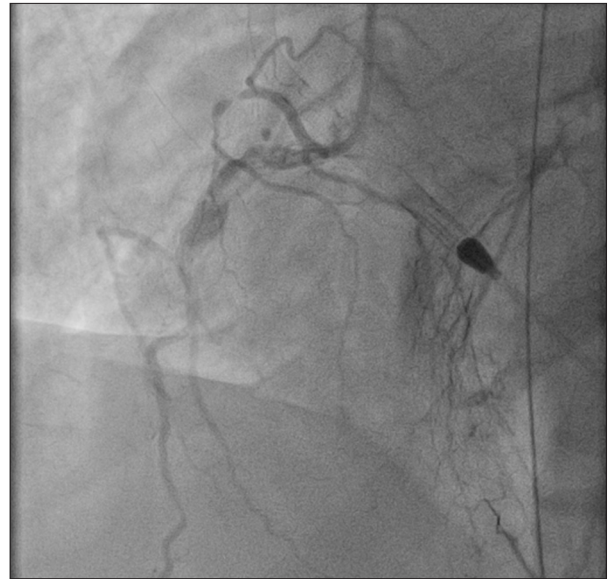
**Figure 1.** Initial 12-lead electrocardiogram shows a normal sinus rhythm at rate 86 beats/min, normal axis, normal QRS length, normal QTc at 458 ms, and diffuse ST-depression in all limb and precordial leads, with concordant isolated lead aVR ST elevation.



**Figure 2.** Subsequent 12-lead electrocardiogram 6 h after admission and after aggressive intravenous fluid resuscitation. Normal sinus rhythm with mild QT prolongation with no ST segment or T wave changes.



**Figure 3.** Right anterior oblique, cranial projection. Cardiac catheterization shows the left circumflex that was visualized into an obtuse marginal artery. The white arrow shows where the left anterior descending artery bifurcates off the left main, which is not visualized with contrast due to complete occlusion in mid-segment. The left main coronary trunk was without disease. Image taken from Tallahassee Memorial Healthcare, Medical Records Database.



**Figure 4.** Cardiac catheterization showing the right coronary artery with collaterals to the left anterior descending artery. Image taken from Tallahassee Memorial Healthcare, Medical Records Database.

In the Intensive Care Unit, medical and supportive care continued. Twelve hours after admission, the third troponin level increased to 152 ng/mL. Subsequently, the patient experienced 2 cardiac arrests with successful resuscitation. Emergent cardiac catheterization showed a partially occluded middle right coronary artery with collaterals into the left anterior descending (LAD) artery, 100% occlusion of the mid-segment of the LAD, and 50% occlusive disease in the remainder of the LAD (Figures 3, 4). An intra-aortic balloon pump was urgently placed followed by coronary artery bypass graft, aortic valve replacement, and left ventricular assist device placement. On postoperative day 3, despite maximal hemodynamic support and cardiopulmonary resuscitation, the patient died from cardiac arrest due to massive myocardial infarction.

## Discussion

Patients with either acute coronary syndrome or valvular heart disease can present with altered mental status with hemodynamic instability, requiring detailed history taking, a thorough physical examination, and a scrupulous review of laboratory and imaging findings routinely. While ST elevation in other leads would prompt emergent cardiac catheterization, global ST depression is less specific. Most reports mentioning cases of ST elevation in lead aVR emphasize the prognostic importance

of lead aVR or explain the lack of utility of lead aVR in clinical medicine owing to the absence of a parallel lead [1–3]. Thus, isolated ST elevation in lead aVR may be difficult to interpret, and when it occurs with global ST depression, it may be interpreted as merely the opposite reflection of ST depression in leads I, II, V5, and V6. Lead aVR is pointed towards the right shoulder electrically, with a vector pointing towards the thin wall of the right ventricle outflow and the interventricular basal septum. The LAD supplies blood through the septal branches to the interventricular basal septum. Transmural infarction of this basal septum could produce ST elevation in lead aVR [1–6].

When combined with global ST depression in other leads, ST elevation in lead aVR has been classically reported to be associated with left main coronary occlusion, proximal LAD occlusion, or acute coronary syndrome with diffuse multi-vessel disease [1]. It is theorized that ST elevation in anterior acute myocardial infarction may be associated with LAD occlusion proximal to the first septal perforator branch, although large-scale studies would be needed to confirm the specificity of this finding. More importantly, ST elevation in lead aVR is a “red flag” for increased risk of 30-day mortality independent of ST changes in other leads, and it has been reported to confer a 23.5% increased risk of mortality in patients with anterior wall acute myocardial infarction [1].

The differential diagnosis of ST elevation in lead aVR and diffuse ST depression includes, but is not limited to, unstable angina in 3-vessel disease, acute pulmonary embolism, arrhythmias,

severe aortic stenosis, atrioventricular dissociation in ventricular tachycardia, left ventricular hypertrophy, atrioventricular nodal tachycardia, cardiomyopathies, re-entry tachycardia with a paraseptal accessory pathway, generalized tonic clonic seizures, left main coronary artery obstruction, and acute anterior wall infarction due to proximal LAD occlusion [7–10]. While this electrocardiographic finding is a predictor of mortality, it is used in the context of clinical findings, hemodynamic instability, and the symptoms reported by individual patients. In fact, some patients with this electrocardiographic finding have no significant ischemia. Knotts et al. assessed 133 patients with ST elevation in lead aVR and diffuse ST depression and reported that only 28% of these patients experienced non-ST elevation myocardial infarction. Additionally, 57 patients underwent cardiac catheterization, and 26% of these patients demonstrated no significant obstructive coronary artery disease. In fact, diffuse ST-depression with ST elevation in lead aVR is not the most common ECG pattern in patients with left main coronary artery obstruction [10].

Interestingly, in our case, with aggressive fluid resuscitation, the ECG findings normalized and hemodynamic and mental status improved. One explanation for the ECG normalization is that rehydration increased cardiac output in an already preload-dependent system with decompensated aortic stenosis, which caused low coronary perfusion and high oxygen demand in a patient without coronary artery disease [11]. Another explanation is that non-ST-segment elevation myocardial infarctions may present after symptoms have improved and the ECG may not reflect active ischemia but rather preconditioning, reperfusion injury, or posts ischemic changes. Therefore, non-ST elevation myocardial infarction can be associated with a normal ECG or dynamic change as opposed to an abnormal baseline ECG, as in the case of our patient [12]. There may have been technical and/or random errors in acquiring the repeat ECGs, although this is unlikely.

There are currently no clinical guidelines for managing patients with isolated ST elevation in lead aVR on initial ECG with resolved findings on repeat ECG after intravenous fluid

resuscitation. Additionally, there are no clinical guidelines for managing the different causes of ST elevation in lead aVR in a patient with severe aortic stenosis. In fact, severe aortic stenosis itself can manifest as diffuse ST depression with reciprocal changes in lead aVR related to left ventricular hypertrophy, increased left ventricular end-diastolic pressure, and decreased subendocardial blood flow [7–11]. A reasonable strategy for any such patient who presents with shock and global ST depression along with isolated ST elevation in lead aVR might be emergent triage based on clinical findings, bedside transthoracic echocardiogram prior to admission, and, perhaps, treatment with glycoprotein IIb/IIIa inhibitors in anticipation of emergent coronary artery bypass grafting. Further research is needed to determine optimal treatment protocols. However, it is clear that patients with such electrocardiographic findings are at increased risk for 30-day mortality and can benefit from an early invasive strategy.

## Conclusions

Diffuse ST depression with isolated aVR ST elevation with normalization after rehydration is a high-risk, unique, and commonly mistaken electrocardiographic finding. It is possible that normalization of this high-risk electrocardiographic finding with improvement in both clinical and hemodynamic status after rehydration can indicate acute severe aortic stenosis with poor cardiac perfusion or mask a stuttering myocardial infarction, or be associated with both. Regardless, urgent coronary artery bypass grafting with aortic valve replacement may be useful. Our case report will increase awareness and educate physicians-in-training, junior physicians, medical students, and healthcare practitioners on the diagnosis and management of this high-risk electrocardiographic finding.

## Conflict of interest

All of the authors certify our affiliations and have no disclosures to report.

## References:

1. Wong C, Gao W, Stewart R et al: aVR ST elevation: An important but neglected sign in ST elevation acute myocardial infarction. *Eur Heart J*, 2010; 31(15): 1845–53
2. de Winter R, Verouden N, Wellens H, Wilde A: A new ECG sign of proximal LAD occlusion. *N Engl J Med*, 2008; 359(19): 2071–73
3. Pahlm U, Pahlm O, Wagner G: The standard 11-lead ECG. *J Electrocardiol*, 1996; 29: 270–74
4. Szymański F, Grabowski M, Filipiak K et al: Admission ST-segment elevation in lead aVR as the factor improving complex risk stratification in acute coronary syndromes. *Am J Emerg Med*, 2008; 26(4): 408–12
5. Yan A, Yan R, Kennelly B et al: Relationship of ST elevation in lead aVR with angiographic findings and outcome in non-ST elevation acute coronary syndromes. *Am Heart J*, 2007; 154(1): 71–78
6. Yamaji H, Iwasaki K, Kusachi S et al: Prediction of acute left main coronary artery obstruction by 12-lead electrocardiography. *J Am Coll Cardiol*, 2001; 38(5): 1348–54
7. Deshpande A: ST-segment elevation: Distinguishing ST elevation myocardial infarction from ST elevation secondary to nonischemic etiologies. *World J Cardiol*, 2014; 6(10): 1067–79
8. George A, Arumugham PS, Figueredo VM: aVR – the forgotten lead. *J Clin Exp Cardiol*, 2010; 15(2): e36–44
9. Kim E, Birnbaum Y: Acute coronary syndromes presenting with transient diffuse ST segment depression and ST segment elevation in lead aVR not caused by “Acute left main coronary artery occlusion”: Description of two cases. *Ann Noninvasive Electrocardiol*, 2012; 18(2): 204–9

10. Knotts R, Wilson J, Kim E et al: Diffuse ST depression with ST elevation in aVR: Is this pattern specific for global ischemia due to left main coronary artery disease? *J Electrocardiol*, 2013; 46(3): 240–48
11. Huang T-C, Lee M-K, Lin S-J et al: Diffuse ST-segment depression with ST-segment elevation in lead aVR in 12-lead electrocardiography may indicate ischemic change of severe aortic stenosis. *Acta Cardiologica Sinica*, 2015; 31(5): 449–52
12. Birnbaum Y, Bayés de Luna A, Fiol M et al: Common pitfalls in the interpretation of electrocardiograms from patients with acute coronary syndromes with narrow QRS: A consensus report. *J Electrocardiol*, 2012; 45(5): 463–75