

## Original Article

Heiko Sorg\*, Eberhard Grambow, Erik Eckl and Brigitte Vollmar

# Oxytocin effects on experimental skin wound healing

<https://doi.org/10.1515/iss-2017-0033>

Received July 1, 2017; accepted July 14, 2017; previously published online August 8, 2017

**Abstract**

**Objective:** Oxytocin (OXY) has significant effects on mammalian behavior. Next to its role in lactation and social interactions, it is described to support better wound healing as well. However, direct OXY effects on wound healing and the regeneration of the microvascular network are still not clarified. We therefore examined the effects of OXY and an OXY receptor antagonist [atosiban (ATO)] on skin wound healing, focusing on epithelialization and neovascularization.

**Methods:** Skin wound healing has been assessed using intravital fluorescence microscopy in a model of full dermal thickness wounds in the dorsal skin fold chamber of hairless mice. Animals received repetitive low or high doses of OXY or ATO. Morphological and cellular characterization of skin tissue repair was performed by histology and *in vitro* cell assays.

**Results:** The assessment of skin tissue repair using this therapy regimen showed that OXY and ATO had no major influence on epithelialization, neovascularization, wound cellularity, or inflammation. Moreover, OXY and ATO did neither stimulate nor deteriorate keratinocyte or fibroblast migration and proliferation.

**Conclusion:** In summary, this study is the first to demonstrate that OXY application does not impair skin wound healing or cell behavior. However, until now, the used transmitter system seems not to be clarified in detail, and it might be proposed that it is associated with the stress response of the organism to various stimuli.

**Keywords:** atosiban; emotion; epithelialization; intravital fluorescence microscopy; skin fold chamber.

**Abbreviations:** ATO, atosiban; bFGF, basic fibroblast growth factor; CAE, chloroacetate esterase; FMD, functional microvascular density; HD, high dose; LD, low dose; OXY, oxytocin; RBCV, red blood cell velocity.

## Introduction

Skin wound healing is a well-orchestrated survival mechanism that can be influenced by various circumstances leading to a better or worse course of healing [1, 2]. Recently, there is also mounting evidence that psychological effects (i.e. stress, social support, positive affect, and environmental enrichment) might also interact with wound healing [3]. The hormone oxytocin (OXY) is best known for its role in lactation, parturition, and uterine contraction. However, much research work has been done on its peripheral psychosocial roles and effects not directly related to gestation or reproduction [4–6]. OXY is a nonapeptide that is synthesized in neurosecretory cells of the supraoptic and paraventricular nuclei of the hypothalamus. From there, it is transported via axons to the neuronal part of the pituitary gland and then stored and released, by touch and warmth, as needed [7]. OXY has significant effects on mammalian behavior, especially for emotional as well as social bonding in relationships and sexuality [5, 7–11]. Additionally, different animal models proved that OXY supported better social interactions (i.e. less stress), which were associated with overall better healing performances [12, 13]. If applied repetitively, the effects on other transmitter systems could demonstrate long-lasting effects that show interaction in both growth and healing actions [7, 12–14]. Herein, it could be demonstrated that OXY application in rats leads to an acute anti-inflammatory response [15]. In different *in vitro* assays, it could also be seen that it acts as an antioxidant substance [16] and stimulates the proliferation of osteoblasts, pituitocytes, blastocysts, myofibroblasts, and dermal as well as malignant endothelial cells [17–20]. However, its direct

\*Corresponding author: Heiko Sorg, Institute for Experimental Surgery, University Medicine Rostock, Schillingallee 69a, 18057 Rostock, Germany; and Department of Plastic, Reconstructive and Aesthetic Surgery, Hand Surgery, Alfried Krupp Krankenhaus, Essen, Germany, E-mail: heiko.sorg@t-online.de

Eberhard Grambow, Erik Eckl and Brigitte Vollmar: Institute for Experimental Surgery, University Medicine Rostock, Rostock, Germany

effects on physiological skin wound healing and the regeneration of the microvascular network in the skin are still not clarified in detail. Therefore, we examined the effects of OXY and atosiban (ATO), an OXY receptor antagonist, during skin wound healing in an *in vivo* animal model of full dermal thickness wounds. Skin wound healing has been further characterized by histology and immunohistochemistry as well as by different *in vitro* cell assays.

## Materials and methods

### Animals and wounding

Male homozygous SKH-1-h hairless mice (12–16 weeks old) with a body weight (bw) of 30–40 g were used in the study. The animals were housed in standard laboratories with a 12 h light-dark cycle and had free *ad libitum* access to standard laboratory food and water. The Animal Ethics Committee of the State Provincial Office of Mecklenburg-West Pomerania approved the animal experiments (permit no. LALLF M-V/TSD/7221.3-1.1-001/08) and the experiments were carried out in accordance with the permits of the Laboratory Animal Centre of the University Medicine Rostock practices and the Institutional Animal Care and Use Committee guidelines. For intravital fluorescence microscopy of skin wound healing, the dorsal skin fold chamber preparation in mice was used as described previously in detail by our group [21]. In brief, mice were anesthetized intraperitoneally with a mixture of ketamine (90 mg/kg bw; 10% ketamine; Bela-Pharm, Vechta, Germany) and xylazine (25 mg/kg bw; 2% Rompun; Bayer Health Care, Leverkusen, Germany). Two symmetrical titanium frames were implanted to sandwich the extended double layer of the skin. The creation of a full dermal thickness wound was achieved after marking the area with a standardized circular ink stamp (2.5 mm in diameter) and by removing the complete skin down to the panniculus carnosus, thus creating a wound area of 3–6 mm<sup>2</sup>. The nonwounded skin of the opposite side still consisted of epidermis, dermis, and striated skin muscle. The wounded site was covered with a removable glass coverslip incorporated in one of the titanium frames. This model allows to visualize the process of revascularization, angiogenesis, and vessel regression in the skin by means of intravital fluorescence microscopy. Additionally, this technique allows the repeated study of the continuing process of skin repair over a period of 2–4 weeks. By implantation of the two titanium frames, we could avoid wound contraction by positioning the skin in between frames and by this allowing microscopy on a plane tissue level [21].

### Experimental groups and protocol

A total of 36 animals with dermal wounds were included into the study and randomly allocated into five experimental groups. Animals received a daily intraperitoneal injection of either low-dose OXY (LD OXY; 1 mg/kg bw; n=9; Sigma-Aldrich, Steinheim, Germany) or high-dose OXY (HD OXY; 10 mg/kg bw; n=6; Sigma-Aldrich). An additional set of animals were treated with a low dose of an OXY receptor inhibitor ATO (LD ATO; Tractocile, 1 mg/kg bw; n=7; Ferring GmbH,

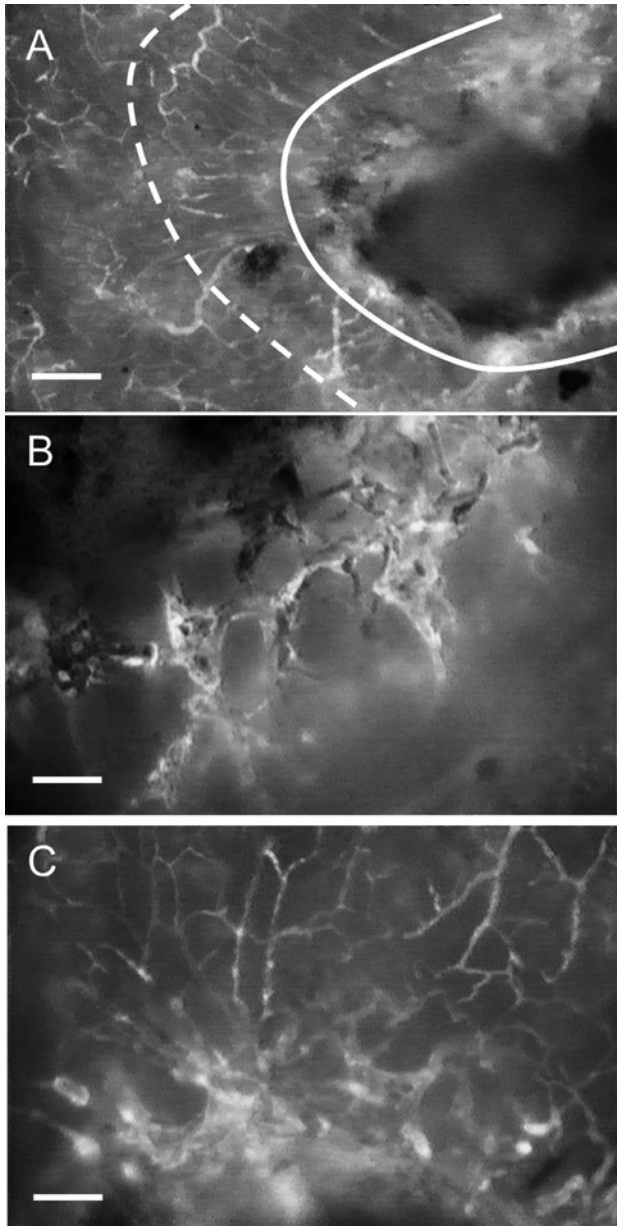
Kiel, Germany) or a high dose (HD ATO; 10 mg/kg bw; n=6; Ferring) to evaluate the effect of an OXY receptor antagonist on wound healing. Control animals received equivalent volumes of physiological saline (0.9% NaCl; 12.5 mL/kg; n=8). Animals were studied by intravital fluorescence microscopy on days 3, 6, 9, and 12 after wounding. At the end of the experiments, blood and wound tissue was collected for subsequent laboratory analysis.

### Microscopic analysis of wound repair and microcirculation

All procedures were performed in ketamine/xylazine-anesthetized mice as described above. The analysis of wound epithelialization was performed under a stereomicroscope using planimetric techniques (IC-A; Leica Microsystems GmbH, Wetzlar, Germany). Wound closure was considered complete when the entire surface area was covered with tissue. The analysis of angiogenesis and microcirculation was performed with the use of an intravital fluorescence epi-illumination microscope (Axiotech vario; Zeiss, Jena, Germany). Contrast enhancement for microvessel imaging was achieved after retrobulbar injection of 0.1 mL of 2% fluorescein isothiocyanate (FITC)-labeled dextran (molecular weight 150 kDa; Sigma Chemical, Deisenhofen, Germany) [21] and allowed the analysis of microvessel diameter, red blood cell velocity (RBCV), and functional microvessel density (FMD; Figure 1). Quantitative offline analysis of the videotaped images was performed by means of a computer-assisted image analysis system (CapImage; Dr Zeintl Software, Heidelberg, Germany). For the analysis of the different microvascular parameters, two to four consecutive areas have been used with clear visibility, which could be reached by focusing through the wound considering the three-dimensional aspect of the wound. In the respective areas, two to four different vessels, which belonged to the chosen area for the FMD measurements, have been used for the analysis of the diameter and the RBCV. The presented data show the mean values of the analyzed areas. RBCV was determined using the line-shift diagram method (modified “frame-to-frame” measurement, CapImage [22]), including the Baker-Wayland factor (1.6) for consideration of the parabolic profile of blood in microvessels [23]. FMD was defined as the total length of RBC-perfused microvessels per observation area and was given in cm/cm<sup>2</sup>. The three-dimensional aspect of the wound was considered by focusing through the depth of the wound.

### Histology and immunohistochemistry

The titanium frames were explanted on day 12 and the sandwiched skin was fixed in 4% phosphate-buffered formalin for 3 days and then embedded in paraffin. From the paraffin-embedded tissue blocks, 4 μm sections were serially cut and stained with hematoxylin-eosin (H&E) for the assessment of routine histology and for wound cellularity as a parameter for the resolution of the granulation and inflammation tissue. For this purpose, digitized images were taken in grayscale format and analyzed by the CapImage software. A random sample of a wound image was taken, and the gray level necessary to mark the complete area of the nuclei of the cells was determined. This gray value served as threshold value for the analysis of all further images. For each wound, an identical area of approximately 1.0 mm<sup>2</sup> was analyzed. Values for cellularity are given as area in mm<sup>2</sup>.



**Figure 1:** Representative intravital fluorescence microscopic images of microcirculation on day 9 of wound healing in an HD OXY-treated animal (A–C).

The process of wound healing shows distinct patterns of newly formed microvascular networks (A). At first, the regeneration of the microvascular network creates an inner circular ring of vessels at the direct wound margin (A; higher magnification in B). The inner ring is surrounded by outer radially localized vessels, supplying the vasculature within the inner circular ring (A; higher magnification in C). Dashed line (A) marks the edge of the wound at the day of wounding; continuous line indicates border between radial and circular microvessels. Scale bar, 200  $\mu\text{m}$  (A) and 80  $\mu\text{m}$  (B and C).

Leukocytes were stained with the AS-D chloroacetate esterase (CAE) technique and identified by positive staining and morphology within the granulation tissue. For CD31 staining, goat polyclonal anti-CD31 (1:50; Santa Cruz Biotechnology, Heidelberg, Germany)

was used as primary antibody at 4 °C overnight followed by exposure to a secondary antibody at room temperature (LSAB Kit; Dako Deutschland GmbH, Hamburg, Germany) according to the manufacturer's instructions. New fuchsin (Dako Deutschland) was used as chromogen. All sections were counterstained with hemalaun and examined by light microscopy (Axioskop 40; Zeiss). The numbers of CAE-positive cells were counted in five to six directly neighboring high-power fields (HPF) within the wound granulation tissue and are given as n/HPF. The wound granulation tissue as well as the initial wound margins could be exactly differentiated by a clear demarcation of the granulation tissue against the noninjured skin [21]. Microvessel density was assessed by counting vascular lumina with CD31-positive endothelial lining within the wound granulation tissue and is given as n/HPF.

### Cell proliferation assay

To evaluate the influence of OXY on cell proliferation, we assessed the proliferative activity of fibroblasts (L929; mouse) and keratinocytes (HaCaT; human) by the water-soluble tetrazolium salt (WST-1) assay (Roche Diagnostics, Mannheim, Germany). Cells were seeded into 96-well microtiter plates at a concentration of  $4 \times 10^3$  cells/well in Dulbecco's modified Eagle's medium (DMEM low-glucose; PAA, Cölbe, Germany), 10% fetal calf serum (FCS), and 1% penicillin/streptomycin supplemented with 10% FCS, basic fibroblast growth factor (bFGF; 20 ng/mL; R&D Systems GmbH, Wiesbaden, Germany), or OXY at three different concentrations of 10 nmol/mL (OXY 10; Sigma-Aldrich), 100 nmol/mL (OXY 100; Sigma-Aldrich), and 1000 nmol/mL (OXY 1000; Sigma-Aldrich). After incubation for 48 h, cells were washed with PBS and the cell proliferation reagent WST-1 was added to the cell culture medium followed by incubation for 4 h with repetitive measurements of optical density every 30 min. Sample absorbance was analyzed using a bichromatic ELISA reader (TECAN CM Sunrise; Grödig, Salzburg, Austria) at 450 nm. All experiments were performed in triplicate.

### *In vitro* cell migration assay

To evaluate the effect of OXY on cell migration, fibroblasts (L929) and keratinocytes (HaCaT) were seeded onto Petri dishes ( $5 \times 10^5$  cells/dish) and grown to confluence in DMEM (DMEM low-glucose; PAA, 10% FCS, and 1% penicillin/streptomycin). After the removal of the medium, cell monolayers were scratched with a pipette tip (10  $\mu\text{L}$ ) to produce an artificial wound. Then, cells were re-exposed to medium supplemented with either 10% FCS or OXY at three different concentrations of 10 nmol/mL (OXY 10), 100 nmol/mL (OXY 100), and 1000 nmol/mL (OXY 1000). As positive stimulant for cell migration, we used bFGF (20 ng/mL; R&D Systems). The scratch area was photographed immediately as well as 24, 48, and 72 h after scratching. The digitized images were taken in grayscale format and analyzed densitometrically by the CapImage software. A random sample of a scratch area was taken, and the gray level necessary to mark the complete area of the cells, migrated into the scratch area, was determined. This gray value served as the threshold value for the analysis of all further images. Values of cell migration into the scratch area are given as the area covered by cells in percent of the initial scratch area. All experiments were performed in triplicate.



## Statistical analysis

All data are given as means  $\pm$  SEM. Data were analyzed for normality and equal variance across groups. Results for continuous variables are presented as means  $\pm$  SEM. Because measurements of wound size were made several times on the same sample within five independent treatment groups (control, LD OXY, HD OXY, LD ATO, and HD ATO), we applied the GLM repeated-measures analysis of variance (ANOVA) for the statistical analysis of the data to test the null hypotheses about the effects of both the between-subject factor (treatment) and the within-subject factor (time). Overall statistical significance was set at  $p < 0.05$ . For clarity and rapid interpretation of data, only the significant differences for comparison between groups at a single point of time are given. Statistics were performed using the software package SigmaStat (version 10.0; Jandel Corporation, San Rafael, CA, USA).

## Results

### Wound epithelialization

In all groups, the size of the wound area was comparable, with an average area of  $4.9 \pm 0.2$  mm<sup>2</sup> immediately after wounding. Planimetric analysis of the wound area at the subsequent time points showed a continuous increase in epithelialization in the control group with a  $51 \pm 3\%$  wound coverage on day 6 and complete wound closure ( $99 \pm 1\%$ ) on day 12 after wounding (Figure 2). LD OXY or HD OXY application did not impair wound epithelialization, as wound coverage on day 6 showed  $49 \pm 2\%$  and  $45 \pm 3\%$  and an almost complete wound closure ( $99 \pm 1\%$  and  $98 \pm 2\%$ ) on day 12 (Figure 2). In LD ATO- and HD ATO-treated groups, similarly as observed in the control or OXY group, continuous epithelialization could be seen on day 6 ( $54 \pm 3\%$  and  $51 \pm 1\%$ ) and day 12 ( $98 \pm 1\%$  and  $98 \pm 2\%$ ), respectively (Figure 2).

### Microvascular parameters

As described previously [21], the neovascularization process of the healing skin follows a distinct regeneration pattern with inner and outer rings of vessels, which has been named “sola cutis se reficientis”. Whereas the inner ring consists of circular vessels directly at the wound edges of the re-epithelializing wound surface, characterized by large and irregular vessel diameters, the outer area of the newly formed epithelium is described by radially running vessels with smaller and less heterogeneous diameters. The outer radial vessels supply the circular vessels at the wound margin and

grow incessantly to the wound center until complete wound closure. In control animals, diameters of circular vessels increased until day 6 ( $\sim 18$   $\mu$ m) and showed finally a diameter reduction toward  $\sim 15$   $\mu$ m on day 12, indicating vessel remodeling and maturation (Figures 1 and 3A). Circular vessels of LD OXY, HD OXY, and LD ATO animals showed similar diameters compared to controls over the 12-day observation period. In contrast, circular vessels of HD ATO showed an increase in vessel diameter ( $\sim 22$   $\mu$ m) on day 6 (Figure 3A) but then demonstrated a maturation process to  $\sim 15$   $\mu$ m as seen in controls (Figure 3A). Radial vessels in the outer area of the re-epithelializing skin were smaller in diameter than the circular ones and could not be observed in wounds on day 3 (Figure 3B). Radial vessels did not significantly differ in diameter among groups on days 6, 9, and 12 after wounding, ranging between 11 and 12  $\mu$ m (Figure 3B).

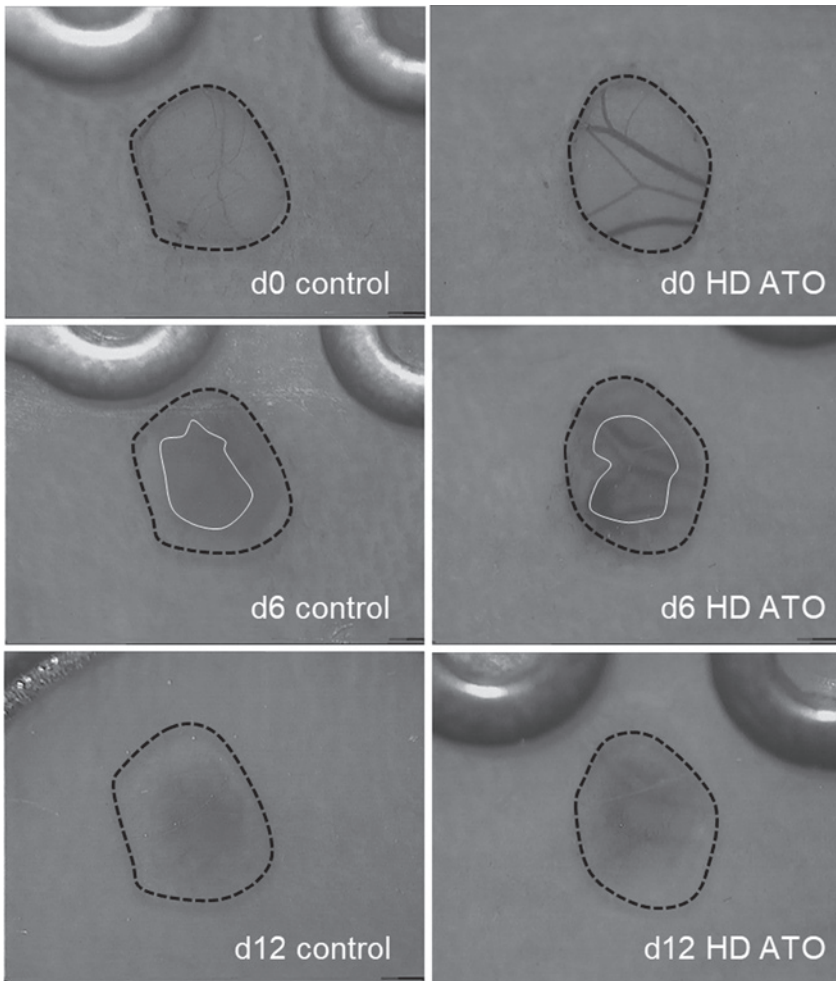
In saline-treated controls, but also in all OXY and all ATO animals, the FMD of circular vessels around the wound margin constantly decreased from  $\sim 150$  to 50 cm/cm<sup>2</sup> (Figure 3C). The FMD of radial vessels remained nearly constant in all groups with values ranging from 98 to 126 cm/cm<sup>2</sup> but has been lower in OXY and ATO groups on day 9 compared to the control group (Figure 3D).

RBCV in the newly formed microvasculature did not significantly differ among groups and days and ranged between 176 and 328  $\mu$ m/s for circular vessels and 319–448  $\mu$ m/s in radial vessels, which did not significantly differ to values in normal skin (Table 1).

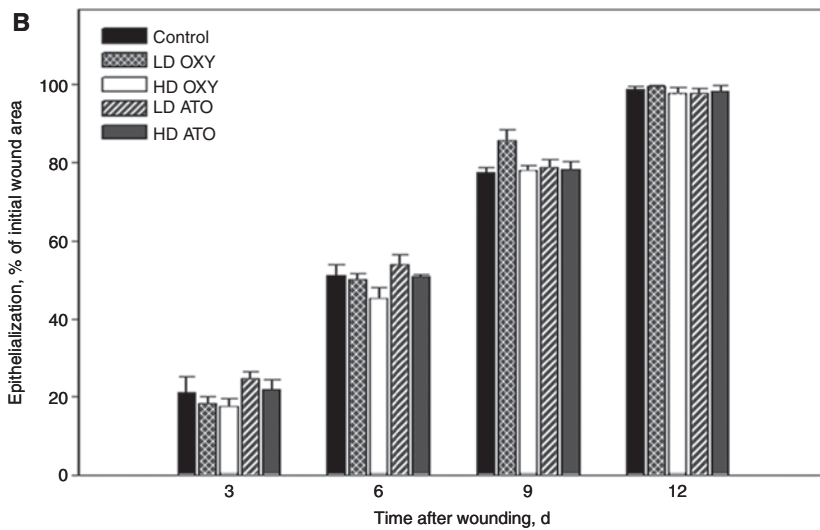
### Wound tissue histology and immunohistochemistry

The threshold-based assessment of cellularity on H&E-stained paraffin sections revealed no significant different values in wounds of animals with LD OXY and HD OXY as well as LD ATO and HD ATO when compared to controls or among each other (Figure 4). These results support the hypothesis that OXY as well as ATO do not interfere with wound granulation tissue formation during the inflammatory phase of skin wound healing (Figure 4). In line with this, the granulation tissue of OXY- or ATO-treated animals presented with decreased leukocytic tissue infiltration on day 12 after wounding, but without statistically significant differences among groups (Figure 5). Interestingly, the HD OXY group showed the lowest leukocytic infiltration in the granulation tissue. The quantification of the neovascular process in the regenerating skin has been assessed by the morphometric quantification of the expression of the

A

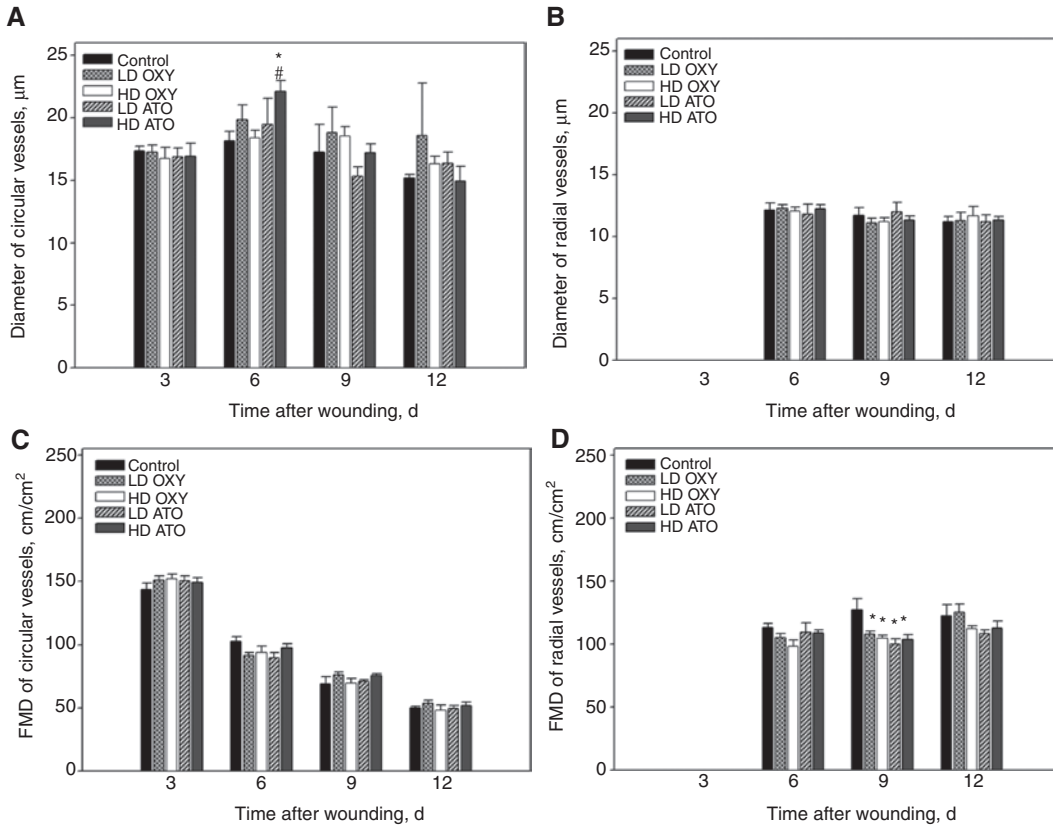


B



**Figure 2:** Analysis of wound epithelialization.

(A) Photomicroscopic images and quantitative planimetric analysis of wounds during regeneration, displaying the continuous process of wound closure with complete epithelialization on day 12. Left, skin fold chamber directly after wounding of the control group; right, wounds of the HD ATO group (dotted line, initial wound area; continuous line, wound area on day 6). (B) Quantitative analysis of wound epithelialization on days 3, 6, 9, and 12 in mice treated daily with saline (control; 0.9% NaCl; 12.5 mL/kg bw; n=8), LD OXY (1 mg/kg bw; n=9), HD OXY (10 mg/kg bw; n=6), LD ATO (1 mg/kg bw; n=7), or HD ATO (10 mg/kg bw; n=6). Data are means  $\pm$  SEM. No statistically significant differences.



**Figure 3:** Quantitative analysis of diameters ( $\mu\text{m}$ ) and FMD ( $\text{cm}/\text{cm}^2$ ) in circular vessels (A and C) and radial vessels (B and D). Animals were treated daily with saline (control; 0.9% NaCl; 12.5 mL/kg bw;  $n=8$ ), LD OXY (1 mg/kg bw;  $n=9$ ), HD OXY (10 mg/kg bw;  $n=6$ ), LD ATO (1 mg/kg bw;  $n=7$ ), or HD ATO (10 mg/kg bw;  $n=6$ ). Data are means  $\pm$  SEM. \* $p < 0.05$  vs. control; # $p < 0.05$  vs. HD OXY.

**Table 1:** Quantitative analysis of RBCV in circular and radial vessels as well as in vessels in nontraumatized skin distal of the wound (DOW) in mice on days 3–12 after wounding treated daily with saline (control; 0.9% NaCl; 12.5 mL/kg bw;  $n=8$ ), LD OXY (1 mg/kg bw;  $n=9$ ), HD OXY (10 mg/kg bw;  $n=6$ ), LD ATO (1 mg/kg bw;  $n=7$ ), or HD ATO (10 mg/kg bw;  $n=6$ ).

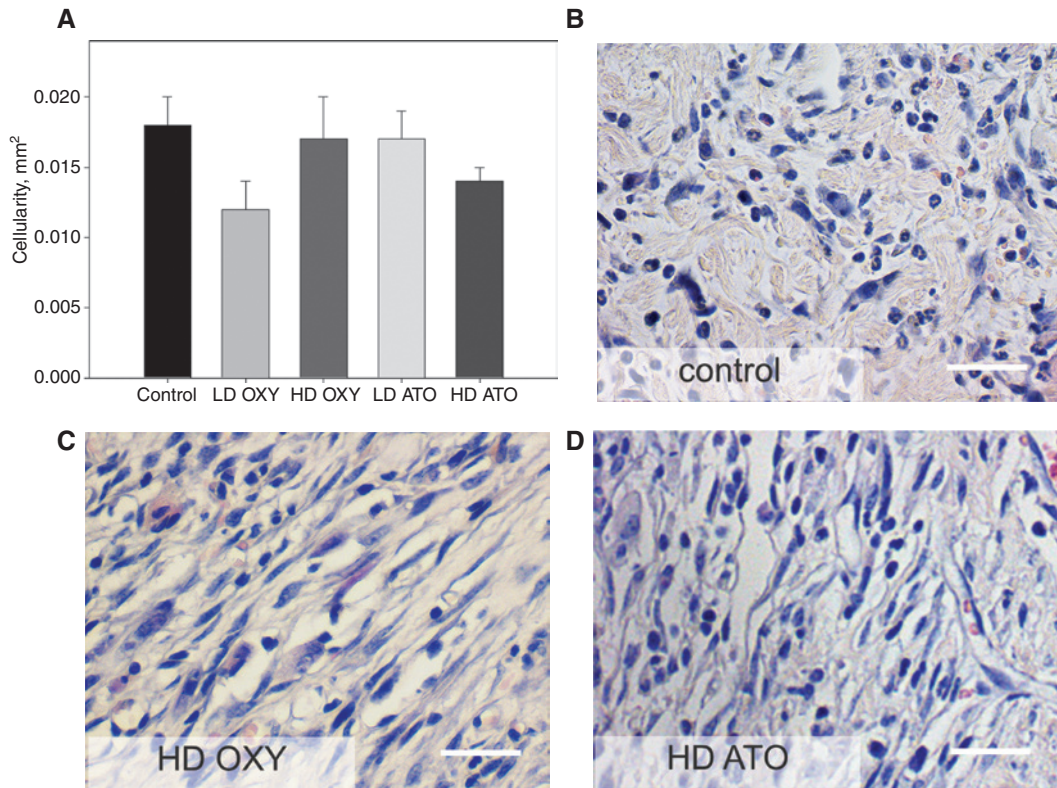
Groups	RBCV ( $\mu\text{m}/\text{s}$ )											
	Circular vessels				Radial vessels				Vessels DOW			
	Day 3	Day 6	Day 9	Day 12	Day 3	Day 6	Day 9	Day 12	Day 3	Day 6	Day 9	Day 12
Control	328 $\pm$ 28	188 $\pm$ 14	176 $\pm$ 12	179 $\pm$ 30	–	436 $\pm$ 17	400 $\pm$ 36	389 $\pm$ 19	470 $\pm$ 33	467 $\pm$ 34	456 $\pm$ 39	388 $\pm$ 32
LD OXY	264 $\pm$ 19	177 $\pm$ 17	187 $\pm$ 6	190 $\pm$ 25	–	388 $\pm$ 34	422 $\pm$ 24	438 $\pm$ 59	400 $\pm$ 19	429 $\pm$ 23	406 $\pm$ 27	397 $\pm$ 37
HD OXY	213 $\pm$ 25	209 $\pm$ 18	169 $\pm$ 18	180 $\pm$ 24	–	419 $\pm$ 33	412 $\pm$ 35	329 $\pm$ 22	428 $\pm$ 30	416 $\pm$ 47	426 $\pm$ 28	424 $\pm$ 41
LD ATO	244 $\pm$ 26	219 $\pm$ 14	167 $\pm$ 17	183 $\pm$ 23	–	319 $\pm$ 19	380 $\pm$ 25	343 $\pm$ 21	402 $\pm$ 33	474 $\pm$ 53	369 $\pm$ 14	404 $\pm$ 14
HD ATO	227 $\pm$ 29	196 $\pm$ 10	169 $\pm$ 13	190 $\pm$ 10	–	353 $\pm$ 15	375 $\pm$ 31	448 $\pm$ 22	449 $\pm$ 44	379 $\pm$ 21	388 $\pm$ 10	402 $\pm$ 18

Data are means  $\pm$  SEM.

endothelial cell marker CD31 within the area of the granulation tissue (Figure 6). Although there have only been marginal differences in the *in vivo* analysis of angiogenesis, immunostaining for microvascular density showed significantly higher values in HD ATO ( $47 \pm 8$  microvessels/HPF)-treated animals compared to HD OXY ( $23 \pm 5$ ) and LD ATO ( $15 \pm 1$ ;  $p \leq 0.05$ ), whereas all other groups did not significantly differ among each other (Figure 6).

### *In vitro* cell proliferation

We analyzed the effects of OXY on fibroblast and keratinocyte proliferation using the WST-1 proliferation assay. The exposure of fibroblasts to 10% FCS as well as to OXY 10 significantly increased the proliferation rate in comparison to OXY 100 and OXY 1000 (Figure 7). Interestingly, the exposure to bFGF was not able to increase the proliferation



**Figure 4:** Quantitative analysis (A) and representative images (B–D) of H&E staining for cellularity in wound tissue specimens on day 12 after wounding.

Animals were treated daily with saline (control; 0.9% NaCl; 12.5 mL/kg bw; n = 8), LD OXY (1 mg/kg bw; n = 9), HD OXY (10 mg/kg bw; n = 6), LD ATO (1 mg/kg bw; n = 7), or HD ATO (10 mg/kg bw; n = 6). Data are means  $\pm$  SEM. No statistically significant differences. Scale bar, 80  $\mu$ m.

rate of fibroblasts during the observation time frame of 240 min (Figure 7). Keratinocytes, however, seemed not to be influenced by OXY supplementation, as they did not significantly increase their proliferation activity as given by the absence of differences among groups (Figure 7).

### ***In vitro* cell migration**

The migrational viability of fibroblasts as assessed by means of the wound scratch assay was significantly increased by bFGF compared to controls (10% FCS) and OXY 10 at early time points (24–48 h after scratch). Fibroblasts that were exposed to OXY 1000 in the wound scratch assay showed significantly increased wound coverage at 48 h after scratch. At 72 h, the areas covered with cells were almost  $\geq 80\%$  and did not show significant differences (Figure 8). Of interest, however, there was no difference between the different supplements in keratinocyte migration during the first 48 h, whereas the exposure of keratinocytes to OXY 100 significantly impaired *in vitro* wound closure compared to 10% FCS, OXY 10, and OXY 1000 (Figure 8).

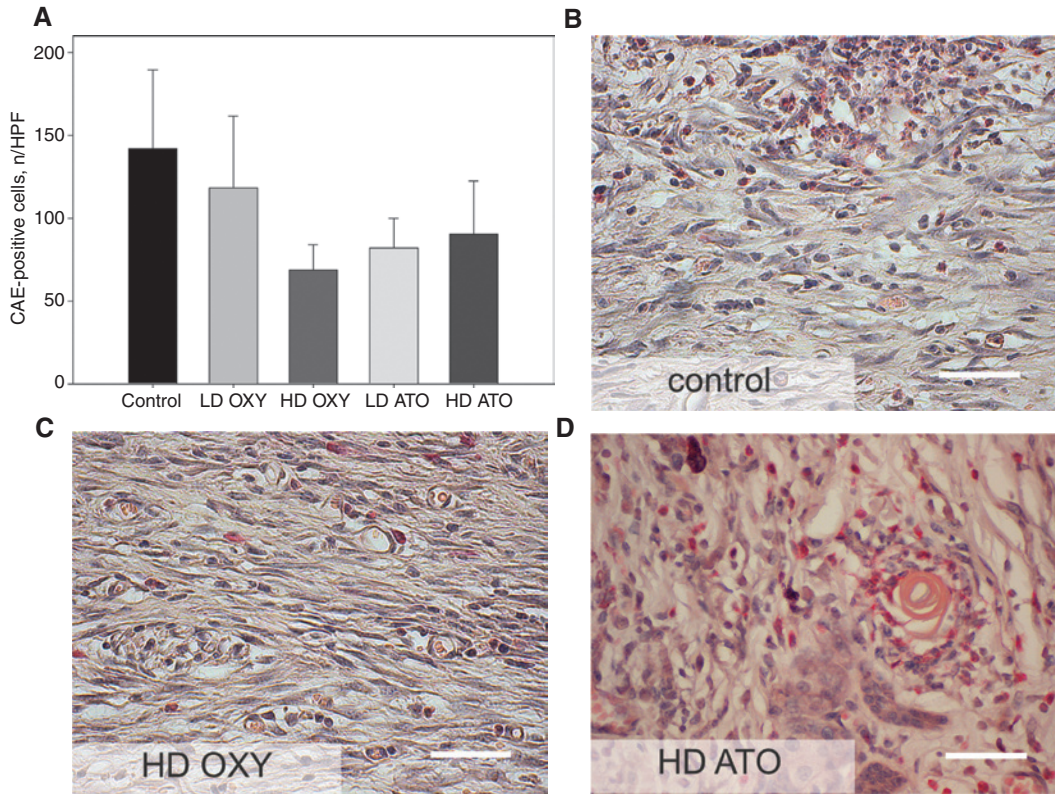
### **Laboratory analysis**

Blood samples of saline-treated controls as well as of OXY- and ATO-treated animals revealed physiological but not statistically significant different values for erythrocytes, leukocytes, platelets, as well as hemoglobin and hematocrit (data not shown).

## **Discussion**

The here presented study examined two major questions: (1) how systemic OXY application affects the repair process of full dermal thickness wounds in mice, specifically the epithelialization of the skin and its effects on keratinocytes and fibroblasts, and (2) how OXY influences the distinct effects on skin neovascularization. Based on these questions, repetitive systemic OXY application has been assessed in a model of full dermal thickness wound healing in the mouse dorsal skin fold chamber, as reported previously by our group [21, 24]. The model of the dorsal skin fold chamber in rodents





**Figure 5:** Quantitative analysis (A) and representative images (B–D) of leukocyte infiltration (AS-D CAE) in wound tissue specimens on day 12 after wounding.

Animals were treated daily with saline (control; 0.9% NaCl; 12.5 mL/kg bw; n=8), LD OXY (1 mg/kg bw; n=9), HD OXY (10 mg/kg bw; n=6), LD ATO (1 mg/kg bw; n=7), or HD ATO (10 mg/kg bw; n=6). Data are means  $\pm$  SEM. No statistically significant differences. Scale bar, 80  $\mu$ m.

displays a standardized technique, which allows a multifaceted use in experimental research [25, 26]. Besides this technique, a variety of other *in vivo* [27–30] and *in vitro* [31, 32] models exist; however, only a limited number of models include the possibility of direct microcirculatory analysis during the process of dermal restoration [33–35]. In general, animal models are only able to mimic physiological as well as pathological human wound healing problems, with dehiscence, ischemia, ulceration, infection, and scarring [36]. However, variances in the tissue architecture, immune system functions, and general physiology among animals in contrast to humans must be taken into consideration [21].

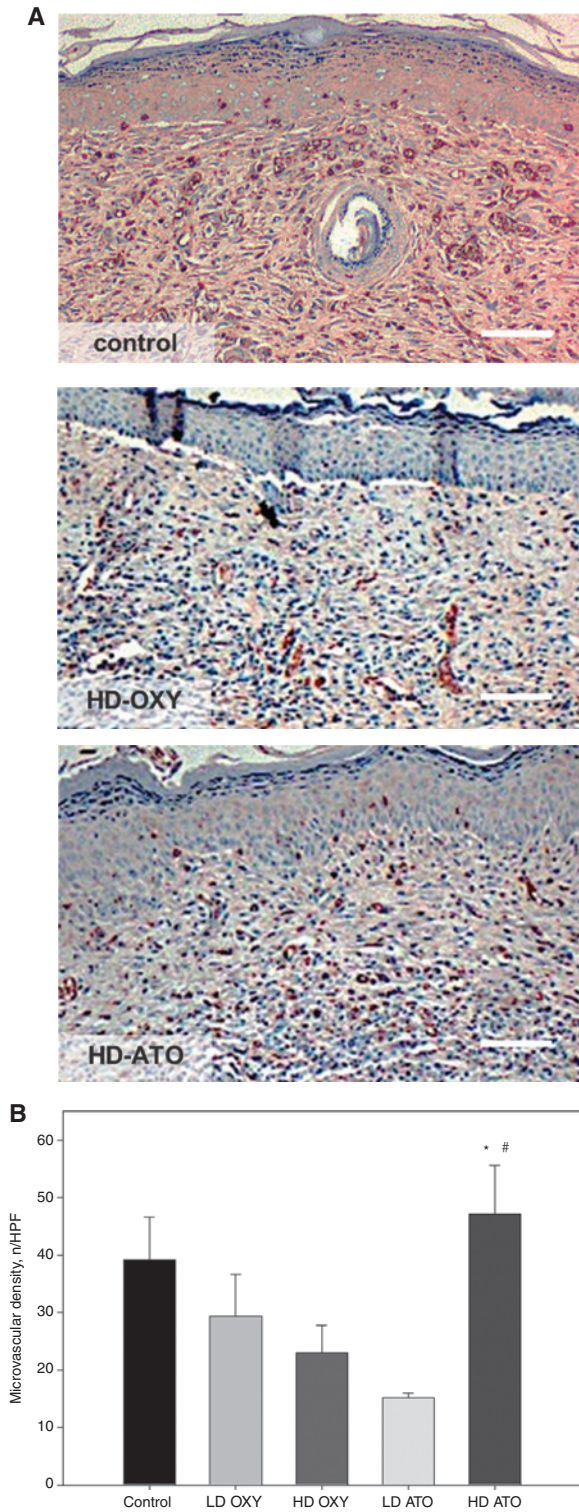
In the here used approach, the analysis of skin wound healing in a systematically and standardized manner was performed. As the regeneration or repair process of the skin is not limited to epithelial recovery, the used model further allows the quantitative assessment of microcirculation and neovascularization of the healing skin in one and the same animal over time. Using this skin wound healing model, we could determine the specific regeneration profile of newly formed

microvascular networks in the healing skin in all animals under investigation as regularly seen in other studies [21, 24]. As newly formed vessels underlie a distinct maturation process over time, as indicated by a reduction of vessel diameter as well as a decrease of vessel density [24, 37], OXY as well as ATO treatment did not interfere with the physiological process of new blood vessel formation in skin defects. This underscores that OXY application causes no harmful effects on angiogenesis during skin regeneration.

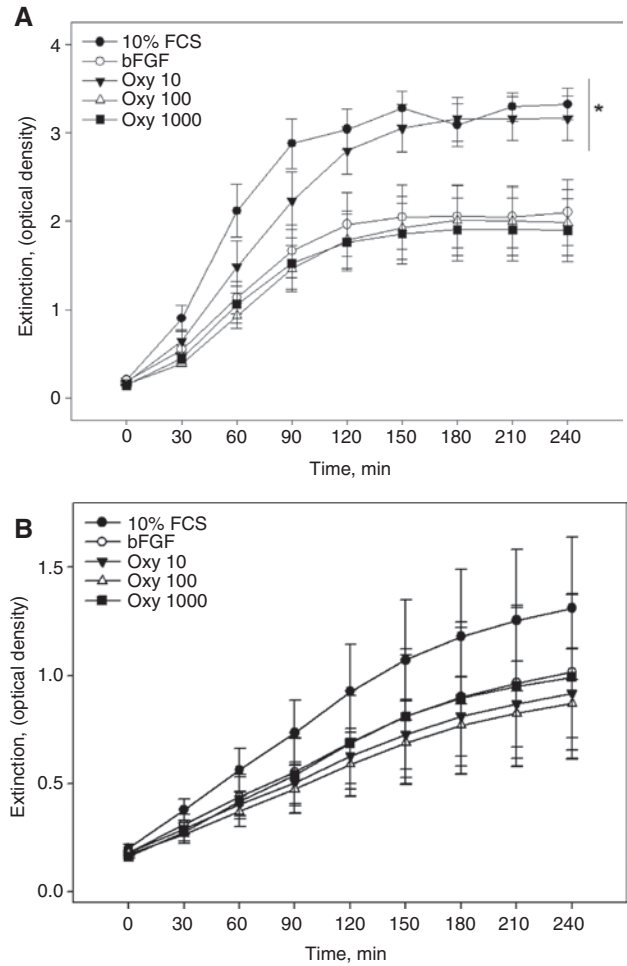
For the here presented study, we orientated us in the dosing regimens of previously done work in the context of OXY [8, 9, 13–15, 38, 39] and its selective OXY receptor antagonist ATO [15, 40–43]. In contrast, treatment with the OXY antagonist ATO elevates oxidative stress in the hearts of the newborn rats [40], abolished the cardio preconditioning effect of OXY [41], and reversed the OXY effect on gastric ischemia-reperfusion injury [42].

As demonstrated in a previously published work, the OXY receptor could be verified in the wound microenvironment [44]. Here, the receptor is expressed in human foreskin fibroblasts as well as in dermal fibroblasts and



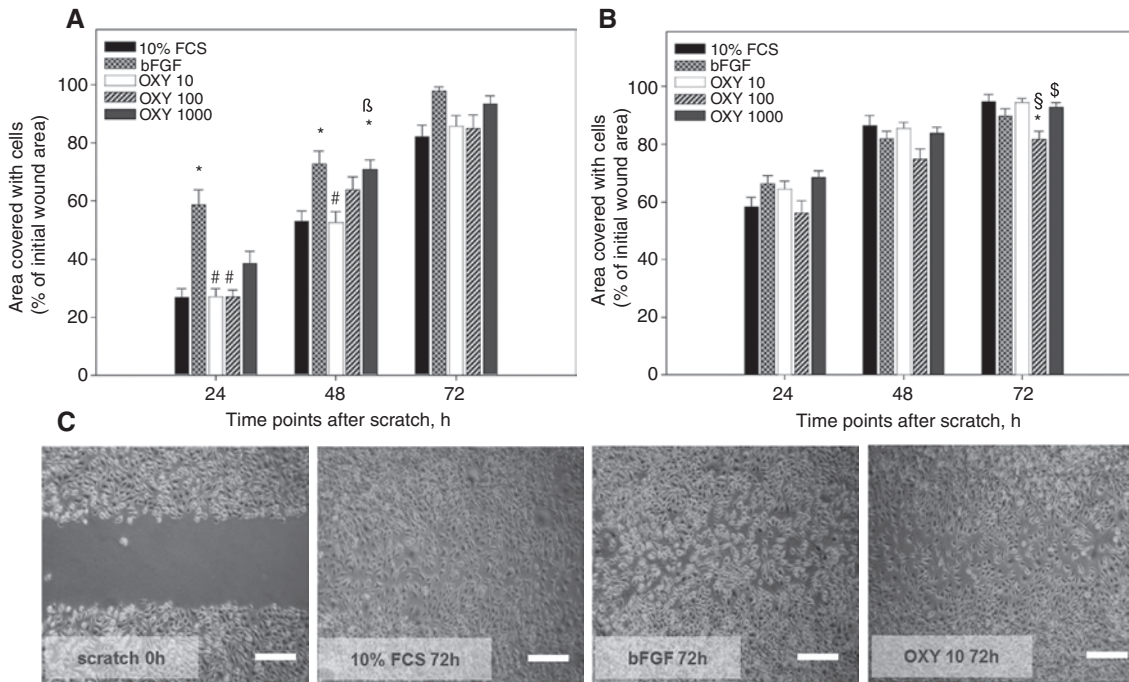


**Figure 6:** Representative images (A) and quantitative analysis (B) of CD31-stained endothelial lining to determine microvessel density in wound tissue specimens after wounding. Animals were treated daily with saline (control; 0.9% NaCl; 12.5 mL/kg bw; n = 8), LD OXY (1 mg/kg bw; n = 9), HD OXY (10 mg/kg bw; n = 6), LD ATO (1 mg/kg bw; n = 7), or HD ATO (10 mg/kg bw; n = 6). Data are means ± SEM. \*p < 0.05 vs. HD OXY; #p < 0.05 vs. LD ATO. Scale bar, 120 μm.



**Figure 7:** Quantitative assessment of *in vitro* cell proliferation by the WST-1 assay of (A) fibroblasts (L929) and (B) keratinocytes (HaCaT) over an observation period of 240 min. Cells ( $4 \times 10^3$  cells/well) were treated with DMEM supplemented with 10% FCS, bFGF (20 ng/mL), or OXY in three different concentrations with 10 nmol/mL (OXY 10), 100 nmol/mL (OXY 100), and 1000 nmol/mL (OXY 1000). After incubation for 48 h, cells were washed with PBS and the cell proliferation reagent WST-1 was added to the cell culture medium followed by incubation for 4 h with repetitive measurements of optical density every 30 min. All experiments were performed in triplicate. Data are means ± SEM. \*p < 0.05 vs. bFGF, OXY 100, and OXY 1000.

keratinocytes [45–47]. However, OXY itself is expressed in human skin and can be predominantly localized in the epidermis [47]. Polymerase chain reaction studies confirmed the expression of OXY in both skin and cultured epidermal keratinocytes [47]. Moreover, OXY is expressed not only in keratinocytes [45] but also in human skin-derived dermal fibroblasts [46]. Immunohistochemical stainings of OXY in human skin confirmed an expression of OXY in all epidermal layers [46]. The OXY receptor, however, was preferentially expressed in the basal layers [46]. Deing et al. could also demonstrate that the inhibition of the OXY receptor



**Figure 8:** Quantitative assessment of *in vitro* cell migration using the wound scratch assay with (A) fibroblasts (L929) and (B) keratinocytes (HaCaT) over an observation period of 72 h.

Cells were grown to confluence in 10% FCS on Petri dishes and then scratched with a pipette tip (C; scratch 0 h). Cells were treated with DMEM supplemented with 10% FCS, bFGF (20 ng/mL), or OXY in three different concentrations with 10 nmol/mL (OXY 10), 100 nmol/mL (OXY 100), and 1000 nmol/mL (OXY 1000). Cells were photographed immediately and 24, 48, and 72 h after the scratch, as representatively shown for fibroblasts among groups at the time point of 72 h after scratching (C). Scale bar, 400  $\mu$ m. Data are means  $\pm$  SEM. \* $p < 0.05$  vs. control; # $p < 0.05$  vs. bFGF;  $\beta p < 0.05$  vs. OXY 10;  $\$ p < 0.05$  vs. OXY 10;  $\$ p < 0.05$  vs. OXY 100.

signaling revealed an impact of OXY on the modulation of oxidative stress and cytokine release in dermal fibroblasts and keratinocytes [46]. Furthermore, OXY receptor knock-down was associated with an increased susceptibility to oxidative stress of skin cells [46]. Interestingly, the OXY receptor has also been described in rat adipocytes [48]. It can therefore be assumed that the given concentrations of OXY and ATO in the here presented study were sufficient enough to differentiate between certain effects of the treatment or its antagonism as well as versus the control group, only receiving saline treatment.

The healing of skin wounds is one of the most multifaceted biological processes in the mammalian organism, comprising different timely overlapping phases [1, 49, 50]. In each of these phases, there is a need of different cells and factors, which should help to regenerate and repair the traumatized tissue. The main objectives of sufficient healing are related to these steps and should finally lead to a fast epithelialization without major scarring. There are also many different influences such as surgical stress, immunosuppression, and reduced nutrition, which slow down or even arrest the physiological healing process. However, many different substances, such as growth

factors, cytokines, and antibodies to specific receptors, have been evaluated to ameliorate skin wound healing [50]. As there are many new substances that are described to have a very wide spectrum of activity, the so-called pleiotropic agents, OXY also is described to have an influence on skin healing. OXY treatment, for example, led to significant smaller wound sizes of full dermal thickness punch wounds in female hamsters in comparison to the control treatment [12]. Furthermore, the application of an OXY antagonist showed opposite results with less healing velocity of the wounds [12]. Interestingly, the healing performance during immobilization as well as social stress was also associated with less cortisol concentrations, suggesting that social interactions promote skin wound healing as well [12]. Other studies assessed OXY in the context of burn injuries. Herein, it could be demonstrated that OXY is able to ameliorate skin regeneration as given by a fast epithelial recovery with mostly intact dermal structures [13, 51]. One major reason for these findings might also be the fact of better social interactions, as group housed rats as well as rats that have been given environmental enrichment presented with overall better healing performances most likely associated with increased OXY

and decreased cortisol levels [12, 13, 51]. On the contrary, it could further be demonstrated that the application of OXY resulted in less remote-to-injury organ damage [51–53]. It has also been suggested that OXY might be involved in the modulation of the immune process and the inflammatory reaction via OXY receptors located in the thymus [54]. This might be due to the fact of less concentrations of tumor necrosis factor- $\alpha$  and interleukin-6, a decreased rate of apoptosis, diminished neutrophil recruitment, and less lipid peroxidation in the different organs under investigation [51]. In this context, OXY has been described to act as an anti-inflammatory agent via the increase of corticosterone levels even after a single OXY injection [7, 14, 15, 55] as well as an antioxidant via the regulation of the oxidant-antioxidant status [52, 53, 56, 57]. Furthermore, the anti-inflammatory OXY action was recently been reported to be a direct neutrophil-dependent mechanism, ameliorating the oxidative organ damage [52, 58]. In our study, the wounds of HD OXY animals revealed a two-fold lower number of infiltrating white blood cells compared to controls or the other OXY-treated group. Although the data have not been statistically significant different, it still shows the decreased effect of leukocytes within the granulation tissue of HD OXY-treated animals in comparison to control animals, indicating that decreased numbers of leukocytes might further contribute to better, at least not worsened, skin regeneration by a reduced inflammatory reaction [59, 60]. However, a clear mechanism on how OXY might lead to beneficial skin regeneration is still not clarified and should be newly discussed as the results of our *in vivo* model as well as the respective *in vitro/ex vivo* analysis could not show major differences in neither epithelialization, neovascularization, and wound cellularity nor inflammation.

However, some findings need to be discussed in more detail. Circular vessels of HD ATO showed an increase in vessel diameter on day 6 of the study. This seems to be a single difference in the study with no further consequence as circular vessels of HD ATO-treated animals did not show any differences on day 3, 9, or 12. Furthermore, circular HD ATO vessels after day 6 also decrease in their diameters until day 12, indicating vessel maturation [24]. Of interest, circular vessels are described as being directly at the wound edge and by this at the forefront of the microvascular regeneration [2, 21]. This so-called inner ring of heterogeneous vessels is characterized by large and irregular diameters, which markedly change over time as can also be seen in the reducing FMD from days 3 to 12 until they will completely disappear, when the wound is closed and the microvascular network has been regenerated [61]. OXY previously showed to have an

important role in angiogenesis [61, 62]. Here, OXY induced the proliferation by binding to OXY receptors on human vascular endothelial cells [62, 63]. Furthermore, OXY stimulates the motility of immortalized human dermal microvascular and breast cancer-derived endothelial cells [64]. It can therefore be suggested that OXY may act as an endocrine/paracrine regulatory factor that contributes to angiogenesis [61]. This could further be supported by the finding that OXY receptor signaling promoted the angiogenic patterns of human umbilical vein endothelial cells (HUVECs) via Gli1-induced transcription of hypoxia-inducible factor-1 $\alpha$  [62]. The lower FMD values for radial vessels on day 9, however, are in contrast to the described proangiogenic role of OXY, as OXY as well as ATO seem to slow down the regeneration of the microvascular network compared to the control group. However, as also shown in the studies of Sorg et al., radial vessels are subject to certain changes but not within the same range than circular vessels [2, 21, 24]. Therefore, this difference must be seen as a singular reduction of the FMD on day 9, which, however, seems still to be in the range of physiological differences over time [21].

The differences in the immunostaining for microvascular density showed significantly higher values in HD ATO-treated animals compared to HD OXY and LD ATO, which is again an interesting but contradictory point to what is known so far. Although there is no long-lasting difference in the OXY to ATO groups in the microvascular analysis over time (diameter, RBCV, and FMD), a marked difference could be detected especially of the HD ATO group in the CD31 staining. Especially, the difference to the LD ATO seems to be interesting, with the overall lowest microvascular density compared to the other groups. This is again in contrast to what is known on the use of ATO. Zhu et al. could demonstrate that the use of ATO (10  $\mu$ M) significantly suppressed the angiogenic properties of HUVECs and clearly showed inhibitory function in comparison to OXY in their study [62]. Zhu et al. therefore concluded the proangiogenic role for OXY and its receptor [62]. However, this could not be detected in our study with HD ATO treatment.

Cellular behavior differed sometimes between fibroblasts and keratinocytes with regard to OXY treatment in our study. These results, however, are not surprising as both cell types are of different origin, showing different behavior patterns for migration and secretion. In the case of fibroblasts, there seems to be an effect that is comparable to the control group that was treated by 10% FCS only. Interestingly, the exposure to bFGF was not able to increase the proliferation rate of fibroblasts during the observation time frame of 240 min. However, the values



of the bFGF and 10% FCS group are in accordance with what could be shown previously [65]. The impairment of keratinocytes in the wound scratch assays at 72 h is interesting. It can be seen throughout the three time points of evaluation that the treatment with OXY 100 showed decreased keratinocyte migration, which then got significant at 72 h. The differences range about 10%, which therefore seems to be negligible even when there is a statistical significant difference.

As many different groups reported about reduced stress levels, it might be likely that the change of glucocorticoid receptors or the cortisol levels as well as the overall reduction of stress-induced radical formation could be accounted for the assessed results [15]. Furthermore, insulin-like growth factor (IGF)-1 might also be a candidate for the mediation of OXY effects, as OXY-treated rats with musculocutaneous flaps showed better flap survival and had significantly elevated IGF-1 plasma levels [43]. Due to this knowledge, OXY seems to play an important role in skin wound healing issues. However, until now, the used transmitter system seems not to be clarified in detail and it might be proposed that it is associated with the stress response of the organism to various stimuli [7, 13, 40].

In conclusion, this study showed that OXY has no significant effects on physiological skin wound healing *in vivo*. Although other groups showed beneficial results, OXY seems at least not to be harmful in ordinary skin wound healing. Furthermore, the current knowledge on the favorable effects of good social interaction on healing processes solely associated with OXY might be newly challenged and deserves further research work.

**Acknowledgments:** The authors kindly thank Berit Blendow and Doris Butzlaff for assistance in cell biology and Dorothea Frenz for help in histology (both from the Institute for Experimental Surgery, University Medicine Rostock). We also kindly thank Prof. Guenther Kundt (Institute for Biostatistics and Informatics in Medicine and Ageing Research, University Medicine Rostock) for the expert help in statistical analysis.

#### Author Statement

Research funding: Authors state no funding involved. Conflict of interest: Authors state no conflict of interest. Informed consent: Informed consent is not applicable. Ethical approval: The Animal Ethics Committee of the State Provincial Office of Mecklenburg-West Pomerania approved the animal experiments (permit no. LALLF M-V/TSD/7221.3-1.1-001/08) and the experiments were carried out in accordance with the permits of the Laboratory

Animal Centre of the University Medicine Rostock practices and the Institutional Animal Care and Use Committee guidelines.

#### Author Contributions

Heiko Sorg: Conceptualization; Data curation; Formal analysis; Investigation; Resources; Software; Supervision; Visualization; Writing – original draft. Eberhard Grambow: Formal analysis; Investigation; Validation; Writing – review & editing. Erik Eckl: Data curation; Methodology; Project administration; Writing – review & editing. Brigitte Vollmar: Conceptualization; Data curation; Funding acquisition; Project administration; Resources; Supervision; Validation; Writing – review & editing.

## References

- [1] Reinke JM, Sorg H. Wound repair and regeneration. *Eur Surg Res* 2012;49:35–43.
- [2] Sorg H, Tilkorn DJ, Hager S, Hauser JR, Mirastschijski U. Skin wound healing: an update on the current knowledge and concepts. *Eur Surg Res* 2017;58:81–94.
- [3] Broadbent E, Koschwanez HE. The psychology of wound healing. *Curr Opin Psychiatry* 2012;25:135–40.
- [4] Lee H-J, Macbeth AH, Pagani J, Young WS. Oxytocin: the great facilitator of life. *Prog Neurobiol* 2009;88:127–51.
- [5] Stein DJ, Vythilingum B. Love and attachment: the psychobiology of social bonding. *CNS Spectr* 2009;14:239–42.
- [6] Enck P, Klosterhalfen S. The story of O – is oxytocin the mediator of the placebo response? *Neurogastroenterol Motil* 2009;21:347–50.
- [7] Uvnäs-Moberg K, Petersson M. Oxytocin, a mediator of anti-stress, well-being, social interaction, growth and healing. *Z Psychosom Med Psychother* 2005;51:57–80.
- [8] Agren G, Lundeberg T. Energy conservation in stressed rats exposed to an oxytocin-injected cage mate. *NeuroReport* 2002;13:1453–7.
- [9] Agren G, Lundeberg T. Social stress blocks energy conservation in rats exposed to an oxytocin-injected cage mate. *NeuroReport* 2002;13:1415–9.
- [10] Kosfeld M, Heinrichs M, Zak PJ, Fischbacher U, Fehr E. Oxytocin increases trust in humans. *Nature* 2005;435:673–6.
- [11] Damasio A. Human behaviour: brain trust. *Nature* 2005;435:571–2.
- [12] Detillion CE, Craft TKS, Glasper ER, Prendergast BJ, DeVries AC. Social facilitation of wound healing. *Psychoneuroendocrinology* 2004;29:1004–11.
- [13] Vitalo A, Fricchione J, Casali M, et al. Nest making and oxytocin comparably promote wound healing in isolation reared rats. *PLoS One* 2009;4:e5523.
- [14] Petersson M, Hulting A, Andersson R, Uvnäs-Moberg K. Long-term changes in gastrin, cholecystokinin and insulin in response to oxytocin treatment. *Neuroendocrinology* 1999;69:202–8.

- [15] Petersson M, Wiberg U, Lundeberg T, Uvnäs-Moberg K. Oxytocin decreases carrageenan induced inflammation in rats. *Peptides* 2001;22:1479–84.
- [16] Moosmann B, Behl C. Secretory peptide hormones are biochemical antioxidants: structure-activity relationship. *Mol Pharmacol* 2002;61:260–8.
- [17] Breit S, Tu Y-K, Bubel M, et al. Soft-tissue injury management and flap reconstruction for mangled lower extremities. *Injury* 2008;39(Suppl 4):75–95.
- [18] Cassoni P. Oxytocin induces proliferation and migration in immortalized human dermal microvascular endothelial cells and human breast tumor-derived endothelial cells. *Mol Cancer Res* 2006;4:351–9.
- [19] Petersson M, Lagumdžija A, Stark A, Bucht E. Oxytocin stimulates proliferation of human osteoblast-like cells. *Peptides* 2002;23:1121–6.
- [20] Pawlikowski M, Majak J, Stepień H. Influence of vasopressin and oxytocin upon mitotic activity of adenohipophyseal cells in rat. *Endokrynol Pol* 1975;26:417–20.
- [21] Sorg H, Krueger C, Vollmar B. Intravital insights in skin wound healing using the mouse dorsal skin fold chamber. *J Anat* 2007;211:810–8.
- [22] Klyszcz T, Jünger M, Jung F, et al. Cap image – a new kind of computer-assisted video image analysis system for dynamic capillary microscopy. *Biomed Tech (Berl)* 1997;42:168–75.
- [23] Baker M, Wayland H. On-line volume flow rate and velocity profile measurement for blood in microvessels. *Microvasc Res* 1974;7:131–43.
- [24] Sorg H, Krueger C, Schulz T, Menger MD, Schmitz F, Vollmar B. Effects of erythropoietin in skin wound healing are dose related. *FASEB J* 2009;23:3049–58.
- [25] Laschke MW, Fatouros MS, Vollmar B, et al. The dorsal skinfold chamber: window into the dynamic interaction of biomaterials with their surrounding host tissue. *Eur Cell Mater* 2011;22:147–64, discussion 164–7.
- [26] Laschke MW, Menger MD. The dorsal skinfold chamber: a versatile tool for preclinical research in tissue engineering and regenerative medicine. *Eur Cell Mater* 2016;32:202–15.
- [27] Breuing K, Eriksson E, Liu P, et al. Healing of partial thickness porcine skin wounds in a liquid environment. *J Surg Res* 1992;52:50–8.
- [28] Rossio-Pasquier P, Casanova D, Jomard A, Démarchez M. Backmatter. *Arch Dermatol Res* 2008;291:1–6.
- [29] Escámez MJ, García M, Larcher F, et al. An *in vivo* model of wound healing in genetically modified skin-humanized mice. *J Invest Dermatol* 2004;123:1182–91.
- [30] Geer DJ, Swartz DD, Andreadis ST. ASAPS2009stats. *Tissue Eng* 2010;10:1–20.
- [31] Harrison CA, Dalley AJ, Mac Neil S. A simple *in vitro* model for investigating epithelial/mesenchymal interactions: keratinocyte inhibition of fibroblast proliferation and fibronectin synthesis. *Wound Repair Regen* 2005;13:543–50.
- [32] Kamamoto F, Paggiaro AO, Rodas A, Herson MR, Mathor MB, Ferreira MC. A wound contraction experimental model for studying keloids and wound-healing modulators. *Artif Organs* 2003;27:701–5.
- [33] Roesken F, Uhl E, Curri SB, Menger MD, Messmer K. Acceleration of wound healing by topical drug delivery via liposomes. *Langenbecks Arch Surg* 2000;385:42–9.
- [34] Uhl E, Rösken F, Sirsjö A, Meßmer K. Influence of platelet-derived growth factor on microcirculation during normal and impaired wound healing. *Wound Repair Regen* 2003;11:361–7.
- [35] Vollmar B, El-Gibaly AM, Scheuer C, Strik MW, Bruch H-P, Menger MD. Acceleration of cutaneous wound healing by transient p53 inhibition. *Lab Invest* 2002;82:1063–71.
- [36] Davidson JM. Animal models for wound repair. *Arch Dermatol Res* 1998;290(Suppl):S1–11.
- [37] Sorg H, Harder Y, Krueger C, Reimers K, Vogt PM. The non-hematopoietic effects of erythropoietin in skin regeneration and repair: from basic research to clinical use. *Med Res Rev* 2013;33:637–64.
- [38] Erbas O, Ergenoglu AM, Akdemir A, Yeniel AÖ, Taskiran D. Comparison of melatonin and oxytocin in the prevention of critical illness polyneuropathy in rats with experimentally induced sepsis. *J Surg Res* 2013;183:313–20.
- [39] Uvnäs-Moberg K, Alster P, Petersson M. Dissociation of oxytocin effects on body weight in two variants of female Sprague-Dawley rats. *Integr Physiol Behav Sci* 1995;31:44–55.
- [40] Simsek Y, Celik O, Karaer A, et al. Elevated cardiac oxidative stress in newborn rats from mothers treated with atosiban. *Arch Gynecol Obstet* 2011;285:655–61.
- [41] Alizadeh AM, Faghihi M, Sadeghipour HR, et al. Oxytocin protects rat heart against ischemia-reperfusion injury via pathway involving mitochondrial ATP-dependent potassium channel. *Peptides* 2010;31:1341–5.
- [42] Zhang W, Zhang J, Xu M, Zhang Y. Effect of oxytocin on gastric ischemia-reperfusion injury in rats. *Front Med China* 2007;1:433–7.
- [43] Petersson M, Lundeberg T, Sohlström A, Wiberg U, Uvnäs-Moberg K. Oxytocin increases the survival of musculocutaneous flaps. *Naunyn Schmiedebergs Arch Pharmacol* 1998;357:701–4.
- [44] Poutahidis T, Kearney SM, Levkovich T, et al. Microbial symbionts accelerate wound healing via the neuropeptide hormone oxytocin. *PLoS One* 2013;8:e78898.
- [45] Kinsey CG, Bussolati G, Bosco M, et al. Constitutive and ligand-induced nuclear localization of oxytocin receptor. *J Cell Mol Med* 2007;11:96–110.
- [46] Deing V, Roggenkamp D, Kühnl J, et al. Oxytocin modulates proliferation and stress responses of human skin cells: implications for atopic dermatitis. *Exp Dermatol* 2013;22:399–405.
- [47] Denda S, Takei K, Kumamoto J, Goto M, Tsutsumi M, Denda M. Oxytocin is expressed in epidermal keratinocytes and released upon stimulation with adenosine 5'-[ $\gamma$ -thio]triphosphate *in vitro*. *Exp Dermatol* 2012;21:535–7.
- [48] Boland D, Goren HJ. Binding and structural properties of oxytocin receptors in isolated rat epididymal adipocytes. *Regul Pept* 1987;18:7–18.
- [49] Gurtner GC, Werner S, Barrandon Y, Longaker MT. Wound repair and regeneration. *Nature* 2008;453:314–21.
- [50] Werner S, Grose R. Regulation of wound healing by growth factors and cytokines. *Physiol Rev* 2003;83:835–70.
- [51] İşeri SÖ, Gedik İE, Erzik C, et al. Oxytocin ameliorates skin damage and oxidant gastric injury in rats with thermal trauma. *Burns* 2008;34:361–9.
- [52] İşeri SÖ, Şener G, Sağlam B, Gedik N, Ercan F, Yeğen BÇ. Oxytocin protects against sepsis-induced multiple organ damage: role of neutrophils. *J Surg Res* 2005;126:73–81.

- [53] Düşünceli F, İşeri SO, Ercan F, Gedik N, Yeğen C, Yeğen BÇ. Oxytocin alleviates hepatic ischemia-reperfusion injury in rats. *Peptides* 2008;29:1216–22.
- [54] Elands J, Resink A, De Kloet ER. Neurohypophyseal hormone receptors in the rat thymus, spleen, and lymphocytes. *Endocrinology* 1990;126:2703–10.
- [55] Gibbs DM, Vale W, Rivier J, Yen SS. Oxytocin potentiates the ACTH-releasing activity of CRF(41) but not vasopressin. *Life Sci* 1984;34:2245–9.
- [56] Tuğtepe H, Şener G, Bıyıklı NK, et al. The protective effect of oxytocin on renal ischemia/reperfusion injury in rats. *Regul Pept* 2007;140:101–8.
- [57] Tas Hekimoglu A, Toprak G, Akkoc H, Evliyaoglu O, Ozekinci S, Kelle I. Oxytocin ameliorates remote liver injury induced by renal ischemia-reperfusion in rats. *Kor J Physiol Pharmacol* 2013;17:169.
- [58] Bıyıklı NK, Tuğtepe H, Şener G, et al. Oxytocin alleviates oxidative renal injury in pyelonephritic rats via a neutrophil-dependent mechanism. *Peptides* 2006;27:2249–57.
- [59] Luster AD, Cardiff RD, MacLean JA, Crowe K, Granstein RD. Delayed wound healing and disorganized neovascularization in transgenic mice expressing the IP-10 chemokine. *Proc Assoc Am Phys* 1998;110:183–96.
- [60] Rico RM, Ripamonti R, Burns AL, Gamelli RL, DiPietro LA. The effect of sepsis on wound healing. *J Surg Res* 2002;102:193–7.
- [61] Cattaneo MG, Chini B, Vicentini LM. Oxytocin stimulates migration and invasion in human endothelial cells. *Br J Pharmacol* 2008;153:728–36.
- [62] Zhu J, Wang H, Zhang X, Xie Y. Regulation of angiogenic behaviors by oxytocin receptor through Gli1-induced transcription of HIF-1. *Biomed Pharmacother* 2017;90:928–34.
- [63] Thibonnier M, Conarty DM, Preston JA, Plesnicher CL, Dweik RA, Erzurum SC. Human vascular endothelial cells express oxytocin receptors. *Endocrinology* 1999;140:1301–9.
- [64] Cassoni P, Sapino A, Marrocco T, Chini B, Bussolati G. Oxytocin and oxytocin receptors in cancer cells and proliferation. *J Neuroendocrinol* 2004;16:362–4.
- [65] Sorg H, Schulz T, Krueger C, Vollmar B. Consequences of surgical stress on the kinetics of skin wound healing: partial hepatectomy delays and functionally alters dermal repair. *Wound Repair Regen* 2009;17:367–77.

---

**Supplemental Material:** The article (<https://doi.org/10.1515/iss-2017-0033>) offers reviewer assessments as supplementary material.





## Reviewer Assessment

Heiko Sorg\*, Eberhard Grambow, Erik Eckl and Brigitte Vollmar

# Oxytocin effects on experimental skin wound healing

<https://doi.org/10.1515/iss-2017-0033>

Received July 1, 2017; accepted July 14, 2017

**\*Corresponding author: Heiko Sorg**, Institute for Experimental Surgery, University Medicine Rostock, Schillingallee 69a, 18057 Rostock, Germany; and Department of Plastic, Reconstructive and Aesthetic Surgery, Hand Surgery, Alfried Krupp Krankenhaus, Essen, Germany, E-mail: heiko.sorg@t-online.de

## Reviewers' Comments to Original Submission

### Reviewer 1: anonymous

Jul 03, 2017

<b>Reviewer Recommendation Term:</b>	Revise with Major Modifications
<b>Overall Reviewer Manuscript Rating:</b>	60
<b>Custom Review Questions</b>	<b>Response</b>
Is the subject area appropriate for you?	5 - High/Yes
Does the title clearly reflect the paper's content?	4
Does the abstract clearly reflect the paper's content?	4
Do the keywords clearly reflect the paper's content?	4
Does the introduction present the problem clearly?	4
Are the results/conclusions justified?	1 - Low/No
How comprehensive and up-to-date is the subject matter presented?	3
How adequate is the data presentation?	3
Are units and terminology used correctly?	5 - High/Yes
Is the number of cases adequate?	2
Are the experimental methods/clinical studies adequate?	3
Is the length appropriate in relation to the content?	4
Does the reader get new insights from the article?	3
Please rate the practical significance.	2
Please rate the accuracy of methods.	3
Please rate the statistical evaluation and quality control.	3
Please rate the appropriateness of the figures and tables.	1 - Low/No
Please rate the appropriateness of the references.	3
Please evaluate the writing style and use of language.	4
Please judge the overall scientific quality of the manuscript.	3
Are you willing to review the revision of this manuscript?	Yes

**Comments to Authors:**

In the present study the authors analyzed the effect of oxytocin and the oxytocin-receptor antagonist atosiban in a murine dorsal skin fold chamber model of full thickness wound healing by means of intravital fluorescence microscopy, histology, immunohistochemistry and additional in vitro proliferation and migration assays. Although other studies have previously reported beneficial effects of oxytocin on different regenerative processes, the authors detected no relevant effects of the compounds on skin repair and cell behaviour in their experimental setting.

Although this is an interesting study, which has been performed by an experienced group in an established model, I feel that this manuscript exhibits several major and minor flaws, which have to be clarified to improve the quality of this work:

**Major comments:**

1. It is always difficult to deal with negative results, particularly if others have already demonstrated positive effects. Nonetheless, it is important to publish also such results as they are essential for a real scientific progress. However, in such a case it is of utmost importance to identify potential problems, which may have caused contradictory findings. For instance, in this study the authors used oxytocin doses of 1 and 10 mg/kg, referred to as low and high doses. However, in the discussion section they cite a study (reference 12), which reports positive oxytocin effects when applying a dose of 20 mg/kg. Hence, there is the question whether the authors are sure about their dose selection? At least, the authors should provide detailed references and explanations for the chosen doses.

2. The discussion needs substantial revision. While the authors address many general aspects about their model and oxytocin, they do not comment on several strange findings in the results section, i.e.:

- "In contrast, circular vessels of HD ATO showed an increase in vessel diameter" (page 9)

- "...but has been lower in OXY and ATO-groups by day 9 compared to the control group (Figure 2D)" (page 9)

- "immunostaining for microvascular density showed significantly higher values in HD ATO treated animals compared to HD OXY and LD ATO..." (page 10)

- "The exposure of fibroblasts to 10 % FCS as well as to OXY 10 significantly increased the proliferation rate in comparison to OXY 100 and OXY 1000" (page 11)

- "...while the exposure of keratinocytes to OXY 100 significantly impaired in vitro wound closure compared to 10 % FCS, OXY 10 and OXY 1000 (Figure 6B)" (page 11)

All of these statements need detailed discussion. Particularly, it is questionable whether the overall conclusion of the authors, i.e. oxytocin and its receptor antagonist do not impair wound healing, is substantiated by these findings. Moreover, several of these results indicate that significant effects did not correlate with increasing doses - why?

3. Abstract (and also discussion): The statement "Therefore, the recently published data showing improvement of wound healing by oxytocin might be due to the activation of other pathways" is not plausible. Why should oxytocin activate other pathways in other studies? The signaling cascades activated by oxytocin-oxytocin receptor interaction are well known and are always identical. This cannot be an explanation for the contradictory findings!

**Minor comments:**

1. Page 3, line 19: "stimulated" must read "stimulates"

2. Page 4: Please explain the varying numbers of animals in the different groups. Why didn't the authors choose an identical group size of e.g. n = 8? The differences in group sizes may have markedly affected the statistical analysis!

3. Page 4: "At the end of the experiments blood was collected" - for what? There are no results reporting analyses of blood samples.

4. Page 4: Please add the exact doses of anesthetics.

5. Page 5: The description of the image analysis is poor. The authors should provide more details. How many vessels were analysed for diameter and flow measurements. How were they selected - randomly or not? Please also explain the exact meaning of the statement: "The three-dimensional aspect of the wound was considered by focusing through the depth of the wound" - does it mean that different focus areas were analysed? How many? Do the data show the mean of these areas?

6. Results section: The passages explaining the statistical results read awkward and confusing. Are they really necessary?

7. Page 8: Although the authors cite the study of Sorg et al. (2007), they should provide their own representative images of the “inner and outer vascular ring”. Otherwise, the results section and the performed microcirculatory analyses are difficult to understand.

8. Figure 1: The interpretation of the images in A is difficult. Please show additional images of day 6 or 9 displaying areas of epithelialization vs. non-epithelialized areas. How did the authors exactly identify epithelialized areas on these low-resolution images? The legend in B is wrong (two times white bar).

9. Figure 2: The legend in D is wrong (two times white bar).

10. Figure 3: The authors should add images of the control group in A and C. Moreover, the images in A and C markedly differ between the groups. This does not support the result that there were no significant differences between the groups. Please provide more representative images! Scale bars are not explained in the figure legend.

Figure 4: The authors should add an image of the control group in A. Scale bars are missing.

Figure 5: In A “fibroblast” should read “fibroblasts”.

## Reviewer 2: Ursula Mirastschijski

Jul 04, 2017

**Reviewer Recommendation Term:**

Accept with Minor Revision

**Overall Reviewer Manuscript Rating:**

85

### Custom Review Questions

Custom Review Questions	Response
Is the subject area appropriate for you?	5 - High/Yes
Does the title clearly reflect the paper's content?	5 - High/Yes
Does the abstract clearly reflect the paper's content?	5 - High/Yes
Do the keywords clearly reflect the paper's content?	5 - High/Yes
Does the introduction present the problem clearly?	5 - High/Yes
Are the results/conclusions justified?	5 - High/Yes
How comprehensive and up-to-date is the subject matter presented?	4
How adequate is the data presentation?	5 - High/Yes
Are units and terminology used correctly?	5 - High/Yes
Is the number of cases adequate?	5 - High/Yes
Are the experimental methods/clinical studies adequate?	5 - High/Yes
Is the length appropriate in relation to the content?	5 - High/Yes
Does the reader get new insights from the article?	4
Please rate the practical significance.	4
Please rate the accuracy of methods.	5 - High/Yes
Please rate the statistical evaluation and quality control.	5 - High/Yes
Please rate the appropriateness of the figures and tables.	5 - High/Yes
Please rate the appropriateness of the references.	5 - High/Yes
Please evaluate the writing style and use of language.	5 - High/Yes
Please judge the overall scientific quality of the manuscript.	5 - High/Yes
Are you willing to review the revision of this manuscript?	Yes

### Comments to Authors:

The authors of the article „Oxytocin effects on experimental skin wound healing” describe cutaneous wound healing during systemic treatment with oxytocin or the oxytocin-receptor antagonist atosiban in mice. A full-thickness skin wound model assessing wound repair with the dorsal skin fold chamber model was used. No differences were found between wound healing in groups with different oxytocin or atosiban concentrations in comparison with controls.

First of all, I congratulate the authors for submitting a manuscript describing negative results because of the utmost importance to point out missing effects. Secondly, the experimental animal model used for this study is extremely important and helpful. The stretch of the dorsal chamber mimics human wound repair to a greater degree in comparison to ordinary full-thickness excisional skin wounds in rodents. This fact should be emphasized much more in detail in the discussion - also with regard to diverging results in comparison with literature. Animal models are supposed to mimic human wound healing. This is in fact extremely difficult since human skin wound repair is unique with regard to excessive scarring or chronic non-healing wounds. This should be emphasized in the discussion.



Interestingly, cellular behaviour differed enormously between fibroblasts and keratinocytes with regard to oxytocin treatment. This result is not astonishing since both cell types are of different origin and show different migrational and secretional behaviour patterns. This is a very important finding and should also be discussed more in the discussion. Since oxytocin has an effect on inflammation, were there any differences with regard to inflammatory cell count in wounds?

Please add a short summary of the wound model to the material and method section. It should be also indicated that the in vitro experiments were carried out with human cell lines and not primary cells.

In short, the present article describes the effects of systemic treatment with oxytocin or atosiban on skin wound healing in mice. No differences were found between treatment groups in a dorsal chamber model. These results are extremely important in case of treatment with oxytocin.

---

## Authors' Response to Reviewer Comments

Jul 11, 2017

Authors' point-by-point reply to the comments of the **reviewer #1**:

The authors thank reviewer 1 for the comments and the constructive criticism to improve the content of the paper. We appreciate this and have followed all detailed comments to clarify the manuscript.

Major comments:

1. For instance, in this study the authors used oxytocin doses of 1 and 10 mg/kg, referred to as low and high doses. However, in the discussion section they cite a study (reference 12), which reports positive oxytocin effects when applying a dose of 20 mg/kg. Hence, there is the question whether the authors are sure about their dose selection? At least, the authors should provide detailed references and explanations for the chosen doses.

Thank you for this question and comment. For the here presented study we orientated us in what was given in previously done work in the context of oxytocin (Petersson et al. 2001; Petersson et al. 1999; Iseri et al. 2005; Erbas et al. 2014; Agren & Lundeborg 2002a,b; Vitalo et al. 2009; Uvnäs-Moberg et al. 1995) and its selective oxytocin receptor antagonist atosiban (Petersson et al. 2001; Simsek et al. 2011; Alizadeh et al. 2010; Zhang et al. 2007; Petersson et al. 1998). In a different study by Poutahidis and colleagues mice were injected intraperitoneally every 4–6 hours with 15 units/mouse of oxytocin. This treatment regimen lead to  $875.3 \pm 141.7$  pg/ml, whereas sham treated mice with lactated ringers solution presented with significantly ( $p = 0.0004$ .) lower levels of plasma oxytocin given by  $380.5 \pm 46.82$  pg/ml (Poutahidis et al. 2013). The treatment with the oxytocin antagonist atosiban elevates oxidative stress in the hearts of the newborn rats (Simsek et al. 2011), abolished the cardiopreconditioning effect of oxytocin (Alizadeh et al. 2010) and reversed the oxytocin effect on gastric ischemia-reperfusion injury (Zhang et al. 2007). It can therefore be assumed that the given doses of oxytocin and atosiban in the here presented study were sufficient enough in order to differentiate between certain effects of the treatment or its antagonism as well as versus the control group, only receiving saline treatment.

The above mentioned points have been added to the discussion section of the revised version of the manuscript marked by red font and underlining and reads as follows: "For the here presented study we orientated us in the dosing regimens of previously done work in the context of oxytocin (Petersson et al. 2001; Petersson et al. 1999; Iseri et al. 2005; Erbas et al. 2014; Agren & Lundeborg 2002a,b; Vitalo et al. 2009; Uvnäs-Moberg et al. 1995) and its selective OXY receptor antagonist atosiban (Petersson et al. 2001; Simsek et al. 2011; Alizadeh et al. 2010; Zhang et al. 2007; Petersson et al. 1998). The treatment with the OXY antagonist atosiban elevates oxidative stress in the hearts of newborn rats (Simsek et al. 2011), abolished the cardiopreconditioning effect of OXY (Alizadeh et al. 2010) and reversed the OXY effect on gastric ischemia-reperfusion injury (Zhang et al. 2007). It can therefore be assumed that the given concentrations of OXY and atosiban in the here presented study were sufficient enough in order to differentiate between certain effects of the treatment or its antagonism as well as versus the control group, only receiving saline treatment."

- Agren G, Lundeborg T. Energy conservation in stressed rats exposed to an oxytocin-injected cage mate. *NeuroReport*. 2002a Aug 7;13(11):1453–7.

- Agren G, Lundeborg T. Social stress blocks energy conservation in rats exposed to an oxytocin-injected cage mate. *NeuroReport*. 2002b Aug 7;13(11):1415–9.

- Alizadeh AM, Faghihi M, Sadeghipour HR, MohammadGhasemi F, Imani A, Houshmand F, et al. Oxytocin protects rat heart against isch-

- emia–reperfusion injury via pathway involving mitochondrial ATP-dependent potassium channel. *Peptides*. 2010;31(7):1341–5.
- Boland D, Goren HJ. Binding and structural properties of oxytocin receptors in isolated rat epididymal adipocytes. *Regul Pept*. 1987 Jul;18(1):7–18.
  - D’Andrea F, Nicoletti GF, Grella E, et al. Modification of cysteinyl leukotriene receptor expression in capsular contracture: Preliminary results. *Annals of Plastic Surgery*. 2007 Feb;58(2):212–4.
  - Deing V, Roggenkamp D, Kühnl J, Gruschka A, Stäb F, Wenck H, et al. Oxytocin modulates proliferation and stress responses of human skin cells: implications for atopic dermatitis. *Experimental Dermatology*. 2013 May 27;22(6):399–405.
  - Denda S, Takei K, Kumamoto J, Goto M, Tsutsumi M, Denda M. Oxytocin is expressed in epidermal keratinocytes and released upon stimulation with adenosine 5′-[γ-thio]triphosphate in vitro. *Experimental Dermatology*. 2012 May 14;21(7):535–7.
  - Erbas O, Ergenoglu AM, Akdemir A, Yeniel AÖ, Taskiran D. Comparison of melatonin and oxytocin in the prevention of critical illness polyneuropathy in rats with experimentally induced sepsis. *Journal of Surgical Research*. 183(1):313–20.
  - İşeri SÖ, Şener G, Sağlam B, Gedik N, Ercan F, Yeğen BÇ. Oxytocin Protects Against Sepsis-Induced Multiple Organ Damage: Role of Neutrophils. *Journal of Surgical Research*. 126(1):73–81.
  - Kinsey CG, Bussolati G, Bosco M, Kimura T, Pizzorno MC, Chernin MI, et al. Constitutive and ligand-induced nuclear localization of oxytocin receptor. *J Cell Mol Med*. 2007 Jan;11(1):96–110.
  - Mens WBJ, Witter A, Van Wimersma Greidanus TB. Penetration of neurohypophyseal hormones from plasma into cerebrospinal fluid (CSF): Half-times of disappearance of these neuropeptides from CSF. *Brain Res*. 1983;262(1):143–9.
  - Petersson M, Hulting A, Andersson R, Uvnäs-Moberg K. Long-term changes in gastrin, cholecystokinin and insulin in response to oxytocin treatment. *Neuroendocrinology*. 1999 Mar;69(3):202–8.
  - Petersson M, Lundeberg T, Sohlström A, Wiberg U, Uvnäs-Moberg K. Oxytocin increases the survival of musculocutaneous flaps. *Naunyn Schmiedeberg’s Arch Pharmacol*. 1998 May 31;357(6):701–4.
  - Petersson M, Wiberg U, Lundeberg T, Uvnäs-Moberg K. Oxytocin decreases carrageenan induced inflammation in rats. *Peptides*. 2001 Sep;22(9):1479–84.
  - Poutahidis T, Kearney SM, Levkovich T, Qi P, Varian BJ, Lakritz JR, et al. Microbial Symbionts Accelerate Wound Healing via the Neuropeptide Hormone Oxytocin. Gaetani S, editor. *PLoS ONE*. 2013 Oct 30;8(10):e78898.
  - Siddhu. Pharmacological Role of Oxytocin – A Short Review. 2014 Apr 18;:1–4.
  - Simsek Y, Celik O, Karaer A, Yilmaz E, Gul M, Ozerol E, et al. Elevated cardiac oxidative stress in newborn rats from mothers treated with atosiban. *Arch Gynecol Obstet*. 2011 Aug 25;285(3):655–61.
  - Uvnäs-Moberg K, Alster P, Petersson M. Dissociation of oxytocin effects on body weight in two variants of female Sprague-Dawley rats. *Integr Physiol Behav Sci*. 1995 Dec 31;31(1):44–55.
  - Vitalo A, Fricchione J, Casali M, Berdichevsky Y, Hoge EA, Rauch SL, et al. Nest Making and Oxytocin Comparably Promote Wound Healing in Isolation Reared Rats. Hashimoto K, editor. *PLoS ONE*. 2009 May 13;4(5):e5523.
  - Zhang W, Zhang J, Xu M, Zhang Y. Effect of oxytocin on gastric ischemia-reperfusion injury in rats. *Front Med China*. 2007 Oct;1(4):433–7.

2. The discussion needs substantial revision. While the authors address many general aspects about their model and oxytocin, they do not comment on several strange findings in the results section, i.e.:

We will comment and further describe to the several specific findings in the following.

- “In contrast, circular vessels of HD ATO showed an increase in vessel diameter” (page 9)

This seems to be a single difference in the study, however, with no further consequence in the following as circular vessels of HD ATO treated animals did not show any other differences at days 3, 9 or 12. Furthermore, circular HD ATO vessels after day 6 also decrease in their diameters until day 12, indicating vessel maturation (Sorg et al. 2009). Of interest, circular vessels are described as being directly at the wound edge and by this at the forefront of the microvascular regeneration (Sorg et al. 2007; Sorg et al. 2017). This so called inner ring of heterogenous vessels is characterized by large and irregular diameters, which markedly change over time as can also be seen in the reducing functional microvascular density from day 3 to day 12 until they completely disappear, when the wound is closed and the microvascular network has been regenerated (Sorg et al. 2007).

- Sorg H, Krueger C, Vollmar B. Intravital insights in skin wound healing using the mouse dorsal skin fold chamber. *J Anat*. 2007 Dec;211(6):810-8.
- Sorg H, Krueger C, Schulz T, Menger MD, Schmitz F, Vollmar B. Effects of erythropoietin in skin wound healing are dose related. *FASEB J*. 2009 Sep;23(9):3049-58.
- Sorg H, Tilkorn DJ, Hager S, Hauser J, Mirastschijski U. Skin Wound Healing: An Update on the Current Knowledge and Concepts. *Eur Surg Res*. 2017;58(1-2):81-94.

- "...but has been lower in OXY and ATO-groups by day 9 compared to the control group (Figure 2D)" (page 9)

Oxytocin previously showed to have an important role in angiogenesis (Cattaneo et al. 2008; Zhu et al. 2017). Here oxytocin induced proliferation by the binding to oxytocin-receptors on human vascular endothelial cells (Thibonnier et al., 1999; Zhu et al. 2017). Furthermore oxytocin stimulates the motility of immortalized human dermal microvascular and breast cancer-derived endothelial cells (Cassoni et al., 2006). It can therefore be suggested that oxytocin may act as an endocrine/paracrine regulatory factor that contributes to the formation of new blood vessels (Cattaneo et al. 2008). This could further be supported by the finding, that oxytocin receptor signaling promoted the angiogenic behaviors of HUVECs via Gli1-induced transcription of HIF-1 $\alpha$  (Zhu et al. 2017).

These findings are in contrast to what has been found in our study by day 9, as oxytocin as well as atosiban seem to slow down the regeneration of the microvascular network given by the FMD measurement compared to the control group. However, as also shown in the studies by Sorg et al., radial vessels are subject to certain changes, but not within the same range as circular vessels. Therefore this significance exists, however, seems to be of less importance to the study or the treatment of oxytocin and atosiban.

- Cassoni P, Marrocco T, Bussolati B, Allia E, Munaron L, Sapino A, Bussolati G. Oxytocin induces proliferation and migration in immortalized human dermal microvascular endothelial cells and human breast tumor-derived endothelial cells. *Mol Cancer Res.* 2006 Jun;4(6):351-9.
- Cattaneo MG, Chini B, Vicentini LM. Oxytocin stimulates migration and invasion in human endothelial cells. *Br J Pharmacol.* 2008 Feb;153(4):728-36.
- Sorg H, Krueger C, Vollmar B. Intravital insights in skin wound healing using the mouse dorsal skin fold chamber. *J Anat.* 2007 Dec;211(6):810-8.
- Sorg H, Krueger C, Schulz T, Menger MD, Schmitz F, Vollmar B. Effects of erythropoietin in skin wound healing are dose related. *FASEB J.* 2009 Sep;23(9):3049-58.
- Sorg H, Tilkorn DJ, Hager S, Hauser J, Mirastschijski U. Skin Wound Healing: An Update on the Current Knowledge and Concepts. *Eur Surg Res.* 2017;58(1-2):81-94.
- Thibonnier M, Conarty DM, Preston JA, Plesnicher CL, Dweik RA, Erzurum SC. Human vascular endothelial cells express oxytocin receptors. *Endocrinology.* 1999 Mar;140(3):1301-9.
- Zhu J, Wang H, Zhang X, Xie Y. Regulation of angiogenic behaviors by oxytocin receptor through Gli1-induced transcription of HIF-1 $\alpha$  in human umbilical vein endothelial cells. *Biomed Pharmacother.* 2017 Jun;90:928-934.

- "immunostaining for microvascular density showed significantly higher values in HD ATO treated animals compared to HD OXY and LD ATO..." (page 10)

This seems really to be an interesting point, as there is a clear difference between the in vivo and the histology analysis of our study. While there is no vital difference in the OXY to ATO groups in the microvascular analysis (diameter, RBCV, FMD), a marked difference could be detected especially of the HD ATO group in comparison to the HD OXY and LD ATO group. Especially the difference to the LD ATO seems to be interesting, with the overall lowest microvascular density compared to the other groups. This is again in contrast to what is known on the use of atosiban. Zhu et al. could demonstrate that the use of atosiban (10 $\mu$ M) significantly suppressed the angiogenic properties of HUVECs and clearly showed inhibitory function in comparison to oxytocin in their study (Zhu et al. 2017). Zhu et al. therefore concluded the proangiogenic role for oxytocin and its receptor (Zhu et al. 2017).

Looking detailed at the values there are also no spikes of some animals as the lowest value has been 31 CD31 positive vessels/per HPF and the highest value has been 75 CD31 positive vessels/HPF within the HD ATO group.

- Zhu J, Wang H, Zhang X, Xie Y. Regulation of angiogenic behaviors by oxytocin receptor through Gli1-induced transcription of HIF-1 $\alpha$  in human umbilical vein endothelial cells. *Biomed Pharmacother.* 2017 Jun;90:928-934.

- "The exposure of fibroblasts to 10 % FCS as well as to OXY 10 significantly increased the proliferation rate in comparison to OXY 100 and OXY 1000" (page 11)

- "...while the exposure of keratinocytes to OXY 100 significantly impaired in vitro wound closure compared to 10 % FCS, OXY 10 and OXY 1000 (Figure 6B)" (page 11)

These two statements will be discussed together. Cell proliferation and migration are highly coordinated processes that play a critical role in health and disease. (Kole et al. 2005; Lauffenburger & Horwitz 1996, Pollard & Borisy 2003; Pollard 2003). During cutaneous wound repair, re-epithelialization and cell proliferation are mediated by a wide variety of growth and differentiation factors. There also exist a variety of different approaches to analyze proliferation and migration of cells. Herein, experiments using cell culture techniques offer many advantages in comparison to in vivo investigations. By using cell cultures of fibroblasts and keratinocytes seeded in a monolayer we could analyze the migration behavior after inducing an artificial wound within the Petri dish. After several timepoints the migration from the united cell structure into the wound could be analyzed. In this in vitro approach the wound predominantly closes through nondirectional migration of cells, but also to some extent via cell proliferation (Huang et al. 1998; Gold et al. 2006). Therefore, we certainly cannot distinguish between migration and proliferation within the wound scratch assay. In order to determine the sole proliferation capability, we performed the WST-1



assay. In the case of fibroblasts there seems to be an effect which is comparable to the control group which was treated by 10% FCS only. Interestingly, and as also written in the manuscript, the exposure to bFGF was not able to increase the proliferation rate of fibroblasts during the observation time frame of 240 min compared to 10% FCS and OXY 10. The values of the FGF and 10%FCS group are in accordance to other studies (Sorg et al. 2009). The impairment of the keratinocytes in the wound scratch assays at 72h are interesting, however, cannot be explained in detail. It can be seen throughout the three time points of evaluation, that the treatment with OXY 100 showed decreased keratinocyte migration, which then got significant at 72h. However, we discuss about differences of  $94\pm 2\%$  in OXY 10,  $82\pm 3\%$  in OXY 100 and  $92\pm 2\%$  in OXY 1000, which seems to be negligible, even when there is a statistical significant difference.

- Gold LI, Rahman M, Blechman KM, Greives MR, Churgin S, Michaels J, Callaghan MJ, Cardwell NL, Pollins AC, Michalak M, Siebert JW, Levine JP, Gurtner GC, Nanney LB, Galiano RD, Cadacio CL. Overview of the role for calreticulin in the enhancement of wound healing through multiple biological effects. *J Investig Dermatol Symp Proc.* 2006;11:57-65.
- Huang C, Liu J, Haudenschild CC, Zhan X. The role of tyrosine phosphorylation of cortactin in the locomotion of endothelial cells. *J Biol Chem.* 1998;273:25770-25776.
- Kole TP, Tseng Y, Jiang I, Katz JL, Wirtz D. Intracellular mechanics of migrating fibroblasts. *Mol Biol Cell.* 2005;16:328-338.
- Lauffenburger DA, Horwitz AF. Cell migration: a physically integrated molecular process. *Cell* 1996;84, 359-369
- Pollard TD, Borisy GG. Cellular motility driven by assembly and disassembly of actin filaments. *Cell* 2003;112, 453-465.
- Pollard TD. The cytoskeleton, cellular motility and the reductionist agenda. *Nature* 1996;422, 741-745.
- Sorg H, Schulz T, Krueger C, Vollmar B. Consequences of surgical stress on the kinetics of skin wound healing: partial hepatectomy delays and functionally alters dermal repair. *Wound Repair Regen.* 2009 May-Jun;17(3):367-77.

All of these statements need detailed discussion. Particularly, it is questionable whether the overall conclusion of the authors, i.e. oxytocin and its receptor antagonist do not impair wound healing, is substantiated by these findings. Moreover, several of these results indicate that significant effects did not correlate with increasing doses - why?

These results have now been discussed in detail, which can be read in a new paragraph in the revised version of the manuscript marked by red font and underlining: "However, some findings need to be discussed in more detail. Circular vessels of HD ATO showed an increase in vessel diameter by day 6 of the study. This seems to be a single difference in the study with no further consequence as circular vessels of HD ATO treated animals did not show any differences at days 3, 9 or 12. Furthermore, circular HD ATO vessels after day 6 also decrease in their diameters until day 12, indicating vessel maturation (Sorg et al. 2009). Of interest, circular vessels are described as being directly at the wound edge and by this at the forefront of the microvascular regeneration (Sorg et al. 2007; Sorg et al. 2017). This so called inner ring of heterogenous vessels is characterized by large and irregular diameters, which markedly change over time as can also be seen in the reducing FMD from day 3 to day 12 until they will completely disappear, when the wound is closed and the microvascular network has been regenerated (Sorg et al. 2007). Oxytocin previously showed to have an important role in angiogenesis (Cattaneo et al. 2008; Zhu et al. 2017). Here oxytocin induced the proliferation by binding to oxytocin-receptors on human vascular endothelial cells (Thibonnier et al., 1999; Zhu et al. 2017). Furthermore oxytocin stimulates the motility of immortalized human dermal microvascular and breast cancer-derived endothelial cells (Cassoni et al., 2006). It can therefore be suggested that oxytocin may act as an endocrine/paracrine regulatory factor that contributes to angiogenesis (Cattaneo et al. 2008). The finding could further support that oxytocin receptor signaling promoted the angiogenic patterns of HUVECs via Gli1-induced transcription of HIF-1 $\alpha$  (Zhu et al. 2017). The lower FMD values for radial vessel by day 9, however, are in contrast to the described proangiogenic role of oxytocin, as oxytocin as well as atosiban seem to slow down the regeneration of the microvascular network compared to the control group. Though, as also shown in the studies by Sorg et al., radial vessels are subject to certain changes, but not within the same range than circular vessels. Therefore this difference must be seen as a singular reduction of the FMD by day 9, which however, seems still to be in the range of physiological differences over time (Sorg et al. 2007).

The differences in the immunostaining for microvascular density showed significantly higher values in HD ATO treated animals compared to HD OXY and LD ATO, which is again, an interesting, however, contradictory point to what is known so far. While there is no longlasting difference in the OXY to ATO groups in the microvascular analysis over time (diameter, RBCV, FMD), a marked difference could be detected especially of the HD ATO group in the CD31 staining. Especially the difference to the LD ATO seems to be interesting, with the overall lowest microvascular density compared to the other groups. This is again in contrast to what is known on the use of atosiban. Zhu et al. could demonstrate that the use of atosiban (10 $\mu$ M) significantly suppressed the angiogenic properties of HUVECs and clearly showed inhibitory function in comparison to oxytocin in their study (Zhu et al. 2017). Zhu et al. therefore concluded the proangiogenic role for oxytocin and its receptor (Zhu et al. 2017). However, this could not be detected in our study with HD ATO treatment.

Cellular behaviour differed sometimes between fibroblasts and keratinocytes with regard to oxytocin treatment in our study. These results, however, are not surprising since both cell types are of different origin, showing different behaviour patterns for migration and secretion. In the case of fibroblasts there seems to be an effect, which is comparable to the control group which was treated by 10% FCS only. Interestingly, the exposure to bFGF was not able to increase the proliferation rate of fibroblasts during the observation time frame of 240 min.

Though, the values of the bFGF and 10% FCS group are in accordance what could be shown previously (Sorg et al. 2009). The impairment of the keratinocytes in the wound scratch assays at 72h are interesting. It can be seen throughout the three time points of evaluation, that the treatment with OXY 100 showed decreased keratinocyte migration, which then got significant at 72h. The differences range about 10%, which therefore seems to be negligible, even when there is a statistical significant difference.”

3. Abstract (and also discussion): The statement “Therefore, the recently published data showing improvement of wound healing by oxytocin might be due to the activation of other pathways” is not plausible. Why should oxytocin activate other pathways in other studies? The signaling cascades activated by oxytocin-oxytocin receptor interaction are well known and are always identical. This cannot be an explanation for the contradictory findings!

The reviewer is absolutely right by stating this. The authors however, did not want to doubt the oxytocin-oxytocin receptor interaction, however, rather wanted to underscore a potential other downstream cascade, which might be responsible for these effects. As demonstrated in previously published work, the oxytocin receptor could be verified in the wound microenvironment (Poutahidis et al. 2013). Here, the receptor is expressed in human foreskin fibroblasts but as well in dermal fibroblasts and keratinocytes (Kinsey et al. 2007; Deing et al. 2013; Denda et al. 2012). However, oxytocin itself is expressed in human skin and can be predominantly localized in the epidermis (Denda et al. 2012). Polymerase chain reaction studies confirmed the expression of oxytocin in both skin and cultured epidermal keratinocytes (Denda et al. 2012). Moreover, oxytocin is expressed not only in keratinocytes (Kinsey et al. 2007), but also in human-skin-derived dermal fibroblasts (Deing et al. 2013). Immunohistochemical stainings of oxytocin in human skin confirmed an expression of oxytocin in all epidermal layers (Deing et al. 2013). The oxytocin receptor, however, was preferentially expressed in the basal layers (Deing et al. 2013). Deing and colleagues could also demonstrate that the inhibition of the oxytocin receptor signalling revealed an impact of oxytocin on the modulation of oxidative stress and cytokine release in dermal fibroblasts and keratinocytes (Deing et al. 2013). Furthermore, oxytocin receptor knockdown was associated to an increased susceptibility to oxidative stress of skin cells (Deing et al. 2013). Due to this knowledge, oxytocin seems to play an important role in skin wound healing issues. However, until now the used transmitter system seems not to be clarified in detail and it might be proposed that it is associated to the stress response of the organism to various stimuli (Uvnäs-Moberg et al. 2005; Vitalo et al. 2009; Simsek et al. 2012).

The above mentioned points have been changed and added to the discussion section of the revised version of the manuscript marked by red font and underlining and reads as follows: “As demonstrated in previously published work, the oxytocin receptor could be verified in the wound microenvironment (Poutahidis et al. 2013). Here, the receptor is expressed in human foreskin fibroblasts but as well in dermal fibroblasts and keratinocytes (Kinsey et al. 2007; Deing et al. 2013; Denda et al. 2012). However, oxytocin itself is expressed in human skin and can be predominantly localized in the epidermis (Denda et al. 2012). Polymerase chain reaction studies confirmed the expression of oxytocin in both skin and cultured epidermal keratinocytes (Denda et al. 2012). Moreover, oxytocin is expressed not only in keratinocytes (Kinsey et al. 2007), but also in human-skin-derived dermal fibroblasts (Deing et al. 2013). Immunohistochemical stainings of oxytocin in human skin confirmed an expression of oxytocin in all epidermal layers (Deing et al. 2013). The oxytocin receptor, however, was preferentially expressed in the basal layers (Deing et al. 2013). Deing and colleagues could also demonstrate that the inhibition of the oxytocin receptor signalling revealed an impact of oxytocin on the modulation of oxidative stress and cytokine release in dermal fibroblasts and keratinocytes (Deing et al. 2013). Furthermore, oxytocin receptor knockdown was associated to an increased susceptibility to oxidative stress of skin cells (Deing et al. 2013). As many different groups reported about reduced stress levels, it might be likely that the change of glucocorticoid receptors or the cortisol levels as well as the overall reduction of stress-induced radical formation could be accounted for the assessed results (Pettersson et al. 2001). Furthermore, insulin-like growth factor (IGF)-1 might also be a candidate for the mediation of OXY-effects, as OXY-treated rats with musculocutaneous flaps showed better flap survival and had significantly elevated IGF-1 plasma levels (Pettersson et al. 1998). Due to this knowledge, oxytocin seems to play an important role in skin wound healing issues. However, until now the used transmitter system seems not to be clarified in detail and it might be proposed that it is associated to the stress response of the organism to various stimuli (Uvnäs-Moberg et al. 2005; Vitalo et al. 2009; Simsek et al. 2012).”

- Deing V, Roggenkamp D, Kühnl J, Gruschka A, Stüb F, Wenck H, et al. Oxytocin modulates proliferation and stress responses of human skin cells: implications for atopic dermatitis. *Experimental Dermatology*. 2013 May 27;22(6):399–405.
- Denda S, Takei K, Kumamoto J, Goto M, Tsutsumi M, Denda M. Oxytocin is expressed in epidermal keratinocytes and released upon stimulation with adenosine 5'-[γ-thio]triphosphate in vitro. *Experimental Dermatology*. 2012 May 14;21(7):535–7.
- Kinsey CG, Bussolati G, Bosco M, Kimura T, Pizzorno MC, Chernin MI, et al. Constitutive and ligand-induced nuclear localization of oxytocin receptor. *J Cell Mol Med*. 2007 Jan;11(1):96–110.
- Pettersson M, Lundeberg T, Sohlström A, Wiberg U, Uvnäs-Moberg K. Oxytocin increases the survival of musculocutaneous flaps. *Naunyn-Schmiedeberg's Arch Pharmacol*. 1998 May 31;357(6):701–4.
- Pettersson M, Wiberg U, Lundeberg T, Uvnäs-Moberg K. Oxytocin decreases carrageenan induced inflammation in rats. *Peptides*. 2001

Sep;22(9):1479–84.

- Poutahidis T, Kearney SM, Levkovich T, Qi P, Varian BJ, Lakritz JR, et al. Microbial Symbionts Accelerate Wound Healing via the Neuropeptide Hormone Oxytocin. Gaetani S, editor. PLoS ONE. 2013 Oct 30;8(10):e78898.
- Simsek Y, Celik O, Karaer A, Yilmaz E, Gul M, Ozerol E, et al. Elevated cardiac oxidative stress in newborn rats from mothers treated with atosiban. Arch Gynecol Obstet. 2011 Aug 25;285(3):655–61.
- Uvnäs-Moberg K, Alster P, Petersson M. Dissociation of oxytocin effects on body weight in two variants of female Sprague-Dawley rats. Integr Physiol Behav Sci. 1995 Dec 31;31(1):44–55.
- Vitalo A, Fricchione J, Casali M, Berdichevsky Y, Hoge EA, Rauch SL, et al. Nest Making and Oxytocin Comparably Promote Wound Healing in Isolation Reared Rats. Hashimoto K, editor. PLoS ONE. 2009 May 13;4(5):e5523.

Minor comments:

1. Page 3, line 19: “stimulated” must read “stimulates”

This has been corrected. Please see the revised version of the manuscript marked by red font and underlining.

2. Page 4: Please explain the varying numbers of animals in the different groups. Why didn't the authors choose an identical group size of e.g. n = 8? The differences in group sizes may have markedly affected the statistical analysis!

The reviewer is right in his comment on different sized groups. This is related to animals which have been excluded from the study, mainly by problems with the dorsal skin fold chamber, which had been implanted to the back of the mice. All groups started with nine animals, however, not all animals could then be included into the study. This does therefore not undermine the validity as can be seen by many other groups as well our own published results.

- Dhall S, Wijesinghe DS, Karim ZA, Castro A, Vemana HP, Khasawneh FT, Chalfant CE, Martins-Green M. Arachidonic acid-derived signaling lipids and functions in impaired healing. Wound Repair Regen. 2015 Sep;23(5):644-56
- Michael S, Sorg H, Peck CT, Reimers K, Vogt PM. The mouse dorsal skin fold chamber as a means for the analysis of tissue engineered skin. Burns. 2013 Feb;39(1):82-8.
- Olekson MA, Faulknor R, Bandekar A, Sempkowski M, Hsia HC, Berthiaume F. SDF-1 liposomes promote sustained cell proliferation in mouse diabetic wounds. Wound Repair Regen. 2015 Sep;23(5):711-23.
- Poutahidis T, Kearney SM, Levkovich T, Qi P, Varian BJ, Lakritz JR, Ibrahim YM, Chatzigiagos A, Alm EJ, Erdman SE. Microbial symbionts accelerate wound healing via the neuropeptide hormone oxytocin. PLoS One. 2013 Oct 30;8(10):e78898
- Sorg H, Krueger C, Schulz T, Menger MD, Schmitz F, Vollmar B. Effects of erythropoietin in skin wound healing are dose related. FASEB J. 2009 Sep;23(9):3049-58
- Sorg H, Schulz T, Krueger C, Vollmar B. Consequences of surgical stress on the kinetics of skin wound healing: partial hepatectomy delays and functionally alters dermal repair. Wound Repair Regen. 2009 May-Jun;17(3):367-77.
- Vinish M, Cui W, Stafford E, Bae L, Hawkins HK, Allen Cox R, Toliver-Kinsky T. Dendritic cells modulate burn wound healing by enhancing early proliferation. Wound Repair Regen. 2015 Nov 26.

3. Page 4: “At the end of the experiments blood was collected” - for what ? There are no results reporting analyses of blood samples.

According to this comment we have added the following paragraph in the revised version of the manuscript marked by red font and underlining and reads now as follows: “Laboratory analysis. Blood samples of saline-treated controls as well as of OXY and ATO treated animals revealed physiological, not statistically significant different values for erythrocytes, leukocytes, platelets as well as hemoglobin and hematocrit (data not shown).”

For the information of the reviewer we present the laboratory analysis as stated in the below table given as means±SEM:

groups erythrocytes leukocytes platelets hemoglobin hematocrit

unit x 10<sup>-12</sup> /l x 10<sup>-9</sup> /l x 10<sup>-9</sup> /l mmol/l/l/l

control 7.5±0.7 5.3±0.9 929±161 7.4±0.6 0.43±0.10

LD OXY 8.1±0.2 5.5±0.6 1112±41 8.0±0.1 0.42±0.01

HD OXY 8.0±0.1 6.5±0.9 1042±57 7.9±0.2 0.42±0.01

LD ATO 8.5±0.5 6.1±0.6 1180±92 8.4±0.5 0.45±0.03

HD ATO 7.8±0.2 8.7±1.6 893±170 7.5±0.3 0.40±0.9

4. Page 4: Please add the exact doses of anesthetics.

We have added this information to the revised version of the manuscript marked by red font and underlining, which reads now as follows:

"...mice were anesthetized intraperitoneally with a mixture of ketamine (90 mg/kg body weight; Ketamin 10%, Bela-Pharm, Vechta, Germany) and xylazine (25 mg/kg body weight; Rompun 2%, Bayer Health Care, Leverkusen, Germany)."

5. Page 5: The description of the image analysis is poor. The authors should provide more details. How many vessels were analyzed for diameter and flow measurements. How were they selected - randomly or not? Please also explain the exact meaning of the statement: "The three-dimensional aspect of the wound was considered by focusing through the depth of the wound" - does it mean that different focus areas were analyzed? How many? Do the data show the mean of these areas?

We thank the reviewer for this comment and have described the image analysis now in more detail. The analysis of the different microvascular parameters has been done in 2-4 consecutive areas of clear visibility. This could be reached by focusing through the wound considering the three dimensional aspect of the wound. In the respective areas 2-4 different vessels, which belonged to the chosen area for the FMD measurements, have been used for the analysis of the diameter and the RBCV. The presented data show the mean values of the analyzed areas.

Please see the revised version of the manuscript marked by red font and underlining, which reads now as follows: "For the analysis of the different microvascular parameters 2-4 consecutive areas have been used with clear visibility, which could be reached by focusing through the wound considering the three dimensional aspect of the wound. In the respective areas 2-4 different vessels, which belonged to the chosen area for the FMD measurements, have been used for the analysis of the diameter and the RBCV. The presented data show the mean values of the analyzed areas."

6. Results section: The passages explaining the statistical results read awkward and confusing. Are they really necessary?

We agree with the reviewer. We wanted to underscore that there are some time effects within the groups, which, as the reviewer rightly said, are confusing and therefore not necessary. We have deleted this part in the revised version of the manuscript.

7. Page 8: Although the authors cite the study of Sorg et al. (2007), they should provide their own representative images of the "inner and outer vascular ring". Otherwise, the results section and the performed microcirculatory analyses are difficult to understand. According to the recommendation of the reviewer we have added another figure, which will better describe the performed microcirculatory analyses. Please see therefore the new figure 1.

8. Figure 1: The interpretation of the images in A is difficult. Please show additional images of day 6 or 9 displaying areas of epithelialization vs. non-epithelialized areas. How did the authors exactly identify epithelialized areas on these low-resolution images? The legend in B is wrong (two times white bar).

We have added additional pictures for day 6 post wounding. Please see new figure 2 in the revised version of the manuscript. The epithelialized area could be clearly seen by a border of newly formed skin tissue, which has been marked by a border of a light red to even sometimes white color. We apologize for not showing color images, however, the video system was not able to record colored images. Furthermore, there exist many different measurements to analyze the re-epithelialization of skin wounds. The histological measurement of the gap tissue area could not be performed, as this would require serially cut histological skin tissue specimen of at least 6-9 animals per group and day (n=150-225 animals) in order to achieve standardized evaluated results. In order to minimize the number of experimental animals the authors refrained from this approach. The legend in B has been corrected.

9. Figure 2: The legend in D is wrong (two times white bar).

This has been corrected. Please see the new figure 3 in the revised version of the manuscript marked by red font and underlining.

10. Figure 3: The authors should add images of the control group in A and C. Moreover, the images in A and C markedly differ between the groups. This does not support the result that there were no significant differences between the groups. Please provide more representative images! Scale bars are not explained in the figure legend.

This has been amended with images of the control group and presenting representative images of the groups. Please see the new figure 4 for cellularity and the new figure 5 for the CAE staining.

11. Figure 4: The authors should add an image of the control group in A. Scale bars are missing.

This has been amended with an image of the control group. Please see the new figure 6 in the revised version of the manuscript.



12. Figure 5: In A “fibroblast” should read “fibroblasts”.

This has been corrected. Please see the new figure 7 in the revised version of the manuscript.

Authors’ point-by-point reply to the comments of the **reviewer #2**:

The authors thank reviewer 2 for the nice comments and the constructive criticism to improve the content of the paper. We appreciate this and have followed all detailed comments to clarify the manuscript.

1. First of all, I congratulate the authors for submitting a manuscript describing negative results because of the utmost importance to point out missing effects.

We kindly thank the reviewer for this comment, as we also find it very important to publish negative results, which are also contradictory to what is published elsewhere.

2. Secondly, the experimental animal model used for this study is extremely important and helpful. The stretch of the dorsal chamber mimics human wound repair to a greater degree in comparison to ordinary full-thickness excisional skin wounds in rodents. This fact should be emphasized much more in detail in the discussion - also with regard to diverging results in comparison with literature.

Thank you for this comment. We have added an ongoing and detailed discussion about the used model and the contradictory results to what is known in literature. Please see the revised version of the manuscript marked by red font and underling. This part now reads as follows:”

The model of the dorsal skin fold chamber in rodents displays a standardized technique, which allows a multifaceted use in experimental research (Laschke et al. 2011; Laschke et al. 2016). Besides this technique a variety of other in vivo (Breuing et al. 1992; Rossio-Pasquier et al. 2008; Escamez et al. 2004, Geer et al. 2010) and in vitro models (Harrison et al. 2005; Kamamoto et al. 2003) exist, however, only a limited number include the possibility of direct microcirculatory analysis during the process of dermal restoration (Roesken et al. 2000; Vollmar et al. 2002; Uhl et al. 2003; Langer et al. 2006). In general, animal models are only able to mimic physiological as well as pathological human wound healing problems, with dehiscence, ischemia, ulceration, infection, and scarring (Davidson, 1998). Though, variances in the tissue architecture, in the immune system functions and general physiology among animals in contrast to humans must be taken into consideration (Sorg et al. 2007).

- Breuing K, Eriksson E, Liu P, Miller DR. Healing of partial thickness porcine skin wounds in a liquid environment. *J Surg Res* 1992;52, 50–58.
- Davidson JM. Animal models for wound repair. *Arch Dermatol Res* 1998;290 (Suppl.), S1–11.
- Escamez MJ, Garcia M, Larcher F, et al.. An in vivo model of wound healing in genetically modified skin-humanized mice. *J Invest Dermatol* 2004; 123, 1182–1191.
- Geer DJ, Swartz DD, Andreadis ST. In vivo model of wound healing based on transplanted tissue-engineered skin. *Tissue Eng* 2004;10, 1006–1017.
- Harrison CA, Heaton MJ, Layton CM, Mac Neil S. Use of an in vitro model of tissue-engineered human skin to study keratinocyte attachment and migration in the process of reepithelialization. *Wound Repair Regen* 2006;14, 203–209.
- Kamamoto F, Paggiaro AO, Rodas A, Herson MR, Mathor MB, Ferreira MC. A wound contraction experimental model for studying keloids and wound-healing modulators. *Artif Organs* 2003; 27, 701–705.
- Laschke MW, Menger MD. The dorsal skinfold chamber: A versatile tool for preclinical research in tissue engineering and regenerative medicine. *Eur Cell Mater.* 2016 Sep 20;32:202-15.
- Laschke MW, Vollmar B, Menger MD. The dorsal skinfold chamber: window into the dynamic interaction of biomaterials with their surrounding host tissue. *Eur Cell Mater.* 2011 Sep 20;22:147-64; discussion 164-7.
- Roesken F, Uhl E, Curri SB, Menger MD, Messmer K. Acceleration of wound healing by topical drug delivery via liposomes. *Langenbecks Arch Surg* 2000;385, 42–49.
- Rossio-Pasquier P, Casanova D, Jomard A, Demarchez M. Wound healing of human skin transplanted onto the nude mouse after a superficial excisional injury: human dermal reconstruction is achieved in several steps by two different fibroblast sub- populations. *Arch Dermatol Res* 1999;291, 591–599.
- Sorg H, Krueger C, Vollmar B. Intravital insights in skin wound healing using the mouse dorsal skin fold chamber. *J Anat.* 2007 Dec;211(6):810-8.
- Uhl E, Rosken F, Sirsjo A, Messmer K. Influence of platelet- derived growth factor on microcirculation during normal and impaired wound healing. *Wound Repair Regen* 2003; 11, 361– 367.

- Vollmar B, El-Gibaly AM, Scheuer C, Strik MW, Bruch HP, Menger MD. Acceleration of cutaneous wound healing by transient p53 inhibition. *Lab Invest* 2002;82, 1063–1071.

For the discussion of the diverging results please see also comment No. 5.

3. Animal models are supposed to mimic human wound healing. This is in fact extremely difficult since human skin wound repair is unique with regard to excessive scarring or chronic non-healing wounds. This should be emphasized in the discussion.

We paid respect to this important notice and have added this to the revised version of the manuscript. Please see comment no. 2.

4. Interestingly, cellular behaviour differed enormously between fibroblasts and keratinocytes with regard to oxytocin treatment. This result is not astonishing since both cell types are of different origin and show different migrational and secretional behaviour patterns. This is a very important finding and should also be discussed more in the discussion.

We have discussed our results in the discussion section in more detail, which now reads as follows: "Cellular behaviour differed sometimes between fibroblasts and keratinocytes with regard to oxytocin treatment in our study. These results, however, are not surprising since both cell types are of different origin, showing different behaviour patterns for migration and secretion. In the case of fibroblasts there seems to be an effect, which is comparable to the control group which was treated by 10% FCS only. Interestingly, the exposure to bFGF was not able to increase the proliferation rate of fibroblasts during the observation time frame of 240 min. Though, the values of the bFGF and 10% FCS group are in accordance what could be shown previously (Sorg et al. 2009). The impairment of the keratinocytes in the wound scratch assays at 72h are interesting. It can be seen throughout the three time points of evaluation, that the treatment with OXY 100 showed decreased keratinocyte migration, which then got significant at 72h. The differences range about 10%, which therefore seems to be negligible, even when there is a statistical significant difference." (marked by red font and underlining).

- Sorg H, Schulz T, Krueger C, Vollmar B. Consequences of surgical stress on the kinetics of skin wound healing: partial hepatectomy delays and functionally alters dermal repair. *Wound Repair Regen.* 2009 May-Jun;17(3):367-77.

6. Since oxytocin has an effect on inflammation, were there any differences with regard to inflammatory cell count in wounds?

In the here presented work leukocytes in the skin wound granulation tissue were stained by the AS-D chloroacetate esterase (CAE) technique and were identified by positive staining and morphology within the granulation tissue per tissue specimen. Wounds of HD OXY animals revealed a 2-fold lower number of infiltrating white blood cells compared to controls or the other OXY-treated group. Though the data has not been statistically significant, it still shows the low effect of leukocytes within the granulation tissue of HD OXY-treated animals in comparison to control animals, indicating that decreased numbers of leukocytes might further contribute to better, at least not worsened, skin regeneration by a reduced inflammatory reaction (Luster et al. 1998; Rico et al. 2002). Wound cellularity is a commonly established parameter for the resolution of granulation tissue and/or inflammatory cells (Chebotaev et al. 2007; Palmer et al. 2007). It is proposed that successful wound repair requires the resolution of inflammation and vice versa, sustained inflammation is associated with poor healing, being reflected by high wound cellularity (Eming et al. 2007). However, no statistical significant difference could be determined among groups.

These facts, as well as an amended discussion about the anti-inflammatory and anti-oxidant effect of oxytocin were added to the discussion section, marked by red font and underlining, which now reads as follows: "It has also been suggested that OXY might be involved in the modulation of the immune process and the inflammatory reaction via OXY receptors located in the thymus (Elands et al. 1990). This might be due to the fact of less concentrations of TNF-alpha and IL-6, a decreased rate of apoptosis, diminished neutrophil recruitment and less lipid peroxidation in the different organs under investigation (Iseri et al. 2008). In this context, OXY has been described to act as an anti-inflammatory agent via the increase of corticosterone levels even after a single OXY-injection (Uvnäs-Moberg et al. 2005; Petersson et al. 1999; Petersson et al. 2001; Gibbs et al. 1984) as well as an anti-oxidant via regulation of the oxidant-anti-oxidant status (Düsünceli et al. 2008; Tugtepe et al. 2007; Tas Hekimoğlu et al. 2013; Iseri et al. 2005). Furthermore, the anti-inflammatory OXY action was recently been reported to be a direct neutrophil-dependent mechanism, ameliorating the oxidative organ damage (Iseri et al. 2005; Biyikli et al. 2006). In our study wounds of HD OXY animals revealed a 2-fold lower number of infiltrating WBC compared to controls or the other OXY-treated group. Though the data has not been statistically significant different, it still shows the decreased effect of leukocytes within the granulation tissue of HD OXY-treated animals in comparison to control animals, indicating that decreased numbers of leukocytes might further contribute to better, at least not worsened, skin regeneration by a reduced inflammatory reaction (Luster et al. 1998; Rico et al. 2002)."

- Biyikli NK, Tuğtepe H, Şener G, Velioğlu-Öğünç A. Oxytocin alleviates oxidative renal injury in pyelonephritic rats via a neutrophil-dependent mechanism. *Peptides.* 2006:2249-2257.
- Chebotaev DV, Yemelyanov AY, Lavker RM, Budunova IV. Epithelial cells in the hair follicle bulge do not contribute to epidermal regenera-

tion after glucocorticoid-induced cutaneous atrophy. *J Invest Dermatol* 2007;127:2749-2758

- Düşünceli F, İşeri SO, Ercan F, Gedik N, Yeğen C, Yeğen BÇ. Oxytocin alleviates hepatic ischemia-reperfusion injury in rats. *Peptides*. 2008;29:1216–22.
- Elands J, Resink A, De Kloet ER. Neurohypophyseal hormone receptors in the rat thymus, spleen, and lymphocytes. *Endocrinology*. 1990;126:2703–10.
- Eming SA, Krieg T, Davidson JM. Inflammation in wound repair: molecular and cellular mechanisms. *J Invest Dermatol* 2007;127:514-525
- Gibbs DM, Vale W, Rivier J, Yen SS. Oxytocin potentiates the ACTH-releasing activity of CRF(41) but not vasopressin. *Life Sci*. 1984;34:2245–9.
- İşeri SÖ, Gedik İE, Erzic C, Uslu B, Arbak S, Gedik N, et al. Oxytocin ameliorates skin damage and oxidant gastric injury in rats with thermal trauma. *Burns*. 2008;34:361–9.
- İşeri SÖ, Şener G, Sağlam B, Gedik N, Ercan F, Yeğen BÇ. Oxytocin ameliorates oxidative colonic inflammation by a neutrophil-dependent mechanism. *Peptides*. 2005;26:483–91
- Luster AD, Cardiff RD, MacLean JA, Crowe K, Granstein RD. Delayed wound healing and disorganized neovascularization in transgenic mice expressing the IP-10 chemokine. *Proc Assoc Am Physicians* 1998;110:183-196
- Palmer G, Talabot-Ayer D, Kaya G, Gabay C. Type I IL-1 receptor mediates IL-1 and intracellular IL-1 receptor antagonist effects in skin inflammation. *J Invest Dermatol* 2007;127:1938-1946
- Petersson M, Hulting A, Andersson R, Uvnäs-Moberg K. Long-term changes in gastrin, cholecystokinin and insulin in response to oxytocin treatment. *Neuroendocrinology*. 1999;69:202–8.
- Petersson M, Wiberg U, Lundeberg T, Uvnäs-Moberg K. Oxytocin decreases carrageenan induced inflammation in rats. *Peptides*. 2001;22:1479–84.
- Rico RM, Ripamonti R, Burns AL, Gamelli RL, DiPietro LA. The effect of sepsis on wound healing. *J Surg Res* 2002;102:193-197
- Tas Hekimoglu A, Toprak G, Akkoc H, Evliyaoglu O, Ozekinci S, Kelle I. Oxytocin Ameliorates Remote Liver Injury Induced by Renal Ischemia-Reperfusion in Rats. *Korean J Physiol Pharmacol*. 2013;17:169.
- Tuğtepe H, Şener G, Bıyıklı NK, Yüksel M, Çetinel Ş, Gedik N, et al. The protective effect of oxytocin on renal ischemia/reperfusion injury in rats. *Regul Pept*. 2007; 140:101–8.
- Uvnäs-Moberg K, Petersson M. Oxytocin, a mediator of anti-stress, well-being, social interaction, growth and healing. *Z Psychosom Med Psychother*. 2005;51:57–80.

7. Please add a short summary of the wound model to the material and method section.

Thank you for this recommendation, which have included a short summary to the revised version of the manuscript. This part reads now as follows: "In brief, mice were anesthetized intraperitoneally with a mixture of ketamine (90 mg/kg body weight; Ketamin 10%, Bela-Pharm, Vechta, Germany) and xylazine (25 mg/kg body weight; Rompun 2%, Bayer Health Care, Leverkusen, Germany). Two symmetrical titanium frames were implanted to sandwich the extended double layer of the skin. The creation of a full dermal thickness wound was achieved after marking the area with a standardized circular ink stamp (2.5 mm in diameter) and by removing the complete skin down to the panniculus carnosus, thus creating a wound area of 3-6 mm<sup>2</sup>. The non-wounded skin of the opposite side still consisted of epidermis, dermis, and striated skin muscle. The wounded site was covered with a removable glass coverslip incorporated in one of the titanium frames. This model allows visualizing the process of revascularization, angiogenesis and vessel regression in the skin by means of intravital fluorescence microscopy. Additionally, this technique allows the repeated study of the continuing process of skin repair over a period of 2 – 4 weeks. By implantation of the two titanium frames we could avoid wound contraction by positioning the skin in between frames and by this allowing microscopy on a plane tissue level (Sorg et al. 2007).“ marked by red font and underlining.

- Sorg H, Krueger C, Vollmar B. Intravital insights in skin wound healing using the mouse dorsal skin fold chamber. *J Anat*. 2007 Dec;211(6):810-8.

8. It should be also indicated that the in vitro experiments were carried out with human cell lines and not primary cells.

Thank you for this advice. However, L929 fibroblast were of mouse origin. We have added this information in the materials & methods section. This part reads now as follows: "To evaluate the influence of oxytocin on cell proliferation, we assessed the proliferative activity of fibroblasts (L929; mouse) and keratinocytes (HaCaT; human) by water-soluble tetrazolium salt (WST-1) assay (Roche Diagnostics, Mannheim, Germany).“

## Reviewers' Comments to 1<sup>st</sup> Revision

### Reviewer 1: anonymous

Jul 12, 2017

---

**Reviewer Recommendation Term:** Accept with Minor Revision  
**Overall Reviewer Manuscript Rating:** 90

Custom Review Questions	Response
Is the subject area appropriate for you?	5 - High/Yes
Does the title clearly reflect the paper's content?	5 - High/Yes
Does the abstract clearly reflect the paper's content?	4
Do the keywords clearly reflect the paper's content?	4
Does the introduction present the problem clearly?	5 - High/Yes
Are the results/conclusions justified?	4
How comprehensive and up-to-date is the subject matter presented?	4
How adequate is the data presentation?	4
Are units and terminology used correctly?	4
Is the number of cases adequate?	4
Are the experimental methods/clinical studies adequate?	4
Is the length appropriate in relation to the content?	4
Does the reader get new insights from the article?	5 - High/Yes
Please rate the practical significance.	3
Please rate the accuracy of methods.	4
Please rate the statistical evaluation and quality control.	4
Please rate the appropriateness of the figures and tables.	4
Please rate the appropriateness of the references.	4
Please evaluate the writing style and use of language.	4
Please judge the overall scientific quality of the manuscript.	4
Are you willing to review the revision of this manuscript?	Yes

#### Comments to Authors:

The authors have carefully revised their manuscript according to the reviewers' suggestions. They have provided detailed explanations for their revisions and have changed major parts of the original manuscript. I feel that this has markedly improved the quality of this work.

There is only one minor point left:

The authors state that they removed the passages explaining the statistical results from the manuscript, because they read awkward and confusing (see reviewer comment 6). However, these passages are still included in the revised manuscript (see page 9, lines 8-14; page 10, lines 11-16).

---

### Reviewer 2: Ursula Mirastschijski

Jul 12, 2017

---

**Reviewer Recommendation Term:** Accept  
**Overall Reviewer Manuscript Rating:** 100

Custom Review Questions	Response
Is the subject area appropriate for you?	5 - High/Yes
Does the title clearly reflect the paper's content?	5 - High/Yes
Does the abstract clearly reflect the paper's content?	5 - High/Yes
Do the keywords clearly reflect the paper's content?	5 - High/Yes



Does the introduction present the problem clearly?	5 - High/Yes
Are the results/conclusions justified?	5 - High/Yes
How comprehensive and up-to-date is the subject matter presented?	5 - High/Yes
How adequate is the data presentation?	5 - High/Yes
Are units and terminology used correctly?	5 - High/Yes
Is the number of cases adequate?	5 - High/Yes
Are the experimental methods/clinical studies adequate?	5 - High/Yes
Is the length appropriate in relation to the content?	5 - High/Yes
Does the reader get new insights from the article?	5 - High/Yes
Please rate the practical significance.	5 - High/Yes
Please rate the accuracy of methods.	5 - High/Yes
Please rate the statistical evaluation and quality control.	5 - High/Yes
Please rate the appropriateness of the figures and tables.	5 - High/Yes
Please rate the appropriateness of the references.	5 - High/Yes
Please evaluate the writing style and use of language.	5 - High/Yes
Please judge the overall scientific quality of the manuscript.	5 - High/Yes
Are you willing to review the revision of this manuscript?	Yes

**Comments to Authors:**

-

## Authors' Response to Reviewer Comments

Jul 13, 2017

Authors' point-by-point reply to the comments of the **reviewer #1**:

The authors thank reviewer 1 for his comment. The respective passages have now been deleted. We apologize for that.

## Reviewers' Comments to 2<sup>nd</sup> Revision

### Reviewer 1: anonymous

Jul 14, 2017

**Reviewer Recommendation Term:** Accept  
**Overall Reviewer Manuscript Rating:** 90

**Custom Review Questions**

	<b>Response</b>
Is the subject area appropriate for you?	5 - High/Yes
Does the title clearly reflect the paper's content?	5 - High/Yes
Does the abstract clearly reflect the paper's content?	4
Do the keywords clearly reflect the paper's content?	4
Does the introduction present the problem clearly?	5 - High/Yes
Are the results/conclusions justified?	4
How comprehensive and up-to-date is the subject matter presented?	4
How adequate is the data presentation?	4
Are units and terminology used correctly?	4
Is the number of cases adequate?	4
Are the experimental methods/clinical studies adequate?	4

Is the length appropriate in relation to the content?	4
Does the reader get new insights from the article?	5 - High/Yes
Please rate the practical significance.	3
Please rate the accuracy of methods.	4
Please rate the statistical evaluation and quality control.	4
Please rate the appropriateness of the figures and tables.	4
Please rate the appropriateness of the references.	4
Please evaluate the writing style and use of language.	4
Please judge the overall scientific quality of the manuscript.	4
Are you willing to review the revision of this manuscript?	Yes

**Comments to Authors:**

I have no further comments. The manuscript is now acceptable for publication in ISS.

---