

Evaluation of the Anatomic Position of the Mandibular Canal Regarding to the Segments of the Mandibular Sagittal Split Ramus Osteotomy to Diminish the Possibility of Injuries: a Pilot Study

Victor Diniz Borborema dos Santos¹, Salomão Israel Monteiro Lourenço Queiroz¹, Alessandro Costa da Silva², Susana Silva³, José Sandro Pereira da Silva⁴, Gustavo Vicentis de Oliveira Fernandes⁵, Adriano Rocha Germano⁴

¹Federal University of Rio Grande do Norte (UFRN), Brazil.

²Oral and Maxillofacial Surgeon at a Private Practice, São Paulo, SP, Brazil.

³Departamento de Ortodontia da Universidade Católica de Viseu, Viseu, Portugal.

⁴Oral Maxillofacial and Trauma Surgery of the “Hospital Universitário Onofre Lopes”, Federal University of Rio Grande do Norte, Natal, Rio Grande do Norte, Brazil.

⁵Periodontics and Oral Medicine Department, University of Michigan, Ann Arbor, USA.

Corresponding Author:

Gustavo Vicentis de Oliveira Fernandes
University of Michigan School of Dentistry
1011 North Ave., Ann Arbor - MI, 48109
USA
E-mail: gustfernandes@gmail.com

ABSTRACT

Objectives: This pilot study evaluated the relationship between inferior alveolar nerve location through computed tomography scan and intraoperative inferior alveolar nerve entrapment after bilateral sagittal split osteotomy.

Material and Methods: Overall, 20 helicoidal computed tomography scans were evaluated in patients with facial deformities who underwent to bilateral sagittal split osteotomy (BSSO). The distance from the mandibular canal to the internal surface of the buccal and lingual cortical bone, mandibular thickness, bone density and proportion of medullary and cortical bone in 3 regions were evaluated. During the intraoperative period, the segment to which the nerve remained adhered after performing BSSO was analysed, and the data correlated.

Results: The distance from the mandibular canal to the buccal cortical bone showed a mean of 2.6 mm when the inferior alveolar nerve was adhered to the distal segment and mean of 0.7 mm when the nerve was adhered to the proximal segment. The thickness was 11.2 mm and 9.8 mm when the nerve was adhered the distal the proximal segments respectively. Mandibular thickness, distance from the mandibular canal to the buccal and lingual cortical were statistically related to intraoperative nerve entrapment ($P < 0.05$).

Conclusions: Narrow jaws and the distance from the mandibular canal to buccal cortical bone less than 2 mm increases the risk of the inferior alveolar nerve entrapment in bilateral sagittal split osteotomy.

Keywords: anatomy; mandibular nerve; orthognathic surgery; sagittal split ramus osteotomy.

Accepted for publication: 21 December 2022

To cite this article:

dos Santos VDB, Queiroz SIML, da Silva AC, Silva S, da Silva JSP, Fernandes GVO, Germano AR.

Evaluation of the Anatomic Position of the Mandibular Canal Regarding to the Segments of the Mandibular Sagittal Split Ramus Osteotomy to Diminish the Possibility of Injuries: a Pilot Study

J Oral Maxillofac Res 2022;13(4):e2

URL: <http://www.ejomr.org/JOMR/archives/2022/4/e2/v13n4e2.pdf>

doi: [10.5037/jomr.2022.13402](https://doi.org/10.5037/jomr.2022.13402)

INTRODUCTION

Bilateral sagittal osteotomy of the mandibular ramus is the most frequently used procedure for correcting dentofacial deformities of the mandible due to its versatility because it may be used in both mandibular advancement and setback cases as in mandibular asymmetries [1]. This type of osteotomy has many advantages, such as excellent flexibility regarding repositioning the distal segment, adequate bone contact after repositioning the segments, and minimal changes in the position of temporomandibular muscles and joints [2,3].

Some complications may occur after mandibular sagittal split ramus osteotomy, and the most prevalent is paraesthesia of the inferior alveolar nerve (IAN) due to its intraosseous trajectory and the relationship of the surgical site. Thereby, the IAN undergoes excellent risk of suffering either temporary or permanent injuries [2-4]. This nerve disturbance ranges from 50% to 100% [5,6] in the immediate post-operative period. According to Hanzelka et al. [7], the two leading causes of post-operative paraesthesia may be (a) medial retraction of the extraosseous portion of the IAN at the time of horizontal osteotomy of the mandibular ramus [8,9] and (b) manipulation or damage of the IAN during the osteotomies, which is usually caused by the saw, chisels, retractors, retention screws, and during the split of the mandibular ramus, considered the most critical stage concerning damage to the IAN.

The intraoperative position of the nerve and level of manipulation are strictly correlated with post-operative neurosensory disturbance. Therefore, it is preferable for the nerve to remain adhered to the distal segment as long as possible [10]. Kim et al. [3] have also cited hematoma and/or edema formation close to the mandibular and mental foramina, as another source for IAN paraesthesia.

According to Aizenbud et al. [2] and Noleto et al. [11], the preoperative knowledge of the anatomic location and course of the IAN, by means of computed tomography (CT) scan, is essential for reducing complications related to nerve damage. The measurement of this relationship is important to enable surgeons to correlate the mandibular canal anatomy to the design of the osteotomies and thus to prevent or reduce the incidence of postoperative paraesthesia. Some researchers [1,12,13] investigated this relationship. However, the correlation of the nerve anatomy and the intraoperative findings, such as nerve entrapped inside the bone segments, are scarce in the literature [10].

Thus, the aim of this pilot study was to evaluate the relationship of proximity between the anatomic position of the mandibular canal and the intraoperative position of the inferior alveolar nerve, through means from computed tomography scan, after mandibular sagittal split ramus osteotomy.

MATERIAL AND METHODS

Study design and selection criteria

This pilot clinical trial followed the Declaration of Helsinki (1975, updated 2013), it was designed in accordance with guidelines from CONSORT (<http://www.consort-statement.org>) (Figure 1), and previously approved by the local Ethics Committee (Onofre Lopes University Hospital, Natal - Brazil, number: 379,988). After explanation, evaluation, agreement, and signed the informed consent, all the patients performed the mandibular helicoidal CT imaging exams in the preoperative period.

Moreover, they were also registered in a standardized form that contained some general data, such as name, age, gender, race, address, and professional occupation. Anatomy of the mandibular ramus evaluated using three-dimensional computed tomography scan images, type of dentofacial deformity, type of orthognathic surgery planned, and any uneventful intraoperative event regarding mandibular osteotomy technique (amount of mandibular advancement or setback, unfavourable mandibular fracture, neurovascular bundle section and whether the bundle of nerve remained adhered to the proximal segment of the sagittal osteotomy) were recorded.

The participants (n = 20) in this prospective, cohort, and pilot study had dentofacial deformities, who were submitted to orthognathic surgery that involved bilateral mandibular sagittal split ramus osteotomy (n = 40, mandibular sagittal split ramus osteotomies), and were treated by the Residency Program in Oral and Maxillofacial Surgery and Traumatology of the Onofre Lopes University Hospital of the Federal University of Rio Grande do Norte (UFRN, Brazil), between September 2013 and December 2014 (Figure 1).

The inclusion criteria were the patients with dentofacial deformities, referred for orthognathic surgery including bilateral mandibular sagittal split ramus osteotomy according to the technique of Trauner and Obwegeser [13], modified by Dal Pont [14], and Hunsuck [15]. Patients were classified as ASA I and II (American Society of Anesthesiologist - ASA) and also classified as

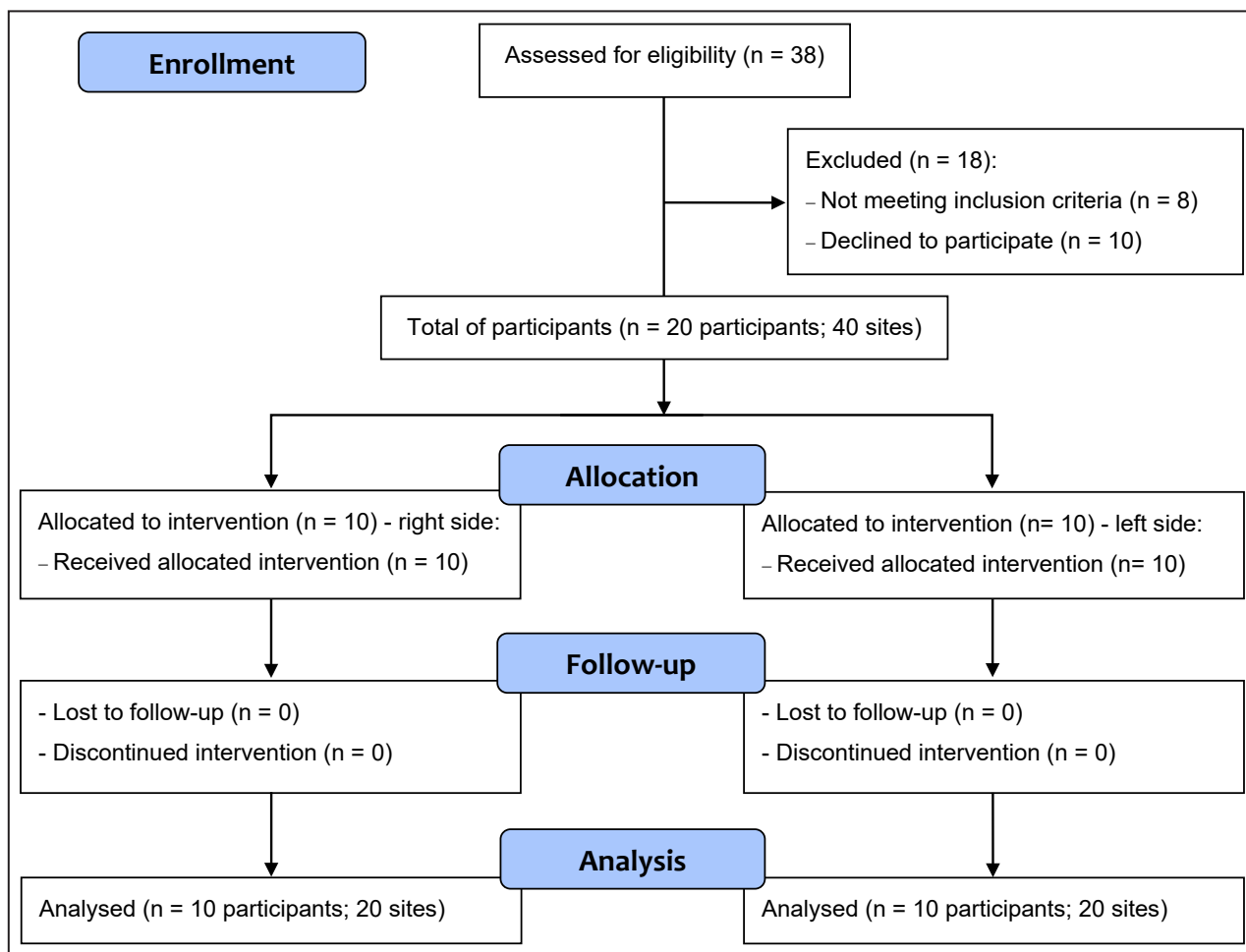


Figure 1. Consort flow diagram.

Goldman Class I and II. Excluded from this study, were claustrophobic patients and/or severely obese patients (weighing over 350 lb), due to the needed to be submitted to preoperative CT scan in a hospital facility. Patients classified as ASA III, IV, and V, and Goldman Class III and IV were also excluded due to the risks inherent to general anaesthesia.

Image characteristics

The analyses were made by means of helicoidal CT (Phillips Brilliance CT 64 channels - Philips Healthcare; Cleveland, Ohio, USA) with slice thickness of 1 mm, reconstruction interval of 1 mm, bone (enhancement) filter, field of view of 16 cm - vertex/suprahyoid. After capturing the axial images, the native images were saved in universal DICOM format. The original data of the CTs were stored in a removable media for posterior reading and analysis at an independent workstation. For measurement of the distances, graphic computation tools would be used to obtain the para-sagittal/coronal views. Analysis of the bone area and density were made by means of

calculating the ROIs within the respective reference lines traced. For this effect, the OsiriX imaging software version 5.0.2 (Pixmeo SARL; Bernex, Switzerland) was used.

Image analysis

The mandibular thickness measurements, distance of the internal aspect between the buccal and lingual cortical plates in relation to the mandibular canal (Figure 2), as well as the measurements of the medullar/cortical bone proportion and density, measured in Hounsfield units (Figure 3), were taken in three different points of the mandible, by means of transversal/coronal views of the helicoidal CT images, and were based on guidelines. Line “A”, which passes in the region of the second molar furcation and follows parallel to the long axis of the mandibular second molar, and line “B” found in the region corresponding to the furcation of the third molar and is parallel to the long axis of the mandibular second molar. The points evaluated were situated in the area of the intersection lines with the mandibular canal as follows: “Point A” is localized at the intersection of

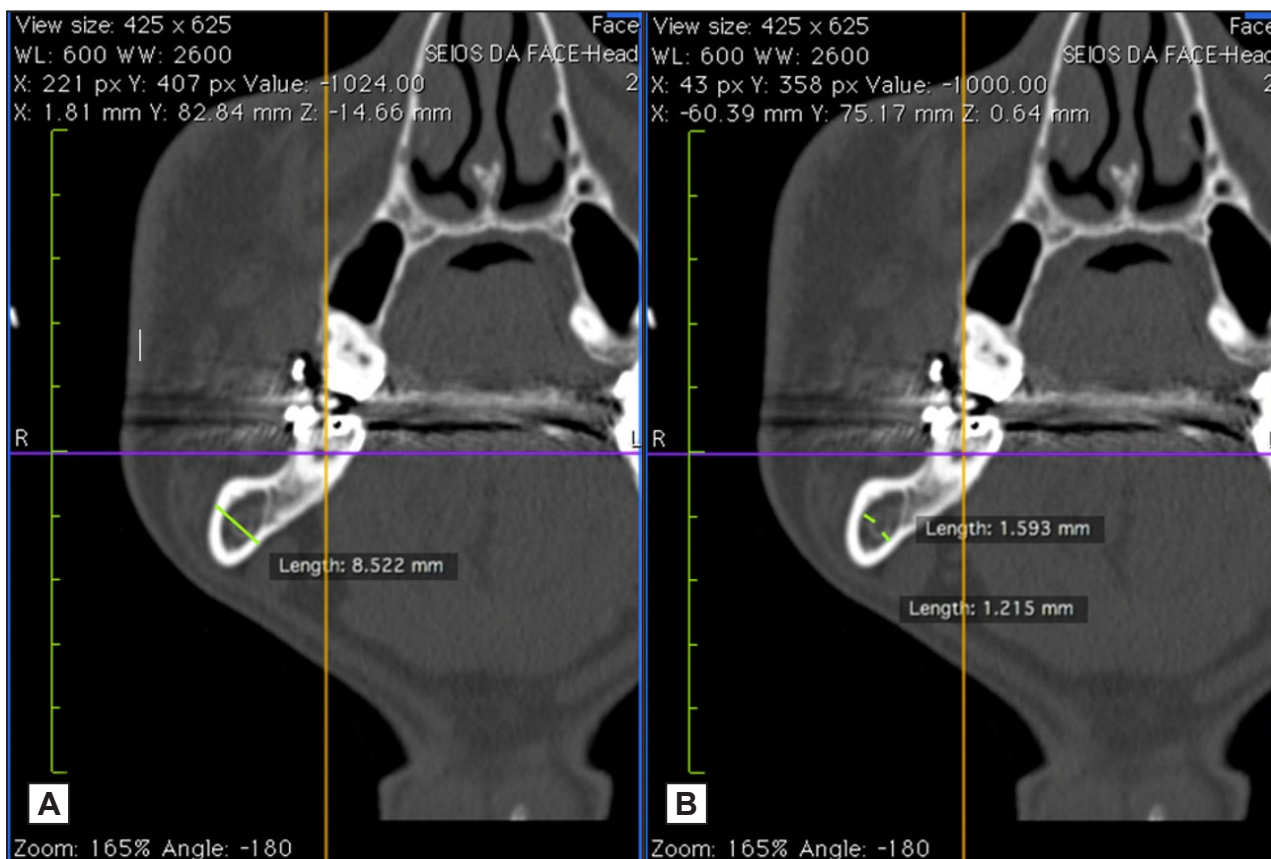


Figure 2. A = mandibular thickness measurement. B = measurement of the distance from the mandibular canal to the internal surface of the buccal cortical bone and measured from the distance of the mandibular canal to the internal surface of the lingual cortical bone.

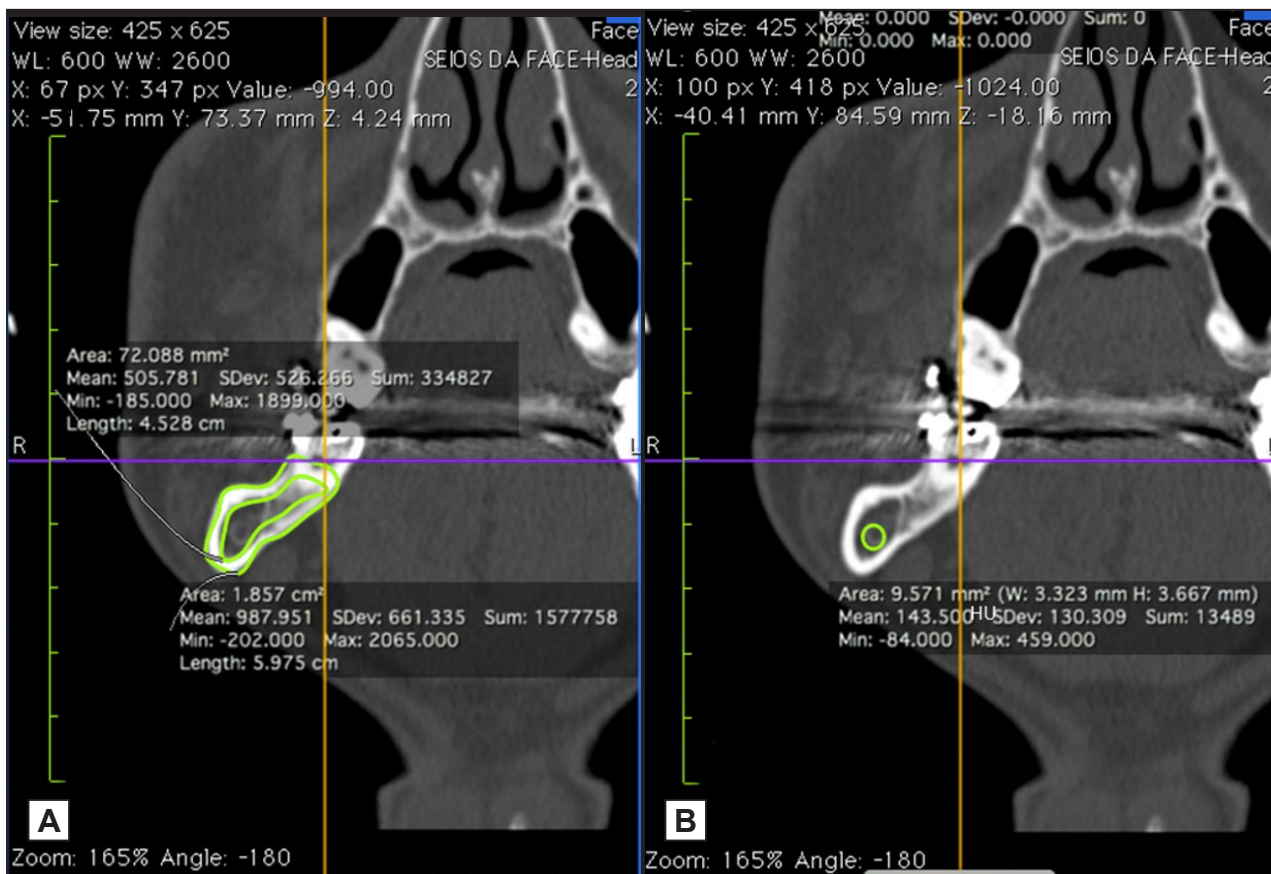


Figure 3. A = evaluation of the area of the cortical and medullary bone. B = area of bone density evaluation (Hounsfield units).

line “A” with the mandibular canal; “point B” at the intersection of line “B” with the mandibular canal. In addition, a third point (C) was evaluated. This point was in the site immediately anterior to the mandibular lingula, where the mandibular canal was found to be completely corticalized (in the CT image) (Figure 4). The evaluations were made in the 3 points in isolation. Measurement of the cortical and medullary bone proportion was made from the absolute measurements of the cortical and medullary areas in mm². The proportion of cortical and medullary bone at each point evaluated was obtained in the three points in conjunction.

All the measurements were made three times, by two referees (V.D.B.S. and G.V.O.F.), individually, by visualization and diagnosis in CT images, independently, with an interval of 5 days between measurements, in a room with a controlled light and free of external stimuli. Afterwards, the means of the 3 measurements made were obtained and inter-observer and intra-observer agreement was calculated. Kappa values between 0 and 0.4 means bad agreement, 0.5 and 0.85 moderate agreement, and between 0.86 and 1.0 high level of agreement.

The intraoperative position of the IAN bundle after mandibular sagittal split ramus osteotomy was divided into two possible sites: (a) distal segment; (b) proximal segment. The nerve was classified as being present in the distal segment when it fitted in with the type I and II classifications of Hanzelka et al. [7] and did not require surgical manipulation; it was classified as being in the proximal segment when it fitted in with the types III and IV, therefore, requiring manipulation of the nerve during the surgical procedure.

Statistical analysis

Data analysis was performed with the SPSS software (Statistical Package for Social Sciences for Windows, v.22). After the verification of the normality of the data (Kolmogorov-Smirnov test), the student's t-test was applied to find significant difference for the variables studied (thickness, MC-BC, MC-LC, medullary bone, cortical bone, and Hounsfield units [HU]). To verify significant association, the Pearson Chi-square and Exact Fisher tests were used. Values of $P < 0.05$ were considered significant. Parametric and non-parametric data were expressed as mean and standard deviation (M [SD]).

RESULTS

Among the 20 participants, 11 (55%) female and

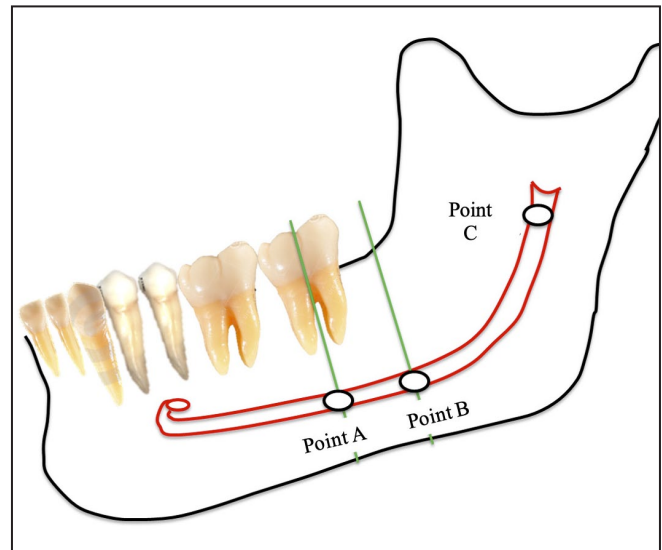


Figure 4. Points used for evaluating the variables in the computed tomography image.

9 (45%) males, with a mean age of 23 years and an age range between 17 and 40 years (Figure 1). Two out of 20 patients were submitted to mandibular sagittal split ramus osteotomy only; 12 were submitted to Le Fort I osteotomy; and 6 patients to Le Fort I osteotomy and mentoplasty, in addition to mandibular sagittal split ramus osteotomy. Then, a total of 40 mandibular sagittal split ramus osteotomies were evaluated.

The relation of the anatomical characteristics with gender

When the female gender was separately evaluated, 22 sagittal split osteotomies were verified; in 13 (59%), the nerve was adhered to the distal segment and 9 (41%) to the proximal segment. Whereas in the male gender, 18 sagittal split osteotomies occurred, the nerve remained adhered to the distal segment in 13 (72.2%) and 5 in the proximal segment (27.8%). All data were detailed in Table 1.

In the evaluation of the mean bone thickness value, there was no statistically significant correlation between the genders, with patients of the male sex showing values of 11.3 mm at point “A”, 9.5 mm at point “B”, 7.3 mm at point “C”. Whereas in the female sex, the mean bone thickness at point “A” was 10.5 mm, at point “B”, 9.1 mm, and at point “C” was 6.6 mm.

The measurements of the distance from the mandibular canal to the buccal cortical bone at points “A”, “B”, and “C” in men patients were: 3 mm, 1.3 mm, and 0.5 mm, respectively. The measurements obtained at points “A”, “B”, and “C” in women patients were: 1.1 mm, 0.6 mm, and 0.5 mm, respectively,

Table 1. Comparison of anatomic mean values by gender

Quantitative variables	Male		Female		P	Inter-observer agreement	Intra-observer agreement
	Mean (first and second referees)	SD	Mean (first and second referees)	SD			
Thickness A (mm)	11.3 (11.2; 11.4)	1.7	10.5 (10.5; 10.5)	1.6	0.2	0.98	0.99/0.97
Thickness B (mm)	9.45 (9.4; 9.5)	2	9.1 (9.1; 9.15)	2.2	0.6		
Thickness C (mm)	7.3 (7.2; 7.4)	1.4	6.6 (6.5; 6.7)	1.3	0.3		
MC-BC A (mm)	3 (2.8; 3.2)	1.2	1.1 (1; 1.15)	1	0.001 ^a	0.96	1/0.99
MC-BC B (mm)	1.32 (1.24; 1.4)	1.3	0.6 (0.5; 0.73)	1.1	0.08		
MC-BC C (mm)	0.45 (0.3; 0.6)	0.8	0.5 (0.4; 0.52)	0.7	0.7		
MC-LC A (mm)	0.35 (0.2; 0.5)	0.7	0.2 (0.2; 0.3)	1.3	0.1	0.92	0.98/0.96
MC-LC B (mm)	0.4 (0.3; 0.5)	0.6	0.35 (0.3; 0.4)	1.4	0.09		
MC-LC C (mm)	0.22 (0.27; 0.18)	0.3	0.1 (0; 0.2)	0.4	0.2		
Medullary bone A (%)	42.5 (42; 43)	8	44 (43.7; 44.5)	7	0.3	0.92	1/0.98
Medullary bone B (%)	40 (39.4; 40.5)	12	45 (44; 45.8)	8	0.6		
Medullary bone C (%)	27.2 (25.7; 28.8)	12	34 (34.2; 33.7)	10.9	0.1		
Cortical bone A (%)	56 (55; 56.8)	9	55 (55; 54.7)	7	0.4	0.93	0.97/1
Cortical bone B (%)	59 (58.4; 59.1)	17	54 (53.6; 55.8)	10	0.6		
Cortical bone C (%)	72 (71.3; 72.6)	11	66 (65.8; 66.4)	5	0.2		
HU A	135 (134.2; 135.3)	172	284 (282.1; 284.5)	144	0.2	0.9	0.98/0.96
HU B	274 (274; 274.3)	173	375 (374; 375.5)	215	0.1		
HU C	455 (454.3; 455.9)	260	378 (377.8; 378)	184	0.5		

^aStatistically significant at level P < 0.05 (Student’s t-test).

SD = standard deviation; MC = mandibular canal; BC = buccal cortical; LC = lingual cortical; HU = Hounsfield units.

demonstrating higher mean values for the male gender, with statistical significance (P < 0.05) at point “A” when evaluated isolated.

When the distance from the mandibular canal to the lingual cortical bone was evaluated, the highest mean values were found in patients of the female gender, with values at points “A”, “B”, and “C” of 0.2 mm, 0.35 mm, and 0.1 mm, respectively. For male, the mean values were 0.35 mm, 0.4 mm, and 0.2 mm, with no statistically significant difference at the points evaluated either in isolation as in conjunction.

Another variable analysed was the proportion of cortical and medullar bone, for which the mean values found for women at points “A”, “B”, and “C” were 55% and 54%; 66% and 44%; 45% and 34%, respectively. For men, the mean values were 56% and 59%; 72% and 43%; 40% and 27%, respectively. There was no significant correlation between these variables in analysing the individual points or those in conjunction.

The bone density in the female group showed higher values than those in the male group at points “A” and “B”; otherwise, the point C was higher in the male group. However, there were not representative differences from the statistical point of view. The mean values in the male group were 135 HU, 274 HU, and 455 HU at points “A”, “B”, and “C”, respectively;

whereas in the female group the mean values were 284 HU, 375 HU, and 378 HU.

The relation between mandibular thickness and intraoperative position of the nerve

The patients who had the nerve adhered to the distal segment after mandibular sagittal split ramus osteotomy were shown to have a mean (segment) thickness of 11.15 mm at point “A”, 9.65 mm at point “B”, and 7.35 mm at point “C” (Table 2); whereas, when the nerve was adhered to the proximal segment, the mean thickness at point “A” was 9.85 mm, at point “B” was 7.8 mm, and at point “C” was 6.55 mm, demonstrating statistically significant difference at the 3 points evaluated separately.

The relation of the distance from the mandibular canal to the internal surface of the buccal cortical bone and the intraoperative position of the nerve

In the CT image, the distance measured from the mandibular canal to the internal surface of the buccal cortical bone showed a mean value of 2.65 mm at point “A”, 1.25 mm at point “B”, and 0.4 mm at point “C”, when the nerve remained adhered the distal segment. For the proximal, the mean at point “A” was

Table 2. Comparison of anatomic analysis means and inferior alveolar nerve position

Quantitative variables	Distal		Proximal		P	Inter-observer agreement	Intra-observer agreement
	Mean (first and second referees)	SD	Mean (first and second referees)	SD			
Thickness A (mm)	11.15 (11.1; 11.2)	1.6	9.85 (9.8; 9.9)	1.6	0.02 ^a	0.92	0.98/1
Thickness B (mm)	9.65 (9.5; 9.8)	1.6	7.8 (7.7; 7.9)	2.6	0.03 ^a		
Thickness C (mm)	7.35 (7.2; 7.5)	1.4	6.55 (6.4; 6.7)	1.2	0.01 ^a		
MC-BC A (mm)	2.65 (2.5; 2.8)	1	0.65 (0.6; 0.7)	0.7	0.001 ^a	0.9	0.97/0.99
MC-BC B (mm)	1.25 (1.2; 1.3)	1.3	0.2 (0.1; 0.3)	0.8	0.02 ^a		
MC-BC C (mm)	0.4 (0.2; 0.6)	0.8	0.5 (0.2; 0.3)	0.8	0.6		
MC-LC A (mm)	1.2 (1.3; 1.1)	0.8	0.9 (1; 0.8)	1.4	0.001 ^a	0.96	1/0.98
MC-LC B (mm)	0.07 (0.05; 0.1)	1.09	0.2 (0.1; 0.3)	1.4	0.6		
MC-LC C (mm)	0.08 (0.04; 0.12)	1.15	0.06 (0.1; 0.02)	1.2	0.4		
Medullary bone A (%)	44.2 (43.8; 44.4)	11.5	43.3 (42.9; 43.8)	10.1	0.2	0.98	1/0.96
Medullary bone B (%)	42.1 (42.5; 41.8)	10.2	42.2 (42.4; 42)	8.7	0.1		
Medullary bone C (%)	34.3 (34; 34.7)	12.6	29.5 (30; 29.1)	9.2	0.2		
Cortical bone A (%)	56.3 (56.2; 56.5)	7.6	54.6 (54; 55.1)	8.4	0.9	0.92	0.96/0.94
Cortical bone B (%)	57.5 (56.8; 58.2)	10	56.6 (56.2; 57)	8.8	0.1		
Cortical bone C (%)	66.7 (67.3; 66.2)	9.4	69.6 (69.3; 70)	9.1	0.4		
HU A	251 (249; 252)	159	229 (228; 231)	150	0.5	0.95	0.98/0.96
HU B	338 (336; 340)	218	387.5 (386; 389)	236	0.6		
HU C	366 (366; 367)	219	437 (438; 436)	233	0.6		

^aStatistically significant at level P < 0.05 (Student’s t-test).

SD = standard deviation; MC = mandibular canal; BC = buccal cortical; LC = lingual cortical; HU = Hounsfield units.

0.65 mm, at point “B” was 0.2 mm, and at point “C” was 0.5 mm. This evaluation demonstrated statistical significance at points A (P = 0.02) and B (P < 0.05) (Table 2).

Thirteen (92.8%) out of 14 osteotomies that had the nerve bundle adhered to the proximal segment, after evaluated at the point A, had distances shorter than 1.5 mm, and 11 (78.5%) osteotomies had distances equal to or shorter than 1 mm, when the nerve remained adhered to the proximal segment, with the maximum value for this measurement of 2.2 mm. Conversely, 20 (77%) out of 26 osteotomies that had the nerve adhered to the distal segment showed distances longer than or equal to 1.5 mm at point “A”. In this outcome, the minimum value found was 0.7 mm.

The relation of the distance from the mandibular canal to the internal aspect of the lingual cortical bone and the intraoperative position of the nerve

Regarding this variable (Table 2), it was observed that when the nerve remained adhered to the distal segment, the mean obtained at point “A” was 1.2 mm, at point “B” was 0.07 mm, and at point “C” was 0.08 mm; whereas when the nerve remained adhered to the proximal segment, the mean values corresponding to, respectively, to points “A”, “B”

and “C” were 0.9 mm, 0.2 mm and 0.06 mm. Of the 3 points evaluated, only the point “A” showed a statistically significant difference.

Twenty-three (88.4%) out of the 26 osteotomies in which the nerve remained adhered to the distal segment showed values lower than 1 mm. When the nerve was adhered to the proximal segment (14 sides), 7 osteotomies (50%) showed values higher than 1 mm at point “A”.

The relation of the proportion between cortical and medullary bone and intraoperative position of the nerve

The patients who had the IAN adhered to the distal segment demonstrated a mean (proportion) of cortical and medullary bone at points “A”, “B”, and “C” of 56.3%, 57.5%, and 66.7%; 44.2%; 42.1%, and 34.3%, respectively. Whereas, when the nerve was adhered to the proximal segment, this same proportion, evaluated at the same point was 54.6%, 56.6%, and 69.9%; and 43.3%; 42.2%, and 29.5%, respectively, demonstrating a higher proportion of medullary bone in the cases in which the nerve was found adhered to the distal segment, and a higher proportion of cortical bone associated with the evaluations of the proximal segment.

The relation of bone density with segments

Concerning bone density (Table 2), which was measured in Hounsfield Units, after analysis of the data, it was verified that for patients with the presence of the nerve in the distal segment, after mandibular sagittal split ramus osteotomy, the mean value at point “A” was 251 HU, 338 HU at point “B”, and 366 HU at point “C”. When the other possibility (nerve on the proximal segment) was analysed, the mean measurements for points “A”, “B”, and “C” were 229 HU, 387.5 HU, and 437 HU, respectively. These results showed no statistical relevance for any analysis. However, the mean bone density value was higher at all 3 points in patients who had the nerve bundle adhered to the proximal segment.

DISCUSSION

The goal of this study was to evaluate the relation of the proximity between the anatomic position of the mandibular canal and the intraoperative position of the IAN, through CT as the imaging exam, based on the affirmatives of Ylikontiola et al. [16] who considered CT the imaging exam of choice for this type of analyses.

The evaluations performed in this current study can help to minimize the most prevalent complication of mandibular sagittal split ramus osteotomy, postoperative paraesthesia, which could compromise the quality of life and reduce the patient satisfaction [2,4]. Thereby, the imaging exam has shown good clinical applicability and has enabled professionals to inform patient about the higher or lower risk of neurosensory disturbance, and to perform surgical manoeuvres that diminish damage to the IAN [2,16,17].

In this study, three points of reference in the mandibular ramus and body were selected for making a meticulous evaluation of the anatomic characteristics along the course of the mandibular canal, similarly to Ylikontiola et al. [16], Yamamoto et al. [18], Wittwer et al. [19], and Huang et al. [20] However, many authors have used only one point of reference for making tomographic measurements of the mandibular canal [5,12,21-25]. This point was found in the region of the mandibular second molar, because it was the region of the vertical component of sagittal osteotomy of the mandibular ramus. Therefore, the evaluation made in this study has advantages in relation to the second procedure cited (one point of reference), since the anatomical characteristics related to the mandibular canal were

analysed along the course of the IAN. Since sagittal split osteotomy occurs along the course of the entire osteotomy, the IAN is subject to damage throughout its extension and not only in the region of the mandibular second molar.

Moreover, the intraoperative position of the IAN was grouped into two possible localizations: proximal or distal segment. In the former there would be the need for surgical manipulation of the nerve, and in the latter, there would be the need for surgical manipulation, similarly to the methodology used by Fridrich et al. [10] These authors, on the same way as Westermarck et al. [26] and Thygesen et al. [27], pointed out that one of the causes of postoperative paraesthesia was manipulation of the IAN after mandibular sagittal split ramus osteotomy. Whereas Hanzelka et al. [7] minimized this factor as being determining for the development of paraesthesia.

In addition to manipulation, other variables have also been described in the literature as being paraesthesia-influencing factors, among them there are medial retraction of the extraosseous portion of the IAN at the time of performing horizontal osteotomy of the mandibular ramus, use of chisels, material used for osteotomy, type of fixation, type of osteotomy, hematoma/edema in the region of the mandibular canal, time taken to perform surgery, age, sex, and preoperative sensitivity [3,7-10,17,27-29].

Anatomical characteristics

In the literature, there is a scarcity of data related to analyses of the anatomical characteristics of the mandibular canal and intraoperative position of the IAN after mandibular sagittal split osteotomy. Many authors correlated the mandibular canal anatomy with postoperative paraesthesia by means of images of the CT and concluded that reduction in the distance from the IAN to the buccal cortical bone and reduction in the mandibular (bone) thickness, increased the risk for development of paraesthesia of the IAN after mandibular sagittal split ramus osteotomy [5,16,18,20,23,25,30,31]. However, these studies did not include the intraoperative position of the IAN after mandibular sagittal split ramus osteotomy as a variable analysed once a greater degree of manipulation of the nerve may lead to a greater chance of the occurrence of postoperative paraesthesia [27].

In the present study, for female patients, 41% of the nerves were adhered to the proximal segment after sagittal split ramus osteotomy, while for male only 27.8% of the nerves were adhered to the proximal

segment. This fact could be explained by the distance from the mandibular canal to the buccal cortical bone, which was significantly shorter ($P < 0.05$) for females, in this study than that of the male sex, corroborating the findings of Yu and Wong [12], Simonton et al. [32], and Yoshioka et al. [5] This favoured the presence of the nerve in the proximal segment after sagittal split ramus osteotomy, and demonstrated the greater possibility of manipulating and damaging the nerve. These data and the affirmation made by Fridrich et al. [10], Westermarck et al. [26], and Thygesen et al. [27], that surgical manipulation of the IAN promoted a higher incidence of neurosensory disturbance, thus justifying the finding of Yoshioka et al. [5] and Bruckmoser et al. [28] who affirmed that patients of the female gender had a greater tendency to develop paraesthesia than patients of the male gender. To the contrary, Hanzelka et al. [7] did not find relationship between paraesthesia and gender.

Therefore, the proximity observed in this research cannot be compared because there is no research that provide this information. However, in concordance with our result, the reduction in the distance from the mandibular canal to the buccal cortical bone promoted higher risk for neurosensory disturbance both in the short and long-term [5,16,18,20,23-25,30,31]. Furthermore, Yoshioka et al. [23] affirmed that when the distance from the mandibular canal to the buccal cortical bone was diminished, the IAN was more subject to suffering injury during surgical procedures such as mandibular sagittal split ramus osteotomy.

The course of the IAN has been demonstrated to be extremely close to the buccal cortical, without spongy bone between the mandibular canal and the buccal cortical bone while its trajectory up to the region of the mandibular second molar. Tamás et al. [33] found an incidence of 19.5% of these cases in their studies conducted by means X-rays of dry mandibles. In the present study an incidence of 10% was found of the distance of mandibular canals to the buccal cortical bone in all the regions evaluated, and in all these cases the nerve remained adhered to the proximal segment after splitting sagittal osteotomy. Tsuji et al. [1], after analyses of CT images, affirmed that 22.9% of the cases evaluated showed some area of fusion of the mandibular canal to the buccal cortical bone in the region from the mandibular foramen to the region of the mandibular body, however, no case of fusion was shown in all the (other) regions evaluated. Yamamoto et al. [18], reported the presence of fusion in 25% of the cases, however, fusion was found only in the region of the mandibular body.

Another important finding in this study was that the distance from the mandibular canal

to the internal surface of the lingual cortical bone showed statistically significant higher mean values at point "A" in the patients in whom the nerve was adhered to the proximal segment, after splitting sagittal ramus osteotomy, in the region of the mandibular second molar. Ylikontiola et al. [16] verified that the mean distance from the mandibular canal to the lingual cortical bone was 2.25 mm, ranging from 1 to 5 mm in the region of the mandibular third molar and a mean of 2.25 mm ranging between 0.8 and 5 mm in the region between the maxillary first and second molars. However, they did not relate this datum to paraesthesia or the segment to which the nerve remained adhered in the surgical procedure. In the present study, the mean value obtained in the region of the mandibular third molar was 0.6 mm ranging from 0 to 4.4 mm and a mean of 0.7 mm ranging between 0 and 4.2 mm in the region of the mandibular second molar. Simonton et al. [32] also evaluated this variable, however, with the aim of finding differences between the male and female genders and found no significant difference in this analysis.

The mean value found by this author was 2.4 mm in the region of the mandibular first molar. The mean values in the study of Simonon et al. [32] and Ylikontiola et al. [16] were higher than those found in the present study because they made their measurements from the mandibular canal to the external surface of the lingual cortical bone of the mandible. The distance from the mandibular canal to the external cortical at point "C" was around 0.4 mm in all the patients, confirming the findings of Gowgiel [34], representing fusion of the mandibular canal with the lingual cortical bone in the mentioned region.

Paraesthesia

Some authors provided objective measurements of risk related to the distance from the mandibular canal to the buccal cortical bone for the development of postoperative paraesthesia. Ylikontiola et al. [16] reported that the risk for neurosensory disturbance increased significantly when this distance was equal to or shorter than 2 mm. Yoshida et al. [30], in their study, affirmed that distances shorter than 1.2 mm were found in 91% of the sides with severe neurosensory disturbance, and Yamamoto et al. [18] found that distances shorter than 0.8 mm increased the risk of permanence of paraesthesia 1 year after the surgical procedure. Yoshioka et al. [23] affirmed that distances shorter than 6 mm increased the chance of neurological damage occurring.

In this current study, 92.8% of the nerves that remained adhered to the proximal segment had distances from the mandibular canal to the buccal cortical bone shorter than 2 mm and 78.5% showed distances shorter than or equal to 1 mm. The justification for the relations among these data (anatomy, intraoperative position, and paraesthesia) is the same as that presented in the paragraph above.

Another factor that had a significant influence on the intraoperative position of the IAN after splitting sagittal osteotomy in this study was the mandibular (bone) thickness. Therefore, the smaller the mandibular (bone) thickness was, the greater was the chance of the IAN remaining adhered to the proximal segment. This analysis showed statistical significance in the 3 regions evaluate in isolation (point “A”, “B” and “C”). According to Ylikontiola et al. [16], the chance of neurological damage increases when the surgery is performed in narrow mandibles, and in these cases, shorter distances are generally observed between the mandibular canal and the buccal cortical of the mandible; this finding was also observed by Tamás [33]. When making an association with the present study, we could relate these affirmatives to the higher presence of the nerve on the proximal segment in narrow mandibles, leading to greater need for manipulation of the IAN, and a smaller quantity of spongy bone surrounding and protecting the IAN in split sagittal osteotomy procedures. These were some of the factors that favoured greater neurological damage.

The proportion of cortical/medullary bone was slightly higher when the nerve was found adhered to the proximal segment in the 3 points evaluated, with greater differences being observed in the region of the mandibular third molar [35]; however, this difference was not statistically significant. There are no studies that have compared the proportion of cortical/medullary bone with the nerve bundle after sagittal split ramus osteotomy, or with postoperative paraesthesia.

The quantity of bone in the region of the IAN was evaluated by Yoshioka et al. [22] who found that the higher the bone density value, measured in Hounsfield Units, the greater the chance of paraesthesia occurring in the postoperative period. One year later, the same author published objective bone density measurements, and affirmed that patients with bone density values higher than 300 HU had greater chance of developing paraesthesia in the long term. In the present study bone density was related to the position of the IAN after sagittal split osteotomy postoperatively, and no statistically significant

measurements were found, however, when the nerve remained adhered to the proximal segment, the mean bone density values were observed to be higher, when compared with the other outcome, in all the 3 points evaluated. A possible explanation for this fact could be that when the bone is denser, fracture occurs in a less predictable manner since more force would be applied to perform the mandibular sagittal split ramus osteotomy [23]. Furthermore, Yoshioka et al. [23] affirmed that in these cases greater impact of the fracture leads to higher temperatures in the bone, resulting in greater neurological damage.

When faced with these findings, the surgeon could prepare better planning and perform the surgical procedure more predictably and cautiously in cases in which the tomography image reveals risk factors for neurosensory disturbance [2,12,16,18,19,33,36]. This study demonstrated that CT could be useful to plan and predict a greater or lesser extent of manipulation of the IAN, making it possible to perform individualized osteotomies in 3 cases of mandibular canal proximity to the buccal cortical bone. The osteotomies performed in the patients of the present study were not changed; they were performed with reciprocating saws and by positioning the sagittal osteotomy at a point that was half of the buccolingual distance from the mandible.

Based on this affirmation, Wittwer et al. [19] analysed the position of the mandibular canal in 3 regions of the mandible and proposed modifications in the sagittal osteotomy, based on the preoperative anatomy. Of the 102 rami evaluated, only 39% were indicated for undergoing conventional osteotomies and the remainder, as they had a relationship of proximity to the IAN, were included in the group with modified osteotomies, based on virtual surgical planning. The first variation was denominated modified classical osteotomy and was indicated for cases in which there was a relationship of proximity between the mandibular canal and the buccal cortical bone in the region of the mandibular third molar, and/or in the region of transition from the ramus to the mandibular body. This variation consisted of osteotomy aided by navigation, in the buccal region of the mandible, and traditional, in the region of the mandibular ramus, with a view to avoiding nerve damage in the region of transition from the ramus to the mandibular body. The second variation was denominated completely individualized osteotomy and was developed for cases that the area of the mandibular canal is close to the buccal cortex in the region before reaching the mandibular foramen. This type of osteotomy requires the use of surgery by navigation throughout its entire extension, and in this case,

the buccal part of the osteotomy is not performed. A disadvantage of this study was that there was no clinical application of the modified osteotomies, and its use was only tested in software programs, so that there was no clinical and scientific evidence to support it.

Yu and Wong [12] suggested a guideline for surgeons to avoid neurological damage when medial osteotomy has to be performed 5 mm in the superior direction and 4 to 8 mm in the posterior direction to the lingual bone cortex. Sagittal osteotomy must not penetrate the medullary bone by more than 8 mm, and at the buccal bone cortical the osteotomy must not exceed 5 mm in the direction of the mandibular medullary bone. Despite this, Yu and Wong [12] supported the practice of performing individualized osteotomies in selected cases. This concern about the modifications made to osteotomy has been demonstrated by some authors, such as Yoshida et al. [30], who reported performing vertical osteotomy in a more posterior position than in the conventional procedure, as being a factor that diminished nerve damage. Furthermore, they reported the use of a thin cement spatula to perform the mandibular sagittal split ramus osteotomy in cases in which they observed small distances between the mandibular canal and buccal cortical bone. This suggestion was also made by Brusati et al. [37], who performed this technique in 20 patients. Of the 40 sides evaluated, only 1 had paraesthesia in the long term. This type of approach would avoid direct damage to the IAN and would allow the presence of a larger quantity of medullary bone covering the mandibular canal. In a systematic review, Mensink et al. [17] suggested that the use of a hammer and chisel to perform split sagittal osteotomy showed greater chances of damaging the IAN when compared with the use of separators, as described by Wolford et al. [36].

Aizenbud et al. [2], in their studies, performed mandibular sagittal split ramus osteotomies in patients with and without undergoing preoperative CT exams. The osteotomies were performed according to the preoperative anatomy in the first case, and conventional osteotomies in the second case. The authors believed that the low incidence of postoperative paraesthesia in the first group (approximately 75% fewer cases than in the second group) were due to the modifications made to the osteotomies, namely: in thick mandibular bone, it was not necessary to perform the osteotomy in the middle of the mandible (buccolingual direction) but rather according to the position of the nerve; the vertical component of the sagittal osteotomy could be modified according to the mandibular canal anatomy,

thereby minimizing intraoperative manipulation of the IAN and postoperative paraesthesia.

Limitation of the study

There were some limitations in this study: (a) there was a reduced sample size due to be a pilot study; (b) the fact that only the anatomy of the mandibular canal and intraoperative position of the IAN were evaluated, whereas postoperative paraesthesia was not evaluated; this fact did not permit to obtain conclusion involving paraesthesia based on this study.

CONCLUSIONS

The following aspects of the present study can be concluded:

- The reduction in the distance from the mandibular canal to the internal surface of the buccal cortical bone in regions of the mandibular second and third molars increased the chance of inferior alveolar nerve being adhered to the proximal segment after mandibular sagittal split ramus osteotomy.
- Greater distance from the mandibular canal to the internal surface of the lingual cortical bone in the regions of the mandibular second molar increased the chance of inferior alveolar nerve being adhered to the proximal segment after mandibular sagittal split ramus osteotomy.
- The chance of the inferior alveolar nerve being adhered to the proximal segment after mandibular sagittal split ramus osteotomy was increased in narrow mandibles.
- The proportion of cortical and medullary bone and bone density did not significantly contribute to the outcome of this study.
- In this study, female patients showed lower mean values of the distance from the mandibular canal to the buccal cortical bone when compared with male patients.

ACKNOWLEDGMENTS AND DISCLOSURE STATEMENTS

The authors report no conflicts of interest related to this study.

REFERENCES

1. Tsuji Y, Muto T, Kawakami J, Takeda S. Computed tomographic analysis of the position and course of the mandibular canal: relevance to the sagittal split ramus osteotomy. *Int J Oral Maxillofac Surg*. 2005 May;34(3):243-6. [Medline: [15741030](#)] [doi: [10.1016/j.ijom.2004.06.001](#)]
2. Aizenbud D, Ciceu C, Hazan-Molina H, Abu-El-Naaj I. Relationship between inferior alveolar nerve imaging and neurosensory impairment following bilateral sagittal split osteotomy in skeletal Class III cases with mandibular prognathism. *Int J Oral Maxillofac Surg*. 2012 Apr;41(4):461-8. [Medline: [22115977](#)] [doi: [10.1016/j.ijom.2011.10.024](#)]
3. Kim YK, Kim SG, Kim JH. Altered sensation after orthognathic surgery. *J Oral Maxillofac Surg*. 2011 Mar;69(3):893-8. [Medline: [21211888](#)] [doi: [10.1016/j.joms.2010.10.025](#)]
4. Sousa CS, Turrinil RNT. Complications in orthognathic surgery: A comprehensive review. *J Oral Maxillofac Surg Med Pathol*. 2012 May;24(2):67-74. [doi: [10.1016/j.ajoms.2012.01.014](#)]
5. Yoshioka I, Tanaka T, Khanal A, Habu M, Kito S, Kodama M, Oda M, Wakasugi-Sato N, Matsumoto-Takeda S, Fukai Y, Tokitsu T, Tomikawa M, Seta Y, Tominaga K, Morimoto Y. Relationship between inferior alveolar nerve canal position at mandibular second molar in patients with prognathism and possible occurrence of neurosensory disturbance after sagittal split ramus osteotomy. *J Oral Maxillofac Surg*. 2010 Dec;68(12):3022-7. [Medline: [20739116](#)] [doi: [10.1016/j.joms.2009.09.046](#)]
6. Ylikontiola L, Kinnunen J, Laukkanen P, Oikarinen K. Prediction of recovery from neurosensory deficit after bilateral sagittal split osteotomy. *Oral Surg Oral Med Oral Pathol Oral Radiol Endod*. 2000 Sep;90(3):275-81. [Medline: [10982946](#)] [doi: [10.1067/moe.2000.108920](#)]
7. Hanzelka T, Foltán R, Pavlíková G, Horká E, Sedý J. The role of intraoperative positioning of the inferior alveolar nerve on postoperative paresthesia after bilateral sagittal split osteotomy of the mandible: prospective clinical study. *Int J Oral Maxillofac Surg*. 2011 Sep;40(9):901-6. [Medline: [21570811](#)] [doi: [10.1016/j.ijom.2011.04.002](#)]
8. Panula K, Finne K, Oikarinen K. Neurosensory deficits after bilateral sagittal split ramus osteotomy of the mandible- influence of soft tissue handling medial to the ascending ramus. *Int J Oral Maxillofac Surg*. 2004 Sep;33(6):543-8. [Medline: [15308252](#)] [doi: [10.1016/j.ijom.2003.11.005](#)]
9. Teerijoki-Oksa T, Jääskeläinen SK, Forssell K, Forssell H, Vähätalo K, Tammissalo T, Virtanen A. Risk factors of nerve injury during mandibular sagittal split osteotomy. *Int J Oral Maxillofac Surg*. 2002 Feb;31(1):33-9. [Medline: [11936397](#)] [doi: [10.1054/ijom.2001.0157](#)]
10. Fridrich KL, Holton TJ, Pansegrau KJ, Buckley MJ. Neurosensory recovery following the mandibular bilateral sagittal split osteotomy. *J Oral Maxillofac Surg*. 1995 Nov;53(11):1300-6; discussion 1306-7. [Medline: [7562195](#)] [doi: [10.1016/0278-2391\(95\)90588-X](#)]
11. Noleto JW, Marchiori E, Da Silveira HM. Evaluation of mandibular ramus morphology using computed tomography in patients with mandibular prognathism and retrognathia: relevance to the sagittal split ramus osteotomy. *J Oral Maxillofac Surg*. 2010 Aug;68(8):1788-94. [Medline: [20493618](#)] [doi: [10.1016/j.joms.2009.12.028](#)]
12. Yu IH, Wong YK. Evaluation of mandibular anatomy related to sagittal split ramus osteotomy using 3-dimensional computed tomography scan images. *Int J Oral Maxillofac Surg*. 2008 Jun;37(6):521-8. [Medline: [18450425](#)] [doi: [10.1016/j.ijom.2008.03.003](#)]
13. Trauner R, Obwegeser H. The surgical correction of mandibular prognathism and retrognathia with consideration of genioplasty. I. Surgical procedures to correct mandibular prognathism and reshaping of the chin. *Oral Surg Oral Med Oral Pathol*. 1957 Jul;10(7):677-89; contd. [Medline: [13441284](#)] [doi: [10.1016/S0030-4220\(57\)80063-2](#)]
14. Dal Pont G. Retromolar osteotomy for the correction of prognathism. *J Oral Surg Anesth Hosp Dent Serv*. 1961 Jan;19:42-7. [Medline: [13719390](#)]
15. Hunsuck EE. A modified intraoral sagittal splitting technic for correction of mandibular prognathism. *J Oral Surg*. 1968 Apr;26(4):250-3. [Medline: [5237786](#)]
16. Ylikontiola L, Moberg K, Huumonen S, Soikkonen K, Oikarinen K. Comparison of three radiographic methods used to locate the mandibular canal in the buccolingual direction before bilateral sagittal split osteotomy. *Oral Surg Oral Med Oral Pathol Oral Radiol Endod*. 2002 Jun;93(6):736-42. [Medline: [12142882](#)] [doi: [10.1067/moe.2002.122639](#)]
17. Mensink G, Gooris PJ, Bergsma JE, van Hooft E, van Merkesteyn JP. Influence of BSSO surgical technique on postoperative inferior alveolar nerve hypoesthesia: a systematic review of the literature. *J Craniomaxillofac Surg*. 2014 Sep;42(6):976-82. [Medline: [24503389](#)] [doi: [10.1016/j.jcms.2014.01.019](#)]
18. Yamamoto R, Nakamura A, Ohno K, Michi KI. Relationship of the mandibular canal to the lateral cortex of the mandibular ramus as a factor in the development of neurosensory disturbance after bilateral sagittal split osteotomy. *J Oral Maxillofac Surg*. 2002 May;60(5):490-5. [Medline: [11988921](#)] [doi: [10.1053/joms.2002.31843](#)]
19. Wittwer G, Adeyemo WL, Beinemann J, Juergens P. Evaluation of risk of injury to the inferior alveolar nerve with classical sagittal split osteotomy technique and proposed alternative surgical techniques using computer-assisted surgery. *Int J Oral Maxillofac Surg*. 2012 Jan;41(1):79-86. [Medline: [21925838](#)] [doi: [10.1016/j.ijom.2011.08.001](#)]

20. Huang CS, Syu JJ, Ko EW, Chen YR. Quantitative evaluation of cortical bone thickness in mandibular prognathic patients with neurosensory disturbance after bilateral sagittal split osteotomy. *J Oral Maxillofac Surg.* 2013 Dec;71(12):2153. e1-10. [Medline: [24135253](#)] [doi: [10.1016/j.joms.2013.08.004](#)]
21. Levine MH, Goddard AL, Dodson TB. Inferior alveolar nerve canal position: a clinical and radiographic study. *J Oral Maxillofac Surg.* 2007 Mar;65(3):470-4. [Medline: [17307595](#)] [doi: [10.1016/j.joms.2006.05.056](#)]
22. Yoshioka I, Tanaka T, Khanal A, Habu M, Kito S, Kodama M, Oda M, Wakasugi-Sato N, Matsumoto-Takeda S, Seta Y, Tominaga K, Sakoda S, Morimoto Y. Correlation of mandibular bone quality with neurosensory disturbance after sagittal split ramus osteotomy. *Br J Oral Maxillofac Surg.* 2011 Oct;49(7):552-6. [Medline: [21071118](#)] [doi: [10.1016/j.bjoms.2010.09.014](#)]
23. Yoshioka I, Tanaka T, Habu M, Oda M, Kodama M, Kito S, Seta Y, Tominaga K, Sakoda S, Morimoto Y. Effect of bone quality and position of the inferior alveolar nerve canal in continuous, long-term, neurosensory disturbance after sagittal split ramus osteotomy. *J Craniomaxillofac Surg.* 2012 Sep;40(6):e178-83. [Medline: [22000578](#)] [doi: [10.1016/j.jcms.2011.09.003](#)]
24. Yamauchi K, Takahashi T, Kaneuji T, Nogami S, Yamamoto N, Miyamoto I, Yamashita Y. Risk factors for neurosensory disturbance after bilateral sagittal split osteotomy based on position of mandibular canal and morphology of mandibular angle. *J Oral Maxillofac Surg.* 2012 Feb;70(2):401-6. [Medline: [21549489](#)] [doi: [10.1016/j.joms.2011.01.040](#)]
25. Kuroyanagi N, Miyachi H, Ochiai S, Kamiya N, Kanazawa T, Nagao T, Shimozato K. Prediction of neurosensory alterations after sagittal split ramus osteotomy. *Int J Oral Maxillofac Surg.* 2013 Jul;42(7):814-22. [Medline: [23265759](#)] [doi: [10.1016/j.ijom.2012.11.016](#)]
26. Westermark A, Bystedt H, von Konow L. Inferior alveolar nerve function after sagittal split osteotomy of the mandible: correlation with degree of intraoperative nerve encounter and other variables in 496 operations. *Br J Oral Maxillofac Surg.* 1998 Dec;36(6):429-33. [Medline: [9881784](#)] [doi: [10.1016/S0266-4356\(98\)90458-2](#)]
27. Thygesen TH, Bardow A, Helleberg M, Norholt SE, Jensen J, Svensson P. Risk factors affecting somatosensory function after sagittal split osteotomy. *J Oral Maxillofac Surg.* 2008 Mar;66(3):469-74. [Medline: [18280379](#)] [doi: [10.1016/j.joms.2007.06.666](#)]
28. Bruckmoser E, Bulla M, Alacamlioglu Y, Steiner I, Watzke IM. Factors influencing neurosensory disturbance after bilateral sagittal split osteotomy: retrospective analysis after 6 and 12 months. *Oral Surg Oral Med Oral Pathol Oral Radiol.* 2013 Apr;115(4):473-82. [Medline: [23182371](#)] [doi: [10.1016/j.oooo.2012.08.454](#)]
29. Ueki K, Sotobori M, Ishihara Y, Iguchi R, Kosaka A, Ikawa H, Moroi A, Yoshizawa K, Marukawa K. Evaluation of factors affecting recovery period in lower lip hypoesthesia after sagittal split ramus osteotomy in mandibular prognathism patients. *J Craniomaxillofac Surg.* 2014 Dec;42(8):1748-52. [Medline: [25033740](#)] [doi: [10.1016/j.jcms.2014.06.010](#)]
30. Yoshida T, Nagamine T, Kobayashi T, Michimi N, Nakajima T, Sasakura H, Hanada K. Impairment of the inferior alveolar nerve after sagittal split osteotomy. *J Craniomaxillofac Surg.* 1989 Aug;17(6):271-7. [Medline: [2671043](#)] [doi: [10.1016/S1010-5182\(89\)80095-2](#)]
31. Rich J, Golden BA, Phillips C. Systematic review of preoperative mandibular canal position as it relates to postoperative neurosensory disturbance following the sagittal split ramus osteotomy. *Int J Oral Maxillofac Surg.* 2014 Sep;43(9):1076-81. [Medline: [24837554](#)] [PMC free article: [4130761](#)] [doi: [10.1016/j.ijom.2014.03.020](#)]
32. Simonton JD, Azevedo B, Schindler WG, Hargreaves KM. Age- and gender-related differences in the position of the inferior alveolar nerve by using cone beam computed tomography. *J Endod.* 2009 Jul;35(7):944-9. [Medline: [19567312](#)] [doi: [10.1016/j.joen.2009.04.032](#)]
33. Tamás F. Position of the mandibular canal. *Int J Oral Maxillofac Surg.* 1987 Feb;16(1):65-9. [Medline: [3104497](#)] [doi: [10.1016/S0901-5027\(87\)80032-2](#)]
34. Gowgiel JM. The position and course of the mandibular canal. *J Oral Implantol.* 1992;18(4):383-5. [Medline: [1298823](#)]
35. Sarikov R, Juodzbaly G. Inferior alveolar nerve injury after mandibular third molar extraction: a literature review. *J Oral Maxillofac Res.* 2014 Dec 29;5(4):e1. [Medline: [25635208](#)] [PMC free article: [4306319](#)] [doi: [10.5037/jomr.2014.5401](#)]
36. Wolford LM, Bennett MA, Rafferty CG. Modification of the mandibular ramus sagittal split osteotomy. *Oral Surg Oral Med Oral Pathol.* 1987 Aug;64(2):146-55. [Medline: [3476891](#)] [doi: [10.1016/0030-4220\(87\)90080-6](#)]
37. Brusati R, Fiamminghi L, Sesenna E, Gazzotti A. Functional disturbances of the inferior alveolar nerve after sagittal osteotomy of the mandibular ramus: operating technique for prevention. *J Maxillofac Surg.* 1981 May;9(2):123-5. [Medline: [6943243](#)] [doi: [10.1016/S0301-0503\(81\)80028-8](#)]

To cite this article:

dos Santos VDB, Queiroz SIML, da Silva AC, Silva S, da Silva JSP, Fernandes GVO, Germano AR.

Evaluation of the Anatomic Position of the Mandibular Canal Regarding to the Segments of the Mandibular Sagittal Split Ramus Osteotomy to Diminish the Possibility of Injuries: a Pilot Study

J Oral Maxillofac Res 2022;13(4):e2

URL: <http://www.ejomr.org/JOMR/archives/2022/4/e2/v13n4e2.pdf>

doi: [10.5037/jomr.2022.13402](https://doi.org/10.5037/jomr.2022.13402)

Copyright © dos Santos VDB, Queiroz SIML, da Silva AC, Silva S, da Silva JSP, Fernandes GVO, Germano AR. Published in the JOURNAL OF ORAL & MAXILLOFACIAL RESEARCH (<http://www.ejomr.org>), 31 December 2022.

This is an open-access article, first published in the JOURNAL OF ORAL & MAXILLOFACIAL RESEARCH, distributed under the terms of the [Creative Commons Attribution-Noncommercial-No Derivative Works 3.0 Unported License](https://creativecommons.org/licenses/by-nc-nd/3.0/), which permits unrestricted non-commercial use, distribution, and reproduction in any medium, provided the original work and is properly cited. The copyright, license information and link to the original publication on (<http://www.ejomr.org>) must be included.