

Endovascular management of extensive ilio caval thrombosis secondary to synchronous uterine myoma compression and May-Thurner syndrome

Thomas Serena, DO,^a Whitney Bailey, MD,^a and Scott Bendix, MD,^b Farmington Hill, MI

ABSTRACT

This report presents a 42-year-old African American woman with bilateral lower extremity pain, swelling, and paresthesias. Imaging demonstrated a large fibroid uterus with a mass effect in proximity to an ilio caval venous thrombosis. Mechanical thrombectomy was performed with recurrent infrarenal vena cava and bilateral iliac thrombosis, prompting hysterectomy. A subsequent intravascular ultrasound examination demonstrated relief of the external caval compression, but with left iliac vein compression by the right common iliac artery. The patient was managed successfully with mechanical thrombectomy and venous stenting. This case highlights the benefit of a multidisciplinary approach to complex ilio caval thrombosis from both an obstructive uterine myoma and May-Thurner syndrome. (*J Vasc Surg Cases Innov Tech* 2022;8:179-82.)

Keywords: Fibroid uterus; Caval thrombosis; May-Thurner syndrome; Endovascular; Case report

Ilio caval thrombosis refers to the formation of thrombus within the large vein that drains the bilateral lower extremities and abdominopelvic region. May-Thurner Syndrome (MTS) refers to left common iliac vein compression by the right common iliac artery. Both conditions may lead to substantial morbidity. This case demonstrates the unique presentation of a patient with an extensive ilio caval thrombosis secondary to both external caval compression by a large uterine myoma and MTS. The patient was managed successfully by staged endovascular techniques and a hysterectomy with complete resolution of symptomatology. She provided consent for the publication of case information and imaging.

CASE REPORT

A 42-year-old African American woman presented with chief complaints of progression of symptoms associated with deep

venous thrombosis (DVT) of the left leg and with shortness of breath with exertion. She had been diagnosed with a left lower extremity DVT 1 one week prior, where she presented with left leg pain, swelling, and paresthesias to an outside medical center. She was diagnosed with a DVT and discharged on rivaroxaban (Xarelto) 25 mg twice daily. She works as a long-haul truck driver. Her past medical history was significant for obesity, tobacco dependence, and uterine fibroids with menorrhagia managed with oral contraceptives. She had no past surgical history. The patient was adopted and unaware of familial clotting or malignant disorders. In summary, the risk factors for thrombotic events included prolonged immobility from work, current tobacco use, oral contraceptive use, and obesity.

A physical examination at our hospital demonstrated readily palpable distal pulses without phlegmasia and progression to now bilateral lower extremity edema. Her pain and shortness of breath were limiting her activities of daily living. Computed tomographic angiography demonstrated segmental and subsegmental pulmonary emboli (PE), uteromegaly measuring 19.6 × 16.5 × 12.4 cm, multiple enlarged fibroids, and extrinsic compression of the infrarenal vena cava (Fig 1, A). An echocardiogram failed to demonstrate right heart strain or cardiac abnormalities; she did not meet the criteria for PE intervention.

Diagnostic assessment and therapeutic interventions.

A bilateral venogram revealed a large acute left iliofemoral vein thrombus with extension into the distal inferior vena cava (IVC), poor filling of the IVC, and failure of progression of contrast demonstrating extensive thrombus burden (Fig 1, B). There was a mild acute thrombus in the right iliofemoral vein. An intravascular ultrasound (IVUS) examination was performed, which demonstrated significant compression of the vena cava by the fibroid uterus. She underwent mechanical thrombectomy of bilateral iliofemoral veins using a mechanical clot removal system (ClotTriever, Inari Medical, Irvine, CA).¹ Postoperatively, there was a

From the Department of General Surgery^a and the Department of Vascular Surgery,^b Beaumont Health, Farmington Hills.

Author conflict of interest: none.

Availability of Supporting Data: All data generated or analyzed during this study are included in this published article. The datasets used and/or analyzed during the current study are available from the corresponding author on reasonable request.

Presented at the forty-fifth Midwestern Vascular Surgical Society Annual Meeting in Chicago, Illinois, September 9-11, 2021.

Correspondence: Thomas Serena, DO, Beaumont Hospital, 28080 Grand River Ave, Farmington Hills, MI 48336 (e-mail: thomas.serena@beaumont.org).

The editors and reviewers of this article have no relevant financial relationships to disclose per the Journal policy that requires reviewers to decline review of any manuscript for which they may have a conflict of interest.

2468-4287

© 2022 The Author(s). Published by Elsevier Inc. on behalf of Society for Vascular Surgery. This is an open access article under the CC BY-NC-ND license (<http://creativecommons.org/licenses/by-nc-nd/4.0/>).

<https://doi.org/10.1016/j.jvscit.2022.01.008>

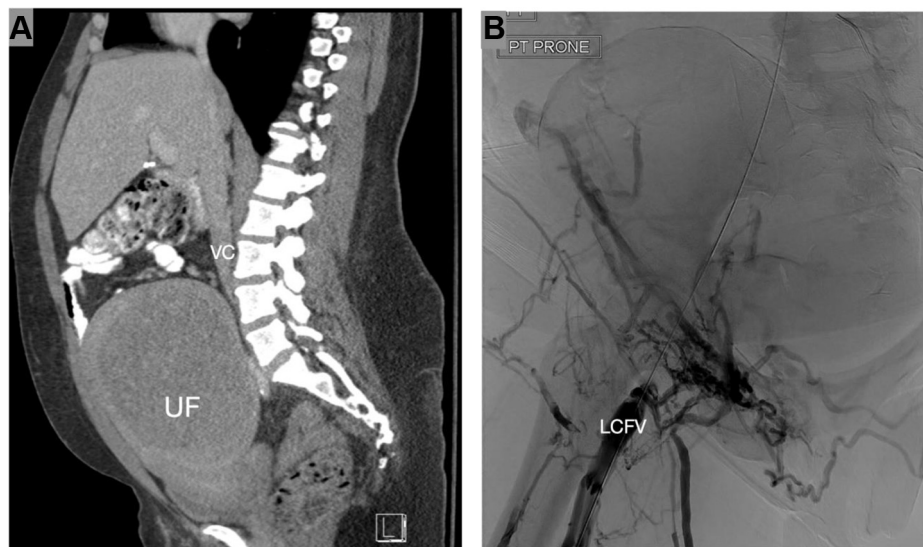

Fig 1. (A) Preoperative computed tomography single view sagittal cut demonstrating large fibroid uterus (UF) with compression of the inferior vena cava (IVC). **(B)** Preintervention intraoperative venogram demonstrating lack of opacification of the ilio caval venous system suggestive of thrombosis with termination of contrast in the left common femoral vein (LCFV).

patent iliofemoral venous system. It was recommended she undergo hysterectomy to improve outflow obstruction as the IVUS findings confirmed proximal extrinsic compression of the IVC.

She was brought back to the endovascular suite post-hysterectomy as her symptoms were only mildly improved. An IVUS examination and venogram revealed near complete occlusion of the left common iliac vein with external compression by the right common iliac artery (Fig 2, A) and resolution of the external compression of the IVC (Fig 2, B). There was also a presumably new occlusive left iliofemoral vein thrombus that had formed after the prior mechanical thrombectomy. Repeat mechanical thrombectomy was performed of the left iliac and femoral veins resulting in patency of the venous system. After thrombectomy, a 14 × 100 mm stent (Venovo, Bard/Becton, Dickinson and Company, Tempe, AZ) was placed in the iliac-IVC confluence. The venous dimensions improved from 19 to 131 mm² (Fig 2, C). A completion venogram (Fig 3, A) demonstrated significant improvement in common iliac and caval flow. The postoperative specimen is shown in Fig 3, B.

Outcome. The remainder of the patient's postoperative course was uneventful. Hysterectomy pathology was consistent with uterine fibroids. She was discharged with compression stockings, apixaban (Eliquis) 5 mg twice a day and clopidogrel (Plavix) 75 mg/day.² In office follow-up, she has complete resolution of her post-thrombotic symptomatology, returned to work, and continues lifestyle modifications. She will continue anticoagulation for a minimum of 6 months with consideration for life-long therapy. Fig 4 presents a timeline of the patient's course.

DISCUSSION

Uterine myoma is a common gynecological disease that may place a patient at high risk for DVT when

weighing more than 1000 g.³ The exact incidence of thrombosis secondary to fibroid disease is unknown, with no explicit guidelines for the treatment of large uterine myomas complicated by venous thrombosis. Available literature suggests placement of IVC filters before hysterectomy as the release of outflow obstruction following hysterectomy may result in PE.⁴ Other literature suggests the use of thrombolytics for large clot burdens.⁵ Our patient underwent mechanical thrombectomy before hysterectomy, limiting concern for clot dislodgement, with contraindications to thrombolytics given ongoing menorrhagia. An IVC filter was, therefore, thought not to be indicated. Regardless of approach, the goal is removal of the offending obstruction and treating the thrombus to limit post-thrombotic complications.¹

MTS refers to the right common iliac artery compressing the left common iliac vein against the lumbar spine, leading to venous outflow obstruction and a high risk of iliofemoral venous thrombosis. The condition was first diagnosed by Virchow in 1851 and has also been described as iliac vein compression syndrome or Cockett's syndrome.⁶ Patients commonly present with venous thrombosis of the left lower extremity, but may also present with left lower extremity swelling, pain, or venous reflux, which can progress to phlebitis and phlegmasia. Among anatomically acquired risk factors of DVT, compression by the right common iliac artery is a common pattern seen in 22% of the normal population and is responsible for 2% to 3% of all lower extremity DVTs and 18% to 49% of left-sided lower extremity DVT.⁷ It is more common in young, otherwise healthy women between 20 and 50 years of age.⁸ There have been multiple

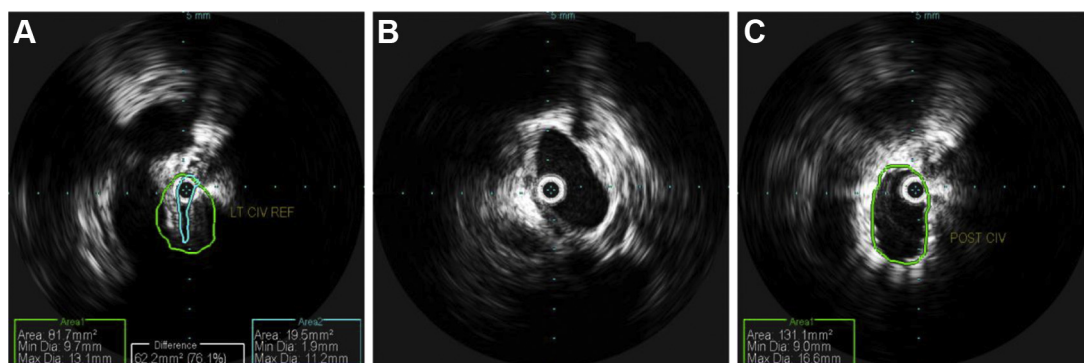


Fig 2. (A) An intravascular ultrasound examination was performed revealing near complete occlusion of the left common iliac vein with external compression by the right iliac common iliac artery. Left common iliac vein with associated area and diameter of vessel and open lumen. (B) Postintervention intraoperative image of intravascular ultrasound examination demonstrating patent inferior vena cava (IVC) without evidence of thrombus. (C) Postintervention intraoperative image of intravascular ultrasound imaging demonstrating the left common iliac vein with associated area and diameter of vessel and open lumen significantly increased in size after thrombectomy.

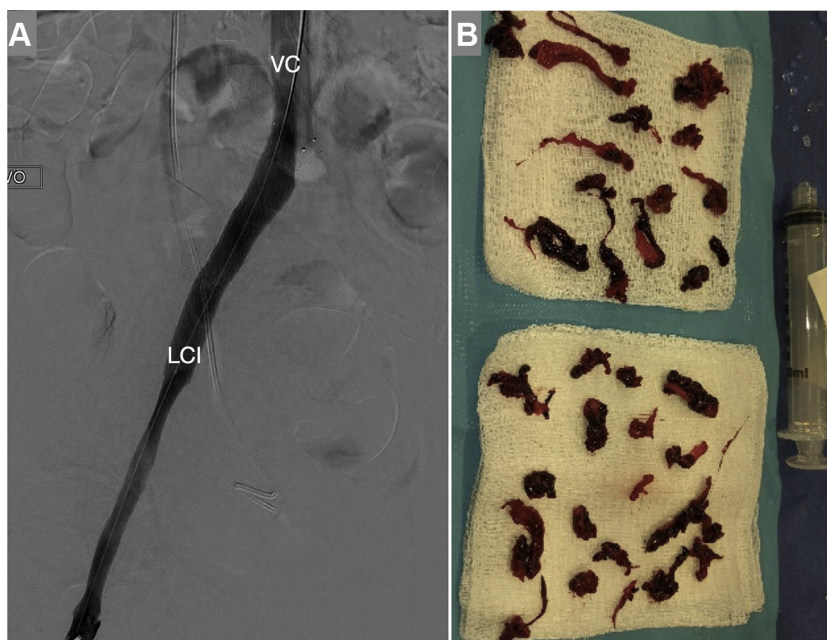


Fig 3. (A) Postintervention intraoperative venogram demonstrating contrast filling from the left common iliac vein (LCI) through to the inferior vena cava (IVC), suggestive of successful mechanical thrombectomy. (B) Postoperative specimen with multiple large clots retrieved from venous mechanical thrombectomy.

case reports published regarding MTS secondary to arterial reconstruction or stenting, aneurysm formation, or anatomical variants. This pathology is largely diagnosed by the presence of clinical features; however, literature supports IVUS examination as the gold standard for the diagnosis of MTS.^{6,9,10}

This case is unique because it involves a patient with both caval compression by a large uterine myoma and classic MTS secondary to arterial compression. The treatment of choice for patients with venous outflow obstruction is removal of the obstructing phenomenon.¹ The

advancements in endovascular techniques have facilitated treatment options of these conditions by direct thrombolysis, balloon angioplasty, mechanical thrombectomy, or stent placement.² The current recommendations are for removal of obstruction and venous stenting.¹¹

One could argue there are benefits of a single surgical approach. The authors believed the ability to remove the clot burden before removal of the obstruction followed by definitive endovascular therapy was the safest approach because it obviates the concern for clot

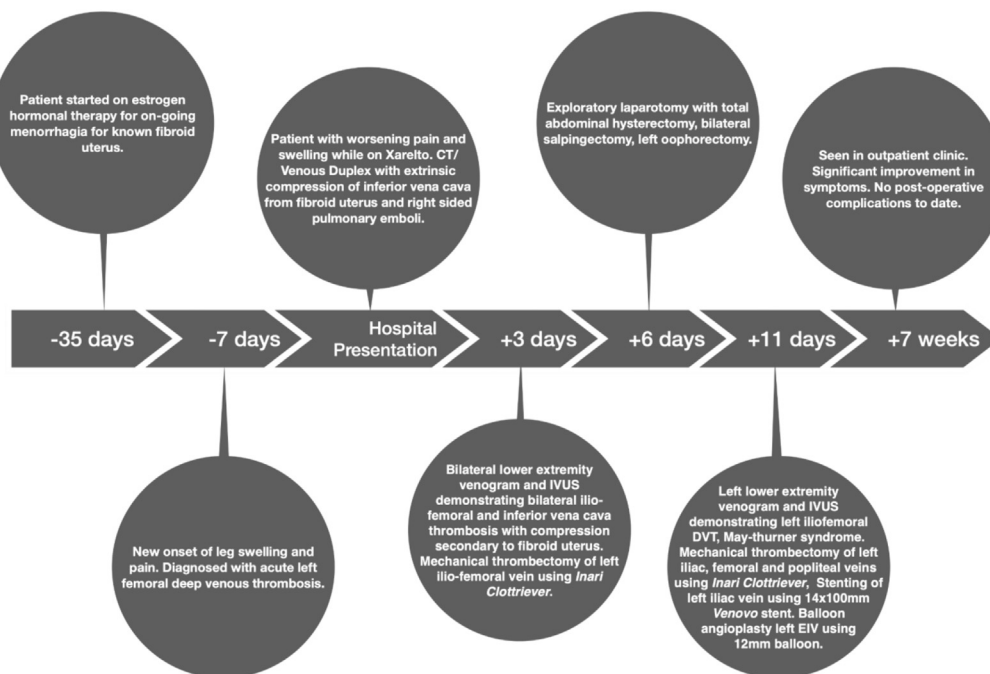


Fig 4. Complete timeline of the patient's pathological course. CT, computed tomography; DVT, deep venous thrombosis; EIV, external iliac vein.

dislodgement after a hysterectomy. Performing an IVUS examination before a hysterectomy confirmed infrarenal caval thrombosis by the uterine myoma, indicating a greater benefit from hysterectomy as opposed to simply performing this potentially morbid procedure. Our surgical team was able to present the patient with all options and believe there was no increased morbidity from the staged endovascular interventions.

CONCLUSIONS

Iliocaval thrombosis and MTS are two clinical pathologies that can be difficult to diagnose and require a high index of suspicion. This case report presents a unique patient with both conditions who successfully underwent staged endovascular intervention. We demonstrate the importance of a multidisciplinary approach, the importance of establishing a diagnosis and treating external causes of compression before definitive thrombus management.¹²

REFERENCES

- Comerota AJ. The current role of operative venous thrombectomy in deep vein thrombosis. *Semin Vasc Surg* 2012;25:2-12.
- Meissner MH, Gloviczki P, Comerota AJ, Dalsing MC, Eklof BG, Gillespie DL, et al. Early thrombus removal strategies for acute deep venous thrombosis: clinical practice guidelines of the Society for Vascular Surgery and the American Venous Forum. *J Vasc Surg* 2012;55:1449-62.
- Shiota M, Kotani Y, Uemoto M, Tobiume T, Tsuritani M, Shimaoka M. Deep-vein thrombosis is common in iliac artery with large uterine fibroids. *Tohoku J Exp Med* 2011;224:87-9.
- Maruyama T, Miyamoto A. Endovascular strategy for deep vein thrombosis caused by a huge uterine myoma accompanied by May-Thurner syndrome: a case report. *Radiol Case Rep* 2020;15:1921-6.
- Chang SC, Tsai MJ, Hsu CF. May-Thurner syndrome caused by a huge uterine myoma. *Ci Ji Yi Xue Za Zhi* 2017;29:235-6.
- Brinegar KN, Sheth RA, Khademhosseini A, Bautista J, Oklu R. Iliac vein compression syndrome: clinical, imaging, and pathologic findings. *World J Radiol* 2015;7:375-81.
- Oguzkurt L, Ozkan U, Tercan F, Koc Z. Ultrasonographic diagnosis of iliac vein compression (May-Thurner) syndrome. *Diagn Interv Radiol* 2007;13:152-5.
- Ahsan I, Qureshi BG, Ghani AR, Malik F, Arif Z. An extensive unprovoked left lower extremity deep vein thrombosis secondary to an anatomical anomaly: a case of May-Thurner syndrome. *Clin Pract* 2017;7:938.
- Yi JA, Hadley JB, Kuwayama DP. Atypical May-Thurner syndrome caused by endovascular aortic aneurysm repair. *J Vasc Surg Cases Innov Tech* 2020;6:397-400.
- Forauer AR, Gemmete JJ, Dasika NL, Cho KJ, Williams DM. Intravascular ultrasound in the diagnosis and treatment of iliac vein compression (May-Thurner) syndrome. *J Vasc Interv Radiol* 2002;13:523-7.
- Du Pont B, Verbist J, Van den Eynde W, Peeters P. Right-sided Cockett's syndrome. *Acta Chir Belg* 2016;116:114-8.
- Riley DS, Barber MS, Kienle GS, Aronson JK, von Schoen-Angerer T, Tugwell P, et al. CARE guidelines for case reports: explanation and elaboration document. *J Clin Epidemiol* 2017;89:218-35.

Submitted Nov 8, 2021; accepted Jan 28, 2022.