

Double-Row Arthroscopic Subscapularis Repair: A Surgical Technique



Brandon C. Cabarcas, B.S., Grant H. Garcia, M.D., Joseph N. Liu, M.D.,
Anirudh K. Gowd, B.S., and Anthony A. Romeo, M.D.

Abstract: The subscapularis is the strongest rotator cuff muscle in the shoulder. Until recently, most surgical repairs were performed through an open approach. Furthermore, the reporting of arthroscopic repair techniques and outcomes is fairly limited. This is likely due to the difficulty involved in all-arthroscopic repairs and the relative rarity of this injury compared with injuries of the other rotator cuff tendons. Arthroscopic subscapularis repair can be challenging, even for an expert surgeon, and attempting a double-row repair adds further complexity. Given these issues, this article provides techniques to allow for successful arthroscopic double-row subscapularis repair and avoid potential complications. The key features of an arthroscopic double-row repair include portal placement, surgical technique, and tips to avoid potential pitfalls, all of which are discussed.

The subscapularis comprises the anterior portion of the rotator cuff and plays a major role in stabilizing the shoulder in both the coronal and transverse planes.¹ Tears of the supraspinatus and even isolated upper fiber subscapularis tears have been shown to alter the biomechanics of the glenohumeral joint, increasing both anterior and superior humeral translation.² Subcoracoid stenosis and impingement causing tensile undersurface fiber failure have been proposed as a mechanism for the etiology of subscapularis tears.³ Although the advent of arthroscopy has allowed for significant advancements in the diagnosis and

treatment of subscapularis tears, all-arthroscopic repair of the subscapularis tendon remains a technically demanding procedure. Double-row repair offers the most secure fixation and, therefore, provides an environment that maximizes the potential for improved functional outcomes and decreased rates of rerupture.^{4,5} This procedure has been shown to demonstrate a significant biomechanical advantage compared with a single-row repair.⁶ Our preference for an all-arthroscopic double-row repair is motivated by both clinical experience and an evidenced-based approach.

Surgical Technique

Patient Positioning

The beach chair position is the authors' preferred technique for arthroscopic subscapularis repair. However, the lateral decubitus position can also be used. The patient is placed on the edge of the table so that the arm can be freely moved throughout the procedure. The shoulder anatomy is positioned in an orientation familiar to the surgeon, making the transition to an open repair approach relatively easy if an all-arthroscopic repair becomes unfeasible. This differs from the orientation of the patient in the lateral decubitus position, which can be more difficult to convert to an open procedure.

Portal Placement

Portal placement and operative technique are outlined in [Video 1](#). The following anatomic landmarks are

From the Department of Orthopaedic Surgery, Rush University Medical Center, Chicago, IL, U.S.A.

The authors report the following potential conflicts of interest or sources of funding: A.R. receives financial or material support from AANA and MLB; research support grants from Aesculap/B. Braun, Histogenics, Medipost, NuTech, OrthoSpace, Smith & Nephew, and Zimmer; grants, personal fees, IP royalties, other financial and material support, research support, and consultant and presenter or speaker payments from Arthrex; and personal fees, publishing royalties, and financial or material support from Saunders/Mosby-Elsevier and SLACK. Full ICMJE author disclosure forms are available for this article online, as [supplementary material](#).

Received March 2, 2018; accepted March 28, 2018.

Address correspondence to Brandon C. Cabarcas, B.S., Rush University Medical Center, Orthopaedic Surgery, 1611 W Harrison St, Suite 300, Chicago, IL 60612, U.S.A. E-mail: bcabarcas44@gmail.com

© 2018 by the Arthroscopy Association of North America. Published by Elsevier. This is an open access article under the CC BY-NC-ND license (<http://creativecommons.org/licenses/by-nc-nd/4.0/>).

2212-6287/18289

<https://doi.org/10.1016/j.eats.2018.03.020>

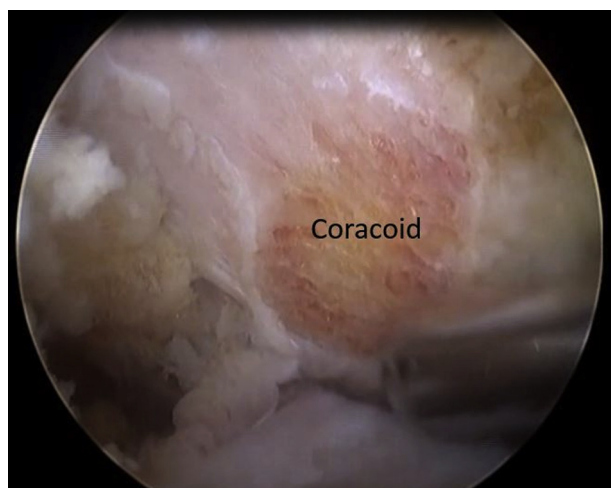


Fig 1. Right-sided coracoplasty performed with a 4.0-mm arthroscopic burr in the anterior portal allows for more space anterior to the subscapularis. After coracoplasty, there should be 5 to 10 mm of space between the coracoid and subscapularis. Viewed from posterior portal.

identified and marked: acromion-clavicular articulation, clavicle, acromion, spine of the scapula, and coracoid process. The posterior portal is placed in the soft spot, which is 2 cm inferior and 1 to 2 cm medial to the posterior lateral corner of the acromion. The anterior portal is placed just lateral to the coracoid. The lateral portal placement is best confirmed with an 18-gauge needle through the skin when viewing from the posterior portal and is often 3 cm inferior to the palpable lateral edge of the acromion. A final anterosuperior lateral portal is then placed 2 fingerbreadths off the edge of the anterolateral corner of the acromion and initially localized with an 18-gauge needle through the skin while viewing from the subacromial space. The anterior and anterosuperior lateral portals are the main working portals for subscapularis repair, whereas the posterior and lateral portals are used for viewing.

Preparation and Evaluation of the Glenohumeral Joint

The basic rotator cuff repair principles of tear pattern recognition, tendon mobilization, footprint preparation,

and tension-free repair should be followed in both primary and revision settings. A 30° arthroscope (Arthrex, Naples, FL) is preferred to obtain optimal visualization, although a 70° arthroscope can be very useful when performing the procedure in the lateral decubitus position. A subscapularis repair is performed first if a concomitant supraspinatus tear is present because repair of the subscapularis can help to reduce the supraspinatus to a more anatomic position. Also, swelling may decrease the anterior shoulder working space, leading to compromised visualization if the subscapularis repair is performed later in the case.

A systematic evaluation of the entire glenohumeral joint is performed, including dynamic examination of rotator cuff tendons. Any subscapularis retraction or subluxation of the long head of the biceps is noted. When in the subacromial space, evaluation and dissection of the axillary nerve may be necessary if significant subscapularis retraction is present.

The long head of the biceps tendon is frequently involved with subscapularis tears. Generally, the medial sling is disrupted and subluxation is present. Regardless of disruption, before subscapularis mobilization, the biceps tendon is amputated to improve visualization, and a biceps tenodesis is performed after the repair. In some cases, biceps tendon rupture can be the presenting symptom, in which retrieval and tenodesis are performed after all rotator cuff tendons are repaired.

Following biceps amputation, the remaining rotator interval tissues are debrided and a coracoplasty is performed with an electrothermal device (Super Turbovac 90; Smith & Nephew, Andover, MA). This is done by clearing periosteum from the posterior coracoid and using a 4.0-mm arthroscopic burr to remove bone from the posterolateral aspect (Fig 1). These steps are essential for achieving adequate visualization and crucial for a successful repair (Table 1). This step is analogous to an acromioplasty for a supraspinatus repair.

Subscapularis Tendon Mobilization and Approximation

A 270° release of the subscapularis tendon is performed using the following approach:

Table 1. Surgeon Pearls and Pitfalls

Pearls	Pitfalls
Coracoplasty is essential for adequate visualization and appropriate working space. Use a 70° arthroscope, if necessary, to improve visualization.	Beware of partial tears, as they may make it difficult to assess the lower edge of the subscapularis. Poor visualization may complicate the case, especially during a surgeon training period.
Extend dissection to medial border of subscapularis for complete removal of adhesions. Ensure proper suture management.	Overmobilization may lead to injury of the nearby neurovascular structures. Overdebridement of the rotator interval can cause increased swelling, necessitating prompt fixation.
Perform a posterior-level push for additional space, if needed.	Failure to reapproximate the appropriate tendon tension or anatomic footprint may increase the risk of failure.

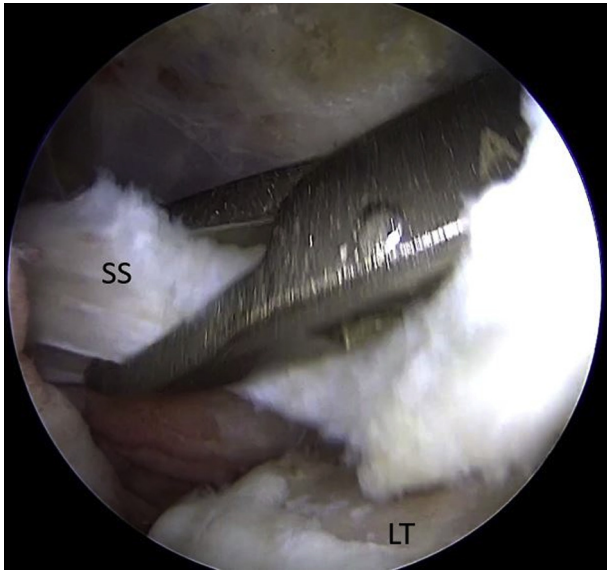


Fig 2. Right subscapularis (SS) tendon approximation and excursion test performed with an arthroscopic grasper (Kingfisher; Arthrex) in the anterosuperior lateral portal. This excursion test serves to help define the previously distorted anatomy of the tendon and characterize the repair footprint. Viewed from posterior portal. (LT, lesser tuberosity of humerus.)

- Superior margin from coracoid.
- Posterior from anterior capsule and scapular neck.
- Anterior from conjoined tendon.

Additional release of the coracohumeral ligament is needed if further mobilization is required. Also, the middle glenohumeral ligament is identified and separated from the tendon with an electrothermal device.

The anterosuperior lateral portal is then established, and an arthroscopic grasper (Kingfisher; Arthrex) is used to identify maximal tendon excursion (Fig 2). This “excursion test” serves to define the potential repair footprint. The arm is internally rotated and abducted to

deliver the tuberosity, and a 4.0-mm arthroscopic burr is used to clear the appropriate footprint down to bleeding bone.

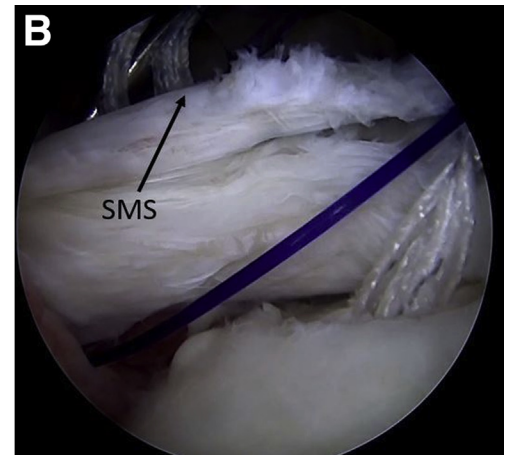
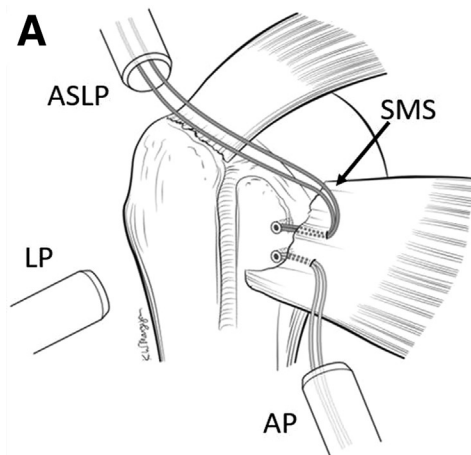
Anchor and Suture Placement

Medial-row suture anchors are placed 5 mm away from the articular surface through the anterior portal. The SwiveLock 4.75 mm anchors (Arthrex) loaded with FiberTape (Arthrex) are preferred. The first anchor is placed at the tear’s inferior margin, and all subsequent medial-row anchors are placed further superiorly. The number of medial-row anchors varies with tear size. Normally, 2 medial-row anchors are sufficient, with 1 anchor placed per every 1 cm of exposed footprint.

The inferior medial anchor is placed after using a 4.75-mm punch (Arthrex) to facilitate insertion. All sutures are then pulled through the anterior cannula. Using a switching stick to remove the cannula, the sutures are pulled outside through the same portal or through an accessory portal to aid in suture management. The sutures are passed with a suture-passing device (30° SutureLasso or Penetrator Retriever; Arthrex) at an angle medial to lateral through the full thickness of the tendon, which best approximates the anatomic footprint. An arthroscopic retriever (FiberTape Retriever; Arthrex) is used to retrieve the shuttled sutures. A second medial anchor is generally used (superior), which is passed in a similar manner (Fig 3). Care is taken to separate the inferior and superior sutures to prevent tangling.

In some cases, a separate inverted mattress suture is passed at the most superior portion of the tendon to properly reapproximate the uppermost portion of the tendon and establish the lower edge of the rotator interval (Table 1). The mattress stitch is retrieved through the lateral portal and can be secured separately with a 4.75-mm anchor (SwiveLock; Arthrex) once passage is completed or integrated into the final lateral-row repair.

Fig 3. (A) Orientation of superior and inferior medial suture anchors with suture limbs. The number of medial-row anchors varies with the size of the tear. Generally, 2 are used with 1 anchor placed per 1 cm of exposed footprint. (B) Superior medial suture (SMS) passage performed with a suture passing device (30° SutureLasso; Arthrex) in the anterosuperior lateral portal. Viewed from posterior portal on the right side. (ASLP, anterosuperior lateral portal; AP, anterior portal; LP, lateral portal.)



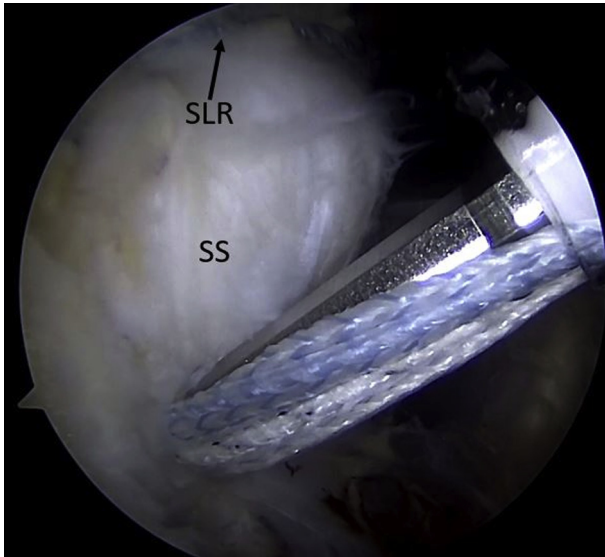


Fig 4. Inferior lateral-row anchor placement in the bicipital groove performed with 4.75-mm anchors (SwiveLock; Arthrex) loaded with FiberTape (Arthrex) in the lateral portal. Suture anchors designed for cancellous bone are ideal for this technique. Viewed from posterior portal on the right side. (SLR, superior lateral row; SS, subscapularis.)

Achieving Adequate Fixation

Final lateral-row fixation is performed once all medial-row sutures have been passed and separated. One suture limb from each medial-row anchor is retrieved from the lateral portal and loaded onto a 4.75-mm anchor (SwiveLock; Arthrex). The bicipital groove is prepared with a 4.0-mm arthroscopic burr and electrothermal device, and the loaded 4.75-mm anchor is placed into the empty bicipital groove to form the superior lateral row. The remaining medial suture limbs from each medial-row anchor are loaded onto a second 4.75-mm anchor (SwiveLock; Arthrex), and this is placed 1 cm below the superior anchor to form the inferior lateral row (Fig 4).

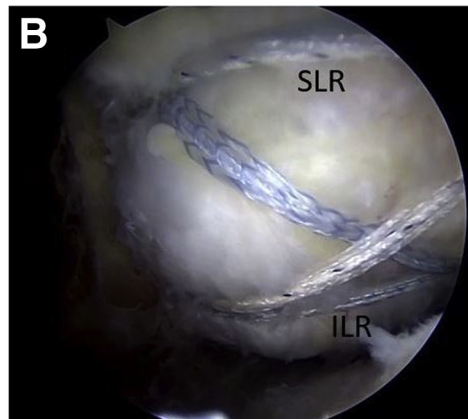
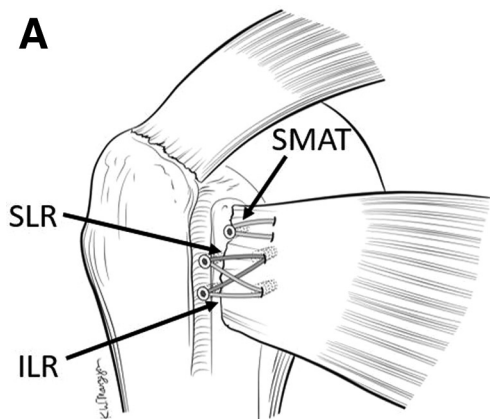


Fig 5. (A) Orientation of superior lateral row (SLR), inferior lateral row (ILR), and superior mattress stitch (SMAT) after completion of the subscapularis tendon double-row repair. (B) Final range-of-motion testing of the integrity of the subscapularis tendon repair is done viewing from the posterior and lateral (pictured) portals on the right side. Once the subscapularis tendon is repaired, any remaining pathology is addressed. Commonly, a biceps tenodesis is also performed.

Final Testing and Concomitant Procedures

Once the original tendon has been secured, the shoulder is put through range-of-motion testing under arthroscopic visualization to assess the integrity of the repair (Fig 5). Any remaining pathology is addressed. A biceps tenodesis is normally performed, with our preferred technique being open subpectoral tenodesis.

Discussion

The technical difficulties associated with a double-row repair may be a reason for the dearth of literature on this topic. Studies reporting clinical outcomes following this technique are scarce, with most combining single-row repair patients in their cohorts. Grueninger et al.⁷ performed a double-row repair on 11 patients with a mean age of 45 years and a mean follow-up of 12 months. Constant scores improved from 43 to 89 postoperatively, and lift-off strength and belly press improved from 2.9 to 4.8 (out of 5). No complications were reported. Lafosse et al.⁸ demonstrated good results in 17 patients with a mean age of 47 years and mean follow-up of 29 months. Their cohort was mixed, with 64.7% of these patients (11/17) receiving a double-row repair. Constant scores improved from 52 to 85, and belly press improved from 2.5 to 4.4 (out of 5). Improved outcomes have also been reported in relatively younger patients after arthroscopic subscapularis repair. In 70 patients younger than 45 who underwent single- or double-row repair, mean postoperative American Shoulder and Elbow Surgeons and Constant scores were reported at 84.6 and 81.7, respectively, after an average of 35.8 months.⁹ Additionally, forward flexion significantly improved from 158.7° to 168.4°, and a 4% failure rate was reported. Although these studies are limited in their ability to solely evaluate results after arthroscopic double-row repair, as a whole they demonstrate a trend of favorable clinical outcomes in a variety of patient populations.

A systematic review by Saltzman et al.⁵ evaluated 8 arthroscopic subscapularis studies. Of the 8 studies that met their criteria, only 3 used a double-row repair in a portion of their patients. After subanalysis of the data, they found a lower rerupture rate with a double-row repair (0%) compared with a single-row technique (5%-10%). In addition, they reported better Constant strength scores improvements with double row (a change of 14) compared with single row (a change of 9). Additionally, they found that patients treated with the double-row technique often had higher grade pre-operative tears, demonstrating a surgeon preference for a more extensive repair with difficult cases. Positive clinical outcomes were also reported by Lanz et al.¹⁰ in a case series of 52 patients who underwent arthroscopic repair of Lafosse type III and IV subscapularis tears with primarily double-row configuration at 2 to 4 years of follow-up. Both mean Constant scores (46.4-79.9 points) and University of California, Los Angeles scores (15.1-31.5 points) significantly improved with an associated strength restoration compared with the contralateral shoulder up to 96%.

The body of literature regarding arthroscopic double-row repair of the subscapularis tendon is generally lacking. Although a potential explanation may be the technical difficulty associated with the procedure, the available evidence demonstrates excellent clinical outcomes after double-row repair.^{5,7,8,10,11} Limitations of the technique include the potential risk for iatrogenic neurovascular injury upon anterior release of the subscapularis tendon. The axillary nerve runs along the inferior and lateral border of the subscapularis, and the posterior circumflex humeral artery courses along with the axillary nerve to eventually enter the quadrangular space.¹² These structures are not routinely visualized; therefore, awareness of their anatomic locations must be maintained to safely achieve adequate tendon mobilization. Conversely, if adequate mobilization and reapproximation of the tendon are not achieved, the risk of failure may increase. Poor visualization may complicate the case, especially in cases of concomitant posterior and superior tears of rotator cuff tendons. A thorough arthroscopic examination is necessary to detect partial-thickness subscapularis tears that may be difficult to observe, as the prevalence of subscapularis tears in patients undergoing arthroscopic rotator cuff repair has been reported to be higher than 31%.¹³ Increased swelling may significantly reduce the working space and visualization in the anterior shoulder if the rotator interval is overdebrided or the subscapularis tear is addressed after concomitant rotator cuff tendon tears. Nonetheless, success is likely with this technique if these risks and limitations are properly kept in mind and addressed throughout the case.

In this article, we have outlined our recommended technique to perform an all-arthroscopic double-row subscapularis repair. Our goal was to improve the feasibility of this procedure to both maximize anatomic repair integrity and potentially improve clinical outcomes for this specific patient group.

References

1. Garofalo R, Flanagan BF, Castagna A, Krishnan SG. Subscapularis tear: Intraoperative evaluation and treatment. In: Gumina S, ed. *Rotator cuff tear: Pathogenesis, evaluation and treatment*. Cham, Switzerland: Springer, 2017;345-351.
2. Su W-R, Budoff JE, Luo Z-P. The effect of anterosuperior rotator cuff tears on glenohumeral translation. *Arthroscopy* 2009;25:282-289.
3. Lo IK, Burkhart SS. The etiology and assessment of subscapularis tendon tears: A case for subcoracoid impingement, the roller-wringer effect, and TUFF lesions of the subscapularis. *Arthroscopy* 2003;19:1142-1150.
4. Denard PJ, Burkhart SS. Arthroscopic recognition and repair of the torn subscapularis tendon. *Arthrosc Tech* 2013;2:e373-e379.
5. Saltzman BM, Collins MJ, Leroux T, et al. Arthroscopic repair of isolated subscapularis tears: A systematic review of technique-specific outcomes. *Arthroscopy* 2017;33:849-860.
6. Wellmann M, Wiebringhaus P, Lodde I, et al. Biomechanical evaluation of a single-row versus double-row repair for complete subscapularis tears. *Knee Surg Sports Traumatol Arthrosc* 2009;17:1477-1484.
7. Grueninger P, Nikolic N, Schneider J, et al. Arthroscopic repair of traumatic isolated subscapularis tendon lesions (Lafosse type III or IV): A prospective magnetic resonance imaging—controlled case series with 1 year of follow-up. *Arthroscopy* 2014;30:665-672.
8. Lafosse L, Jost B, Reiland Y, Audebert S, Toussaint B, Gobeze R. Structural integrity and clinical outcomes after arthroscopic repair of isolated subscapularis tears. *J Bone Joint Surg Am* 2007;89:1184-1193.
9. Lin EC, Mall NA, Dhawan A, et al. Arthroscopic primary rotator cuff repairs in patients aged younger than 45 years. *Arthroscopy* 2013;29:811-817.
10. Lanz U, Fullick R, Bongiorno V, Saintmard B, Campens C, Lafosse L. Arthroscopic repair of large subscapularis tendon tears: 2- to 4-year clinical and radiographic outcomes. *Arthroscopy* 2013;29:1471-1478.
11. Barth J, Fotiadis E, Barthelemy R, Genna S, Saffarini M. Ultrasonic evaluation of the repair integrity can predict functional outcomes after arthroscopic double-row rotator cuff repair. *Knee Surg Sports Traumatol Arthrosc* 2015;23:376-385.
12. Kuntz AF, Raphael I, Dougherty MP, Abboud JA. Arthroscopic subscapularis repair. *J Am Acad Orthop Surg* 2014;22:80-89.
13. Narasimhan R, Shamse K, Nash C, Dhingra D, Kennedy S. Prevalence of subscapularis tears and accuracy of shoulder ultrasound in pre-operative diagnosis. *Int Orthop* 2016;40:975-979.