

Episcleral plaque brachytherapy using 'BARC I-125 Ocu-Prosta seeds' in the treatment of intraocular tumors: A single-institution experience in India

Parag K Shah, V Narendran, U Selvaraj¹, P Guhan¹, Sanjay K Saxena², Ashutosh Dash², Melvin Astrahan³

Context: To analyze the results of episcleral plaque brachytherapy using indigenous Bhabha Atomic Research Centre (BARC) Iodine-125 Ocu-Prosta seeds for the management of intraocular tumors from a single institute. **AIM:** To report our initial experience and learning curve on the use of 'BARC I-125 Ocu-Prosta seeds' for the management of intraocular tumors such as choroidal melanomas, retinoblastomas and vasoproliferative tumors (VPT). **Materials and Methods:** We retrospectively reviewed 13 eyes of 13 patients who underwent ophthalmic brachytherapy between May 2008 to March 2012. Nine cases had choroidal melanomas; three had retinoblastomas while one case had VPT. **Results:** For choroidal melanomas the average apical diameter before brachytherapy was 7.6 mm and average largest basal diameter was 12.1 mm, respectively, which reduced to 4.2 mm and 7.7 mm after the procedure at an average follow-up of 24 months (range 10-43 months). Retinoblastoma and VPT also showed good regression after brachytherapy. **Conclusion:** Plaque radiotherapy using ¹²⁵I seeds can be performed under peribulbar anesthesia and provides a viable option for the management of intraocular cancer with minimal invasiveness and surgical complications. Patients in our studies experienced excellent local tumor control. With the availability of indigenous 'BARC I-125 Ocu-Prosta seeds' locally, cost effective ophthalmic brachytherapy can be performed in India.

Key words: 'BARC I-125 Ocu-Prosta seeds', choroidal melanoma, plaque brachytherapy, retinoblastoma, vasoproliferative tumors, Asian Indian

There are very few reports in the literature on malignant melanoma of the uveal tract in the Asian Indian population.^[1] India is one of the low incidence regions of the world. Because of the relative rarity of the condition it is not often suspected till the tumor is large enough to cause a secondary retinal detachment. Many patients with uveal melanoma have a reasonable chance of surviving and retaining the eye with good vision. Therefore, it is important to identify them and begin treatment before metastasis occurs. Over the past decade, brachytherapy using removable episcleral plaques containing sealed radioisotope sources is being studied as an effective modality in the treatment of intraocular tumors like choroidal melanomas,^[2] retinoblastoma^[3] and vasoproliferative tumors (VPT).^[4] Iodine-125 is currently the most commonly used isotope for plaque radiotherapy. The Collaborative Ocular Melanoma Study (COMS), which was the largest randomized clinical trial comparing ¹²⁵I brachytherapy vs enucleation for

medium-sized choroidal melanoma revealed that there was no statistically significant difference in all-cause mortality between the two groups.^[2,5,6] Retinoblastoma's and VPT have also shown good results following ¹²⁵I brachytherapy.^[3,4]

The Radiopharmaceuticals Division, Bhabha Atomic Research Centre (BARC) has successfully developed a technology for the production of indigenous ¹²⁵I brachytherapy sources for the treatment of ocular cancer patients in India^[7,8] and assessed its dosimetry.^[9] We describe our initial experience and learning curve using 'BARC ¹²⁵I Ocu-Prosta seed' for the treatment of intraocular tumors.

Materials and Methods

This is a retrospective case series from May 2008 to March 2012. Thirteen patients were operated. Eight were with posterior choroidal melanomas, one with ciliary body melanoma, three with retinoblastomas and one with VPT. All the cases with melanomas underwent chest X-ray, ultrasound of abdomen and clinical examination by an oncologist to rule out metastasis. The steps involved in brachytherapy were the following.

Dosimetry (Dose Calculation)

We used the plaque simulator software version 5.3.9 (Bebig GmbH, Berlin, Germany), developed by one of the authors (MA). It is a three dimensional treatment planning software. Modelling of the eye is done first using axial computerized tomography or magnetic resonance image, from the center of the eye. Next, modeling of the tumor is done using the ultrasound image. The largest longitudinal, circumferential and apical diameters are entered in the software. The fundus image is next uploaded on the software to chart the tumor location and also to measure the exact distance from optic disc to fovea. This creates a precise computer model of the patient's

Access this article online

Website:

www.ijo.in

DOI:

10.4103/0301-4738.98708

Quick Response Code:



Department of Pediatric Retina and Ocular Oncology, Aravind Eye Hospital and Postgraduate Institute of Ophthalmology, Coimbatore, ¹Department of Oncology, Sri Ramakrishna Hospital, Coimbatore, Tamilnadu, ²Department of Radiopharmaceuticals Division, Bhabha Atomic Research Centre, Trombay, Mumbai, India, ³Emeritus Professor, University of Southern California School of Medicine, Los Angeles, California, USA

Correspondence to: Dr. Parag K. Shah, Department of Pediatric Retina and Ocular Oncology, Aravind Eye Hospital, Avinashi Road, Coimbatore- 641 014, Tamil Nadu, India. E-mail: drshahpk2002@yahoo.com

Manuscript received: 31.08.11; **Revision accepted:** 16.02.2012

This paper received the AIOS-Sujatha Savithri Rao Best Paper Award, 2010

eye and tumor. The prescription point is the apex of the tumor for all having apical diameter >5 mm and it is kept at 5 mm for all tumors with apical diameter <5 mm. Dose calculated was 85 Gy for choroidal melanomas [Fig. 1] till tumor apex. For retinoblastomas and VPT it was kept as 40 Gy. The average dose rate in our study was 0.62 Gy/hr (range 0.44-0.9 Gy/hr), given over 2-8 days depending on the tumor type and size.

Selection of plaques

Commercially both rimmed and unrimmed plaques are available. The COMS plaques are circular rimmed plaques available in five sizes, 12, 14, 16, 18 and 20 mm. There are several disadvantages of COMS plaques. First, they are rimmed and hence bulky. Thus they cannot be passed behind the rectii muscle without resecting them. Second, as they are circular in shape, they cannot be used for tumors near the optic nerve which would require a notched plaque. Third, the seeds have to be loaded on a Siliastic™ carrier which is then fitted over the plaque [Fig. 2]. Thus when placed over the eye, there is a

1-mm gap between the seeds and the sclera. Hence higher dose is required to reach the tumor apex which correspondingly increases the scleral dose and also to the structures distal to the apex. Fifth, as there is lateral overlap of the radiation from the corresponding seeds, the effective dose to sclera is higher. Sixth, they are expensive. All these disadvantages are partly overcome by the unrimmed slotted plaques (Eyephysics, LLC, Los Alamitos, CA). Three of the currently available plaques, models 517, 917 and 2025 are pictured in Fig. 3. New computer-prototyped plaques are in development according to the manufacturer. Being unrimmed, they are thin (≤ 2 mm) and can easily be passed behind the rectii muscles without resecting them. The model 917 also has a notch which can accommodate the optic nerve for tumors close to it. Because the ¹²⁵I seeds are glued into individually collimating slots carved into the concave surface of the gold plaque, the seeds are closer to the sclera compared to the seeds in the Siliastic™ carrier of a COMS plaque. Most of the laterally directed soft radiation emanating from the seeds in an Eye Physics plaque is blocked by the gold collimation, eliminating much of the radiation overlap immediately in front of the plaque [Fig. 4].

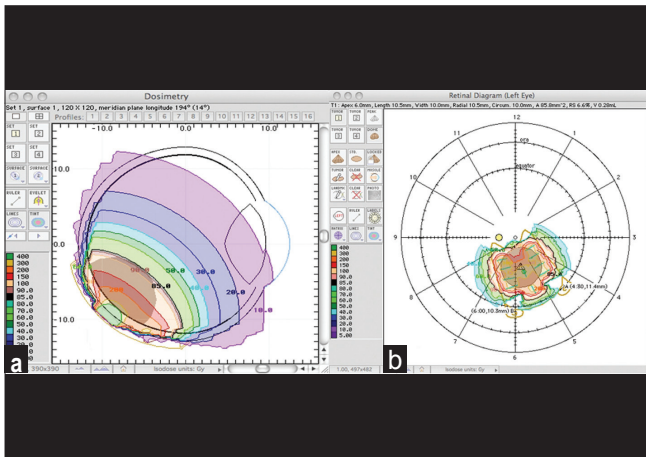


Figure 1: (a) Longitudinal section of computerized model of the eye ball with the tumor (posterior melanoma) as seen in the planning software. The various doses of radiation the tumor is exposed to once the plaque is fixed on the sclera and is demonstrated in different colors. Note 85 Gy (black color) is just covering the apex of the tumor. (b) Computerized model of transverse section of the same tumor on retinal chart



Figure 2: (a) Circular COMS plaque seen above along with the corresponding circular siliastic carrier below which is loaded with the I-125 seeds. (b) Siliastic carrier fitted in the COMS plaque with the seeds on inside surface

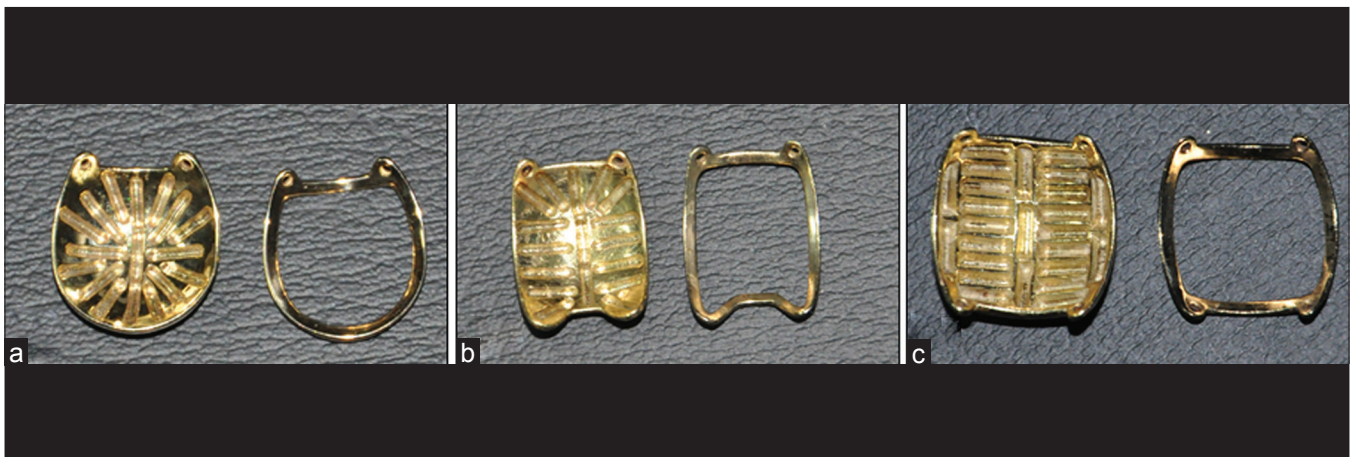

Figure 3: (a-c) Models 517, 917 and 2025 slotted gold plaques (Eyephysics, LLC, Los Alamitos, California, USA) along with the corresponding dummy plaques (wire frames). Note model 917 in the center has a notch for tumors close to optic nerve

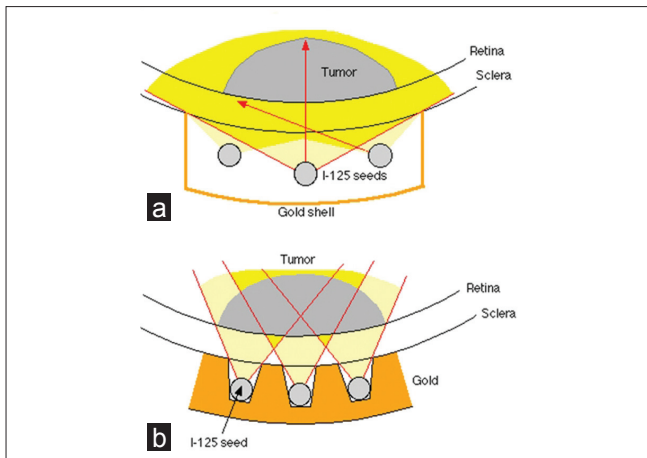


Figure 4: (a) Illustration of COMS plaque showing a gap between the seeds and the sclera. Hence higher dose is required to reach the tumor apex which correspondingly increases the scleral dose and also to the structures distal to the apex. There is lateral overlap of the radiation from the corresponding seeds (dark yellow). Thus the effective dose to sclera is higher. (b) Slotted plaque showing the seeds closer to sclera and minimal overlap of radiation (dark yellow) compared to COMS plaque, hence lesser dose to sclera

Reducing this overlap more than compensates for the anticipated “inverse-square” increase in dose to the sclera adjacent to each seed that results from the seeds being closer to the sclera (compared to the COMS plaque). It also reduces radiation to the structures adjacent to the plaque edges and distal to the tumor apex. Surprisingly, these plaques can also be less expensive than COMS plaques.

¹²⁵I sources

‘BARC ¹²⁵I Ocu-Prosta seeds’ consisting of ¹²⁵I source of dimension 4.75 mm (l) × 0.8 mm (φ) encapsulated in titanium capsules were supplied by Radiopharmaceuticals Division of Bhabha Atomic Research Center, Mumbai. A novel method of adsorption of radioiodine (¹²⁵I) on palladium-coated silver rod was developed. By this method, 3 - 4 mCi of ¹²⁵I could be firmly deposited.^[7,8] Titanium capsules were used for encapsulation [Fig. 5]. These sources were encapsulated using a 50-W, Neodymium:Yttrium-Aluminum-Garnet laser welding system. The laser-welded sources were subjected to numerous checks such as visual inspection, activity measurement, swipe test, leak test, immersion test, etc., that are obligatory by regulatory authorities.^[10]

Preparation of plaque

Once the basic dosimetry is done, seeds were placed into the slots of the plaque and glued to achieve a desired dose rate distribution. The typical activity used were 3-4 mCi per seed so as to achieve treatment dose rates of 0.5-1.25 Gy/h, with a prescription dose of 40-80 Gy delivered in 5-12 consecutive days. Seed assignment was straightforward as seeds were fabricated as per requirement. Prior to surgery, the plaque was sterilized by flash autoclaving for 4 minutes.

Surgical procedure

Under peribulbar block localized peritomy is done in the quadrant where tumor is present. Bridle sutures of the corresponding rectii muscles are taken. The tumor margins

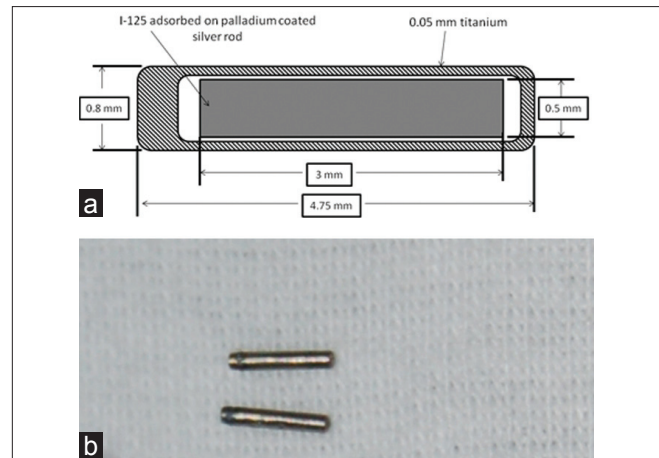


Figure 5: (a) Illustration showing cross section and the dimensions of BARC I-125 Ocu-Prosta seeds. (b) BARC I-125 Ocu-Prosta seeds

were identified using transscleral illumination and indirect ophthalmoscopy. A minimum safety margin of 2 mm is maintained. The exact clock hours are marked on the limbus. Then the exact distance of suture placement points from the limbus are marked with marker pen using a calliper. The dummy plaque (“cold plaque”) is then secured with temporary knots after passing the sutures through the eye-lets. The placement of the dummy plaque is confirmed by indirect ophthalmoscopy and scleral indentation. Keeping the episcleral sutures in place, the dummy plaque is then replaced with the “hot plaque” containing the radioactive seeds and then the suture knots are made permanent [Fig. 6]. The plaque is then covered with the conjunctiva. The plaque is then removed after an appropriate time as per the dosimetry. During that time the patient is kept in an isolated room with the eye covered with a lead shield. Immediately after the plaque removal, the eye is then checked for any residual radiation by the physicist using radiation survey meter. This is to make sure that all the seeds have been removed and none are left behind accidentally. The seeds are then unloaded by the physicist after soaking it for few minutes in acetone and sent back in a special lead container for proper disposal.

Radiological safety

All steps of the treatment procedure were planned in advance to minimize radiation exposure of personnel. All radioactive source movements were recorded. The personnel involved in this work were monitored for radiation exposure levels by thermoluminescent dosimetry (TLD) badge.

Results

From May 2008 to January 2011, we operated 13 eyes of 13 patients. The type of tumor with baseline tumor size is given in Table 1. Majority of patients noted a decreased visual acuity at the time of presentation.

Choroidal melanomas

Of the 13, nine were with choroidal melanomas. Of these, eight were posterior while one case involved the ciliary body region. The COMS study had divided the choroidal melanomas into three types, viz. small, medium and large according to the size.^[11] Tumors with apical diameter (AD) <1 mm and largest

Table 1: Baseline characteristics of the tumors

Tumor type	Apical diameter (mm)	Largest basal diameter (mm)
Large posterior melanoma	13.4	12.3
Medium ciliary body melanoma	3.8	5.2
Medium posterior melanoma	4.5	11.5
Medium posterior melanoma	8.1	8.3
Medium posterior melanoma	7.9	13.8
Medium posterior melanoma	4.5	13.5
Large posterior melanoma	9	17.3
Medium posterior melanoma	5.8	10.1
Large posterior melanoma	11	16.8
Retinoblastoma	3.1	11.5
Retinoblastoma	3	7.5
Retinoblastoma	3.7	6.3
Vasoproliferative tumor	4	9

basal diameter (LBD) <5 mm are called as choroidal naevus. Although the precise COMS size criteria were somewhat more complicated and also changed over the course of the study, generally speaking, tumours with AD between 1 and 3 mm and LBD between 5 and 16 mm are classified as small melanomas. With AD between 3 and 10 mm and LBD between 5 and 16 mm are classified as medium (unless it is located within 2 mm from optic disc) and tumors with AD >10 mm and LBD >16 mm are classified as large melanomas. Of the nine cases, six were medium sized and three were large melanomas. The mean AD was 7.6 mm (range 3.8-13.4 mm) and mean LBD was 12.1 mm (range 5.2-17.3 mm). The average seed strength was 3.2 mCi (range 2.88-3.54 mCi) and the average number of seeds used was 16.1 (range 9-25). The average number of days for plaque removal was 6.4 days (range 4-8 days) and the average dose rate was 0.58 Gy/hour (range 0.44-0.89). Model 2025 was used for five cases while model 917 was used for remaining four. Transpupillary thermotherapy (TTT) was given in the three large melanomas, 2 days before plaque removal as part of the sandwich technique described by Kreusel *et al.*^[12] In immediate postoperative period case 1 had vitreous hemorrhage with hemorrhagic choroidal detachment and case 3 had bleeding inside the tumor [Fig. 7]. Both these complications were assumed to be due to the sharp tip of the diaphanoscope, which is the instrument used for transillumination [Fig. 8]. After these two initial complications, we did localization of posterior tumors by indirect ophthalmoscopy and scleral indentation and did not face similar complications. At the mean follow-up of 24 months (range 10-43 months), the average AD reduced to 4.2 mm and 7.7 mm, respectively [Fig. 9]. Two eyes were enucleated after brachytherapy at 10 and 18 months. Both cases developed active exudation and hemorrhage suggestive of advanced radiation retinopathy. Although in both cases tumor had not increased in size, there was optic nerve infiltration in one case and other one was case 3, which had got injured by the diaphanoscope. The tumor completely disappeared in a large and a medium-sized posterior melanoma. One case, at 3 years follow-up, was found to have optic atrophy postvitrectomy for nonresolving vitreous hemorrhage. Of the seven cases, five had visual acuity of >20/200 before brachytherapy and by last follow-up this was reduced to three [Table 2].

Retinoblastoma

Three eyes of three babies had retinoblastoma. All were recurrent tumors after completing six cycles of chemotherapy and several sittings of laser. The mean AD was 2.6 mm and mean LBD was 8.4 mm. The average dose given was 40 Gy with the average dose rate of 0.75 Gy/hr. The plaque was kept for an average of 2.5 days. Case one was enucleated at 4.2 month follow-up as it developed peripheral new tumors along with vitreous hemorrhage. Second case was lost to follow-up. The third case did extremely well. This tumor kept on recurring even after 13 cycles of chemotherapy and several sittings of laser. With ¹²⁵I brachytherapy, it regressed within 2 weeks time and the child is doing extremely well at 15 months follow-up.

Vasoproliferative tumor

We did brachytherapy in a single case of VPT. The AD was 4 mm and LBD was 9 mm. It was situated in inferotemporal quadrant beyond the equator with exudative retinal detachment involving inferior half of retina. The dose given was 40 Gy and the plaque was kept for 3 days. At 21-month follow-up, the tumor had become flat with markedly reduced exudation and vascularization. The exudative retinal detachment also completely settled. Prior to brachytherapy, triple freeze thaw cryotherapy along with intravitreal injection of bevacizumab was tried without success.

Discussion

This study gives our experience and learning curve in the management choroidal melanomas, retinoblastomas and VPT with indigenous ¹²⁵I brachytherapy. Risk factors for intraocular melanoma include Caucasian race, light skin or eye color, dysplastic nevus syndrome, oculodermal melanocytosis, sun exposure and occupation exposure. The etiology for the most part is multifactorial or unknown.^[13] Most patients with ocular melanoma have symptoms such as blurry vision, loss of vision, floaters, visual field loss (as in our patients), growing dark spot on the iris or alteration in the size or shape of the pupil. Pain is a very rare symptom.^[13,14] Diagnosis is accomplished by a comprehensive eye exam done by an ophthalmologist.^[13]

The four radioactive isotopes most widely used in ocular oncology are iodine-125, palladium-103, cesium-131 and ruthenium-106. The radiation characteristics of these three isotopes are given in Table 3. ¹⁰⁶Ru plaques emit β -particles that travel a relatively short distance in tissue and cannot completely irradiate tumors more than 5-mm tall. Several authors have reported that local tumor control rates and need for enucleation appear to be inferior with ¹⁰⁶Ru compared to ¹²⁵I, especially when apical tumor height is considered.^[15-18] ¹²⁵I for choroidal melanoma was first described by Sealy in 1976.^[19] The major advantages of this radioisotope were the ability to protect the surrounding ocular structures, including the eyelids and lacrimal system, and the decrease in radiation exposure to the surgical staff.^[19,20] The excellent screening characteristics, good tissue penetration, low oxygen enhancement ratio and high relative biological effectiveness make ¹²⁵I an ideal source for local radiotherapy. Finger *et al.*^[21] have reported on the use of ¹⁰³Pd in the United States to treat choroidal melanomas. The seeds are the same size and thus can be used in the same carrier plaque as ¹²⁵I. Cesium-131 is an X-ray emitter (29 keV to 34 keV) with a half-life ~9.7 days that can also be used as ¹²⁵I.^[22] Large scale production process to avail ¹⁰³Pd and ¹³¹Cs

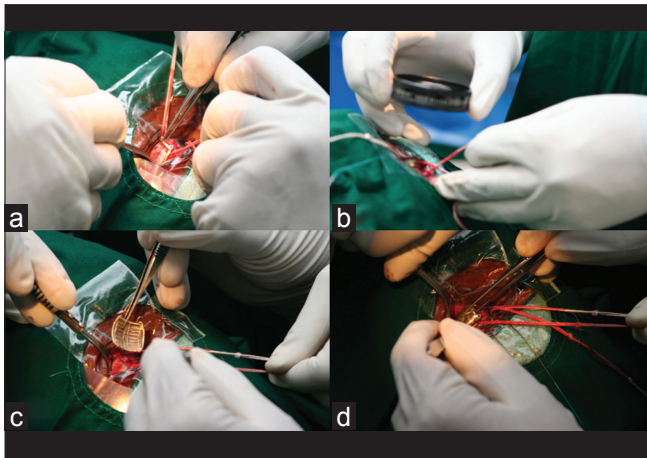


Figure 6: Intraoperative pictures showing brachytherapy procedure being done. (a) Dummy plaque (“cold plaque”) being inserted. (b) Localisation of the dummy plaque being confirmed with indirect ophthalmoscopy and scleral indentation (not shown). (c) “Hot plaque” with the radioactive I-125 seeds loaded shown just before insertion (after removing the cold plaque). (d) The hot plaque being inserted with the seeds facing the sclera



Figure 8: Above is the long bent tip of the diaphanoscope used for localisation of posterior tumors with transillumination through the sclera. This tip was thought to cause the complications illustrated in Figure 6. Below is the short straight tip used for transilluminating anterior tumors through the pupil

Table 2: Shows pre and postoperative visual acuity of choroidal melanoma cases

Visual acuity	No. of eyes pre-operative (n=7)	No. of eyes at last follow-up (n=7)
20/20 – 20/40	3	1
20/40 – 20/200	2	2
Less than 20/200	2	4

for seed brachytherapy application has not been established in India. The Indian pursuit of developing technology for ¹²⁵I brachytherapy sources was driven mainly by three considerations, namely, (a) well-established production of ¹²⁵I in several GBq quantities, (b) need to provide ¹²⁵I- brachytherapy

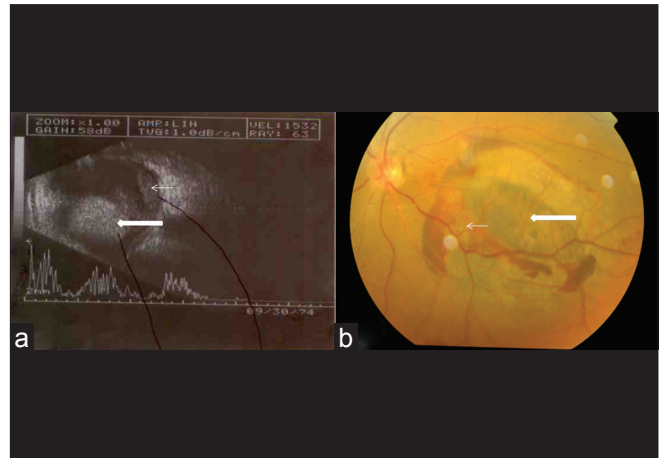


Figure 7: (a) Immediate postoperative B-scan image of case one showing large posterior melanoma (thick white arrow) along with hemorrhagic choroidal detachment (thin white arrow). (b) Immediate postoperative fundus image of case three showing intratumoral bleed (thin white arrow) and track of injury (thick white arrow) caused by the bend tip of diaphanoscope during intraoperative transillumination

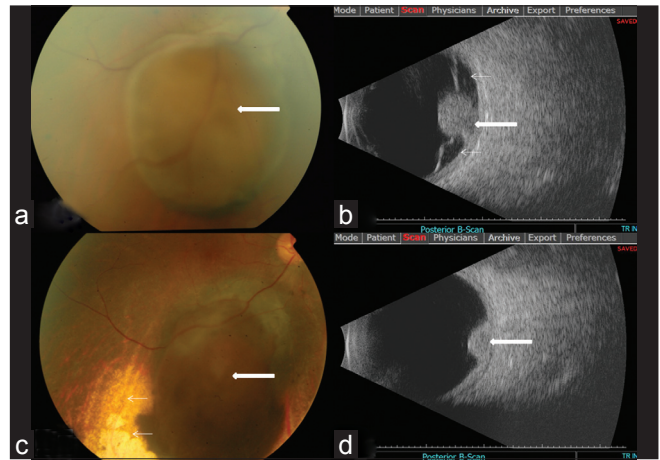


Figure 9: (a) Preoperative fundus picture of posterior choroidal melanoma situated in inferior quadrant of right eye (thick white arrow). (b) Preoperative B-scan picture showing mushroom-shaped melanoma (thick white arrow) along with surrounding exudative retinal detachment (thin white arrows). (c) Two-year post-brachytherapy fundus picture showing smaller condensed tumor (thick white arrow) along with surrounding choroidal degeneration (thin white arrows) secondary to radiation. (d) Two-year follow-up B-scan image showing a smaller dome shaped tumor (thick white arrow) with resolved retinal detachment

Table 3: Radiation characteristics of radionuclides used in prostate seed implantation

Isotope	Half life (days)	Specific Activity (TBq/g)	Mode of Decay (%)	Average Energy (keV) (%)
¹²⁵ I	60	650	EC (100)	28.5
¹⁰³ Pd	17	2763	EC (100)	21
¹⁰⁶ Ru	373.6	3.5 Ci/g	B γ	3541 (79.1) 911.9 (20.4) 621.9 (9.9) 1050.4 (1.6)
¹³¹ Cs	9	3808	EC (100)	30.4

EC: Electron capture

sources to meet the domestic needs and (c) help to promote the beneficial use of ^{125}I brachytherapy sources in the country.

For choroidal melanomas, the local treatment failure rate in COMS trial was 13%^[23] while it was 22.2% in our study. Two eyes of two patients were enucleated in our study. One had infiltration of the optic nerve head by the tumor. This eye received a dose rate of 0.44 Gy/hr, which was the lowest dose rate in our study. Although COMS trial recommended a dose rate between 0.43 and 1.05 Gy/hr, the American Brachytherapy Society recommends a dose rate between 0.6 and 1.05 Gy/hr, as dose rates of less than 0.6 Gy/h show lower tumor control rates.^[24] Thus, this low dose rate could be a factor for poor tumor control in this patient. Another eye was enucleated as along with radiation retinopathy there was a bulge from the central part of the tumor, at the site of injury by the sharp tip of the diaphanoscope. The five year all cause mortality was 19% in enucleation group and 18% for ^{125}I brachytherapy group, in the COMS trial. None of our cases had any metastasis till the last follow-up. However, in our study the sample size was much smaller and final follow-up shorter compared to COMS study. Of the seven eyes which were analyzed for visual acuity (VA), three (50%) had VA $\geq 20/40$ while two (28.6%) had VA $\leq 20/200$ preoperatively. At mean follow-up of 24 months only one (14.3%) had VA $\geq 20/40$ while four (57.1%) had VA $\leq 20/200$. In the COMS trial, 70% and 10% of eyes had VA $\geq 20/40$ and $\leq 20/200$, respectively. Three years after brachytherapy, only 31% and 41% of eyes had VA $\geq 20/40$ and $\leq 20/200$, respectively.^[25] Again our numbers and follow-up were smaller than COMS trial. Moreover in our study three cases were with large tumors that would be expected to fare worse with respect to visual acuity.

For retinoblastoma, Merchant *et al.*^[3] reported a preservation rate of 60% (15/25 eyes). In our study, of the three eyes of three babies, globe preservation rate was 50% (1/2 eyes). However, again our sample size is quite small. One child was lost for follow-up. Although we had only one case of VPT in our study, it was having an AD of 4 mm with a large exudative detachment which successfully resolved after brachytherapy. Thus we agree with Cohen *et al.*^[4] that I-125 plaque radiotherapy is an effective method of treating larger (>2.5-mm thickness) VPTs with extensive exudative retinal detachment.

Although efficacy of 'BARC ^{125}I Ocu-Prosta seeds' has been reported,^[26] it was based on a single case report, that too of a patient with choroidal metastasis whose long-term follow-up is questionable. Thus our study is the longest series of patients treated with these indigenous seeds and it shows results which are comparable to international standards. In conclusion, episcleral plaques brachytherapy using ^{125}I seeds is one of the modalities to control intraocular tumor. Despite the general axiom that ocular melanomas are radiation resistant, highly concentrated radiation therapy can be successful in promoting tumor regression. While there is still a long path to travel to find the ultimate cure for ocular melanoma, the results of this institutional retrospective study represent a significant step forward in the management of intraocular melanomas in India.

Acknowledgements

The authors wish to express their gratitude to Dr. P. Namperumalsamy, Chairman Emeritus, Aravind Eye Care System, Madurai; Dr. V. Anilkumar, Dean, Sri Ramakrishna Hospital, Coimbatore and Dr. M. R. A. Pillai, Head, Radiopharmaceuticals Division, Bhabha Atomic

Research Center (BARC) for their guidance, encouragement and continued support. The authors wish to thank Dr. Meera Venkatesh, former Head, Radiopharmaceuticals Division, BARC for her scientific and administrative supports and Board of Radiation and Isotope Technology (BRIT) authorities for timely shipment of source.

References

1. Biswas J, Kabra S, Krishnakumar S, Shanmugam MP. Clinical and histopathological characteristics of uveal melanoma in Asian Indians. A study of 103 patients. *Indian J Ophthalmol* 2004;52:41-4.
2. Collaborative Ocular Melanoma Study Group. The COMS randomized trial of iodine 125 brachytherapy for choroidal melanoma: V. Twelve-year mortality rates and prognostic factors: COMS report No. 28. *Arch Ophthalmol* 2006;124:1684-93.
3. Merchant TE, Gould CJ, Wilson MW, Hilton NE, Rodriguez-Galindo C, Haik BG. Episcleral plaque brachytherapy for retinoblastoma. *Pediatr Blood Cancer* 2004;43:134-139.
4. Cohen VM, Shields CL, Demirci H, Shields JA. Iodine I-125 plaque radiotherapy for vasoproliferative tumors of the retina in 30 eyes. *Arch Ophthalmol* 2008;126:1245-51.
5. Diener-West M, Earle JD, Fine SL, Hawkins BS, Moy CS, Reynolds SM, Schachat AP, *et al.* The COMS randomized trial of iodine 125 brachytherapy for choroidal melanoma, III: initial mortality findings: COMS report No. 18. *Arch Ophthalmol* 2001;119:969-82.
6. Collaborative Ocular Melanoma Study Group. Ten-year follow-up of fellow eyes of patients enrolled in Collaborative Ocular Melanoma Study randomized trials: COMS report No. 22. *Ophthalmology* 2004;111:966-76.
7. Saxena SK, Shanta A, Rajurkar Nilima S, Majali MA. Studies on the production and quality assurance of miniature ^{125}I radioactive sources suitable for treatment of ocular and prostate cancers. *Appl Radiat Isot* 2006;64:441-7.
8. Mathew C, Majali MA, Balakrishnan SA. A novel approach for the adsorption of ^{125}I on silver wire as matrix for brachytherapy for the treatment of eye and prostate cancer. *Appl Radiat Isot* 2002;57: 359-67.
9. Sharma SD, Basu M, Shanta A, Selvam TP, Tripathi UB, Bhatt BC. Dosimetry parameters of BARC OcuProsta I-125 seed source. *Australas Phys Eng Sci Med* 2005;28:14-20.
10. AERB SS-3 (Rev-1), Testing and Classification of Sealed Radioactive Sources. A publication of Atomic Energy Regulatory Board of India. 2001.
11. Straatsma BR. Golden Jubilee Lecture. Randomised clinical trials of choroidal melanoma treatment. *Indian J Ophthalmol* 2003;51:17-23.
12. Kreusel KM, Bechrakis N, Riese J, Krause L, Wachtlin J, Foerster MH. Combined brachytherapy and transpupillary thermotherapy for large choroidal melanoma: Tumor regression and early complications. *Graefes Arch Clin Exp Ophthalmol* 2006;244: 1575-80.
13. Inskip PD, Devesa SS, Fraumeni JF. Trends in the incidence of ocular melanoma in the United States, 1974-1998. *Cancer Causes Control* 2003;14:251-7.
14. Pandey M, Prakash O, Mathews A, Nayak N, Ramachandran K. Choroidal melanoma metastasizing to maxillofacial bones. *World J Surg Oncol* 2007;5:30.
15. Wilson MW, Hungerford JL. Comparison of episcleral plaque and proton beam radiation therapy for the treatment of choroidal melanoma. *Ophthalmology* 1999;106:1579-87.
16. Lommatzsch PK, Werschnik C, Schuster E. Long-term follow-up of Ru-106/Rh-106 brachytherapy for posterior uveal melanoma. *Graefes Arch Clin Exp Ophthalmol* 2000;238:129-37.
17. Rouberol F, Roy P, Kodjikian L, Gerard JP, Jean-Louis B, Grange JD. Survival, anatomic, and functional long-term results in choroidal and ciliary body melanoma after ruthenium brachytherapy (15

- years' experience with beta-rays). *Am J Ophthalmol* 2004;137:893-900.
18. Bergman L, Nilsson B, Lundell G, Lundell M, Seregard S. Ruthenium brachytherapy for uveal melanoma, 1979-2003: survival and functional outcomes in the Swedish population. *Ophthalmology* 2005;112:834-40.
 19. Sealy R, Le Roux PLM, Rapley F, Hering E, Shackleton D, Sevel D. The treatment of ophthalmic tumours with lowenergy sources. *Br J Radiol* 1976;49:551-4.
 20. Quivey J, Takamiya R, Char D. Uveal melanoma. In: Leibel SA, Phillips TL, editors. *Textbook of Radiation Oncology*. 2nd ed. Philadelphia: Saunders; 2004. p.1443-661.
 21. Finger PT, Berson A, Ng T, Szechter A. Palladium-103 plaque radiotherapy for choroidal melanoma: An 11-year study. *Int J Radiat Oncol Biol Phys* 2002;54:1438-45.
 22. Armpilia CI, Dale RG, Coles IP, Jones B, Antipas V. The Determination of Radiobiologically Optimized Half-lives for Radionuclides Used in Permanent Brachytherapy Implants. *Int J Radiat Oncol Biol Phys* 2003;55:378-85.
 23. Jampol LM, Moy CS, Murray TG, Reynolds SM, Albert DM, Schachat AP, *et al.* The COMS randomized trial of iodine 125 brachytherapy for choroidal melanoma. IV. Local treatment failure and enucleation in the first 5 years after brachytherapy. COMS report no. 19. *Ophthalmology* 2002;109:2197-206.
 24. Nag S, Quivey JM, Earle JD, Followill D, Fontanesi J, Finger PT. The American Brachytherapy Society recommendations for brachytherapy of uveal melanomas. *Int J Radiat Oncol Biol Phys* 2003;56:544-55.
 25. Melia BM, Abramson DH, Albert DM, Boldt HC, Earle JD, Hanson WF, *et al.* Collaborative ocular melanoma study (COMS) randomized trial of I-125 brachytherapy for medium choroidal melanoma. I. Visual acuity after 3 years COMS report no. 16. *Ophthalmology* 2001;108:348-66.
 26. Chaudhari S, Deshpande S, Anand V, De S, Saxena S, Dash A, *et al.* Dosimetry and treatment planning of occu-prosta I-125 seeds for intraocular lesions. *J Med Phys* 2008;33:14-8.

Cite this article as: Shah PK, Narendran V, Selvaraj U, Guhan P, Saxena SK, Dash A, *et al.* Episcleral plaque brachytherapy using 'BARC I-125 Ocu-Prosta seeds' in the treatment of intraocular tumors: A single-institution experience in India. *Indian J Ophthalmol* 2012;60:289-95.

Source of Support: Nil. **Conflict of Interest:** None declared.

Staying in touch with the journal

1) Table of Contents (TOC) email alert

Receive an email alert containing the TOC when a new complete issue of the journal is made available online. To register for TOC alerts go to www.ijo.in/signup.asp.

2) RSS feeds

Really Simple Syndication (RSS) helps you to get alerts on new publication right on your desktop without going to the journal's website. You need a software (e.g. RSSReader, Feed Demon, FeedReader, My Yahoo!, NewsGator and NewzCrawler) to get advantage of this tool. RSS feeds can also be read through FireFox or Microsoft Outlook 2007. Once any of these small (and mostly free) software is installed, add www.ijo.in/rssfeed.asp as one of the feeds.