

Received: 2020.02.07

Accepted: 2020.06.09

Available online: 2020.06.20

Published: 2020.08.06

# Use of Adjunctive Therapy to Achieve Preoperative Euthyroidism in Graves' Disease: A Case Report

## Authors' Contribution:

Study Design A  
Data Collection B  
Statistical Analysis C  
Data Interpretation D  
Manuscript Preparation E  
Literature Search F  
Funds Collection G

ABDEF 1 **Noor Abdulghani Alghanim**  
ABDEF 1 **Shymaa M. Alkahtani**  
AEF 1 **Fatimah S. Assari**  
AEF 1 **Sarah W. Alnoaier**  
AEF 1 **Reham M. Bader**  
AEF 1 **Isra E. Elmahi**  
ABEF 1 **Mariam M. Hendaz**  
AEF 2 **Amal Alhefdhi**

1 College of Medicine, Alfaisal University, Riyadh, Saudi Arabia

2 Breast and Endocrine Surgery, King Faisal Specialist Hospital and Research Center, Riyadh, Saudi Arabia

**Corresponding Author:** Noor Abdulghani Alghanim, e-mail: [nalghanim@alfaisal.edu](mailto:nalghanim@alfaisal.edu)  
**Conflict of interest:** None declared

**Patient:** Male, 37-year-old  
**Final Diagnosis:** Graves' disease  
**Symptoms:** Difficulty breathing • voice change • weight gain  
**Medication:** —  
**Clinical Procedure:** Total thyroidectomy  
**Specialty:** Surgery

**Objective:** Unusual clinical course

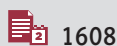
**Background:** Graves' disease is an autoimmune disease of the thyroid gland and it is considered the most common cause of hyperthyroidism. It is characterized by particular eye manifestations, skin changes, and pretibial myxedema in addition to the signs and symptoms of hyperthyroidism. Graves' disease can be diagnosed based on clinical presentation and low thyroid stimulating hormone (TSH) and elevated free T4 (FT4) levels. Presence of TSH receptor antibody (TRAb) in the serum confirms the diagnosis of Graves' disease. Imaging studies like radioactive iodine scan will show a high and diffuse uptake. Graves' disease can be managed with three different treatment modalities: antithyroid medications, radioactive iodine, or surgical removal of the thyroid gland. Whenever surgery is indicated, careful preoperative management to achieve euthyroidism is needed to optimize the surgical outcome.

**Case Report:** This is a case of a 37-year-old Saudi male known to have Graves' disease for 2 years who presented to the endocrine surgery clinic with neck swelling, difficulty breathing, and change in voice. After multiple attempts to control his fluctuating thyroid levels, the team eventually managed to achieve a euthyroid state in the patient with the addition of saturated solution of potassium iodide (SSKI), and thus rendering him eligible for urgent surgery.

**Conclusions:** We report this case to show that SSKI can be used as adjunctive therapy to achieve a preoperative euthyroid state in refractory Graves' disease.

**MeSH Keywords:** Graves' Disease • Hyperthyroidism • Hypothyroidism

**Full-text PDF:** <https://www.amjcaserep.com/abstract/index/idArt/923342>



1608



4



28

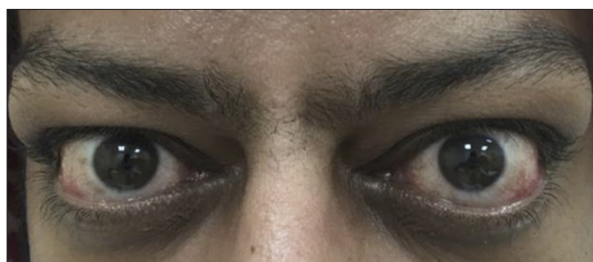

## Background

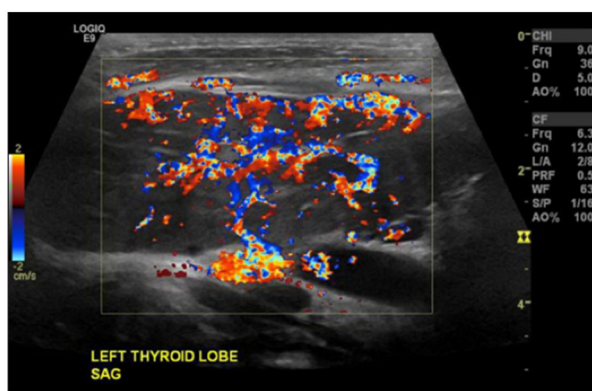
Graves' disease is an autoimmune disease affecting the thyroid gland [1]. It is characterized by presence of autoantibodies that target thyroid stimulating hormone (TSH) receptors, causing stimulation of the thyroid gland [2]. Patients with Graves' disease usually present with signs and symptoms of hyperthyroidism that include fatigue, heat intolerance, sweating, weight loss, palpitations, and tremor along with particular eye manifestations and sometimes skin changes [3]. It is considered the most common cause of hyperthyroidism, accounting for approximately 60% to 80% of cases [1]. The diagnosis of Graves' disease can be straightforward in the presence of typical signs and symptoms along with low thyroid stimulating hormone (TSH) and elevated free T4 (FT4) levels [4]. Measuring TSH receptor antibody (TRAb) is helpful for confirming the diagnosis, as it is present in 90% of patients. If the cause of hyperthyroidism remains uncertain, a radioactive iodine uptake scan should be considered. The scan helps to distinguish Graves' disease from thyroiditis and other causes of hyperthyroidism. In Graves' disease, iodine uptake is increased and diffuse [5]. Treatments of choice for hyperthyroidism include antithyroid medications, radioactive iodine, and surgical approaches [4]. The success rate for antithyroid medications is almost 50%, compared to 90% and 95% with radioactive iodine and surgery, respectively [5–7]. Whenever surgery is indicated, careful preoperative management to achieve euthyroidism is needed to optimize the surgical outcome. In most cases, a euthyroid state is reached within a few weeks of conventional antithyroid medications; however, in certain conditions, as in drug malabsorption and in cases of predominantly high T3 levels, it cannot be easily achieved and adjunctive therapy should be considered [8,9].

## Case Report

A 37-year-old Saudi male presented to the endocrine clinic with palpitation, sweating, and weight loss. He was diagnosed with Graves' disease and treated with methimazole (20 mg orally, twice daily). When symptoms of hypothyroidism developed, the dose was decreased to (10 mg orally, twice daily). The patient was referred to the endocrine surgery clinic complaining of obstructive symptoms in the form of difficulty breathing and voice changes due to neck swelling, weight gain of 20 kg during the last month, and easy fatigability, along with the typical eye manifestations of proptosis and periorbital edema (Figure 1). He was otherwise healthy and the rest of his history was unremarkable. On physical examination, the patient had a hoarse voice, fine tremor in both hands, and his skin was warm with diaphoresis. There was proptosis, lid retraction, and diplopia involving both eyes. Neck examination showed a diffuse, tender swelling with bilateral lumps measuring 33 cm on the right and 22 cm on the left along with positive Pemberton sign. The rest



**Figure 1.** Typical eye manifestations of Graves' disease; proptosis and periorbital edema.

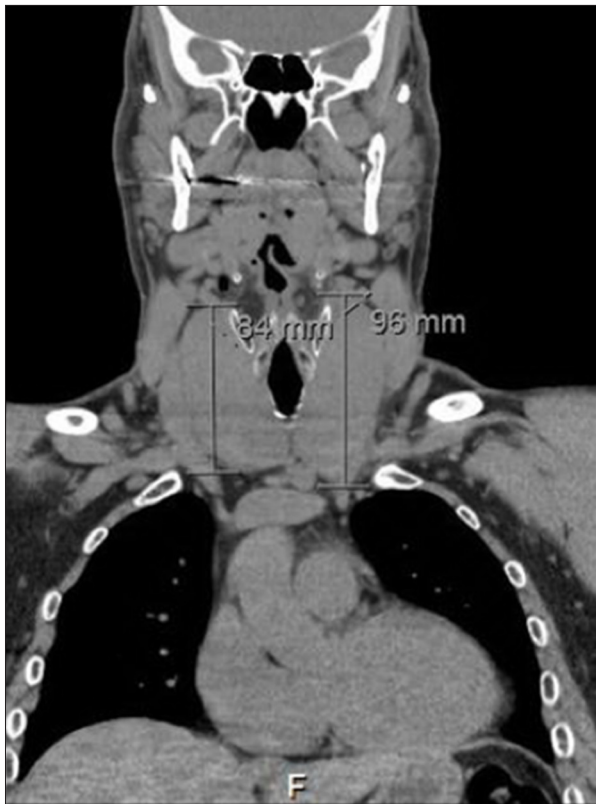

**Figure 2.** Ultrasound showing an enlarged and hypervascular left thyroid lobe with no suspicious nodules.

of the examination was unremarkable except for right scrotal swelling and delayed deep tendon reflexes.

The patient then underwent ultrasound (US) of the thyroid, which showed an enlarged and hypervascular gland compatible with Graves' disease with no suspicious nodules (Figure 2). A computed tomography (CT) scan was done, which revealed homogeneous, diffuse swelling of bilateral thyroid lobes with no retrosternal extension along with bilateral proptosis (Figures 3, 4). Therefore, the patient was admitted to achieve a euthyroid state before proceeding for a total thyroidectomy. The patient was managed by a multidisciplinary team with the goal of clearing him for surgery. During the patient's 3-week hospital stay, the dosage of methimazole was continuously altered because serial thyroid function tests showed a change from hyperthyroid to hypothyroid status. His TSH and FT4 levels ranged from 0.045 mU/L to 44 mU/L and 0.4 pmol/L to 48.2 pmol/L, respectively. A few days after administration of saturated solution of potassium iodide (SSKI) was initiated (3 drops, three times daily), the patient achieved a euthyroid state with TSH 0.054 mU/L and FT4 19.7 pmol/L, so urgent surgery was performed.

Intraoperatively, the patient's thyroid gland was found to be enlarged and vascular, with each lobe measuring approximately 8 to 10 cm. The gland was excised bilaterally along with the pyramidal lobe because it was also enlarged. The postoperative



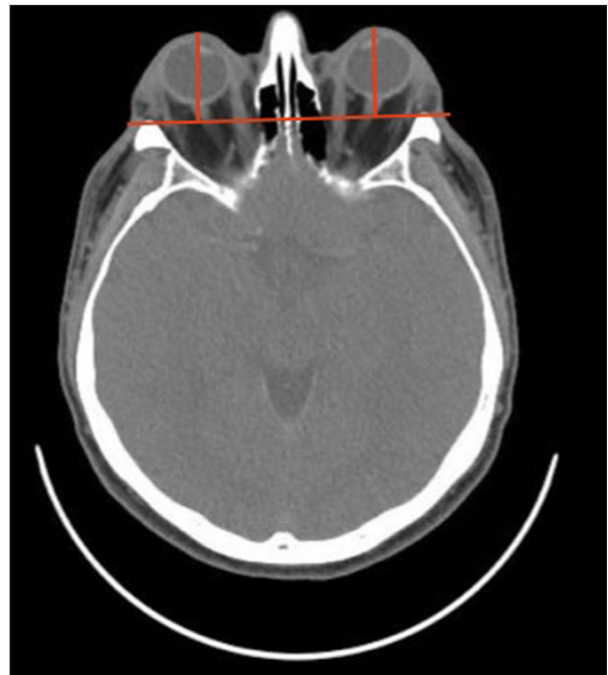**Figure 3.** CT scan showing diffuse enlargement of the thyroid with no retrosternal extension or invasion of surrounding structures.

pathology report showed diffuse hyperplasia consistent with Graves' disease with no evidence of malignancy. After the surgery, the patient was moved to the Intensive Care Unit (ICU), where he was assessed and found to be stable with no signs and symptoms of thyrotoxicosis or hypocalcemia. Three days later, the patient was discharged with orders to take calcium carbonate (600 mg orally, three times daily) for 30 days, acetaminophen (650 mg orally, as needed) for 10 days, levothyroxine (125 mcg orally, daily) for 120 days, and calcitriol (0.5 mcg orally, daily) for 30 days.

When the patient presented to the clinic 3 weeks later for follow-up, he was found to be in good health with no active complaints. He had lost weight and there were no voice changes. His eye manifestations had decreased but not disappeared completely. Laboratory results showed a euthyroid state with a normal calcium level.

## Discussion

Graves' disease can be managed with three different treatment modalities: antithyroid medications, radioactive iodine, or surgical removal of the thyroid gland [4]. The success rate



**Figure 4.** CT scan demonstrating that the distance from the anterior margin of the globe to the interzygomatic line exceeds 21 mm, indicating significant bilateral proptosis.

for antithyroid medications is almost 50%, compared to 90% with radioactive iodine therapy [6,7]. Surgical approaches are considered the most successful and definitive treatment, with total thyroidectomy being the preferred choice [8]. A review of the literature done in 2013 showed that total thyroidectomy is 3.44 times more successful than radioactive iodine therapy [10]. Another study concluded that the highest rates of long-term remission, reaching up to 95%, are achieved with surgery [5]. Nonetheless, there is no clear consensus on the best treatment modality for Graves' disease and the choice should be individualized. Choice of modality depends on several factors, including age, comorbidities, size of the goiter, and severity of thyrotoxicosis [4]. Surgery is recommended in certain conditions, for example, in patients with compression symptoms due to presence of a large goiter, those with low radioactive iodine uptake, suspected thyroid cancer, moderate to severe Graves' ophthalmopathy, and patients who cannot tolerate antithyroid medications [4,11]. Whenever surgery is selected, careful preoperative management is needed to optimize the surgical outcome. Preparing a patient with antithyroid medications is recommended by the American Thyroid Association (ATA) to achieve a euthyroid state and thus lower risk of intraoperative complications [8].

In most cases, a euthyroid state is achieved within 6 weeks of antithyroid treatment. In certain conditions, however, that is difficult to achieve with conventional therapy and patients

should be prepared for surgery using adjunctive therapy [8]. Resistance to conventional antithyroid medications is not commonly encountered in clinical practice; however, there are few reported cases addressing the use of adjunctive therapy to rapidly restore normal thyroid function [12]. SSKI has been used for many years in management of Graves' disease [13,14]. ATA hyperthyroidism management guidelines recommend preoperative administration of potassium iodide solutions (KI) for thyroidectomy [15]. The main rationale of using KI preoperatively is to decrease vascularity and blood loss during the surgery; however, a few studies suggest that, when combined with antithyroid medications, it can decrease thyroid hormone levels [12–16]. In 2017, a retrospective study showed the effectiveness of adding KI as a rescue preoperative management in uncontrolled Graves' disease. In 27 patients in the study, use of KI was safe and effective as preoperative preparation for total thyroidectomy [17].

Cholestyramine was first used to treat Graves' disease in 2016 in Korea [18]. The patient in that study was a 22-year-old female with severe refractory Graves' disease who was initially managed with a maximal dose of methimazole and propranolol, with no improvement. She was admitted and treated with methimazole, propranolol, hydrocortisone, and KI. The next day cholestyramine was added, which resulted in a rapid decline of FT4. Ten days after admission, the patient underwent total thyroidectomy [18]. Several cases of refractory Graves' disease were reported in the literature between 2008 to 2018. In all these cases, the patients failed to achieve a preoperative euthyroid state with conventional antithyroid medications. Within 1 to 2 weeks of administration of cholestyramine as adjunctive therapy, they became euthyroid. Two studies were published in 1996 and 2005 to evaluate the effectiveness of adding cholestyramine to the conventional treatment regimen in cases of resistant Graves' disease. The conclusion from these reports is that cholestyramine can be used to safely and rapidly achieve preoperative euthyroidism [9,12,19–21].

## References:

1. Pokhrel B, Bhusal K: Graves disease: In: StatPearls. Treasure Island (FL): StatPearls Publishing, 2020
2. Barbesino G, Tomer Y: Clinical review: Clinical utility of TSH receptor antibodies. *J Clin Endocrinol Metab*, 2013; 98(6): 2247–55
3. DeGroot LJ: Graves' disease and the manifestations of thyrotoxicosis. In: Feingold KR, Anawalt B, Boyce A et al. (eds.), *Endotext*. South Dartmouth (MA): MDText.com, Inc.; 2000
4. Subekti I, Pramono LA: Current diagnosis and management of Graves' disease. *Acta Med Indones*, 2018; 50(2): 177–82
5. Girgis CM, Champion BL, Wall JR: Current concepts in Graves' disease. *Ther Adv Endocrinol Metab*, 2011; 2(3): 135–44
6. Wiersinga WM: Graves' disease: Can it be cured? *Endocrinol Metab (Seoul)*, 2019; 34(1): 29–38
7. Wong KK, Shulkin BL, Gross MD, Avram AM: Efficacy of radioactive iodine treatment of Graves' hyperthyroidism using a single calculated 131 I dose. *Clin Diabetes Endocrinol*, 2018; 4: 20
8. Piantanida E: Preoperative management in patients with Graves' disease. *Gland Surg*, 2017; 6(5): 476–81
9. Yang Y, Hwang S, Kim M et al: Refractory Graves' disease successfully cured by adjunctive cholestyramine and subsequent total thyroidectomy. *Endocrinol Metab (Seoul)*, 2015; 30(4): 620–25
10. Genovese BM, Noureldine SI, Gleeson EM et al: What is the best definitive treatment for Graves' disease? A systematic review of the existing literature. *Ann Surg Oncol*, 2013; 20(2): 660–67
11. Bartalena L: Diagnosis and management of Graves disease: A global overview. *Nat Rev Endocrinol*, 2013; 9(12): 724–34
12. Sebastian-Ochoa A, Quesada-Charneco M, Fernandez-Garcia D et al: Dramatic response to cholestyramine in a patient with Graves' disease resistant to conventional therapy. *Thyroid*, 2008; 18(10): 1115–17
13. Calissendorff J, Falhammar H: Lugol's solution and other iodide preparations: Perspectives and research directions in Graves' disease. *Endocrine*, 2017; 58(3): 467–73

Moreover, the largest case series of patients with severe thyrotoxic Graves' disease was published in 2004. The study involved 17 patients who reached euthyroidism after 7 days of an intensive treatment regimen. The authors concluded that patients with severe hyperthyroid Graves' disease can rapidly achieve preoperative euthyroidism with simultaneous administration of iopanoic acid, dexamethasone, beta-blocker, and methimazole or propylthiouracil [22]. Another case of Graves' disease resistant to antithyroid medications was reported in 2004. The patient was promptly managed preoperatively with both iopanoic acid and dexamethasone [23].

Three scientific papers on resistant thyrotoxicosis due to Graves' disease were published between 1996 to 2018. In all cases, a euthyroid state could not be reached with the usual antithyroid medications, and the patients received prednisolone and/or lithium, which resulted in complete normalization of thyroid function before surgery [24–26]. Furthermore, several refractory cases of Graves' disease unresponsive to usual preoperative management were reported in 2009 and 2017. The patients were successfully prepared for surgery with use of plasmapheresis [27,28].

## Conclusions

Preoperative management of Graves' disease can sometimes be challenging. There have been many attempts to achieve a euthyroid state with different approaches. In the patient described here, Graves' disease was resistant to conventional antithyroid medication for establishment of preoperative euthyroidism. Our experience demonstrates that SSKI can be used in a case like ours to not only decrease vascularity of the thyroid gland but also as adjunctive therapy to achieve preoperative euthyroidism.

14. Naafs MA: Lugol's solution in thyroid surgery: A mini-review. *Global Journal of Otolaryngology*, 2017; 11(4): 555817
15. Muldoon BT, Mai VQ, Burch HB: Management of Graves' disease: An overview and comparison of clinical practice guidelines with actual practice trends. *Endocrinol Metab Clin North Am*, 2014; 43(2): 495–516
16. Burch HB, Cooper DS: Management of Graves disease: A review [published erratum appears in *JAMA* 2015;314(23): 2544–54]. *JAMA*, 2016; 315(6): 614
17. Calissendorff J, Falhammar H: Rescue pre-operative treatment with Lugol's solution in uncontrolled Graves' disease. *Endocr Connect*, 2017; 6(4): 200–5
18. Chae SB, Kim ES, Lee YI, Min BR: A case of methimazole-resistant severe Graves' disease: Dramatic response to cholestyramine. *Int J Thyroidol*, 2016; 9(2): 190–94
19. Kadem SG: Resistant hyperthyroidism, responses dramatically to adjunctive oral cholestyramine. *Jourbnal of Diabetes and Endorinology*, 2018; 4(1): 14–16
20. Mercado M, Mendoza-Zubieta V, Bautista-Osorio R, Espinoza-De Los Monteros AL: Treatment of hyperthyroidism with a combination of methimazole and cholestyramine. *J Clin Endocrinol Metab*, 1996; 81(9): 3191–93
21. Tsai WC, Pei D, Wang TF et al: The effect of combination therapy with propylthiouracil and cholestyramine in the treatment of Graves' hyperthyroidism. *Clin Endocrinol (Oxf)*, 2005; 62(5): 521–24
22. Panzer C, Beazley R, Braverman L: Rapid preoperative preparation for severe hyperthyroid Graves' disease. *J Clin Endocrinol Metab*, 2004; 89(5): 2142–44
23. Pandey CK, Raza M, Dhiraaj S et al: Rapid preparation of severe uncontrolled thyrotoxicosis due to Graves' disease with Iopanoic acid – a case report. *Can J Anaesth*, 2004; 51(1): 38–40
24. Saleem T, Sheikh A, Masood Q: Resistant thyrotoxicosis in a patient with Graves disease: A case report. *J Thyroid Res*, 2011; 2011: 649084
25. Nair GC, C Babu MJ, Menon R, Jacob P: Preoperative preparation of hyperthyroidism for thyroidectomy – role of supersaturated iodine and lithium carbonate. *Indian J Endocrinol Metab*, 2018; 22(3): 392–96
26. Jude EB, Dale J, Kumar S, Dodson PM: Treatment of thyrotoxicosis resistant to carbimazole with corticosteroids. *Postgrad Med J*, 1996; 72(850): 489–91
27. Candoni A, De Marchi F, Vescini F et al: Graves' disease thyrotoxicosis and propylthiouracil related agranulocytosis successfully treated with therapeutic plasma exchange and G-CSF followed by total thyroidectomy. *Mediterr J Hematol Infect Dis*, 2017; 9(1): 2017058
28. Ezer A, Caliskan K, Parlakgumus A et al: Preoperative therapeutic plasma exchange in patients with thyrotoxicosis. *J Clin Apher*, 2009; 24(3): 111–14