

# Lost Venous Access Guidewire Identified by Its Late Cervical Protrusion: Case Report

Ahmed Osailan, MD, Mathilde De Queiroz Siqueira, MD, Lionel Bouvet, MD, PhD, and Dominique Chassard, MD, PhD

We report a pediatric patient who underwent a central venous catheter (CVC) insertion and presented with a sudden protrusion of a guidewire from the neck 26 months later. The guidewire was extracted via femoral venotomy. A 5-cm portion of the guidewire adhering to the superior vena cava wall was left in place. We recommend always using a CVC checklist, inspecting the guidewire before and after insertion, and carefully examining the postinsertion radiographs. This checklist should be mandatory with every CVC insertion, including the perioperative period. (A&A Practice. 2022;16:e01565.)

## GLOSSARY

**ASA** = American Society of Anesthesiologists; **CLABSI** = central line-associated bloodstream infection; **CT** = computed tomography; **CVC** = central venous catheter; **ICU** = intensive care unit; **MAGIC** = Michigan Appropriateness Guide for Intravenous Catheters; **PACS** = Picture Archiving and Communication System; **TTE** = trans thoracic echography

Complications associated with central venous catheters (CVCs) are infections, failure to place the catheter, arterial puncture, improper catheter positioning, pneumothorax, hematoma, and hemothorax.<sup>1</sup> Intravascular loss of a guidewire constitutes an extremely rare complication that is usually recognized immediately.<sup>2-6</sup> Sometimes, the loss of a guidewire is noticed incidentally during a routine radiograph or computed tomography (CT) examination performed several weeks or months after the procedure.<sup>5,6</sup>

The discovery of a lost guidewire after it protrudes from the body is rare. A previous case report reported a guidewire emerging from the skin near the knee of a patient who had undergone a right femoral CVC insertion 2 years earlier.<sup>7</sup> Another study described a female patient complaining about the protrusion of the end of a metallic wire from the nail bed of the left big toe following a left femoral vein catheterization performed months earlier.<sup>8</sup>

Herein, we report a case of guidewire migration from a right jugular vein catheterization, complicated by a protrusion from the neck, 26 months after its insertion.

The patient's family provided written consent for the publication of this case report.

From the Service d'Anesthésie-Réanimation, Hôpital Femme Mère Enfant, Bron Cedex, France.

Accepted for publication December 17, 2021.

Funding: None.

The authors declare no conflicts of interest.

Address correspondence to Dominique Chassard, MD, PhD, Service d'Anesthésie-Réanimation, Hôpital Femme Mère Enfant 59, Blvd, Pinel 69677 Bron Cedex, France. Address e-mail to dominique.chassard@chu-lyon.fr.

Copyright © 2022 International Anesthesia Research Society. This is an open-access article distributed under the terms of the Creative Commons Attribution-Non Commercial-No Derivatives License 4.0 (CCBY-NC-ND), where it is permissible to download and share the work provided it is properly cited. The work cannot be changed in any way or used commercially without permission from the journal.

DOI: 10.1213/XAA.0000000000001565

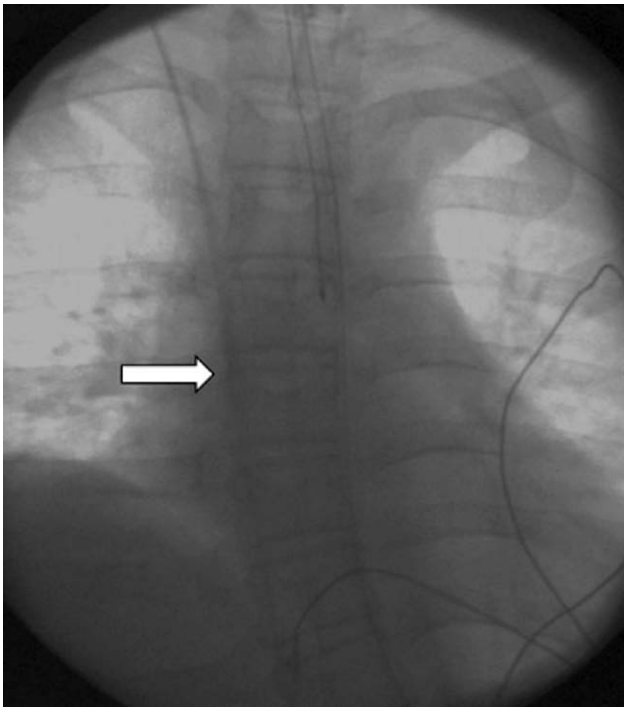
## CASE DESCRIPTION

A 13-year-old boy, 160-cm tall and 44-kg weight, with muscular dystrophy and progressive ventilatory insufficiency underwent vertebral arthrodesis to treat scoliosis.

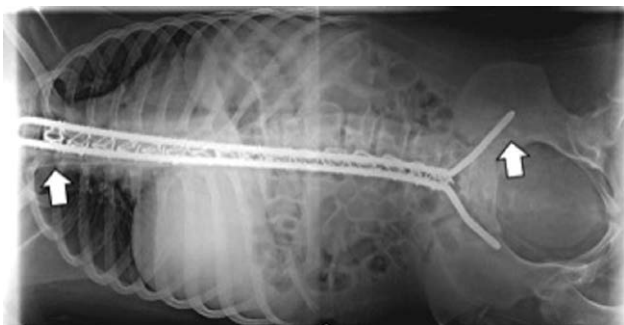A senior anesthesiologist, familiar with central venous catheterization, inserted a CVC via the right jugular vein at the beginning of the surgical procedure because of the risk of hemorrhage associated with vertebral arthrodesis. Venous puncture was performed using ultrasound. A perioperative CVC checklist was not completed because it was not in use in our institution in 2018. No problem with the catheterization procedure was recorded, and fluoroscopy was performed before surgery to check the position of the tip of the catheter (Figure 1). At the end of the surgical procedure, the patient recovered in the postoperative recovery room for 2 hours and was then transferred to the pediatric orthopedic ward. A postoperative chest radiograph was performed on arrival to the surgery ward and reviewed by the surgeon (Figure 2) who did not note the guidewire. The postoperative course was uncomplicated, and the patient was discharged from the hospital 9 days after surgery.

Twenty-six months after the initial orthopedic surgical procedure and after several surgical follow-up consultations during which several radiographs were performed and reviewed by the surgeon (Figure 3), the patient complained of a 2-day history of posterior cervical pain radiating to the right arm. A few days later, the patient came to the emergency department complaining about a metallic object protruding from his neck, the external part was about 10-cm long (Figure 4). A CT scan was immediately performed and revealed the guidewire that has been inserted during the surgical procedure 26 months earlier. The wire extended from the right jugular vein to the right femoral vein. No sign of hematoma or vascular injury was observed.

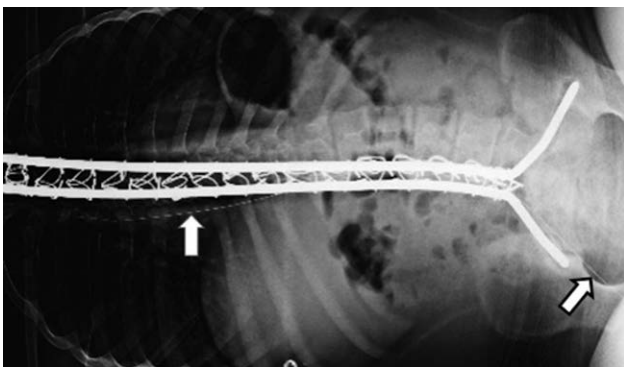
A multidisciplinary team (a vascular surgeon, 2 anesthesiologists, and an interventional radiologist) was assembled and decided to immediately remove the wire under



**Figure 1.** Fluoroscopy at the end of the CVC procedure. The guidewire is not seen. CVC indicates central venous catheter.

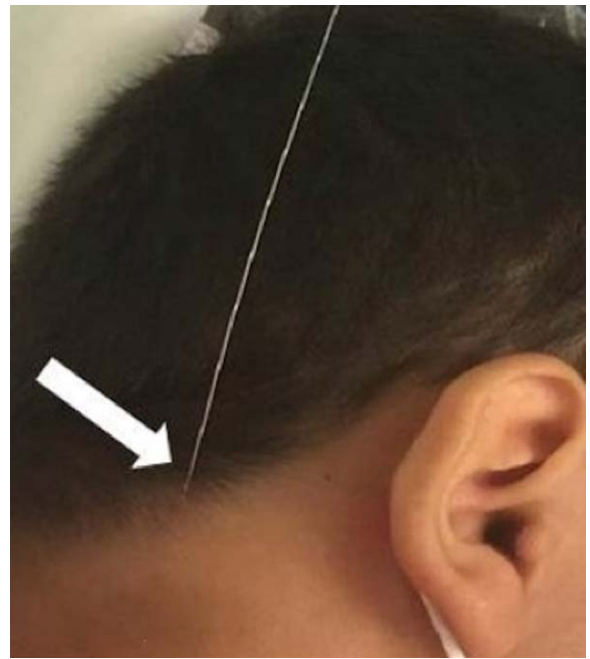


**Figure 2.** Postoperative day 1 radiograph. The guidewire extends from the superior vena cava to the left femoral vein.



**Figure 3.** Postoperative radiograph 7 mo after the procedure. Note that the guidewire has moved into the right femoral vein.

fluoroscopic guidance by grasping the exterior part at its exit point. After the procedure, a radiograph showed that a part of the guidewire remained in place (from the inferior vena cava to the femoral vein).



**Figure 4.** Neck protrusion of the lost guidewire.

Another surgical procedure was scheduled for 3 weeks later to remove the rest of the guidewire through a femoral venotomy under local anesthesia, hypnosis, and light sedation (propofol 40mg and remifentanyl 233 µg). An incision was made anterior to the femoral canal, the femoral vein was exposed, the guidewire was removed under fluoroscopy, and the procedure lasted 3 hours. There was resistance during retraction of the wire and the guidewire broke.

A postoperative radiograph revealed approximately 5cm of metallic guidewire remaining in the superior vena cava. The decision was made not to remove this part, and the patient received 3 weeks of prophylactic anticoagulation (enoxaparin 3000 Units S/C) but no long-term anticoagulation was planned. The patient has not returned to the hospital since the last surgical procedure. Phone contact was made in June 2021 (1 year after catheter removal) and no complications related to the remaining part of the guidewire were reported. Because of the risk of cardiac dysfunction with Duchenne disease, an electrocardiogram and a transthoracic echocardiogram were done in August 2021 showing no cardiac dysfunctions, no cardiac thrombosis, and no guidewire within the heart. The remaining guidewire was still seen in the vena cava on a thoracic radiograph done in August 2021 and was not seen at the same date in cardiac cavities during the trans thoracic echography (TTE; no position change since the last surgical procedure).

## DISCUSSION

Previous case reports have described broken and lost guidewires after CVC insertions using the Seldinger technique.<sup>2-8</sup> A lost guidewire is a rare complication, while the rate of central line-associated bloodstream infections (CLABSIs) is more frequent (0.5–4.5 CLABSI per 1000 central line days). Because of the high prevalence, cost, and risks of CLABSI, several studies have tried to

decrease CLABSI occurrence by both promoting the culture of patient safety and improving CVC procedure techniques. A number of studies that include a large number of patients have shown reductions in CLABSI without promoting a safety culture, but mainly through improvements in the standardization of the procedures.<sup>9</sup> Implementation of the Michigan Appropriateness Guide for Intravenous Catheters (MAGIC), a tool developed to decrease the inappropriate use of peripherally inserted central catheters, has reduced complications of infection and thrombosis to a modest extent.<sup>10</sup> Promoting safety culture is essential to reduce complications. For rare complications associated with technical procedures, such as the loss of a guidewire, physicians must prioritize the standardization of these procedures. Checklists constitute an important tool to achieve this goal, and the American Society of Anesthesiologists (ASA) Task Force on central venous access has recommended their use since 2012.<sup>11</sup> They recommend performing a postprocedure chest radiograph even if fluoroscopy was used during the procedure.

Immediately after placement of the CVC in our patient in the operating room, fluoroscopy was used to confirm the catheter tip position but the guidewire was not visible. The guidewire had apparently already migrated. Hence, our case report showed that the ASA 2012 recommendation was not sufficient to prevent the loss of a guidewire. The ASA task force has updated these recommendations in 2020.<sup>12</sup> They now recommend confirming the presence of the removed wire in the procedural field at the end of the procedure. If the complete guidewire cannot be found in the procedural field, a radiograph must be done to identify the guidewire. This has now been added to our CVC procedure checklist with an additional notation "chest radiograph checked" requiring confirmation. Our case also illustrates how important it is that the person placing the CVC reviews a radiograph confirming accurate placement.

Accurate radiograph review and reporting are essential requirements for patient safety. A UK survey investigated intensive care unit (ICU) radiology reporting and showed that <50% of the radiologic reports were by radiologists.<sup>13</sup> In our case, several postprocedure chest and total body radiographs were reviewed by the orthopedic surgeon who never identified the lost guidewire. This physician is not well trained to detect CVC complications. He probably focused his analysis and attention on the osteosynthesis material and the scoliosis correction. Despite the introduction of the Picture Archiving and Communication System (PACS) in our hospital, some units rely on radiologists for reporting, whereas in other units, ICU clinicians, anesthesiologists, and surgeons are solely responsible for chest radiograph reporting. This is a concern because radiologists frequently highlight abnormalities that require active management and are missed by other physicians. Unfortunately, the workload of radiologists in our hospital (as in many countries) does not allow these specialists to read all radiographs.

Why the guideline was not removed from our patient after placement of the CVC remains unknown. Inattention or distraction of the senior anesthesiologist might be the cause. Several studies have revealed that

work interruptions are thought to be a prominent factor in medical errors. Promotion of a safety culture for CVC procedures must focus on eliminating distractions that can threaten patient safety.

Thirteen cases of retained guidewires were reported in the UK Never Events database in 2019.<sup>14</sup> Despite the introduction of safety measures, including checklists, retained guidewires still occur because all preventable measures rely on the operator remembering to perform the safety check. Ultimately, CVC design equipment changes have been proposed to prevent guidewire retention.<sup>15</sup>

In conclusion, we identified several pitfalls explaining the late discovery of this lost guidewire, namely the absence of a perioperative CVC checklist, the lack of postprocedure chest radiograph review for CVC performed by anesthesiologists, and the review of several radiographs only by a surgeon instead of a radiologist. The checklist in our hospital now requires additional items: "complete guidewire withdrawal" and "chest radiograph checked." The review of all radiographs by radiologists in our hospital remains a challenge for us, as probably for many other hospitals. ■

## DISCLOSURES

**Name:** Ahmed Osailan, MD.

**Contribution:** This author helped write the manuscript.

**Name:** Mathilde De Queiroz Siqueira, MD.

**Contribution:** This author helped write the manuscript.

**Name:** Lionel Bouvet, MD, PhD.

**Contribution:** This author helped write/edit the manuscript.

**Name:** Dominique Chassard, MD, PhD.

**Contribution:** This author helped edit the manuscript.

**This manuscript was handled by:** BobbieJean Sweitzer, MD, FACP.

## REFERENCES

1. McGee DC, Gould MK. Preventing complications of central venous catheterization. *N Engl J Med*. 2003;348:1123–1133.
2. Pokharel K, Biswas BK, Tripathi M, Subedi A. Missed central venous guide wires: a systematic analysis of published case reports. *Crit Care Med*. 2015;43:1745–1756.
3. Guo H, Peng F, Ueda T. Loss of the guide wire: a case report. *Circ J*. 2006;70:1520–1522.
4. Schummer W, Schummer C, Gaser E, Bartunek R. Loss of the guide wire: mishap or blunder? *Br J Anaesth*. 2002;88:144–146.
5. Zhao S, Wang Z, Zhao Y. Loss of guidewire and its sequelae after central venous catheterization: a case report. *Medicine (Baltimore)*. 2019;98:e16513.
6. Pérez-Díez D, Salgado-Fernández J, Vázquez-González N, et al. Images in cardiovascular medicine. Percutaneous retrieval of a lost guidewire that caused cardiac tamponade. *Circulation*. 2007;115:e629–e631.
7. Arnous N, Adhya S, Marof B. A case of retained catheter guidewire discovered two years after central venous catheterization. *Am J Case Rep*. 2019;20:1427–1433.
8. Bahar GCB, Sertac G, Murat S, Ibrahim G, Hayri R. Complete guidewire retention after femoral vein catheterization. *Ann Saudi Med*. 2015;35:479–481.
9. Meddings J, Reichert H, Greene MT, et al. Evaluation of the association between Hospital Survey on Patient Safety Culture (HSOPSC) measures and catheter-associated infections: results of two national collaboratives. *BMJ Qual Saf*. 2017;26:226–235.
10. Swaminathan L, Flanders S, Rogers M, et al. Improving PICC use and outcomes in hospitalised patients: an interrupted time series study using MAGIC criteria. *BMJ Qual Saf*. 2018;27:271–278.
11. Rupp SM, Apfelbaum JL, Blitt C, et al. Practice guidelines for central venous access: a report by the American Society

- 
- of Anesthesiologists Task Force on Central Venous Access. *Anesthesiology*. 2012;116:539–573.
12. Apfelbaum JL, Rupp SM, Tung A, et al. Practice Guidelines for Central Venous Access 2020. An updated report by the American Society of Anesthesiologists Task Force on Central Venous Access. *Anesthesiology*. 2020;132:8–43.
  13. Spiritoso R, Padley S, Singh S. Chest X-ray interpretation in UK intensive care units: a survey 2014. *J Intensive Care Soc*. 2015;16:339–344.
  14. Mariyaselvam MZA, Patel V, Young HE, Blunt MC, Young PJ. Central venous catheter guidewire retention. Lessons from England's never event database. *J Patient Safety*. 2021. January 26, doi: 10.1097/PTS.0000000000000826.
  15. Mariyaselvam MZA, Catchpole KR, Menon DK, Gupta AK, Young PJ. Preventing retained central venous catheter guidewires: a randomized controlled simulation study using a human factors approach. *Anesthesiology*. 2017;127: 658–665.