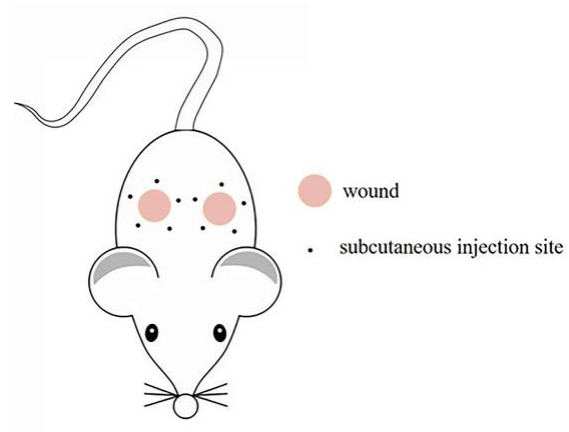


**Figure S1.** The subcutaneous vitamin D injection sites in the murine full-thickness skin defect model.



**Figure S2.** Pathological study of *in vivo* potential toxicity of the four doses of vitamin D on liver and kidney at 21 days post-wounding (scale bars: 100  $\mu$ m).

