

Contents lists available at [ScienceDirect](http://www.sciencedirect.com)

## International Journal of Surgery Case Reports

journal homepage: [www.casereports.com](http://www.casereports.com)

## Modified tension-free mesh repair used in rare case of Littre's hernia



Raimkhanov Aidar Duysenovich\*, Aimagambetov Meyirbek Zhaksybekvich,  
Omarov Nazarbek Bakytbekovich, Zhagniyev Zhandos Yermukhambetovichzhan

Department of Surgery, Medical Center of Semey State Medical University, Semey 071400, Sechenovst. 1, Kazakhstan

## ARTICLE INFO

## Article history:

Received 23 April 2015

Received in revised form 20 May 2015

Accepted 20 May 2015

Available online 22 May 2015

## ABSTRACT

**INTRODUCTION:** Meckel's diverticulum is found at the antimesenteric border of the ileum, usually located from 30 to 90 cm from the ileocecal valve. Meckel's diverticulum complications, such as bowel obstruction, diverticulitis, hemorrhage and rarely, hernias containing a Meckel's diverticulum (Littre's Hernia) required surgical intervention.

**CASE PRESENTATION:** We introduce the case report of 77-year-old man with inguinal hernia containing Meckel's diverticulum operated by the modified tension-free mesh repair.

**DISCUSSION:** Although Meckel's diverticulum is a relatively common anomaly, herniation of these embryological remnants is an exceedingly rare event. It can be difficult to diagnose Littre's hernia before operation.

**CONCLUSION:** The important thing is not to hesitate to perform diverticulectomy, to avoid complications of the patient in the future.

© 2015 The Authors. Published by Elsevier Ltd. on behalf of Surgical Associates Ltd. This is an open access article under the CC BY-NC-ND license (<http://creativecommons.org/licenses/by-nc-nd/4.0/>).

## 1. Introduction

Embryologically, Meckel's diverticulum is the persistent intestinal part of the omphaloenteric duct through which the midgut communicates with the umbilical vesicle until the fifth week. It is found at the antimesenteric border of the ileum, usually located at 30–90 cm from the ileocecal valve, measuring 3–6 cm in length and 2 cm in diameter. Usual sites of Littre hernia are inguinal (50%), umbilical (20%), and femoral (20%) [1]. In estimated 4% of cases, medical or surgical intervention is required to treat complications connected with Meckel's diverticulum, such as bowel obstruction, diverticulitis, hemorrhage and rarely, hernias containing a Meckel's diverticulum (Littre's Hernia) [2]. We introduce the case report of 77-year-old man with inguinal hernia containing Meckel's diverticulum who was operated by the modified tension-free mesh repair.

## 2. Presentation of case

A 77-year-old man was admitted to our hospital for surgery of inguinal hernia of large size. He complained of pain during physical activity within 2 years. Additionally, he suffers from ischemic heart disease, atrial fibrillation, COPD, and lung emphysema. He had no history of previous abdominal surgeries.

Abdominal examination revealed a soft and painful mass measuring 8–6 cm in the right groin. It was non-pulsatile. In horizontal position of the patient, the mass was reducible. The abdomen was without any signs of peritonitis.

The inguinal hernia was diagnosed. During the revision of hernia sac, the knitted Meckel's diverticulum approximately 8 cm in length was revealed (Fig. 1). A diverticulectomy was done and modified tension-free mesh repair was used to close the inguinal defect (Fig. 2). The method is performed by covering the posterior wall of opening by polypropylene mesh. Firstly, polypropylene mesh is fixed on periosteum of pubic bone and its crest, wherein the femoral canal is strengthened. Further, polypropylene mesh from medial and above sides is sutured to transverse abdominal muscle and to its fascia, laterally – to the inguinal ligament, wherein the posterior wall of hernia and inguinal canal are strengthened. The edge of the internal oblique muscle is stitched to the polypropylene mesh without tension, after that free lateral edge of polypropylene mesh is placed on the surface of the internal oblique muscle and fixed, wherein the defect of inguinal gap is liquidated without tension of tissues, and the internal inguinal ring is formed and strengthened (Fig. 3). In the end, stitches are on the aponeurosis of the external oblique muscle and on the skin. The proposed method can reduce the recurrence rate and improve the outcomes of large and recurrent inguinal hernias.

The patient recovered and was discharged from hospital without any complications.

\* Corresponding author. Tel.: +7 7073320084.

E-mail addresses: [raimkhanovaidar@gmail.com](mailto:raimkhanovaidar@gmail.com) (R.A. Duysenovich), [zhagniyev@gmail.com](mailto:zhagniyev@gmail.com) (Z.Z. Yermukhambetovichzhan).

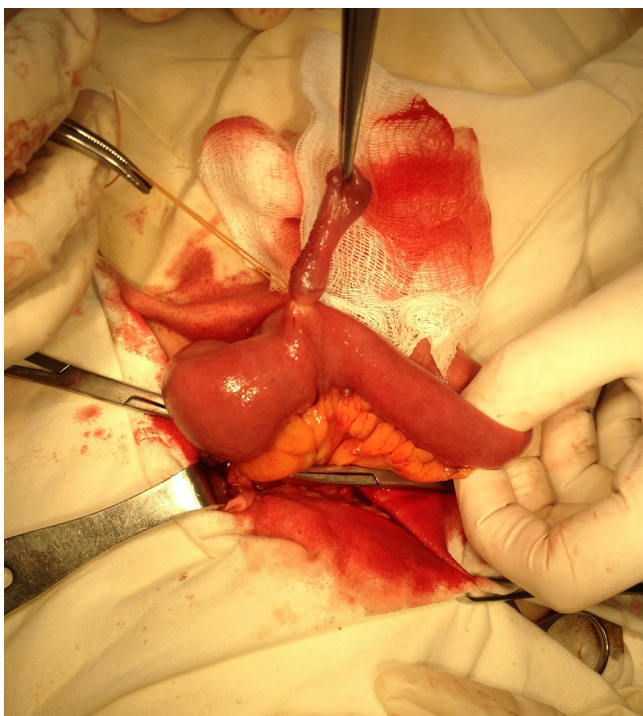


Fig. 1. Meckel's diverticulum.

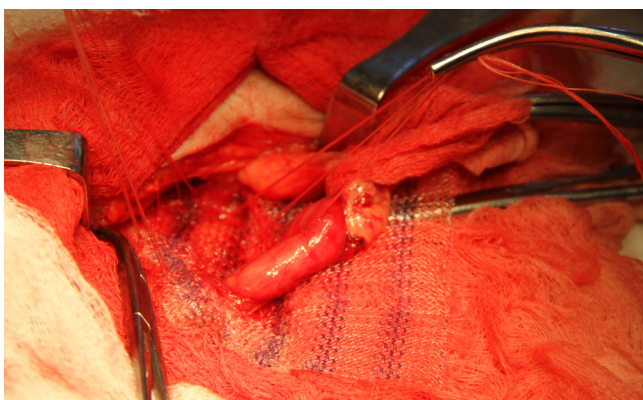


Fig. 2. Fixation of posterior wall of inguinal canal.

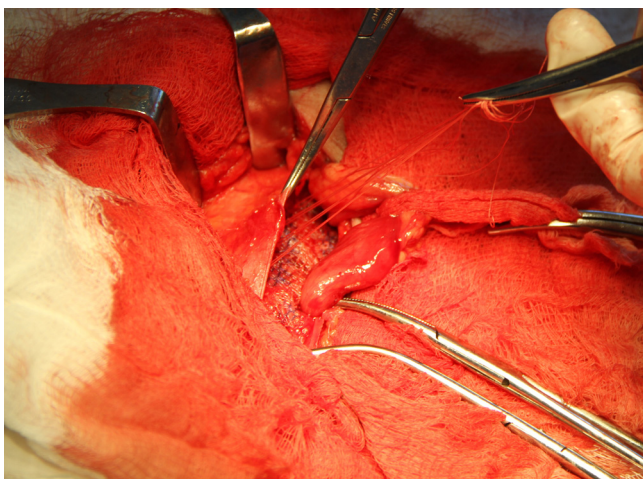


Fig. 3. Fixation of anterior wall of inguinal canal by lateral branch of mesh.

### 3. Discussion

In 1700, a French surgeon Alexandre de Littre described for the first time a new form of inguinal hernia. Littre's hernia is defined as any hernial sac which contains a Meckel's diverticulum [3].

Meckel's diverticulum occurs both in males and females in approximately 1–3% of the population with equal incidence but symptoms commonly occur in males. Although Meckel's diverticulum is a relatively common anomaly, herniation of these embryological remnants is an exceedingly rare event. It could be difficult to diagnose Littre's hernia before operation [3]. Most of them are clinically silent and often incidentally found during laparotomy or in inguinal incision as in our case [4].

We have said before that the prevalence of Meckel's diverticulum is up to 4% in general population. Individuals born with a Meckel's diverticulum may develop symptoms at any point during their lifetime from infancy to adulthood [5].

Complicated Meckel's diverticulum may cause intussusception of the Meckel's diverticulum within its own lumen, small bowel obstruction, colicky abdominal pain, vomiting and distention in adults and pediatric patients [6]. Our patient had no that kind of symptoms. Factors pre-disposing to intussusception of the Meckel's diverticulum within its own lumen include a narrow diverticulum, large diverticulum, and associated inflammation of the diverticulum [7]. According to the well-known statement of Charles Mayo, 'MD is frequently suspected, often looked for and seldom found'. I have not suspected, have not looked for MD but found it in our patient.

### 4. Conclusion

I am a surgeon having 7 years of surgical practice, have not met before the inguinal hernia containing Meckel's diverticulum. Immediately after operation, I searched the internet and found interesting articles. The important thing is not to hesitate to perform diverticulectomy, in order to avoid complications of the patient in the future. The patient was discharged from Medical Center without any complications.

#### Conflict of interest

None.

#### Ethical approval

13 November 2013 was given by Ethnical Committee of Semey State Medical University, protocol No.2

#### Consent

Written informed consent was obtained from the patient for publication of this case report and accompanying images. A copy of the written consent is available for review by the Editor-in-Chief of this journal on request.

#### Author contribution

Raimkhanov Aidar Duysenovich – Performed the operation. Participated in writing the case report.

Aimagambetov Meyirbek Zhaksybekovich – Doctor of Medical Science, Dean of Chair of Surgery. Participated in data collection, data analysis, writing a case report.

Omarov Nazarbek Bakytbekovich – Participated in data collection, data analysis, writing a case report.

Zhagniyev Zhandos Yermukhambetovich – Participated in data collection, data analysis, writing a case report.

**Guarantor**

Raimkhanov Aidar Duysenovich.

**References**

- [1] P.N. Skandalakis, O. Zoras, J.E. Skandalakis, P. Mirilas, Littre hernia: surgical anatomy, embryology, and technique of repair, *Am. Surg.* 72 (3) (2006) 238–243.
- [2] J. Michael Horkoff, G. Nathan Chan Smyth, M. James Hunter, A large incarcerated Meckel's diverticulum in an inguinal hernia, *Int. J. Surg. Case Rep.* 5 (12) (2014) 899–901, <http://dx.doi.org/10.1016/j.ijscr.2014.09.036>
- [3] M. Akin, O. Kurukahvecioglu, T. Tezcaner, A.Z. Anadol, K. Onur, Acute hemiscrotum due to inguinoscrotal Littre hernia: a case report, *Am. J. Emerg. Med.* 26 (8) (2008) 973.e3–973.e4, <http://dx.doi.org/10.1016/j.ajem.2008.02.023>
- [4] K. Paras Pandove, A. Moudgil, M. Pandove, Chandrashekhar, D. Sharda, V.K. Sharda, Meckel's diverticulum mesentery along with its band forming a hernial sac: a rare case of internal herniation, *Int. J. Surg. Case Rep.* 10 (2015) 17–19, <http://dx.doi.org/10.1016/j.ijscr.2015.03.005>
- [5] K.A. Ruscher, J.N. Fisher, C.D. Hughes, S. Neff, T.J. Lerer, D.W. Hight, M.D. Bourque, B.T. Campbell, National trends in the surgical management of Meckel's diverticulum, *J. Pediatr. Surg.* 46 (5) (2011) 893–896, <http://dx.doi.org/10.1016/j.jpedsurg.2011.02.024>
- [6] J.K. Clark, D.A. Paz, G.G. Ghahremani, Imaging of Meckel's diverticulum in adults: pictorial essay, *Clin. Imaging* 38 (5) (2014) 557–564, <http://dx.doi.org/10.1016/j.clinimag.2014.04.020>
- [7] R. Kassir, T. Debs, C. Boutet, S. Baccot, K. Abboud, J. Dubois, A. Boueil Bourlier, V. Yvorel, O. Tiffet, Intussusception of the Meckel's diverticulum within its own lumen: unknown complication, *Int. J. Surg. Case Rep.* 10 (2015) 111–114.

**Open Access**

This article is published Open Access at [sciencedirect.com](http://www.sciencedirect.com). It is distributed under the [IJSCR Supplemental terms and conditions](#), which permits unrestricted non commercial use, distribution, and reproduction in any medium, provided the original authors and source are credited.