

## Oncology

## A case report of perineal liposarcoma

Aymen Sakly\*, Mohamed Hmidi, Khalil Abdennadher, Maher Chtourou

Department of Urology, Hbib Thameur Hospital, Tunisia

## ARTICLE INFO

## Keywords:

Dedifferentiated liposarcoma  
Liposarcoma prognosis  
Perineum

## ABSTRACT

Perineal localization of liposarcoma is extremely rare among all localization of soft tissue sarcoma. We report the case of 33-year-old man presenting a large perineal swelling.

Throughout this case, we bring new insights into the surgical management difficulty of this tumor and we review the place of adjuvant therapy and prognosis factors.

## Introduction

Liposarcoma is the second most common malignancy of soft tissue. This entity is a challenge for both the surgeon and the pathologist for its high potential of metastasis and recurrence. The clinical presentation is variable and it ranges from extreme indolence to rapid growth and metastatic features. Computed tomography and magnetic resonance imaging can be extremely useful to help assess these tumors.

We report the case of 33-year-old man presenting a large perineal liposarcoma.

Throughout this case, we report the diagnostic approach, MRI features, the surgical management of this tumor and the prognosis factors.

## Patient and observation

A 35-year-old man who was referred to our center complaining of large perineal mass evolving since 6 months. He noticed a weight loss of 7 kg without lower urinary tract symptoms or erectile dysfunction. Clinical examination revealed a swelling extending from the gluteal region to the base of the penis (Fig. 1). In rectal examination, we found a normal sphincterian tonus and there was not gross involvement of the rectal wall.

On MRI, we found a huge heterogeneous signal mass measuring 12,5 \*5\*8,5 cm that has intermediate signal intensity on T1 weighted MR images and low signal intensity on T2 weighted MR images with marked signal enhancement by gadolinium. The lesion had severe synechia with bulbospongiosus muscle, urogenital diaphragm and the right spermatic cord. We also noticed a suspicious infiltration into the external urethral sphincter (Fig. 2).

Us guided biopsy with fine needle suggested the possibility of myxoid liposarcoma.

A local wide resection was achieved through a perineal approach.

Intra operative findings revealed a nodular tumor with admixed areas of fatty necrotic and hemorrhagic areas and solid components infiltrating adjacent structures. The histological examination revealed a sarcomatous process with two contingents consisting of round mesenchymal cells and signet ring lipoblasts in myxoid stroma. The predominant proliferation was represented by a storiform growth pattern with pleomorphic tumor cells characterized by foamy cytoplasm and marked atypia. Mitotic figures were numerous (more than 15/10 HPF) including atypical forms (Fig. 3). Microscopic margins were positive. Re-resection was scheduled in 3 weeks.

After one month, the patient was referred to the oncologist for adjuvant radiotherapy consisting of a total of 60 Gy in 30 fractions with 10 Gy to the tumor bed.

The patient reported was free of disease at 15 months postoperative follow-up.

## Discussion

Soft tissue sarcoma are uncommon biologically and histologically heterogeneous neoplasms arising from mesenchymal tissues. Perineal sarcoma represented 4.7% of all localizations and liposarcoma 6.7% of all mesenchymatous subtypes.

At clinical presentation, these tumors are often painless swellings and asymptomatic that progressively increase in size.

On MRI, undifferentiated liposarcomas appear heterogeneous dimorphic, mostly with lobulated margins. They have high signal intensity on T2 weighted images with area of enhancement on contrast-enhanced. The well differentiated liposarcoma are composed of mainly mature fat.<sup>1</sup> these tumors show faint or no enhancement after administration of contrast material on the gradient fat saturated T1-weighted sequences. Increased cellularity of liposarcomas have a low signal on T1-weighted images. This finding can be helpful in differentiating from

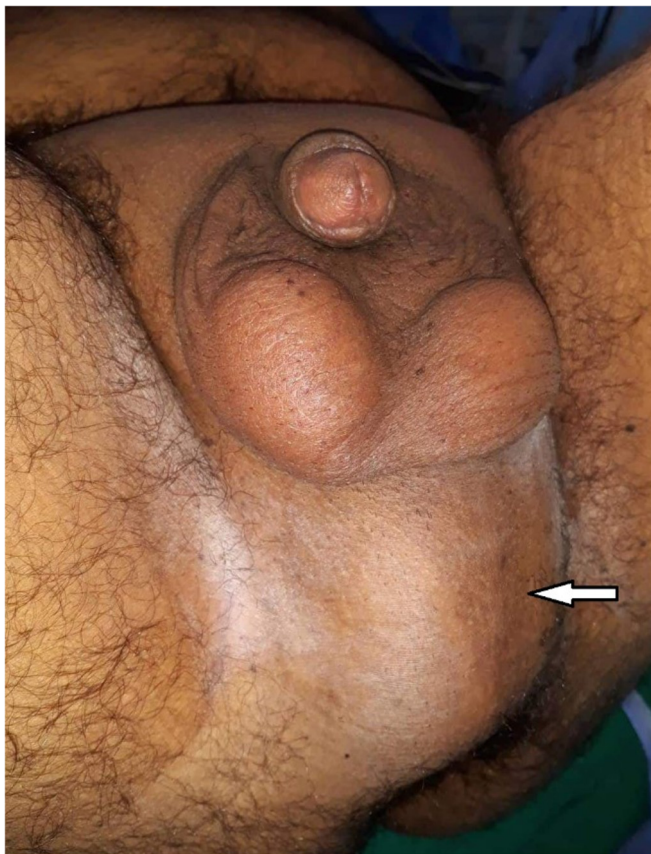\* Corresponding author.

E-mail address: [dr.aymen.sakly@gmail.com](mailto:dr.aymen.sakly@gmail.com) (A. Sakly).<https://doi.org/10.1016/j.eucr.2019.100897>

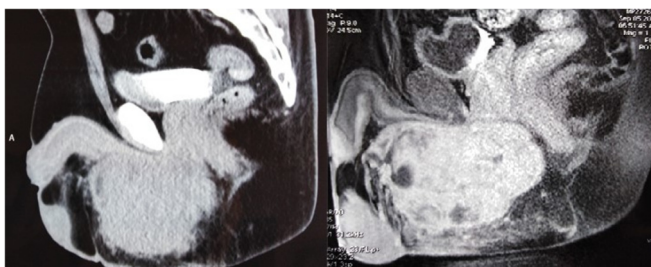
Received 8 April 2019; Accepted 23 April 2019

Available online 24 April 2019

2214-4420/© 2019 The Authors. Published by Elsevier Inc. This is an open access article under the CC BY-NC-ND license (<http://creativecommons.org/licenses/by-nc-nd/4.0/>).



**Fig. 1.** The large swelling extending from the gluteal region to the base of the penis.



**Fig. 2.** On MRI we found a heterogeneous signal mass measuring 12,5 \*5\*8,5 cm with intermediate signal intensity on T1 weighted MR images and low signal intensity on T2 weighted MR images with marked signal enhancement by gadolinium.

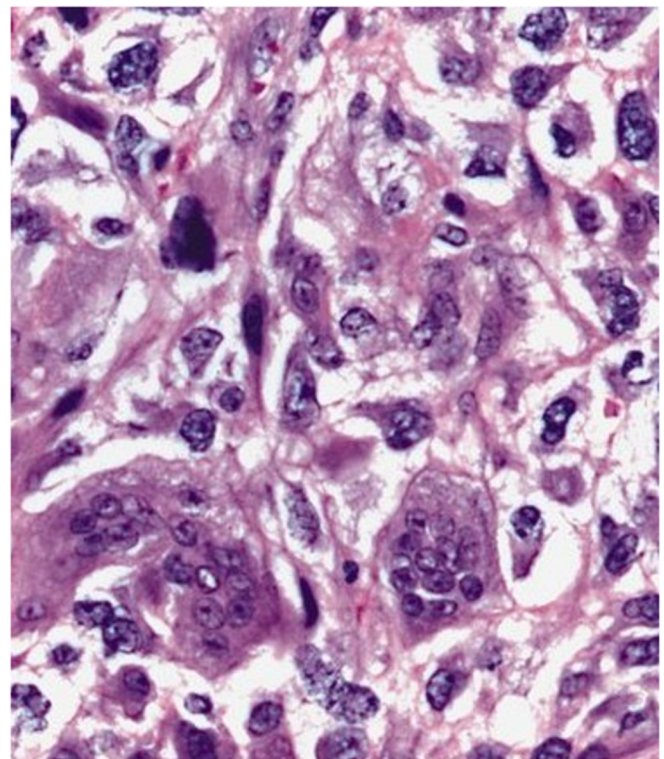
lipoma.

Finally, MRI can be useful in the assessment of the position, depth and anatomical relationships of the lesion.

Treatment options are determined in large part by the primary site, the stage, and the FNCLCC grade.

When the mass is resectable, wide excision followed by radiotherapy is recommended for adequate local disease control.<sup>2</sup> In our case, the tumor proximity of vital structures was a challenge. Negative gross margins of resection should be the goal of surgery for the primary lesion. The challenge is to obtain negative microscopic margins that is not evident and increasing the risk of urethral, bulbocavernous injuries and anorectal dysfunction especially among young patients. When microscopic margins are positive, re-excision should be considered.

For adjuvant therapy, it's shown in a large retrospective cohort, that adjuvant radiotherapy resulted in the highest median survival (93 months) and 5-year survival probabilities (63.4%), while chemotherapy



**Fig. 3.** The histological examination showed pleomorphic tumor cells characterized by foamy cytoplasm in background of inflamed collagenous stroma. Mitotic figures with atypical cells are frequent and associated with numerous cell necrosis.

is reserved for metastatic disease.<sup>3</sup>

High grade lesions and positive microscopic margins are associated with high risk of recurrence,<sup>4</sup> while histological grade and percentage of round cells are predicting factors for metastasis.<sup>5</sup>

Regarding histologic grade, low-grade (grade 1) dedifferentiated liposarcoma has much better survival outcomes compared to high-grade with a median survival for low-grade and high-grade dedifferentiated tumors were 113 and 48 months.

In this case, a long-term follow-up is recommended.

### Conclusion

The perineal localization of liposarcoma is very rare. Preoperative MRI is helpful in identifying anatomical relationships prior to surgery especially for the perineal localization. These aggressive tumors should be closely followed.

### Authors' contributions

AS wrote and submitted the manuscript. MH and MC provided the images and reviewed the manuscript. KA contributed to the writing and the reviewing of the manuscript. All authors read and approved the final manuscript.

### Competing interests

The authors declare that there are no conflicts of interest regarding the publication of this article.

### Fundings

This research did not receive any specific grant from funding agencies in the public, commercial, or not-for-profit sectors.

### Patient consent

Written consent was obtained from the patient to participate in this case report.

### References

1. Arkun R, Memis A, Akalin T, Ustun EE, Sabah D, Kandiloglu G. Liposarcoma of soft tissue: MRI findings with pathologic correlation. *Skeletal Radiol.* 1997;26:167–172.
2. Loubignac F, Bourtoul C, Chapel F. Myxoid liposarcoma: a rare soft tissue tumor with a misleading benign appearance. *World J Surg Oncol.* 2009;7:42.
3. Gootee J, Aurit S, Curtin C, Silberstein P. Primary anatomical site, adjuvant therapy, and other prognostic variables for dedifferentiated liposarcoma. *J Cancer Res Clin Oncol.* 2019;145(1):181–192 1 janv.
4. Grobmyer SR, Clary B, Lewis JJ, Delgado R, Woodruff JM, Brennan MF. Adult perineal sarcomas. *J Surg Oncol.* 2001;77(2):101–104.
5. Fiore M, Grosso F, Lo Vullo S, et al. Myxoid/round cell and pleomorphic liposarcomas: prognostic factors and survival in a series of patients treated at a single institution. *Cancer.* 2007;109(12):2522–2531.