

An unpredictable complication of a transcatheter closure device and surgical treatment

The incidence of paravalvular leak (PVL) in patients who underwent mitral valve replacement is 7–17%. Hemolysis and congestive heart failure, which require an operation or intervention, are two main consequences with an incidence of 1–3%. In consequence of this reoperation is associated with high mortality and morbidity.

A 48-year-old man who underwent coronary artery bypass and mitral valve replacement surgery was evaluated. Paravalvular regurgitant jet flow adjacent to the appendix was localized with TEE imaging. Transapical transcatheter PVL closure was planned because of con-

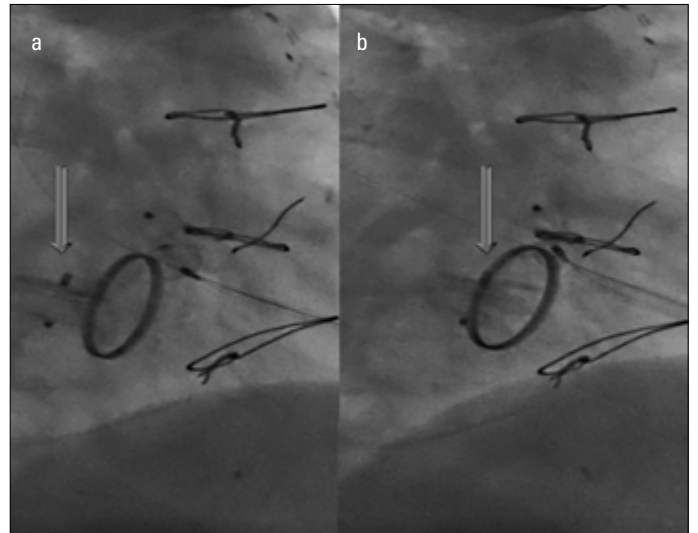


Figure 1. a, b. The forward motion of the closure device in the left atrium

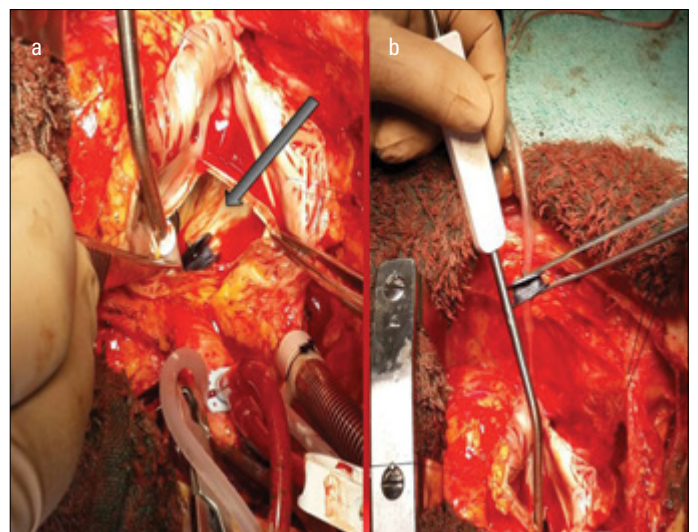


Figure 2. a, b. The position of the closure device in the left atrium during surgery

tinuing congestive heart failure symptoms, which were resistant to medical treatment. A closure device (Amplatzer Vascular Plug III) was forwarded to PVL, which is the destination point. At the moment of deploying the closure device to the defect, the device fell down to the left atrium (Fig. 1, Video 1-2). The cardiac team tried to extract the device via a transcatheter route; however, the interventions failed, and the patient underwent emergency operation. An emergency reoperation was performed with median sternotomy, and the closure device was explored in the left atrium (Fig. 2). The closure device was retrieved, and the mitral prosthetic paravalvular defect was closed with pledged sutures. The perioperative TEE imaging study showed neither a paravalvular defect nor regurgitant flow. The patient was transferred to the ward on postoperative first day and was discharged from hospital on the seventh day.

During PVL, embolization of closure devices and malposition of occluder devices could cause serious complications. Consequently, the cooperation of cardiac surgeon, invasive cardiology, and imaging specialist is obligatory for the successful performance of such an intervention.

Video 1. The free movement of the closure device in the left atrial chamber

Video 2. The forward motion of the closure device in the left atrium

Ünal Aydın, Ersin Kadiroğulları, Onur Şen, Emre Akkaya*, Korhan Erkanlı, İhsan Bakır
Departments of Cardiovascular Surgery and *Cardiology, İstanbul Mehmet Akif Ersoy Thoracic and Cardiovascular Surgery Training and Research Hospital; İstanbul-Turkey

Address for Correspondence: Dr. Ersin Kadiroğulları,
İstanbul Mehmet Akif Ersoy, Göğüs ve Kalp Damar Cerrahisi Eğitim ve Araştırma Hastanesi, İstasyon Mah. İstanbul Cad. Bezirganbahçe Mevkii, Küçükçekmece 34303 İstanbul-Türkiye

Phone: +90 212 692 20 00 (1398 ext.)

E-mail: ersinkadirogullari@gmail.com

Available Online Date: 22.05.2015

©Copyright 2015 by Turkish Society of Cardiology - Available online at www.anatoljcardiol.com
DOI:10.5152/AnatolJCardiol.2015.6472