



ELSEVIER

Contents lists available at [ScienceDirect](https://www.sciencedirect.com)

Trauma Case Reports

journal homepage: www.elsevier.com/locate/tcr

Case Report

Penetrating angle grinder injury to the neck causing subclavian artery injury

Vincent Varley^{a,*}, Matthew Claydon^a, Jarryd Solomon^a, Anastasia Dean^a,
Thomas Lovelock^a, Mark C. Fitzgerald^b

^a Department of Vascular Surgery, The Alfred Hospital, Melbourne, Victoria, Australia

^b National Trauma Research Institute, The Alfred Hospital, Melbourne, Victoria, Australia

ARTICLE INFO

Keywords:

Trauma
Penetrating
Angle grinder
Subclavian
Thoracic outlet
Penetrating neck

ABSTRACT

Penetrating injuries to the neck present a unique challenge due to the confined space of the thoracic outlet for haemorrhage control and repair. This results in high mortality rates when the major vascular structures of the neck are transected, as well as potential neurological compromise. We present the case of a penetrating injury to the proximal subclavian artery from a broken angle grinder disc which is a unique mechanism of injury that can have fatal consequences. The patient described in this case underwent an emergent median sternotomy for proximal control of the brachiocephalic trunk and ligation of the right vertebral artery to facilitate a primary repair of the injured vessel segment. Post operatively the patient made a complete recovery with no central or peripheral neurologic deficits and requiring no further interventions. The key points from this case are that angle grinders pose a significant injury burden and early specialised medical attention should be sought, rapid control of the proximal neck vessels can be obtained via a median sternotomy and that the vertebral artery can be ligated in an emergent situation without neurological consequence.

Introduction

Penetrating neck injuries comprise approximately 1% of adult trauma admissions and are associated with injuries to vascular, aerodigestive and nervous structures with mortality most commonly associated with a major vascular injury [1].

Angle grinders are devices used by both professionals and amateurs that cause more injuries than any other power tool. A common but lethal failure of these devices occurs when the rotating disc chips or shatters sending high velocity sharp missiles towards the operator, with the head and neck the most common areas affected. Discs are manufactured in two main sizes 9 in. (230 mm) and 14 in. (356 mm) and they are designed to rotate at a maximum outside edge speed of approximately 70 m/s. Larger discs are commonly fitted to smaller angle grinders that operate with significantly higher rev/min for ease of use. This use brings about significant safety concerns [2].

- 1; The protective guard is removed to fit the larger disc (Fig. 1).
- 2; The higher rev/min increases the outside edge speed to over 120 m/s, nearly twice the safe limit of the disc.
- 3; The central disc hole will not be centred correctly therefore causing vibrations and increasing the risk of breaking.

* Corresponding author at: Department of Vascular Surgery, The Alfred Hospital, Commercial Road, Melbourne, Victoria 3004, Australia.
E-mail address: vincent.varley@ucdconnect.ie (V. Varley).

<https://doi.org/10.1016/j.tcr.2020.100378>

Accepted 6 December 2020

Available online 10 December 2020

2352-6440/© 2020 Published by Elsevier Ltd. This is an open access article under the CC BY-NC-ND license

(<http://creativecommons.org/licenses/by-nc-nd/4.0/>).

The subclavian artery is rarely injured due to protection by the thoracic cage, clavicle and muscular structures; however, these protective factors subsequently lead to management dilemmas when faced with this injury. We describe a case of a patient with a right-sided penetrating neck injury, who presented in haemorrhagic shock requiring repair of two separate injuries to the proximal subclavian artery and ligation of the right vertebral artery.

Case presentation

The Trauma Team attended a 54-year-old male who had sustained an injury from an angle grinder accident, in which the blade shattered and a shard penetrated the base of his right neck causing arterial bleeding. On arrival to the Emergency Department the patient was visibly pale and diaphoretic with direct pressure being applied to the wound located in Zone 1 of the neck as the shard had fallen out post injury (Fig. 2). A primary survey was performed after which it was decided to delay intubation until the patient was in theatre as there were no overt signs of aerodigestive injury or impending airway compromise. The patient received further volume resuscitation of packed red blood cells and fresh frozen plasma with a permissive hypotensive approach. Neurovascular examination of the arm revealed faint brachial and radial pulses, however, he had 0/5 power in his right arm from the C5 to T1 myotomes.

The decision was made to proceed directly to theatre for haemorrhage control and exploration without further imaging. A median sternotomy was performed and the aortic arch inspected for signs of contained rupture or dissection, of which there were none. A vessel loop was placed around the brachiocephalic trunk which was subsequently clamped. This allowed external compression of the neck wound to be removed and the bleeding controlled.

A neck incision was performed anterior to the sternocleidomastoid to inspect the anterior triangle of the neck which revealed muscle contusions without obvious haematoma or pulsatile mass, while the common carotid artery was explored showing no signs of injury. The sternotomy and neck incisions were joined over the manubrium to allow complete visualisation from the aortic arch to the carotid bifurcation. The brachiocephalic clamp was then removed and placed at the origin of the subclavian artery to allow flow to the right carotid artery.

A right transverse supraclavicular incision was made to explore the proximal subclavian artery. Care was taken to identify and protect the phrenic nerve as it ran anterior to the subclavian artery (yellow loop Fig. 3). An infraclavicular incision was made to expose the axillary artery which was looped and control of the bleeding was achieved by clamping the axillary artery and direct pressure over the proximal subclavian artery. Further dissection revealed two transactions in the subclavian artery as shown in Fig. 4. There was continued bleeding despite control of the subclavian and axillary arteries with vascular clamps primarily due to back bleeding from the vertebral artery. As such, the region of vessel between the two sites of injury was excised and the vertebral, internal mammary and thyrocervical trunks ligated. There was enough laxity in the remaining subclavian artery to allow a primary anastomosis.

The patient was extubated with no residual neurovascular deficit. It was thought that the loss of motor function and paraesthesia in his right arm was due to a neuropraxia from brachial plexus compression during manual compression. An MRI brain was performed to investigate for potential sequelae of vertebral artery ligation which was normal and the patient was successfully discharged home on post-operative day six and had returned to normal function at two months follow up.

Discussion

Penetrating neck trauma represents just 1% of trauma admissions but is associated with significant morbidity and mortality. Injuries to the subclavian and proximal axillary arteries provide a further challenge for surgeons due to their anatomic location, with some data suggesting a 40% mortality rate [3].

The basic principles of vascular trauma management are applicable to proximal subclavian injuries however the challenge lies in identifying where proximal control should be sought. Exposures commonly described in the literature for this situation include a supraclavicular incision, median sternotomy, high thoracotomy, trapdoor incision or a claviclectomy [4]. The routine use of the latter



Fig. 1. Angle grinder with protective guard removed to fit a larger disc. <https://www.worksafe.qld.gov.au/injury-prevention-safety/alerts/whsq/2017/guards-and-discs-on-angle-grinders>.




Fig. 2. Location of penetrating wound in Zone 1 of the neck.

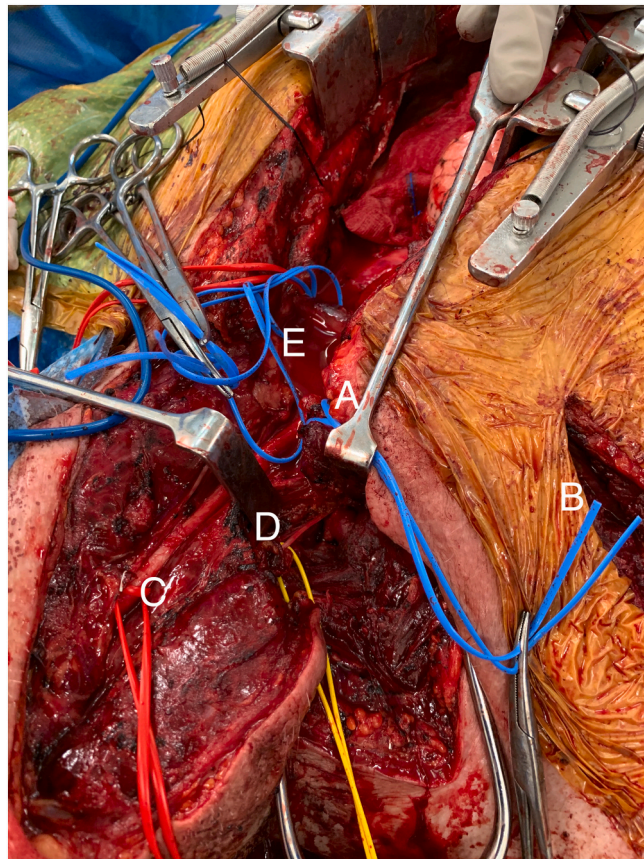


Fig. 3. A - Proximal subclavian artery with vessel loop
B - Infraclavicular exposure for axillary artery control
C - Common carotid artery with vessel loop
D - Phrenic nerve – looped for protection
E - Aortic arch.

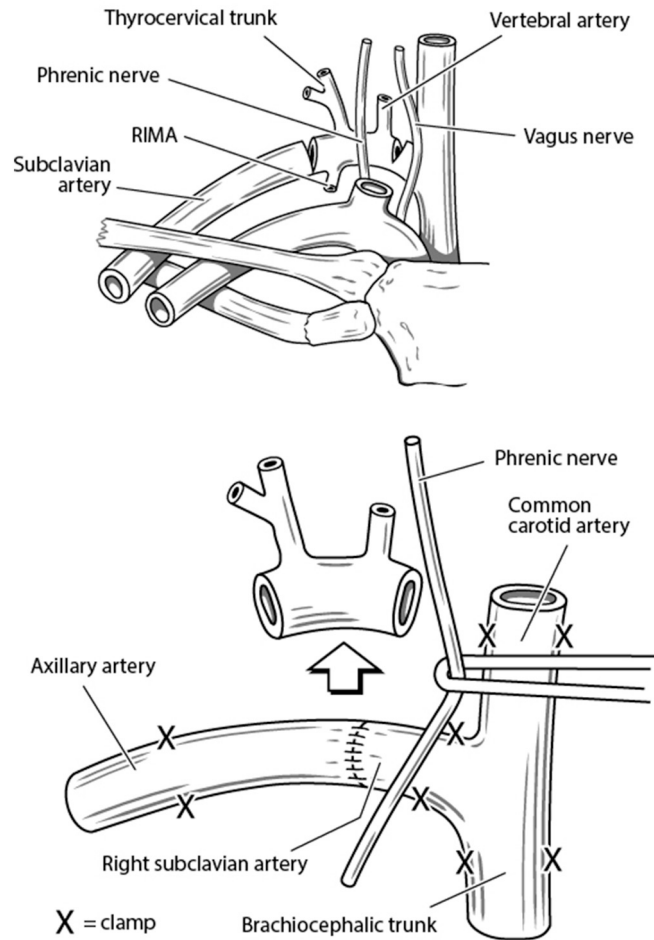


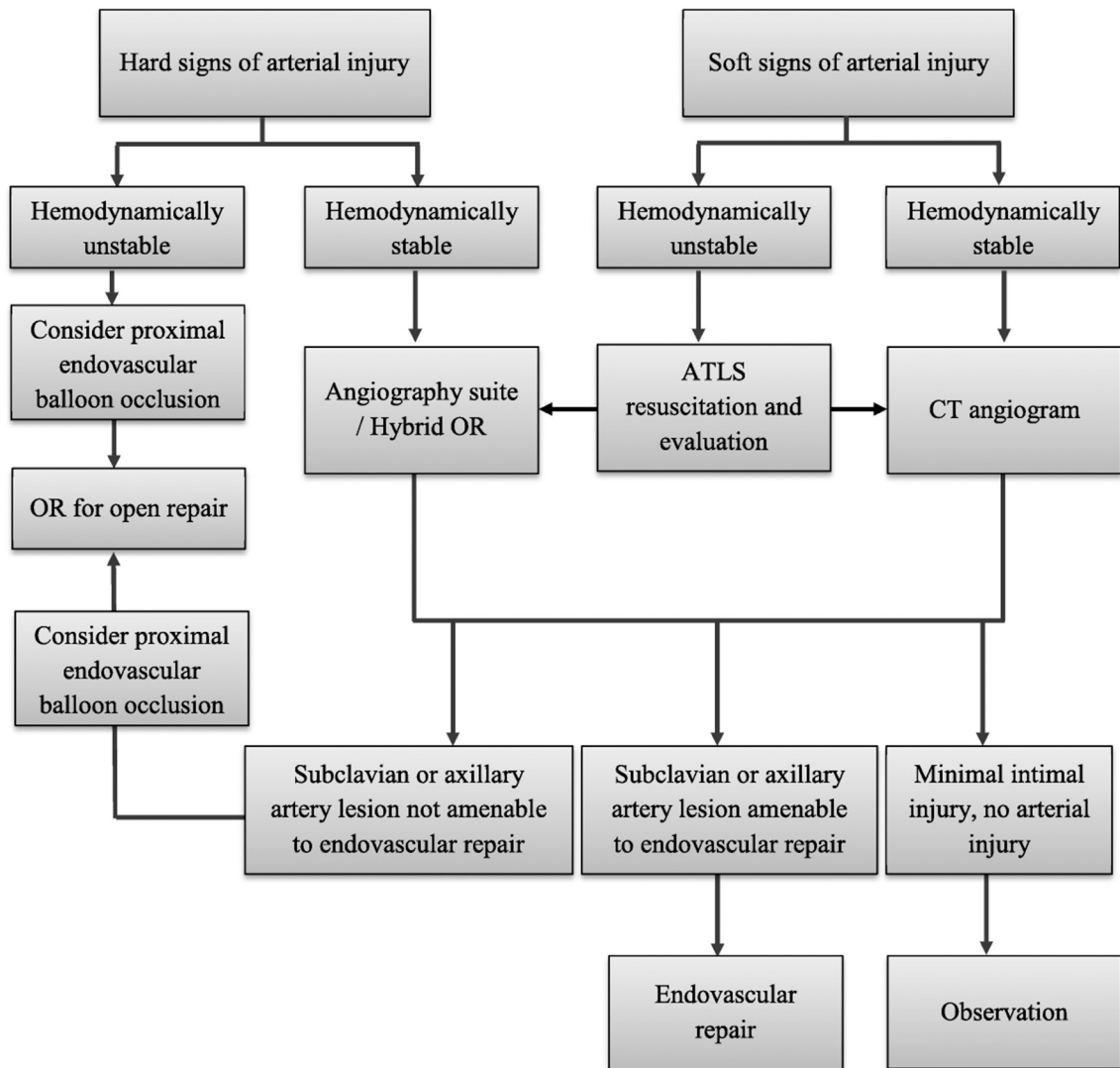
Fig. 4. Injury and primary repair.

two approaches has become less common due to associated post-operative pain and reduced function [5]. For patients in extremis, a resuscitative thoracotomy may be performed in order to apply direct pressure to the apex of the thoracic cavity. As demonstrated in this case, despite adequate proximal (median sternotomy) and distal (axillary cutdown) arterial control, non-compressible haemorrhage was still present due to back-bleeding from the vertebral, internal thoracic and thyrocervical trunks.

The ‘Hard’ signs of vascular injury which warrant immediate surgical exploration are external haemorrhage, expanding haematoma, a palpable thrill or bruit or evidence of arterial occlusion. The ‘Soft’ signs consist of a haematoma, unexplained hypotension, a history of bleeding, difference in pulses or the injury proximity to vascular structures [6]. The Western Trauma Association (WTA) algorithm (Fig. 5) suggests that for haemodynamically unstable patients with hard signs of arterial injury such as in the case presented, proximal balloon occlusion can be considered as an adjunct to open repair [7]. In a ten-year review by the WTA, 17% of subclavian and axillary artery injuries were managed with an endovascular approach, the vast majority of these patients presenting without haemodynamic compromise and had lower grade injuries such as pseudoaneurysms. With the growing experience of endovascular techniques in trauma and use of hybrid operating rooms, there may be increasing use of endovascular repair techniques for traumatic thoracic outlet injuries in the future.

Concerns for central and peripheral neurologic consequences in proximal subclavian artery injuries are evident due to close proximity of surrounding structures such as brachial plexus, phrenic nerves and recurrent laryngeal nerves as well as the ischaemic related consequences of arterial clamping. Left sided injuries theoretically carry a lower risk of stroke as the subclavian artery has its own origin from the Aorta therefore allowing for safe proximal control and/or deployment of a covered stent. In right subclavian injuries, timely clamp control of the subclavian artery beyond the brachiocephalic bifurcation is encouraged to allow for reperfusion of the carotid circulation.

As described in the case, the right vertebral artery was a source of ongoing haemorrhage requiring ligation. In elective procedures requiring sacrifice of a vertebral artery, balloon test occlusion is described to investigate completeness of the circle of Willis. Antecedent angiography and balloon occlusion tests are unfeasible in the trauma setting however case series have demonstrated relative safety of unilateral vertebral sacrifice without neurologic consequence in patients who cannot undergo pre-operative testing such as in trauma [8].



OR = operating room; ATLS = Advanced Trauma Life Support; CT = computed tomography.

Fig. 5. Management Algorithm for Subclavian and Axillary Artery Injuries. Western Trauma Association [6].

Conclusions

Penetrating injuries to the proximal subclavian artery are a rare presentation even to trauma centres and pose unique challenges in resuscitation and surgical management. Early recognition of the gravity of these injuries is essential to provide appropriate expertise in mediastinal exposure, vascular repair and endovascular techniques. In healthy individuals, back-bleeding especially from cerebral vessels can be a source of significant haemorrhage however unilateral vertebral artery ligation for haemorrhage control does not confer an increased risk of stroke.

Declaration of competing interest

None.

Acknowledgments

We would like to acknowledge the National Trauma Research Institute as a funder. We would also like to acknowledge Carrier Street Clinic, Benalla, Victoria for their initial resuscitation and management. Marcus Cremonese, Medical Illustrations, <http://www.>

medicalillustration.com.au/.

References

- [1] C. Evans, T. Chaplin, D. Zelt, Management of major vascular injuries, Neck, Extremities, and Other Things that Bleed. *Emerg Med Clin North Am.* 36 (1) (2018) 181–202.
- [2] W. Queensland, Guards and Discs on Angle Grinders: Workplace Health and Safety Electrical Safety Office Workers' Compensation Regulator, updated. Available from: <https://www.worksafe.qld.gov.au/injury-prevention-safety/alerts/whsq/2017/guards-and-discs-on-angle-grinders>, 2017.
- [3] C.S. Cox Jr., G.S. Allen, R.P. Fischer, L.D. Conklin, J.H. Duke, C.S. Cocanour, et al., Blunt versus penetrating subclavian artery injury: presentation, injury pattern, and outcome, *J. Trauma* 46 (3) (1999) 445–449.
- [4] M.J. Wall Jr., P.I. Tsai, K.L. Mattox, Heart and thoracic vascular injuries, in: E.E. Moore, D.V. Feliciano, K.L. Mattox (Eds.), *Trauma*, 8e, McGraw-Hill Education, New York, NY, 2017.
- [5] A.G. McKinley, A.T. Carrim, J.V. Robbs, Management of proximal axillary and subclavian artery injuries, *Br. J. Surg.* 87 (1) (2000) 79–85.
- [6] D.V. Feliciano, F.A. Moore, E.E. Moore, M.A. West, J.W. Davis, C.S. Cocanour, et al., Evaluation and management of peripheral vascular injury. Part 1. Western trauma association/critical decisions in trauma, *J. Trauma* 70 (6) (2011) 1551–1556.
- [7] C.J. Waller, T.H. Cogbill, K.J. Kallies, L.D. Ramirez, J.M. Cardenas, S.R. Todd, et al., Contemporary management of subclavian and axillary artery injuries—a Western trauma association multicenter review, *J. Trauma Acute Care Surg.* 83 (6) (2017) 1023–1031.
- [8] G.H. Zoarski, R. Seth, Safety of unilateral endovascular occlusion of the cervical segment of the vertebral artery without antecedent balloon test occlusion, *AJNR Am. J. Neuroradiol.* 35 (5) (2014) 856–861.