



Since January 2020 Elsevier has created a COVID-19 resource centre with free information in English and Mandarin on the novel coronavirus COVID-19. The COVID-19 resource centre is hosted on Elsevier Connect, the company's public news and information website.

Elsevier hereby grants permission to make all its COVID-19-related research that is available on the COVID-19 resource centre - including this research content - immediately available in PubMed Central and other publicly funded repositories, such as the WHO COVID database with rights for unrestricted research re-use and analyses in any form or by any means with acknowledgement of the original source. These permissions are granted for free by Elsevier for as long as the COVID-19 resource centre remains active.



ELSEVIER

Contents lists available at [ScienceDirect](https://www.sciencedirect.com)

Journal of Pediatric Surgery Case Reports

journal homepage: www.elsevier.com/locate/epsc

Spontaneous resolution of intussusception after COVID-19 infection found at laparoscopy in a 6-year-old

Renato Díaz-Ruiz^{a,b,*}, Paula Ponce-de-León-Lovatón^c, Paulo Delgado-Seminario^a, Diego Urrunaga-Pastor^d

^a Hospital III Jose Cayetano Heredia, EsSalud, Piura, Peru

^b Clínica Belen, Red SANNA, Piura, Peru

^c Clínica San Felipe, Red SANNA, Lima, Peru

^d Instituto de Evaluación de Tecnologías en Salud e Investigación – IETSI, EsSalud, Lima, Peru

ARTICLE INFO

Keywords:

Intussusception
COVID-19
SARS-CoV-2
Pediatric surgery
Child

ABSTRACT

The incidence of intussusception is 2.5 per 1000 live births, and infants between 4 and 10 months of age represent the highest frequency peak. Cases of intussusception with acute COVID-19 infection have been reported in infants under one year of age and with one death associated with MIS-C. However, we have not found reports of intussusception in schoolchildren. We report the case of a 6-year-old male with two days of illness that began with a sensation of temperature rise, headache, abdominal pain, liquid stools with mucus and no blood, hyporexia, chills, and food vomiting. He presented a negative result for the detection of SARS-CoV-2 antigen, negative SARS-CoV-2 IgM/IgG serology positive (lateral flow immunochromatography test), in addition to total IgM/IgG antibodies in 11.88 COI by means of a test of electrochemiluminescence. An abdominal ultrasound was performed that concluded invagination, for which an exploratory laparoscopy was performed and the patient evolved favorably. 13 cases of intussusception associated with acute COVID-19 infection have been described in this group. However, no reports of intussusception have been described after COVID-19 infection in school age. We recommend ruling out active or past SARS-CoV-2 infection in children with gastrointestinal symptoms and, if it exists, ruling out invagination by means of abdominal ultrasound.

1. Introduction

The incidence of intussusception is 2.5 per 1000 live births and infants between 4 and 10 months of age represent the maximum frequency peak [1] and it is considered the main cause of intestinal obstruction in infants [2–9]. Although most are idiopathic [2, 6–10], 30% are associated with previous viral infection [4,8] being the most common etiological factor [1,2,4]. Adenoviruses and rotaviruses represent 50% of cases associated with viral infection [2–5], although poliovirus, enterovirus, parechovirus, and norovirus have also been found [4,8]. 6% of cases of intussusception are due to Meckel's diverticulum, Henoch-Schonlein purpura, intestinal duplication, polyp or lymphoma [8], with a precipitating lesion found in 10%–25% of cases [2].

10% of children with COVID-19 present gastrointestinal symptoms [8] being more common than in adults [2,8]. It increases up to 18% in some reports [1] and manifests as abdominal pain, diarrhea and vomiting [3,4,6,10]. Cases of intussusception with acute COVID-19 infection have been reported in infants under one year of age and with one death associated with MIS-C [1–12].

* Corresponding author. Hospital III Jose Cayetano Heredia, EsSalud, Avenida Independencia, Piura, 20002, Peru.
E-mail address: renatodiaz11@gmail.com (R. Díaz-Ruiz).

<https://doi.org/10.1016/j.epsc.2022.102273>

Received 18 March 2022; Received in revised form 1 April 2022; Accepted 4 April 2022

Available online 9 April 2022

2213-5766/© 2022 The Authors. Published by Elsevier Inc. This is an open access article under the CC BY-NC-ND license (<http://creativecommons.org/licenses/by-nc-nd/4.0/>).

Although there are cases of intussusception in infants with active SARS-CoV-2 infection, we have not found reports of intussusception in schoolchildren who have presented the disease.

2. Case report

A 6-year-old male with two days of illness that began with a sensation of temperature rise, headache, and abdominal pain. Subsequently, liquid stools with mucus are added, without blood, hyporexia, chills and food vomiting. He goes to a private clinic where he is treated and discharged. The abdominal pain intensifies the next day, for which he returns to the private clinic, where laboratory tests are requested (Table 1), he is given treatment (not specified by relatives) and when the crampy pain in the mesogastrium and epigastrium increases, accompanied by feeling nauseous, they request voluntary withdrawal and come to our institution due to an emergency. Physical examination revealed pain on deep palpation in the mesogastrium. An abdominal ultrasound was performed that concluded intussusception, so surgical intervention was decided (Fig. 1a).

Preoperative tests (Table 1) show increased C-reactive protein (CRP), negative result for SARS-CoV-2 antigen detection, negative SARS-CoV-2 IgM/positive IgG serology (lateral flow immunochromatography test), in addition to total IgM/IgG antibodies in 11.88 COI by electrochemiluminescence test (normal value: 0.00–0.99). Urinalysis revealed albumin 1+, ketone bodies 2+, hemoglobin 2+, red blood cells 26–50/field (normal value: 0–1). The child's mother reported contact of the child with uncles who had a positive result for IgG in a lateral flow immunochromatography test, without having presented symptoms.

During surgery, mesenteric adenitis, non-invaginated ileum, appendix without significant alterations and liver with change in color were observed (Fig. 1b, 1c and 1d). An appendectomy was performed using a laparoscopic technique and a postoperative liver profile was requested (Table 1). Given a presumptive diagnosis of MIS-C, the pediatrician requested laboratory tests (Table 1) and the cardiologist suggested continuing management by pediatric surgery. The patient evolved with mild and occasional pain, for which he was discharged on the second day after the operation, with analgesic. The patient came to the office 8 days after the operation and without symptoms. Control laboratory tests (Table 1) and echocardiography were taken, finding mild tricuspid regurgitation. In addition, the urinalysis did not present alterations, however, the functional coprology was positive for thevenon.

3. Discussion

The incidence of intussusception is 2.5 per 1000 live births, affecting infants in most cases [1]. 13 cases of intussusception associated with COVID-19 infection have been described in infants with a positive active infection test, although one of them had already been diagnosed with COVID-19 three weeks before the intussusception [9]. However, no reports of intussusception have been found after COVID-19 infection in school age.

Most cases of intussusception occur in infants. This coincides with the cases of intussusception associated with COVID-19 infection, which mostly range between 4 and 10 months [1,2,4–8,10–12]. However, cases have also been described in infants aged 2 months and 2.5 months [3,9]. We have not found cases in school-age children like the one we have presented who do not have an active SARS-CoV-2 infection.

Table 1
Summary of laboratory markers in the patient.

| Diagnostic Aid Exam | Before Hospital Attention | Preoperative analysis | Postoperative analysis | Analysis on the eighth postoperative day |
|-------------------------|---|---|---|--|
| PCR and/or VSG | PCR 11.1 mg/dl (0–0.5) | PCR 77.9 mg/l (0.01–5) | VSG 15mm/h (1–10) PCR 38.5 mg/l (0.01–5) | VSG 15mm/h (1–10) PCR 1.9 mg/l (0.01–5) |
| Urine and/or stool test | RIH: >100 leukocytes/field 8–10 red blood cells/field | Ex. Urine: Red blood cells 26–50/field (0–1) Hemoglobin 2+ albumin 1+ Ketone bodies 2+ | | Normal urine Functional stool: positive thevenon |
| Complete blood count | Leukocytes 13500 (5000–12000) Hb 13g/dl Lymphocytes 25% (40–56) | Leukocytes 11570 (4310–11000) Hb 11.1d/dl Lymphocytes 21% (15.5–56.6) | | Platelets 522000 (206000–369000) Rest within normal |
| SARS CoV 2 Detection | | SARS CoV 2 Antigen Negative SARS CoV 2 serology IgM antibodies negative Positive IgG antibodies Total Ant IgM/IgG 11.88 COI (0–0.99) | | |
| Liver Profile | | | Albumin 3.4g/dl (3.8–5.4) Proteins 5.7g/dl (6–8) Rest of normal liver profile | |
| Others | | | Creatinkinase MB 3.5 ng/ml (0.3–4.87) Procalcitonin negative Troponin T 0.001 ng/ml (0.001–0.014) Ferritin 131ng/ml (30–250) | |

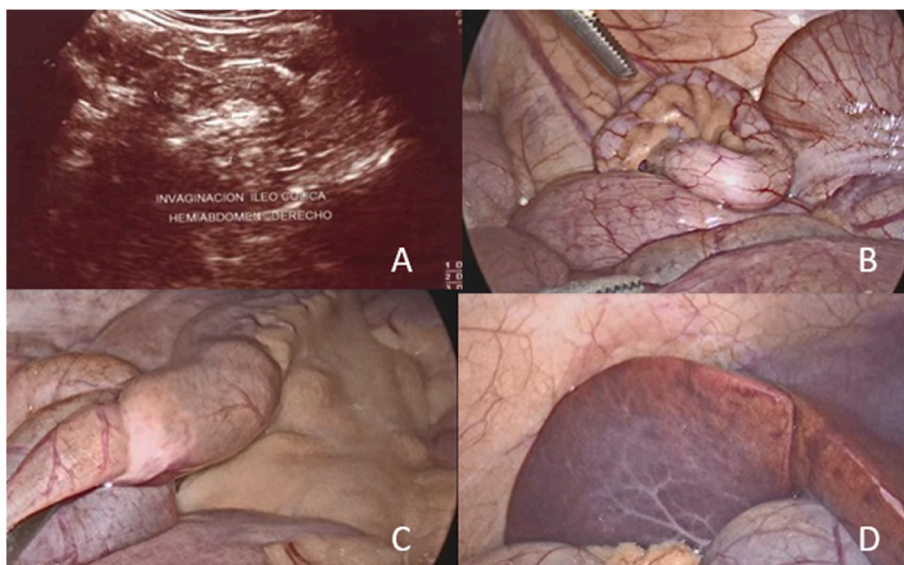


Fig. 1. A: Abdominal ultrasound showing image of intussusception; B: Appendix without significant alteration and distal ileum not invaginated; C: mesenteric adenitis found during laparoscopic exploration; D: Liver with changes in its usual coloration.

The generalized immune activation that exists during COVID-19 can cause hypertrophy of Peyer's patches [2], the virus binds to the angiotensin II converting enzyme and enters the cell of the intestinal tract, altering peristalsis and could cause invagination [8]. We believe that the mechanism by which our patient presented intussusception is the same as in the cases of infants reported to date, since despite being of school age, we did not find a mechanical cause, but we did find mesenteric adenitis.

The clinical picture was characterized by intermittent colicky abdominal pain, hyporexia, fever, vomiting and liquid stools. Some of the symptoms were present in the previous cases and although our patient did not present bloody stools, red blood cells were found in the stools and urine before surgery. Most of the cases published to date do report the presence of bloody stools and some report palpation of an abdominal mass, which was not found in our patient (Table 2).

The image of choice to reach the diagnosis of intussusception is ultrasound. In most of the reported cases, ultrasound has also been used and in other cases, radiography and tomography. On the other hand, although the treatment of choice is non-surgical reduction, we opted for exploratory laparoscopy as it is a useful and valid diagnostic and treatment option with fewer complications than laparotomy. In addition, we did not have the necessary resources to do an emergency pneumatic or hydrostatic reduction.

Most of the cases presented in the literature have been resolved non-surgical, others reached laparotomy after failure of non-surgical treatment, some performed laparotomy in the first instance and none attempted to resolve the case by laparoscopy.

4. Conclusion

In conclusion, in children with gastrointestinal symptoms, it is necessary to rule out an active or past COVID-19 infection and rule out the presence of associated invagination through ultrasound. If the diagnosis of intussusception is confirmed, laparoscopy offers a valuable method of treatment in our country, where resources such as ultrasound and/or fluoroscopy in emergency areas are not always available.

Despite the limitation that exists in the diagnosis of COVID-19 through a lateral flow immunochromatography and electrochemiluminescence test, the epidemiological link of relatives with a positive lateral flow immunochromatography test increases the probability that they have asymptomatic. Thus, we recommend ruling out past SARS-CoV-2 infection in children with intussusception.

Contributors

All the authors have participated in the conception and design of the article, data collection, writing, critical review of the article and approved the final version.

Funding

None.

Ethical approval and informed consent

We obtained the mother written informed consent to publish this clinical case including images and data reported.

Table 2
Summary of previous clinical cases described in the literature.

| Author | Age | Sex | COVID – 19 exposure | Duration of symptoms | Fever | Respiratory Symptoms | Abdominal Symptoms | Image/type of intussusception | Treatment and result |
|-----------------------------|----------------------|--------|----------------------------------|----------------------|------------|----------------------|---|---|---|
| Díaz-Ruiz et al. | 6 years | M | Yes | 2 days | Yes | No | Abdominal pain, vomiting, liquid stool, hyporexia. No palpable mass | Ultrasound, ileocolic | Laparoscopy, recovered |
| Bazuaye-Ekwuyasi et al. [2] | 9 months | M | Yes | 6 days | Yes | Yes | Abdominal pain, dark stools No palpable mass | Ileocolic | Hydrostatic reduction, recovered |
| Martínez-Castaño et al. [5] | 6 months | M | Yes | 2 days | No | No | Abdominal pain, vomiting, bloody stools. No palpable mass | Ultrasound, ileocecal | Hydrostatic reduction, recovered |
| Moazzam et al. [4] | 4 months | M | No | 2 days | No | Yes | Abdominal pain, bloody stools. Finding of palpable mass | Ileocecal | Pneumatic reduction, recovered |
| Cay et al. [2] | 10 months | F | No | 1.25 days | Yes | No | Vomiting, bloody stools. Does not specify palpable mass | X-ray, ultrasound, CT, does not specify | Pneumatic reduction. Then laparotomy. Died. |
| Makrinioti et al. [11] | 10 months | F | Yes | 2 weeks | | Yes | Vomiting, bloody stools. | Ultrasound | Failed pneumatic reduction, then laparotomy. Recovered |
| Rajalakshmi et al. [12] | 8 months | M | No | 2 days | Yes | No | Vomiting, bloody stools. Finding of palpable mass | Ultrasound ileocolic | Pneumatic reduction, recovered |
| Osorno et al. [1] | 8 months | M | | 3 days | Yes | | Abdominal pain, bloody stools. Finding of palpable mass | Ultrasound, ileocolic | Laparotomy: ileostomy. Recovered |
| Athamnah et al. [3] | 2.5 months | M | Mother with respiratory symptoms | | Yes | | Abdominal pain, vomiting, bloating abdominal, bloody stools | Ultrasound, ileocolic | Pneumatic reduction, recovered |
| Noviello et al. [6] | 7 months | M | Yes | 12 hours | No | | Abdominal pain, hyporexia, vomiting, drowsiness, bloody stools | Ultrasound, ileocolic | Failed nonsurgical treatment, then laparotomy (resection and anastomosis), recovered |
| Sullivan et al. [7] | 7 months | M | | 2 weeks | | | Intermittent abdominal pain | Ultrasound, ileocolic | Contrast enema reduction and discharge. Symptoms returns in the same way the next day, a CT scan is taken and ileoileal invagination is found. Resolved spontaneously and is discharged |
| Mercado-Martínez et al. [8] | 8 months 7 months | M F | | 2 days 1.5 days | Yes Yes | No Yes | Vomiting, bloody stools. No palpable mass | Ultrasound, ileocolic Radiography: dilated loops, air-fluid levels, no distal air. | Laparotomy: manual reduction, recovered Laparotomy: manual reduction, recovered |
| | | M | | | No | | Abdominal pain, bloody stools. Finding of palpable mass | Ileocolic | |

(continued on next page)

Table 2 (continued)

| Author | Age | Sex | COVID – 19 exposure | Duration of symptoms | Fever | Respiratory Symptoms | Abdominal Symptoms | Image/type of intussusception | Treatment and result |
|-----------------|----------|-----|---------------------|----------------------|-------|----------------------------------|--|-------------------------------|--------------------------------|
| Khan et al. [9] | 2 months | | | | | COVID-19, 3 weeks before illness | Abdominal pain, bloody stools, vomiting. | | Pneumatic reduction, recovered |

Declaration of competing interest

The authors declare that they have no known competing financial interests or personal relationships that could have appeared to influence the work reported in this paper.

References

- [1] Osorno JF, Giraldo M, Marin AF, Figueroa LM. Novel Coronavirus infection in an infant with intussusception. *Glob Pediatr Health* 2021;8. 2333794 X211012978.
- [2] Bazuaye-Ekwuyasi EA, Camacho AC, Saenz Rios F, Torck A, Choi WJ, Aigbivbalu EE, et al. Intussusception in a child with COVID-19 in the USA. *Emerg Radiol* 2020 Dec;27(6):761–4.
- [3] Athamnah MN, Masade S, Hamdallah H, Banikhaled N, Shatnawi W, Elmughrabi M, et al. COVID-19 presenting as intussusception in infants: a case report with literature review. *J Pediatr Surg Case Rep* 2021 Mar;66:101779.
- [4] Moazzam Z, Salim A, Ashraf A, Jehan F, Arshad M. Intussusception in an infant as a manifestation of COVID-19. *J Pediatr Surg Case Rep* 2020 Aug;59:101533.
- [5] Martínez-Castaño I, Calabuig-Barbero E, González -Piñera J, López-Ayala JM. COVID-19 infection is a diagnostic challenge in infants with ileocecal intussusception. *Pediatr Emerg Care* 2020 Jun;36(6):e368.
- [6] Noviello C, Bollettini T, Mercedes R, Papparella A, Nobile S, Cobellis G. COVID-19 can cause severe intussusception in infants: case report and literature review. *Pediatr Infect Dis J* 2021 Nov 1;40(11):e437–438.
- [7] Sullivan GA, Skertich NJ, Jones KB, Williams M, Gulack BC, Shah AN. An infant with COVID-19-associated intussusception. *Am Surg*. September 2021;22: 31348211047456.
- [8] Mercado-Martínez I, Arreaga-Gutiérrez FJ, Pedraza-Peña AN. Intussusception and SARS-CoV-2 infection. *J Pediatr Surg Case Rep* 2021 Apr;67:101808.
- [9] Khan S, Hartman L, Navarro YJS, Rossini CJ, Burdett C, Pennell C. Pediatric Covid-19 mesenteric lymphoid hyperplasia associated intussusception: a case report and literature review. *J Pediatr Surg Case Rep* 2021 Oct;73:101988.
- [10] Giovanni JE, Hrapcak S, Melgar M, Godfred -Cato S. Global reports of intussusception in infants with SARS-CoV-2 infection. *Pediatr Infect Dis J* 2021 Jan;40(1): 35–6.
- [11] Makrinioti H, MacDonald A, Lu X, Wallace S, Jobson M, Zhang F, et al. Intussusception in 2 children with severe acute respiratory syndrome Coronavirus-2 infection. *J Pediatric Infect Dis Soc* 2020 Sep 17;9(4):504–6.
- [12] Rajalakshmi L, Satish S, Nandhini G, Ezhilarasi S. Unusual presentation of COVID-19 as intussusception. *Indian J Practice Pediatr* 2020;22:236.