

The External Obturator Footprint Is a Usable, Accurate, and Reliable Landmark for Stem Depth in Direct Anterior THA

Georges Vles MD, PhD^{1,2}, Alexander Meynen MSc², Jef De Mulder MD¹, Stijn Ghijselings MD^{1,2}

Received: 11 December 2020 / Accepted: 9 April 2021 / Published online: 4 May 2021
Copyright © 2021 The Author(s). Published by Wolters Kluwer Health, Inc. on behalf of the Association of Bone and Joint Surgeons

Abstract

Background Previous CT and cadaver studies have suggested that the external obturator footprint might be used as a landmark for stem depth in direct anterior THA. Instructions on where to template this structure with small variability in height have been developed but have not been tested in daily clinical practice.

Questions/purposes In this study we sought to investigate the (1) usability, (2) accuracy, and (3) reliability of the external obturator footprint as a landmark for stem depth in direct anterior THA.

Methods The distance between the superior border of the external obturator tendon and the shoulder of the stem was

measured intraoperatively in all patients (n = 135) who underwent primary THA via a direct anterior approach performed by the senior author between November 2019 and October 2020. The landmark was considered useful when two of three evaluators agreed that the intersection of the vertical line comprised of the lateral wall of the trochanteric fossa and the oblique line formed by the intertrochanteric crest was clearly visible on the preoperative planning radiograph, and when the landmark was furthermore identified with certainty during surgery. Accuracy was defined as the degree of agreement (categorical for thresholds of 2 and 5 mm, the latter representing the threshold for developing unphysiological gait parameters) between the intraoperative distance and radiographic distance as measured on intraoperative fluoroscopy images or postoperative radiographs, which were calibrated based on femoral head sizes in a software program commonly used for templating. Intrarater reliability was defined as the degree of agreement (categorical for thresholds of 1 mm, which we considered an acceptable measurement error) between the ratings of one observer, who measured the radiographic distance on two different occasions separated by a washout period of at least 2 weeks. Interrater reliability was defined as the degree of agreement (categorical for thresholds of 1 mm, which we considered an acceptable measurement error) between the ratings of three observers with varying levels of experience (a fellowship-trained hip surgeon, a hip surgery fellow, and a medical student).

Results The landmark was considered useful in 77% (104 of 135) of patients who underwent direct anterior THA based on the observations that the trochanteric fossa was clearly visible on the planning radiograph in 117 patients and that the tendon was identified with certainty during surgery in 118 patients. There was good-to-excellent accuracy (intraclass correlation coefficient

Each author certifies that neither he or she, nor any member of his or her immediate family, has funding or commercial associations (consultancies, stock ownership, equity interest, patent/licensing arrangements, etc.) that might pose a conflict of interest in connection with the submitted article.

All ICMJE Conflict of Interest Forms for authors and *Clinical Orthopaedics and Related Research*® editors and board members are on file with the publication and can be viewed on request. Ethical approval for this study was obtained from University Hospitals Leuven, Leuven, Belgium (reference number: S63944). This study was registered in [Clinicaltrials.gov](https://clinicaltrials.gov) (reference number: NCT04623073).

This work was performed at University Hospitals Leuven – Gasthuisberg, Leuven, Belgium.

¹Division of Orthopaedic Surgery, Hip Unit, Gasthuisberg, University Hospitals Leuven, Leuven, Belgium

²Institute of Orthopaedic Research and Training, Gasthuisberg, University Hospitals Leuven/Catholic University of Leuven, Leuven, Belgium

G. Vles ✉, Division of Orthopedic Surgery – Hip Unit, Gasthuisberg, University Hospitals Leuven, Herestraat 49, 3000, Leuven, Belgium, Email: Georges.vles@uzleuven.be

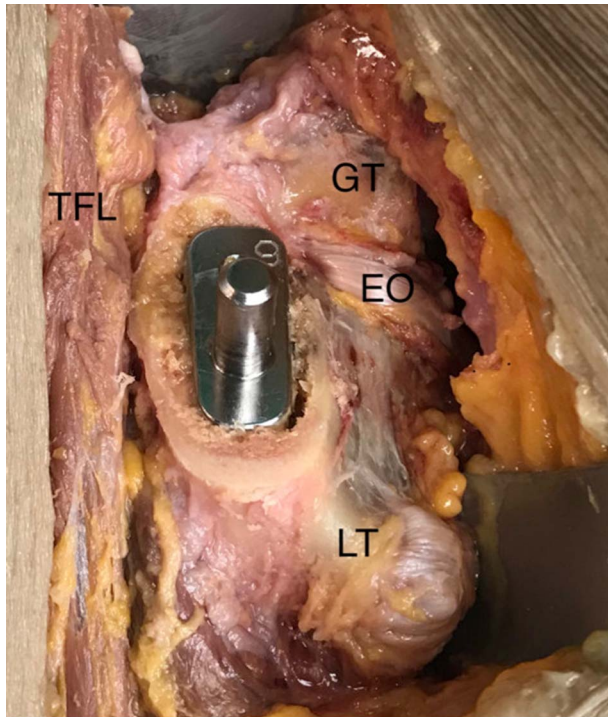


Fig. 1. This intraoperative photograph shows the superior border of the external obturator tendon and its position relative to the femoral broach in a cadaveric specimen; GT = greater trochanter; LT = lesser trochanter; TFL = tensor fascia latae; EO = external obturator.

0.75-087), and intrarater reliability (ICC 0.99) and inter-rater reliability (ICC 0.99) were both excellent.

Conclusion This clinical study showed that the external obturator footprint is a useful, accurate, and reliable landmark for stem depth in direct anterior THA.

Clinical Relevance The external obturator landmark allows the surgeon to position the stem within a range of the templated depth that is beneath the threshold for the development of unphysiological gait parameters. Although strictly speaking it was found useful in 77% of patients in this study, we found that this percentage of usability can easily be improved to around 90% by providing the radiology lab technician with instructions to correct external rotation of the foot during the taking of the planning radiograph. Future studies could compare the established (in)equality in leg length in patients using the external obturator landmark with computer-assisted surgery.

Introduction

Recent studies have discovered that the external obturator footprint (Fig. 1) might be used as a landmark for the stem depth in direct anterior THA [12, 13]. Using two-dimensional (2D) and three-dimensional (3D) anatomic mapping of cadaveric specimens, we were able to illustrate that the inferior border of this tendon's footprint can reliably be found on a conventional radiograph at the intersection of the vertical line composed of the lateral wall of the trochanteric fossa and the oblique line formed by the intertrochanteric crest [13]. Using 200 CT scans, Rüdiger et al. [12] concluded that the footprint displays only small variability in height: 6.4 ± 1.4 mm. These two findings, together with the fact that the superior border of the external obturator can easily be seen during femoral

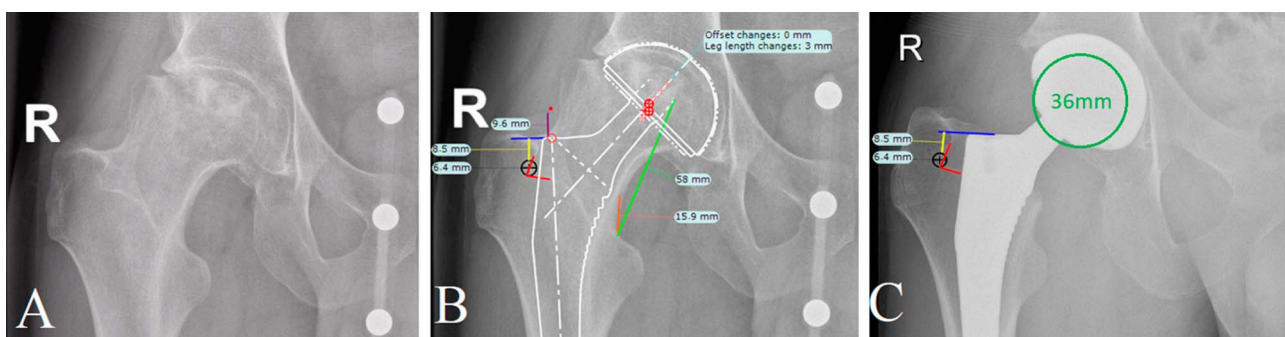


Fig. 2. A-C (A) This preoperative planning radiograph of the right hip including an adjustable Kingmark (Brainlab) calibration device is from a 25-year-old man with Association Research Circulation Osseous classification Stage IIIb avascular necrosis of both femoral heads who had undergone chemotherapy for acute myeloid leukemia. (B) The distance (yellow line: 8.5 mm) between the shoulder of the stem (blue line) and the upper border of the external obturator footprint (black circle) in the trochanteric fossa (red lines) can be used for intraoperative guidance regarding the stem depth. Other frequently used landmarks and distances are illustrated as well (purple, orange, and green lines). (C) A postoperative AP pelvic radiograph shows the result of THA via a direct anterior approach. Visibility of the trochanteric fossa allowed us to examine the distance (yellow line: 8.5 mm) between the shoulder of the stem (blue line) and the upper border of the external obturator footprint (black circle) in the trochanteric fossa (red lines), which corresponded well to the distance of 9 mm measured intraoperatively.

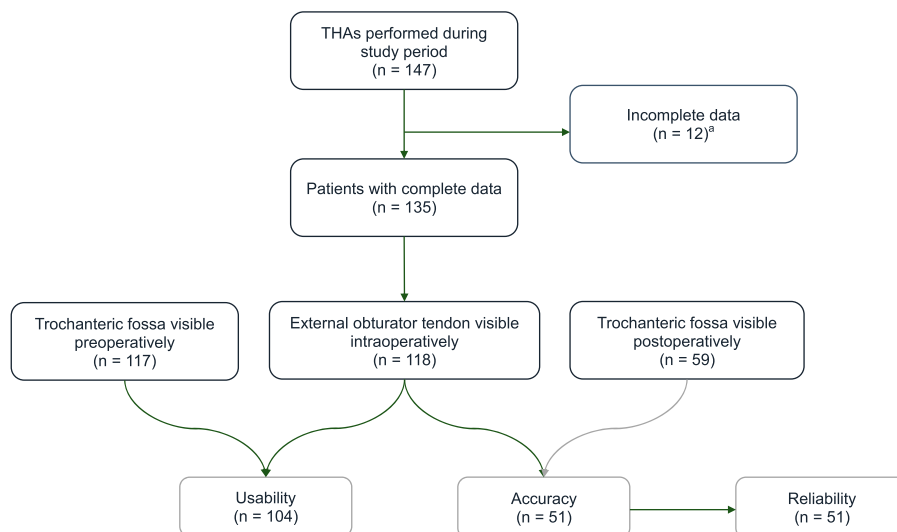


Fig. 3. This flowchart shows the number of patients available per phase. ^aFor patients with incomplete data, it was unclear from the surgical notes whether the measured distance indicated that the shoulder of the stem was proximal or distal to the external obturator tendon.

preparation in direct anterior THA, allow templating of this anatomic structure on a preoperative planning radiograph of the pelvis (Fig. 2). The distance between the templated shoulder of the stem and the superior border of the external obturator footprint (hereafter known as the radiographic distance) can be used intraoperatively to guide the stem depth (hereafter known as the intraoperative distance).

Landmarks for stem depth in direct anterior THA are limited. The greater trochanter is covered by the lateral capsule and is not in the same plane as the stem. It is impossible to see and sometimes even to feel the lesser trochanter as it is located posteriorly on the femur. With the absence of these traditional landmarks, the external obturator footprint has the potential to be a valuable landmark for surgeons using the direct anterior approach, but to our knowledge, there are no data on its clinical application. In particular, data on usability, accuracy, and reliability are needed to assess the utility of this new landmark.

We therefore sought to investigate the (1) usability, (2) accuracy, and (3) reliability of the external obturator footprint as a landmark for the stem depth in direct anterior THA in daily clinical practice.

Patients and Methods

Study Design and Setting

This study was designed as a fresh analysis of longitudinally maintained data of patients who underwent THA via the direct anterior approach.

Patients

All patients who underwent primary THA via the direct anterior approach between November 2019 and October 2020 were eligible for inclusion (Fig. 3). Exclusion criteria were the unavailability of preoperative or postoperative pelvic radiographs and missing or incomplete documentation about the external obturator footprint in the patient's surgical notes. In total, 147 patients underwent a THA via a direct anterior approach, but 8% (12) of patients were excluded as it was unclear from the surgical notes whether the measured distance indicated that the shoulder of the stem was proximal or distal to the external obturator tendon. Images were available for all patients. Fifty-one patients were available for assessment of accuracy and reliability because in these patients the trochanteric fossa remained visible on the postoperative radiograph and was not obscured by the radiopaque stem.

Demographics

We included 135 patients (66 female; 69 male) with a mean age of 66 ± 12 years, height of 170 ± 9 cm, and weight of 80 ± 15 kg. Indications for joint arthroplasty included osteoarthritis (84% [114 of 135]), avascular necrosis (9% [12 of 135]), post-traumatic sequelae (4% [5 of 135]), focal cartilage defects (1% [2 of 135]), Paget disease (1% [1 of 135]), and inflammatory arthritis (1% [1 of 135]). The mean neck-shaft angle was $130^\circ \pm 6^\circ$, and nine and 17 patients had varus ($< 120^\circ$) and valgus hip ($> 135^\circ$)

morphology, respectively. The median (range) implanted cup and stem sizes were 54 (Pinnacle cup, DePuy Synthes [48-60]) and 12 (Corail stem, DePuy Synthes [9-16]), respectively. All the demographics and characteristics showed no differences when comparing the group of patients where the trochanteric fossa remained visible and the group of patients where the trochanteric fossa was obscured by the stem after implantation (see Supplemental Table 1; Supplemental Digital Content 1, <http://links.lww.com/CORR/A565>).

Description of Surgical Technique

The surgeon in this series (SG) performs direct anterior THA with the patient in the supine position on a carbon-fiber operating table that he does not break, which is a technique some surgeons use to facilitate femoral exposure [15]. The following summarizes our steps after the cup has been implanted. The inferior capsule at the level of the calcar and superolateral capsule are routinely released. The femur is exposed using a blunt bone hook and a curved double-spiked retractor between the gluteal tendons and femur. The leg is placed in a figure-of-four position underneath the contralateral leg. The femoral canal is opened and broached sequentially. At this point, the superior border of the external obturator tendon is identified (Fig. 1). It might already be exposed or it may require minimal dissection, which usually does not involve more than rubbing some overlying fat away with a gauze and forceps. A trial reduction is performed, followed by a clinical evaluation of leg length and stability and a fluoroscopic evaluation of the stem's position. Once the stem position is satisfactory, the definitive stem is implanted and the distance between the shoulder of the prosthesis and the superior border of the external obturator tendon is determined using a sterile measuring rod. The intraoperative distance and the process of identifying the external obturator tendon are routinely documented in the surgical notes (A: no dissection required, B: minimal dissection required, C: not sure, D: not found). If the shoulder of the stem is proximal to the tendon, the distance is considered positive and vice versa.

Variables and Outcome Measures

In this study, we aimed to investigate the usability, accuracy, and reliability of the external obturator footprint as a landmark for the stem depth in direct anterior THA in daily clinical practice (Fig. 3).

We defined usability as the percentage of patients who met both of the following two criteria. First, the lines of the trochanteric fossa needed to be clearly visible on the

preoperative planning radiograph (which contained the adjustable Kingmark[®] [Brainlab] calibration device) so that the external obturator footprint could be templated effectively. This criterion was met if at least two of three observers (GV, SG, JDM) agreed this was true (Fig. 2B). Second, the external obturator footprint needed to be identified with certainty intraoperatively.

We defined accuracy as the degree of agreement (categorical yes/no) between the intraoperative distance and the radiographic distance as measured on intraoperative fluoroscopy images or postoperative radiographs, using thresholds of 2 and 5 mm as acceptable. Two millimeters is what we pursue for our patients, and 5 mm is the threshold for the development of unphysiological gait parameters [11]. The latter distance can only be determined if the trochanteric fossa is not obscured by the radiopaque stem. For these patients, their images were uploaded to TraumaCad[®] (Brainlab) and calibrated using their 32-mm or 36-mm femoral heads (Fig. 2C). Next, the distance between the presumed superior border of the external obturator footprint and the shoulder of the stem was measured according to the previously explained methodology.

Intrarater reliability was defined as the degree of agreement (categorical yes/no for thresholds of 1 mm) between the ratings of one observer (GV), who measured the radiographic distance on two different occasions separated by a washout period of at least 2 weeks. Interrater reliability was defined as the degree of agreement (categorical yes/no for thresholds of 1 mm) between the ratings of a senior hip surgeon (SG), a hip surgery fellow (GV), and a medical student (JDM). At no point were the observers aware of the distances measured intraoperatively.

Ethical Approval

This study was approved by our ethical review board (University Hospitals Leuven; approval number S63944). The full details of the design of this study were registered at clinicaltrials.gov (NCT04623073) in advance.

Statistical Analysis

All data were entered into Statistical Package for the Social Sciences, version 26.0 (IBM Corp). Means, medians, SDs, and ranges were calculated using descriptive statistics. Normal distribution of the intraoperative and radiographic distances was assessed using the Shapiro-Wilk test. A stepwise logistic regression analysis was performed to identify possible factors associated with lower usability and accuracy. Odds ratios and associated 95% confidence intervals were reported for each identified factor. Accuracy, intrarater reliability, and interrater reliability

were calculated using intraclass correlation coefficients [8]. ICCs were calculated for a range of acceptable differences (1-5 mm). Measurements within the acceptable difference were considered equal in the ICC calculation. During the interrater reliability calculation, differences were only considered equal if the measurements of all raters were lower than the acceptable difference. Interpretation of the ICC is based on the more strict criteria described by Koo and Li [4], where values less than 0.50, 0.50-0.75, 0.75-0.90, and more than 0.90 are considered poor, moderate, good, and excellent, respectively.

Results

Clinical Usability

Observers agreed that the outline of the trochanteric fossa was clearly visible in 87% (117 of 135) of patients when they had only access to the preoperative Kingmark planning radiographs, which is taken supine.

In two patients, the trochanteric fossa was compromised by previous trauma (surgery).

The external obturator tendon was identified intraoperatively without any or minimal dissection in 87% (118 of 135) of patients. In the remaining 13% (17 of 135), the external obturator was not found. Binary logistic regression analysis showed that this was associated with higher BMI (OR 0.953 [95% CI 0.92 to 0.99]; $p = 0.011$) and non-osteoarthritic etiology as an indication for joint arthroplasty (OR 22.32 [95% CI 2.83 to 175.74]; $p = 0.006$).

Overall, in 104 of 135 patients, both the preoperative radiographic distance and the intraoperative distance could be determined, resulting in a usability of 77%.

Clinical Accuracy

There was good agreement (mean ICC 0.75 [95% CI 0.59 to 0.86]) between the intraoperative distance and radiographic distance when a difference of only 2 mm was considered acceptable (Fig. 4). Using the threshold of 5 mm for the development of unphysiologic gait parameters, ICCs approached excellent agreement (mean ICC 0.87 [95% CI 0.77 to 0.93]) [11]. No factors were associated with lower accuracy in the stepwise logistic regression analysis.

Clinical Reliability

There was excellent intrarater reliability (ICC 0.99 [95% CI 0.98 to 0.99]) and interrater reliability (ICC 0.99 [95% CI 0.98 to 0.99]) if a measuring inaccuracy of 1 mm was considered acceptable. This indicates that observers with a

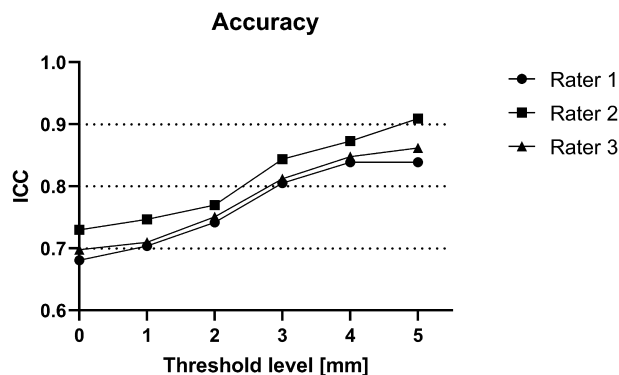


Fig. 4. This graph shows the intraclass correlation coefficients between the intraoperative distance and radiographic distance per rater for varying levels of acceptable differences (threshold).

broad spectrum of experience template the external obturator landmark with high consistency.

Other Relevant Findings

Currently, many direct anterior hip surgeons teach their fellows/registrars the adage that if the shoulder of the stem is close to the external obturator footprint, they cannot be far away from achieving equal leg length. Our data show that in 11% (13 of 118) of the implanted stems, the shoulder was not within 3 mm of the upper border of the external obturator footprint, underlining the importance of templating and appreciating differences in hip morphology and neck-shaft angle options of modern stems.

Discussion

Although leg-length discrepancy after THA is a common source of patient dissatisfaction and litigation [1], there are only a handful of studies on the accuracy and reliability of the landmarks we rely on daily [3, 7]. In our opinion, the key tool in preventing a clinically important leg-length discrepancy is the availability of a landmark that is visible on both a preoperative planning radiograph and during stem implantation. This study provides data that show that the external obturator footprint is a usable, accurate, and reliable landmark for stem depth in direct anterior THA.

Limitations

This study has limitations. First, we propose a landmark for stem depth in direct anterior THA but do not report clinical or radiological measurements of leg length. However, it was

not the intent of this study to prove that templating in general helps with reducing leg-length discrepancies. Instead, our main goal was to show that the distance between the superior border of the external obturator footprint and the shoulder of the stem as measured intraoperatively corresponds well to the distance measured on a postoperative radiograph where the presumed insertion of the external obturator tendon into the trochanteric fossa is templated. With this knowledge, it is now indeed possible to conduct a subsequent study where the surgeon stringently follows the template and investigates the results in terms of leg length. However, one must realize that there can be reasons to deviate from the templated plan for stem depth, the most obvious being accepting a slightly longer leg to solve instability at the hip or when having to compensate for a cup that was positioned slightly higher than templated.

Secondly, 62% (84 of 135) of postoperative radiographs did not allow us to evaluate the radiographic distance because the trochanteric fossa was obscured by the radiopaque stem. There is currently no method to remedy this. However, it is unlikely that it influenced the results given that no differences were found for a large set of items between the group of patients where the trochanteric fossa remained visible and the group of patients where the trochanteric fossa was obscured by the stem after implantation (see Supplemental Table 1; Supplemental Digital Content 1, <http://links.lww.com/CORR/A565>).

Thirdly, so far this methodology has only been clinically evaluated at one of the institutions where it was designed, and we would encourage other groups to perform similar studies to confirm or negate our results.

Clinical Usability

In this study, we found that the external obturator landmark was available in 77% of patients. We also found that this number can easily be increased to approximately 90% if attention is paid to the position of the affected leg during supine, calibrated radiography of the pelvis.

The outline of the trochanteric fossa becomes less visible with more external rotation of the hip, which is a position preferred by most patients with endstage osteoarthritis [10]. Looking at previous standing, noncalibrated radiographs of patients in whom the trochanteric fossa was not visible on the Kingmark planning radiograph, we found that it had already been visible in virtually all cases. Since we have provided our radiology lab technician with some simple instructions to correct excessive external rotation of the foot in the supine position, we are able to template the external obturator landmark without exception. Furthermore, surgeons should be aware that they might not be able to rely on the external obturator landmark in patients with higher BMI. Especially in younger men with well-developed musculature and older men with a stiff and contracted posterior

capsule, the external obturator tendon might be partially released when attempting to improve the femoral exposure, and in such circumstances, it would no longer be usable for the purpose of determining stem-depth insertion. Additionally, in some patients, the trochanteric fossa will have been used previously as an entry point for intramedullary nailing, and in such patients, this landmark can therefore be absent. However, one must realize that the assumption that other landmarks and methods can be used virtually 100% of the time is incorrect [3]. All traditional landmarks for stem depth are in a way based on the greater and lesser trochanter, which are severely compromised when using the direct anterior approach. We considered measuring distances from the stem to the greater and lesser trochanter; however, we stopped doing this as the measurements turned out to be arbitrary. We believe the external obturator landmark is valuable as (1) its usefulness was proposed on the basis of an extensive CT study showing very small variability in height [12], (2) templating guidelines have been developed on the basis of 2D and 3D anatomical mapping studies in cadavers [13], and (3) it has been demonstrated to be usable, accurate, and reliable in this clinical follow-up study.

Clinical Accuracy and Reliability

Probably the most important result of this study is the high agreement between the intraoperative distance and the radiographic distance, regardless of the observer's level of experience. This indicates that the proposed methodology allows the surgeon to position the stem within that range of the templated depth with high accuracy and consistency. This is well within the acceptable reported range [9, 5].

Conclusion

This study evaluated the clinical use of the external obturator footprint for guiding the stem depth in direct anterior THA. Key findings are that this landmark can be used in most patients and is highly accurate and reliable. We encourage direct anterior hip surgeons to template this structure on the preoperative planning radiograph and verify the distance between its upper border and the shoulder of the stem intraoperatively. Future studies are needed to confirm our results and also to compare our methodology to, for example, computer-assisted surgery [2, 6, 14, 16].

This is an open-access article distributed under the terms of the [Creative Commons Attribution-Non Commercial-No Derivatives License 4.0 \(CCBY-NC-ND\)](https://creativecommons.org/licenses/by-nc-nd/4.0/), where it is permissible to download and share the work provided it is properly cited. The work cannot be changed in any way or used commercially without permission from the journal.

Acknowledgments We thank Prof. dr. Geert Molenberghs (biostatistics) for his help with the statistical analysis.

References

1. Bolink SAAN, Lenguerrand E, Brunton LR, et al. The association of leg length and offset reconstruction after total hip arthroplasty with clinical outcomes. *Clin Biomech.* 2019;68:89-95.
2. Kayani B, Konan S, Thakrar RR, Huq SS, Haddad FS. Assuring the long-term total joint arthroplasty: a triad of variables. *Bone Joint J.* 2019;101:11-18.
3. Kim JI, Moon NH, Shin WC, Suh KT, Jeong JY. Reliable anatomical landmarks for minimizing leg-length discrepancy during hip arthroplasty using the lateral transgluteal approach for femoral neck fracture. *Injury.* 2017;48:2548-2554.
4. Koo TK, Li MY. A guideline of selecting and reporting intraclass correlation coefficients for reliability research. *J Chiropr Med.* 2016;15:155-163.
5. Loughenbury FA, McWilliams AB, Stewart TD, Redmond AC, Stone MH. Hip surgeons and leg length inequality after primary hip replacement. *HIP Int.* 2019;29:102-108.
6. Manzotti A, Cerveri P, De Momi E, Pullen C, Confalonieri N. Does computer-assisted surgery benefit leg length restoration in total hip replacement? Navigation versus conventional freehand. *Int Orthop.* 2011;35:19-24.
7. Marcucci M, Indelli PF, Latella L, Poli P, King D. A multimodal approach in total hip arthroplasty preoperative templating. *Skeletal Radiol.* 2013;35:19-24.
8. McGraw KO, Wong SP. Forming inferences about some intraclass correlation coefficients. *Psychol Methods.* 1996;1:30-46.
9. McWilliams AB, Grainger AJ, O'Connor PJ, Redmond AC, Stewart TD, Stone MH. A review of symptomatic leg length inequality following total hip arthroplasty. *HIP Int.* 2013;3:6-14.
10. Metcalfe D, Perry DC, Claireaux HA, Simel DL, Zogg CK, Costa ML. Does this patient have hip osteoarthritis? The rational clinical examination systematic review. *J Am Med Assoc.* 2019;322:2323-2333.
11. Renkawitz T, Weber T, Dullien S, et al. Leg length and offset differences above 5 mm after total hip arthroplasty are associated with altered gait kinematics. *Gait Posture.* 2016;49:196-201.
12. Rüdiger HA, Fritz B, Impellizzeri FM, Leunig M, Pfirrmann CW, Sutter R. The external obturator footprint as a landmark in total hip arthroplasty through a direct anterior approach: a CT-based analysis. *HIP Int.* 2019;29:96-101.
13. Vles G, Roussot M, Haddad F. *Robotic Arm Assisted Total Hip Arthroplasty Using a Posterolateral Approach: Surgical Technique.* Ed Minerva Medica; 2020:29-40.
14. Vles G, van Eemeren A, Taylan O, Scheys L, Ghijselings S. Anatomical mapping of the external obturator footprint: a study in cadavers with implications for direct anterior THA. *Clin Orthop Relat Res.* 2021;479:288-294.
15. Vles GF, Corten K, Driesen R, van Elst C, Ghijselings SG. Hidden blood loss in direct anterior total hip arthroplasty: a prospective, double blind, randomized controlled trial on topical versus intravenous tranexamic acid. *Musculoskelet Surg.* Published online March 10, 2020. DOI: [10.1007/s12306-020-00652-0](https://doi.org/10.1007/s12306-020-00652-0).
16. Weber M, Thieme M, Kaiser M, et al. Accuracy of leg length and offset restoration in femoral pinless navigation compared to navigation using a fixed pin during total hip arthroplasty. *Biomed Res Int.* Published online June 25, 2018. DOI: [10.1155/2018/1639840](https://doi.org/10.1155/2018/1639840).
17. Yoon BH, Mont MA, Koo KH, et al. The 2019 revised version of association research circulation osseous staging system of osteonecrosis of the femoral head. *J Arthroplasty.* 2020;35:933-940.