

# Digital Image Analyses of Preoperative Simulation and Postoperative Outcome following Blepharoptosis Surgery

Xiaodong Zheng, MD, PhD\*†  
 Hiroko Yamada, MD\*  
 Tomoyuki Kamao, MD, PhD\*  
 Tomoko Goto, MD, PhD†  
 Atsushi Shiraiishi, MD, PhD\*

**Background:** Before blepharoptosis surgery, simulation of eyelid features, including lid height and crease position, is often performed. However, discrepancies of the simulation and outcome can occur. The purpose of this study was to analyze the pre- and postoperative images and to evaluate factors contributing to the discrepancies.

**Methods:** Forty-one involuntional blepharoptosis patients ( $68.2 \pm 7.1$  years) underwent levator aponeurosis advancement. A semicircular bent wire was used to push the preoperative ptotic eyelid up to simulate the postoperative appearance of the eyelid. Digital images of the simulation were compared with the appearance at 3 months after the surgery. The ImageJ software was used to analyze the pre- and postoperative margin reflex distance-1 (MRD-1), pretarsal show (PTS), fissure height (FH), and ocular surface area (OSA). Factors with a potential of affecting the predictability of simulation were determined.

**Results:** During simulation, the MRD-1 was  $3.6 \pm 0.4$  mm, the PTS was  $3.48 \pm 1.2$  mm, the FH was  $8.5 \pm 0.9$  mm, and the OSA was  $120.7 \pm 22.3$  mm<sup>2</sup>. After the surgery, the corresponding values were  $3.3 \pm 1.2$  mm,  $3.3 \pm 1.5$  mm,  $8.6 \pm 1.4$  mm, and  $119.1 \pm 25.1$  mm<sup>2</sup>, respectively. The postoperative MRD-1 was significantly smaller than that of the simulation ( $P = 0.005$ , paired *t* test). The MRD-1 simulation error was positively correlated with the length and width of the skin resection (all  $P < 0.05$ ), and the PTS error was positively correlated with the length of the skin resection ( $r = 0.332$ ,  $P = 0.031$ ) and negatively correlated with the preoperative OSA ( $r = -0.588$ ,  $P = 0.007$ ).

**Conclusions:** The postoperative appearance of the eyelid can be simulated fairly accurately by pushing up the upper eyelid with a curved wire. However, the MRD-1 tended to be overestimated, especially for cases requiring a large skin resection. (*Plast Reconstr Surg Glob Open* 2020;8:e2923; doi: [10.1097/GOX.0000000000002923](https://doi.org/10.1097/GOX.0000000000002923); Published online 16 June 2020.)

## INTRODUCTION

Involuntional blepharoptosis is an age-related abnormal drooping of the upper eyelid that is present when the eye is in the primary position. The incidence of involuntional blepharoptosis is increasing due to an increase in the

aged population and also by the increase in the number of older, long-time contact lens wearers.<sup>1</sup> The thinning of the aponeurosis and/or a disinsertion of the levator muscle are believed to be the mechanisms for blepharoptosis. The problems associated with blepharoptosis are not only its negative cosmetic effect but also its negative effect on the quality of vision and on the quality of life.<sup>2,3</sup> Evidence has been accumulating on the negative changes, including the reduction in the size of the visual field, alterations of the corneal topography, and decrease in the contrast sensitivity in patients with blepharoptosis.<sup>4</sup>

Advancement of the levator aponeurosis is the most commonly used procedure to effectively treat involuntional blepharoptosis.<sup>5,6</sup> A restoration of the upper visual field and an improvement and rejuvenation of the facial

From the \*Department of Ophthalmology, Ehime University School of Medicine, Toon City, Ehime, Japan; and †Hanamizuki Eye Clinic, Matsuyama, Ehime, Japan.

Received for publication February 12, 2020; accepted April 23, 2020.

Copyright © 2020 The Authors. Published by Wolters Kluwer Health, Inc. on behalf of The American Society of Plastic Surgeons. This is an open-access article distributed under the terms of the [Creative Commons Attribution-Non Commercial-No Derivatives License 4.0 \(CCBY-NC-ND\)](https://creativecommons.org/licenses/by-nc-nd/4.0/), where it is permissible to download and share the work provided it is properly cited. The work cannot be changed in any way or used commercially without permission from the journal.

DOI: [10.1097/GOX.0000000000002923](https://doi.org/10.1097/GOX.0000000000002923)

**Disclosure:** The authors have no financial interest to declare in relation to the content of this article.

appearance after the surgery are greatly appreciated by the patients. The most appreciated cosmetic changes following blepharoptosis surgery are the elevation of the upper eyelid as quantified by the increase in the margin reflex distance (MRD-1) and the formation of the upper eyelid crease known as a double eyelid crease, which can be quantified by the pretarsal show (PTS).<sup>7,8</sup>

As in other facial surgeries, preoperative planning and simulation is essential for accurate and optimal outcomes.<sup>9–11</sup> Before blepharoptosis surgery, an oculoplastic surgeon often lifts up the ptotic eyelid to simulate what the postoperative eyelid appearance would be, that is, the improvements of the postoperative MRD-1 and PTS. This simulation can help the physician explain the surgical procedures and to present an expected appearance after the blepharoptosis surgery to the patient. However, discrepancies between the preoperative simulated appearance and the postoperative outcome can occur, which will disappoint both the patients and surgeons. Thus, knowing the preoperative factors that can affect the postoperative outcome is important.

Rosser et al<sup>12</sup> has reported a “paper-clip technique” for upper eyelid skin crease assessment. The bent paper clip is used to push into the lid for desired eyelid height and skin crease position before a number of eyelid procedures including blepharoplasty. Although, this technique is commonly used by many oculoplastic surgeons, to the best of our knowledge, there has not been a report documenting the predictability of the preoperative simulations, and none of the earlier studies have focused on analyses of the factors contributing to the discrepancies between the simulated image and the outcome appearance.

We have previously reported on the use of digital image analyses with the ImageJ software (NIH, Bethesda, Md.) on patients before and after blepharoptosis surgery.<sup>13</sup> This method is quantitative and feasible for evaluating the eyelid features before and after surgery. The purpose of this study was to quantitatively compare the values of the different parameters of the preoperative simulated image of the eye to those of the same parameters in the postoperative images. To accomplish this, we measured the MRD-1, PTS, fissure height (FH), and the ocular surface area (OSA) in the preoperative simulated images and the postoperative images at 3 months after the blepharoptosis surgery.

## PATIENTS AND METHODS

### Subjects

Forty-one patients with a mean age of  $68.2 \pm 7.1$  years and a range of 52 to 89 years were studied. All had been diagnosed with bilateral involutional blepharoptosis between March 2019 and November 2019 at the Hanamizuki Eye Clinic or the Department of Ophthalmology, Ehime University Hospital. Patients with an MRD-1 < 2.5 mm were included. The exclusion criteria were corneal changes that precluded accurate measurements of the eyelid parameters, current use of oral or topical sympathomimetic drugs, prior eyelid surgery, other types of ptosis, for example, congenital, traumatic, or mechanical, and any types of myopathies.

All subjects were informed on the procedures to be used and the possible complications, and an oral or signed informed consent was obtained. This study was approved by the Ethics Committee of Hanamizuki Eye Clinic and Ehime University Hospital. This study adhered to the ethical principles outlined in the Declaration of Helsinki as amended in 2013.

### Preoperative Eyelid Simulation

Preoperative simulation of the expected postoperative appearance of the eyelids was performed by using the inner guide wire of a lacrimal tube (Nunchaku 105, FCI; Zeiss, Tokyo, Japan), which was bent to a semicircular shape to conform to the shape of the upper eyelid. The wire was placed at the estimated incision line, approximately 5–7 mm above the eyelid margin, and used to push the ptotic upper eyelid up to simulate the postoperative lid crease and eyelid features. The excess skin was also lifted by tapping when necessary (Fig. 1).

### Surgical Procedures

All patients underwent standard bilateral levator aponeurosis advancement by the same surgeon (X.Z.). In brief, an incision was made at 5–7 mm above the upper eyelid margin. Redundant skin was resected when necessary. The subcutaneous tissue was dissected, and the levator aponeurosis was isolated and advanced by 8–10 mm using 6-0 Asflex suture (polyvinylidene fluoride; CROWNJUN KONO Co., Ltd, Ichikawa, Chiba, Japan). The upper eyelid margin was set to be about 1 mm lower than the upper limbus of the cornea when the subject was in a sitting position. Preorbital fat was resected when necessary. Continuous sutures were used to close the incision. Antibiotic ointment was applied twice a day on the wound for 2 weeks. All subjects were examined on the first day after the surgery and again 1 week later. The sutures were removed at 1 week after the surgery.

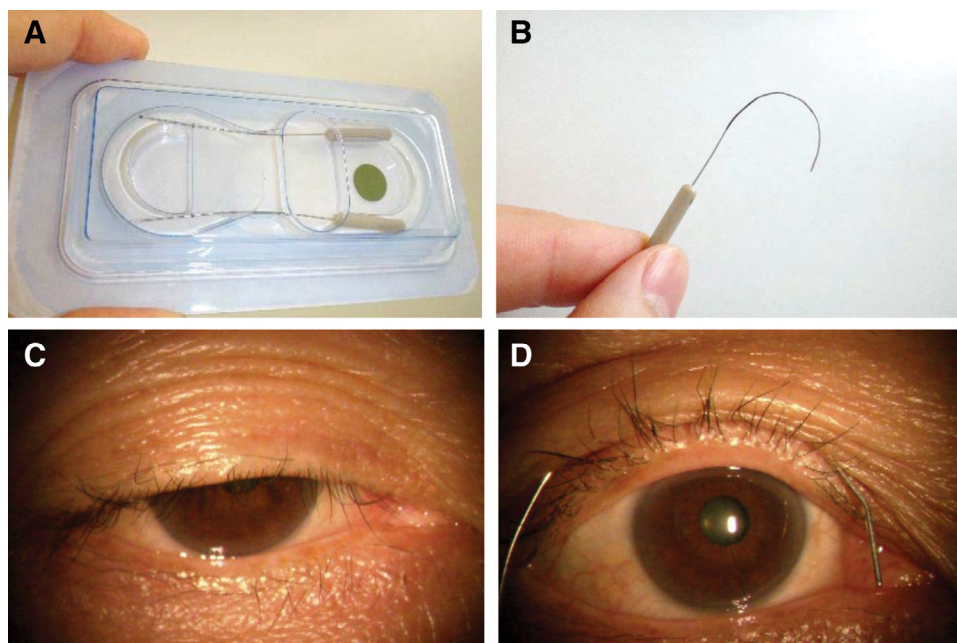
### Digital Image Analysis

Frontal facial photographs were taken preoperatively and at 3 months postoperatively with the eyes in the primary position and the patient in a sitting position. The preoperative photographs included one with the eyelids in the normal position and one simulated image. A Nikon 5500 digital camera (Nikon, Tokyo, Japan) with strobe light was used. The digital images were transferred to a personal computer and analyzed with the ImageJ software (version 1.45; NIH), with the Java platform version 1.6.<sup>13</sup>

The following parameters were measured and evaluated: the MRD-1, the distance between upper eyelid margin and corneal light reflex; PTS, the distance between the upper eyelid margin and lid crease; FH, the distance between the center of upper and lower eyelid margins; and OSA, the area surrounded by the upper and lower margins of the eyelid, which was manually traced, and the area was automatically calculated by the ImageJ software (Fig. 2). The measurements were performed by 2 of the authors (X.Z., T.G.), and the average was used for statistical analysis.

### Statistical Analyses

Data are expressed as the means  $\pm$  SDs. The significance of the differences between the simulated values and



**Fig. 1.** Preoperative simulation of the upper eyelid appearance after blepharoptosis surgery. The inner wire of a lacrimal tube (A) was bent to a semicircle (B). The ptotic eyelid (C) was pushed up by the wire at the line selected for the eyelid crease to simulate the postoperative eyelid appearance (D).

the postoperative values were determined by paired *t* tests. A  $P < 0.05$  was taken to be significantly significant.

## RESULTS

### Outcome of Levator Aponeurosis Advancement Surgery

All patients underwent uneventful surgery. No complications were noted during or after the surgery. No reoperation was needed for all subjects during the observation period.

### Reliability of Image Analysis

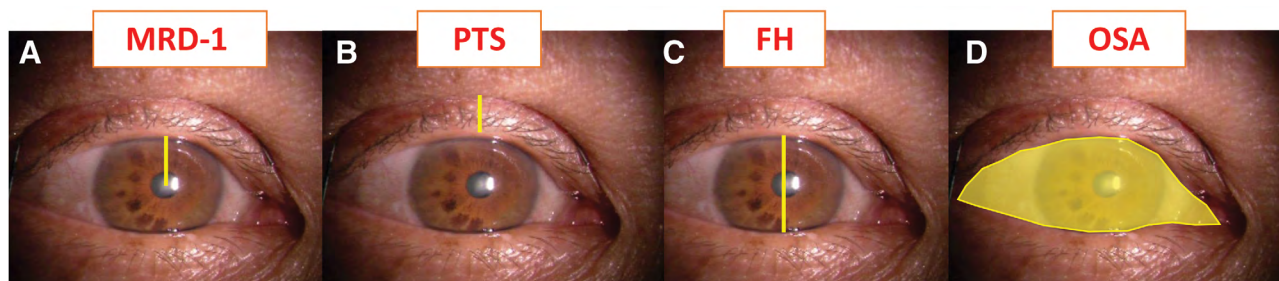
The reliability of ImageJ analysis of the eyelid features was evaluated by calculating the intra/interclass correlation coefficients for all parameters measured. The intra/interclass correlation coefficients ranged from 0.944 to 0.998, indicating a very high reliability of the measurements. A representative result for OSA is shown in Table 1.

### Predictability of Preoperative Simulation

Before surgery, the simulated MRD-1 was  $3.6 \pm 0.4$  mm, PTS was  $3.48 \pm 1.2$  mm, FH was  $8.5 \pm 0.9$  mm, and OSA was  $120.7 \pm 22.3$  mm<sup>2</sup>. After the surgery, the MRD-1 was  $3.3 \pm 1.2$  mm, the PTS was  $3.3 \pm 1.5$  mm, the FH was  $8.6 \pm 1.4$  mm, and the OSA was  $119.1 \pm 25.1$  mm<sup>2</sup>. The simulated MRD-1 was significantly larger than postoperative MRD-1 ( $P = 0.005$ , paired *t* test). The simulated PTS ( $P = 0.233$ ), FH ( $P = 0.699$ ), and OSA ( $P = 0.378$ ) were not significantly different from the corresponding postoperative values (paired *t* tests).

### Factors Related to Simulation Errors of MRD-1 and PTS

Correlation analyses were performed to determine the factors that were related to the simulation error of MRD-1 (difference between the simulation and outcome values). Possible factors included the length and width of skin resection, preoperative OSA, preoperative MRD-1, FH, and levator function. Among these, the length and width of the skin resection was the only factor that was significantly



**Fig. 2.** Digital image analyses of the eyelid features were performed by the ImageJ software. The following parameters were measured: A, MRD-1, distance between upper eyelid margin and corneal light reflex; B, PTS, distance between the upper eyelid margin and lid crease; C, FH, distance between the center of upper and lower eyelids margins; and D, OSA, the area surrounded by the upper and lower margins of the eyelid.

**Table 1. Representative ICC of ImageJ Analysis (OSA)**

Reliability and Reproducibility	ICC*	95% Confidence Interval		P
		Lower	Upper	
X.Z. repeat test (reliability)	0.9782	0.9724	0.9833	<0.001
T.G. repeat test (reliability)	0.9636	0.9618	0.9782	0.003
X.Z. and T.G. repeat test (reproducibility)	0.9524	0.9468	0.9874	0.008

\*The reliability of ImageJ analysis of the eyelid features was evaluated by calculating the ICCs for all parameters measured. A representative result of OSA is shown.

ICC, intra/interclass correlation coefficients.

**Table 2. Correlation Analyses of Factors Related to Simulation Errors of MRD-1 and PTS**

	Simulation Error of MRD-1	Simulation Error of PTS
Length of skin resection	r = 0.366, P = 0.024	r = 0.332, P = 0.031
Width of skin resection	r = 0.411, P = 0.011	r = 0.223, P = 0.421
Preoperative OSA	r = 0.058, P = 0.774	r = -0.588, P = 0.007
Preoperative MRD-1	r = -0.082, P = 0.622	r = -0.368, P = 0.057
Fissure height	r = -0.132, P = 0.457	r = -0.182, P = 0.332
Levator function	r = 0.085, P = 0.623	r = 0.144, P = 0.559

r, Spearman correlation coefficient.

and positively correlated with the MRD-1 error (r = 0.366, P = 0.024 and r = 0.411, P = 0.011; Spearman correlation coefficient; Table 2). A larger area of skin resection was significantly correlated with a larger MRD-1 discrepancy between the simulation and outcome.

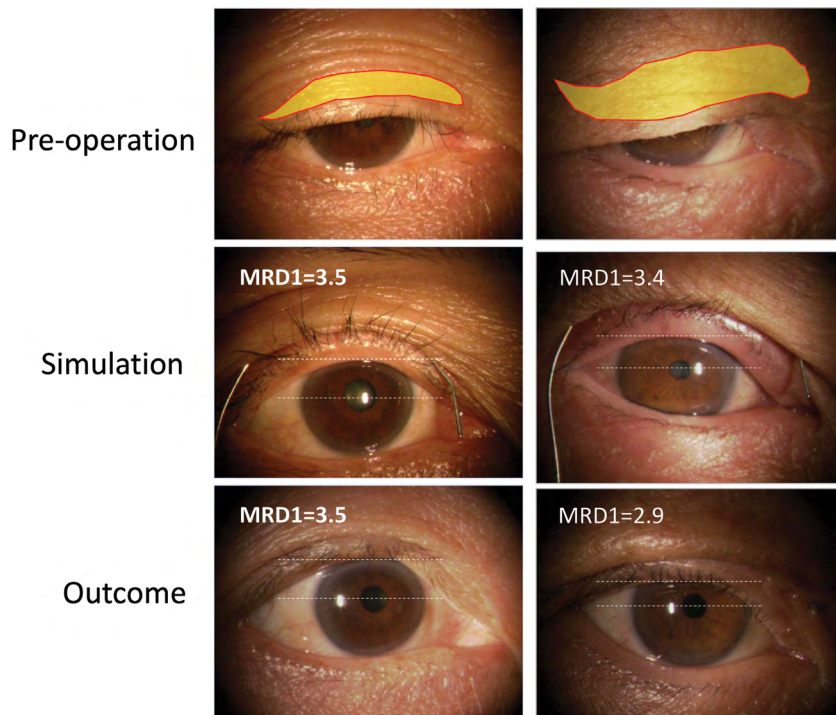
Similarly, correlation analyses were also performed to determine factors related to the PTS error (difference

between the simulation and outcome values). The PTS simulation error was found to be significantly and positively correlated with the length of skin resection (r = 0.332, P = 0.031) and significantly and negatively correlated with the preoperative OSA (r = -0.588, P = 0.007; Table 2). Representative cases showing a good agreement of simulation with less skin resection and a poor agreement with large skin resection are shown in Figure 3.

**DISCUSSION**

In planning for blepharoptosis surgery, surgeons often push the ptotic eyelid up to determine the skin thickness, laxity, and levator function and to simulate the postoperative appearance of the eyelid contours. This simulation is useful for physicians to plan the surgical procedures such as the site of the incision, the need to create an eyelid crease, amount of skin resections, and to predict the postoperative MRD-1. These examinations are also important because it allows patients to imagine the postoperative eyelid appearances and cosmetic changes after the surgery. A simple technique using the paper clip to create postoperative image has been reported.<sup>12</sup> However, to date, there has been no study to determine the accuracy of this technique quantitatively.

Our findings showed that using a bent metal wire for eyelid simulation is a simple and feasible method. The analyses of digital images using the ImageJ software were quantitative and reliable, whose results are in accordance with the findings of our earlier study.<sup>13</sup> Our data showed that while the preoperative simulation of PTS, FH, and OSA were predictable and accurate, the MRD-1 of the



**Fig. 3.** Preoperative simulation and postoperative outcome following blepharoptosis surgery. Representative cases showing less skin resection (left) had a good predictability of postoperative MRD-1 and large skin resection (right) resulted in poor prediction. Image of the extent of skin resection is outlined as the yellow area.

simulated image was significantly larger than the postoperative value. The discrepancies between the MRD-1 assessment with that of FH and OSA could be due to the possibility that the lower eyelid may simultaneously elevate somehow when the upper lid is pushed by the wire at simulation.

The MRD-1 difference between simulation and outcome can be explained by several factors, for example, elevation of the eyelid by a metal wire was greater than the natural lifting of the eyelid by the levator muscle; the redundant skin was taped up during the simulation, which may also be different from the actual surgical resection. In addition, the simulation was done at a sitting position, which is different from intraoperative supine position during the surgical procedures. The degree of dermatochalasis may be intraoperatively underestimated, resulting in less skin resection than preoperative planning at simulation.

Our correlation analyses also showed a significant and positive correlation between the overestimated MRD-1 simulation and the volume of skin resection. This finding is compatible with our clinical observation that blepharoptosis complicated by severe dermatochalasis often results in a smaller postoperative MRD-1 than was estimated to be. Although under-corrected, most patients would be satisfied with the outcome of the surgery. This could be due to the fact that severe dermatochalasis is generally associated with older individuals and the postoperative cosmetic improvements were the more important factor. In addition, under-correction may be beneficial for preventing any possible dry eye symptoms following surgery. However, for younger patients that required large skin resections, the simulation error of MRD-1 may be problematic. Thus, care should be taken that the degree of skin resection should be designed in a sitting position and the possibility of underestimation of MRD-1 should be informed before the surgery.

The position of eyelid crease is another critical cosmetic factor. The simulated PTS was not significantly different from the postoperative values, indicating the accuracy and usefulness of the preoperative simulation for this factor. The PTS can be adjusted by the position of incision line at surgery. The correlation analyses also showed a significant and positive correlation between the PTS simulation error and the length of skin resection and a negative correlation between the PTS simulation error and the preoperative OSA. This again indicates that blepharoptosis with severe dermatochalasis has a poorer predictability on the location of the eyelid crease postoperatively. Care should be given to the selection of the incision line and to the wound closure for the formation of the eyelid crease.

Some limitations exist for this study. In the real world of clinical practice, it is not possible to make identical preoperative MRD-1 simulation in all cases. The simulated MRD-1 varies according to the patient's age, sex, and eyelid features. However, we limited the range of simulated MRD-1 to between 1 and 2 mm under the upper corneal limbus. In addition, blepharoptosis of other etiologies,

such as congenital and contact lens-associated ptosis, should also be investigated. The stiffness of the wire used for simulation was not investigated. Further studies should also include studies on different materials and stiffness of the wire used for the pushing of the eyelid.

In conclusion, our results showed that image analyses of the preoperative simulated eyelid features can provide important information on the postoperative outcomes after blepharoptosis surgery. While the eyelid simulation is predictable, the simulated MRD-1 tends to be overestimated, especially for cases of severe dermatochalasis. Our findings should be helpful for oculoplastic surgeons while planning a surgery or obtaining informed consent from patients before a surgery.

Xiaodong Zheng, MD, PhD

Department of Ophthalmology

Ehime University School of Medicine

Ehime 791-0295, Japan

E-mail: zheng.xiaodong401@gmail.com

## REFERENCES

- Hwang K, Kim JH. The risk of blepharoptosis in contact lens wearers. *J Craniofac Surg*. 2015;26:373–374.
- Briceno CA, Fuller ML, Bradley EA, et al. Assessment of the abbreviated National Eye Institute Visual Function Questionnaire (NEI VFQ 9) in blepharoptosis and dermatochalasis. *Arq Bras Oftalmol*. 2016;79:226–228.
- Battu VK, Meyer DR, Wobig JL. Improvement in subjective visual function and quality of life outcome measures after blepharoptosis surgery. *Am J Ophthalmol*. 1996;121:677–686.
- Cahill KV, Bradley EA, Meyer DR, et al. Functional indication for upper eyelid ptosis and blepharoplasty surgery: a report by the American Academy of Ophthalmology. *Ophthalmology*. 2011;118:2510–2517.
- Kakizaki H, Zako M, Mito H, et al. A guide to making a natural eyelid margin curvature in blepharoptosis surgery. *Acta Ophthalmol Scand*. 2004;82:240–241.
- Wada Y, Hashimoto T, Kakizaki H, et al. What is the best way to handle the involuntional blepharoptosis repair? *J Craniofac Surg*. 2015;26:e377–e380.
- Karesh JW, Putterman AM, Fett DR. Conjunctiva-Müller's muscle excision to correct an ophthalmic ptosis. *Ophthalmology*. 1986;93:1068–1071.
- Anderson RL, Beard C. The levator aponeurosis. Attachments and their clinical significance. *Arch Ophthalmol*. 1977;95:1437–1441.
- Zhang N, Liu S, Hu Z, et al. Accuracy of virtual surgical planning in two-jaw orthognathic surgery: comparison of planned and actual results. *Oral Surg Oral Med Oral Pathol Oral Radiol*. 2016;122:143–151.
- Zheng GS, Wang L, Su YX, et al. Maxillary reconstruction assisted by preoperative planning and accurate surgical templates. *Oral Surg Oral Med Oral Pathol Oral Radiol*. 2016;121:233–238.
- Shen Y, Sun J, Li J, et al. Using computer simulation and stereomodel for accurate mandibular reconstruction with vascularized iliac crest flap. *Oral Surg Oral Med Oral Pathol Oral Radiol*. 2012;114:175–182.
- Rosser PM, Collin JR. Paper-clip technique for upper eyelid skin crease assessment. *Aust N Z J Ophthalmol*. 1991;19:368–369.
- Zheng X, Kakizaki H, Goto T, et al. Digital analysis of eyelid features and eyebrow position following CO<sub>2</sub> laser-assisted blepharoptosis surgery. *Plast Reconstr Surg Glob Open*. 2016;4:e1063.