



Original Article

# Correlation of panoramic high-risk markers with the cone beam CT findings in the preoperative assessment of the mandibular third molars



Shaima Al Ali <sup>a</sup>, Mohamed Jaber <sup>b\*</sup>

<sup>a</sup> Department of Oral Surgery, Hamdan Bin Mohamed College of Dental Medicine, United Arab Emirates

<sup>b</sup> College of Dentistry, Ajman University, United Arab Emirates

Received 15 April 2019; Final revision received 17 August 2019

Available online 19 October 2019

## KEYWORDS

Cone beam computed tomography;  
Nerve injury;  
Third molar;  
Panoramic radiography

**Abstract** *Background/purpose:* Preoperative radiographic examination of mandibular third molars (MTM) is essential to prevent inferior alveolar nerve (IAN) injury. The aim of this study was to assess the panoramic radiography (PAN) signs considered as indicators of increased risk of IAN injury and to correlate them with the cone beam CT (CBCT) findings.

*Materials and methods:* 58 patients who had MTMs extraction between January 2012 and January 2018. OPG were evaluated for the following signs: interruption of the roof of the canal, root darkening, roots deflection and narrowing, canal deviation, superimposition between the MTM roots and mandibular canal. Loss of canal cortication, root grooving, thinning and perforation of lingual cortex were assessed in CBCT images. Chi-square test and multivariate logistic regression tests were used to test the relationship between PAN signs and CBCT findings.

*Results:* A total of 79 MTMs were examined. Loss of canal cortication in CBCT was seen in 22 (27.8%) of the cases. Root darkening in PAN images was the most frequent radiographic sign. Canal deviation and interruption of white line in PAN demonstrated a statistically significant correlation with the loss of canal cortication between the MTM and the mandibular canal on CBCT images ( $p = 0.004$  and  $p = 0.012$ , respectively). No statistically significant association was observed for the other PAN signs and CBCT findings.

*Conclusion:* Canal deviation and interruption of white lines were associated with loss of canal cortication on CBCT, indicating a direct contact between the roots and the mandibular canal which required a further assessment prior to the extraction.

© 2019 Association for Dental Sciences of the Republic of China. Publishing services by Elsevier B.V. This is an open access article under the CC BY-NC-ND license (<http://creativecommons.org/licenses/by-nc-nd/4.0/>).

\* Corresponding author. Department of Oral Surgery, Ajman University, Ajman P. O. Box 346, United Arab Emirates. Fax: +971 050 5178052.

E-mail addresses: [mjaber4@hotmail.com](mailto:mjaber4@hotmail.com), [mohamed.jaber@ajman.ac.ae](mailto:mohamed.jaber@ajman.ac.ae) (M. Jaber).

## Introduction

Extraction of mandibular third molar (MTM) is one of the most common procedures in oral and maxillofacial surgery; therefore several complications may arise postoperatively. These complications generally considered being minor and infrequent; however, the incidence and severity can vary considerably.<sup>1,2</sup> Pain, edema and decreased function are commonly reported and typical postoperative complication; however, these symptoms will normally resolve within a few days of the procedure.<sup>3,4</sup>

The most serious postoperative complication that arises after mandibular third molar surgery is nerve injury, specifically injury to lingual and inferior alveolar nerve. The reported incidence of inferior alveolar nerve (IAN) paresthesia was varied between 0.35% and 8.4%.<sup>5–8</sup> In most cases, IAN paresthesia is temporary and recovers within 6 months,<sup>9</sup> however, in less than 1% of the cases the injury may become permanent and lasts longer than 6 months.<sup>10</sup>

The panoramic radiograph is the standard diagnostic image for the initial preoperative assessment of mandibular third molars and their anatomical relationship with the inferior alveolar canal. One of the limitation of the panoramic radiography is that they provide information in only two dimensions, thus panoramic images alone are not sufficient for evaluating the proximity of the inferior alveolar canal to the roots of lower third molar teeth.<sup>11,12</sup> If the panoramic radiograph shows a close relationship between the root of the third molar and the inferior alveolar canal, then an additional investigation using computed tomography (CT) was recommended to verify the anatomical relationship in a three-dimensional (3D) view.<sup>13–15</sup>

The close anatomic relationship between the mandibular third molar and the IAC may result in injury to the IAN during third molar extraction. To prevent this serious postoperative complication, several studies have identified radiographic signs on panoramic radiographs, which may suggest a close relationship between the mandibular canal and mandibular third molars.<sup>16–18</sup>

Before considering routine use of CBCT in the preoperative assessment of MTMs, it is imperative to know if it is superior and likely give the treating practitioner more details than the conventional radiographic techniques in predicting IAN injuries. Numerous studies have been conducted to correlate the high-risk signs of IAN injury seen on panoramic or periapical radiographs with the findings on CBCT.<sup>11,12,17–19</sup> Therefore, the aim of this study was to assess the radiographic signs considered as indicators of increased risk of inferior alveolar nerve injury in panoramic radiographs and to correlate them with the cone beam CT (CBCT) findings in the preoperative assessment of MTMs.

## Material and methods

### Study design/sample

This is a cross sectional study which included patients who consulted the department of Oral and Maxillofacial Surgery, Hamdan Bin Mohammed College of Dental Medicine for MTMs removal between January 2012 and January 2018. The sample consist of 58 individuals with 79 MTMs whose digital

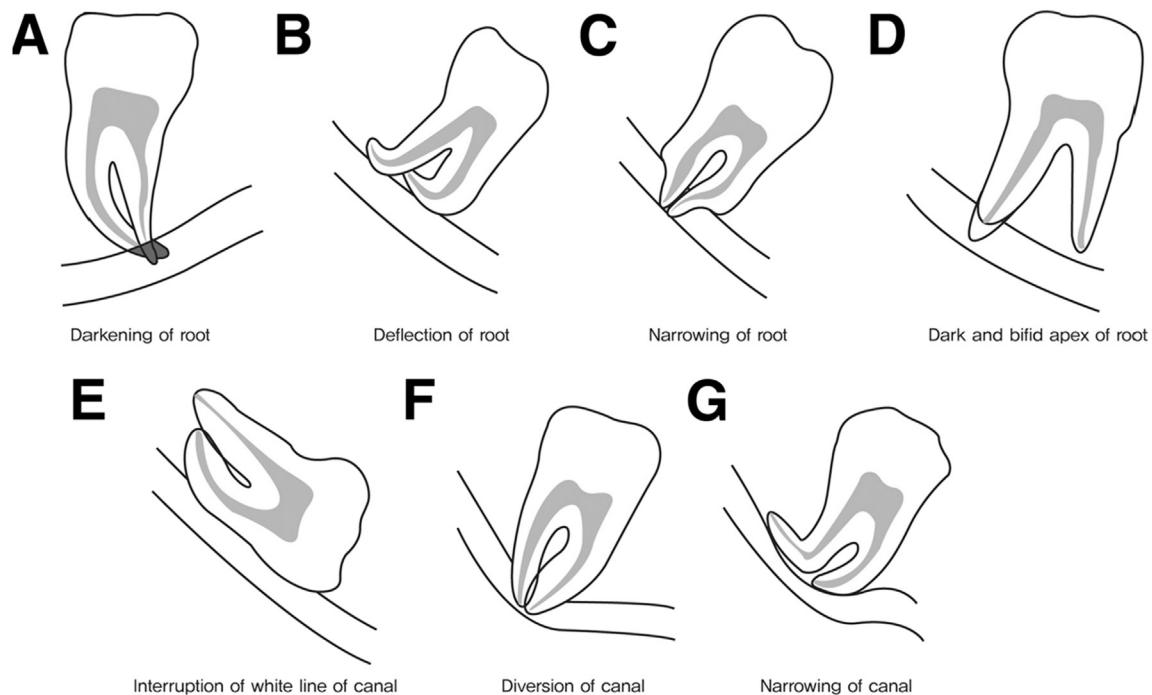
panoramic radiograph (PAN) suggested a close relationship between the inferior alveolar canal (IAC) and MTM and therefore underwent an additional radiographical investigation with cone beam computer tomography (CBCT). Patients were selected according to the following inclusion exclusion criteria: 1) patients over 18 years old, 2) panoramic images of the MTMs showing at least one of the high-risk markers and 3) availability of acceptable CBCT images of the same patient. The exclusions criteria were 1) presence of periapical pathology associated with MTM or IAC, 2) mandibular third molars with incomplete root formation, 3) presence of artifacts, which obscure the mandibular third molar and IAC and 4) images with poor density and inadequate contrast.

Digital panoramic radiographs were obtained with (Gendex orthoralix 9200, Cusano Milanino, Italy) DDE device operated at 60–84 kV and 3–15 mA and an exposure time of 12 s. GALILEOS Dental CBCT imaging machine was used to take CBCT views (GALAXIS, REKO software, Bensheim, Germany). It is operating at 85 kVp/7 mA, with a 0.5 mm voxel size and a field of view of 8 cm. The scan time is 14 s.

To determine the topographic relationship between the MTM and the inferior alveolar canal, an experience maxillofacial radiologist with more than twenty years of work history evaluated the digital panoramic and CBCT images independently. All the images were viewed blindly. They were assigned with an identification number for the first evaluation. After 30 days, the images were randomly selected and assigned to a new identification number by person who was blind to the study design and re-evaluated by the examiner. The digital panoramic images were evaluated on a computer monitor (21-inch LCD monitor with 1280 × 1024 resolution), in dark room, with the use of the “zoom” tool and manipulation of brightness and contrast. After 30 days, all images were re-evaluated by the same observer. Panoramic images were evaluated according to the criteria established by Rood and Shehab.<sup>16</sup> Four of these signs were tooth related (darkening, root deflection, root narrowing, and a bifid apex), and the other three were canal related signs (diversion, narrowing, and interruption in the canal white line).<sup>20</sup> (see Fig. 1). The seven radiographic signs were described according to Huang et al.,<sup>21</sup> (see Table 1). On the CBCT images, the presence or absence of cortication between the MTM and the mandibular canal was evaluated. The images were evaluated in all three dimensions: sagittal, coronal and axial plane. The position of the mandibular canal in relation to the MTM was classified as: buccal, lingual, inferior and intra-radicular position. All data were collected and entered into Excel data sheets using a special form.

In panoramic radiographs, the primary variable was the radiographic relationship of the mandibular third molar to the IAC or tooth-related findings (darkness of the root, narrowing of the root, and deflection of the root) and canal-related findings (narrowing of the canal, diversion of the canal, and interruption of the white line). The secondary variable was the superimposition between the root of MTM and the inferior alveolar canal in the absence of the other radiographic signs.

For the CBCT images, the main variable was presence or absence of cortication between the tooth and the IAC in CBCT images. Absence of cortication was defined as loss of



**Figure 1** The radiographic relationship of the mandibular third molar to the inferior alveolar canal.

**Table 1** Radiographic signs of the intimate relationship between the mandibular third molar root and inferior alveolar nerve canal (Huang et al.).<sup>21</sup>

Radiographic signs	Description
Darkening of the mandibular third molar root	Radiolucency of the mandibular third molar root area, where mandibular third molar root and mandibular canal are superimposed
Interruption of the radiopaque line	Absence of continuity of mandibular canal cortex
Diversion of the mandibular canal	Obviously, direction change of the mandibular canal in passage of the mandibular third molar root
Dark and bifid apex	Bifid and darkening of the mandibular third molar root, where mandibular canal is superimposed to it
Deflection of the root	Dilacerations root morphology of mandibular third molar, where mandibular canal is contact or superimposed to it
Narrowing of the mandibular canal	Narrowing of the mandibular canal dimension where the canal and mandibular third molar root are contact or superimposed
Narrowing of the root	Narrowing of the mandibular third molar root, where the mandibular canal and mandibular third molar root are contact or superimposed

cortical lines between the tooth and the IAC. The secondary variable was position of inferior alveolar canal in relation to the root of the MTM, grooving of the root by the mandibular canal, thinning and perforation of the lingual cortex.

Data collection and statistical analyses were carried out with Statistical Package for Social Sciences program (SPSS) version 24 (USA). The frequencies of the panoramic and CBCT findings were calculated. The demographic factors for the study population were analyzed. The association of each panoramic variable with the CBCT findings was compared by Cross-tabulations and chi-square test. Multiple logistic regression analysis was used to evaluate the

contributions of panoramic findings and age on the loss of canal cortication in CBCT view. Multivariate ORs and 95% confidence intervals were also calculated. The relation between the patient age and loss of canal cortication was evaluated by t-test. A P value less than 0.05 was considered significant. McNamara statistic was used to calculate intra-observer agreement. The Research Ethics committees of the HBMCDM approved this study. Intra examiner agreement for the repeated radiographic readings were analyzed using McNamara's Test. For panoramic radiographs, there was concordance for all the radiographic signs. For CBCT the entire findings showed concordances between the two readings.

## Result

A total of 79 lower third molars were examined in 58 patients. The study sample consisted of 31 females (53.4%), 27 males (46.6%) with a mean age of 39.62 (SD = 9.89) and range of 21–67 years. Twenty-one patients (36.2%) had bilateral MTMs while 37 patients (63.8%) had unilateral MTMs.

Panoramic images were investigated according to Rood's criteria;<sup>16</sup> the most frequent radiographic sign which is an indicators of a close relationship between the MTMs and the inferior alveolar canal was root darkening. The second most frequent radiographic sign was root deflection, which was observed in Seventeen cases (21.5%) while narrowing of the canal was detected in 16 cases (20.3%). Interruption of the white line of the canal was the least frequently seen panoramic signs (9 cases, 11.4%).

Superimposition between the MTM roots and the IAC in the absence of all other high risk signs in PAN was observed in 13 cases (16.5%), [Table 2](#).

As determined on CBCT images out of 79 MTMs teeth investigated in this study, 22 (27.8%) showed loss of canal cortication, which represent a direct contact between MTM root and IAC ([Fig. 2](#)). The frequencies of CBCT findings were

**Table 2** The frequencies of the panoramic radiographic signs.

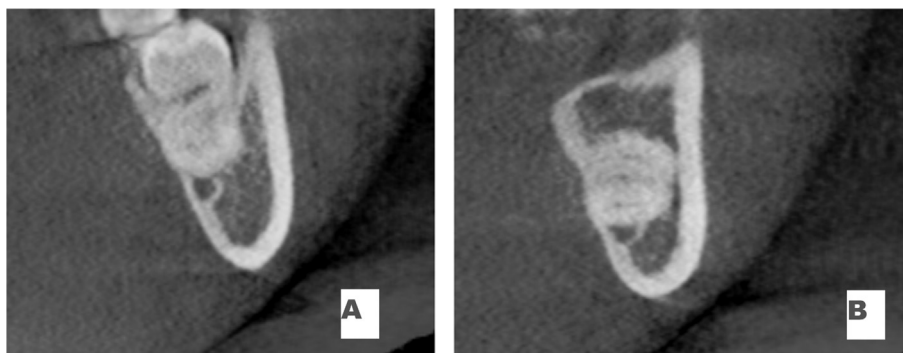
Radiographic sign	Number of cases (N = 79)	Percentage %
Root darkening	52	65.8
Narrowing of the root	12	15.2
Deflection of the roots	17	21.5
Bifid apex	12	15.2
Narrowing of the canal	16	20.3
Interruption of white line	9	11.4
Deviation of the canal	10	12.7
Superimposition in the presence of other signs	54	68.4
Super imposition in the absence of other signs	13	16.5

**Table 3** The frequencies of CBCT findings.

CBCT findings	Number of cases (N = 79)	Percentage %
Loss of canal cortication	22	27.8
Canal location		
• Buccal	45	57
• Lingual	18	22.8
• Inferior	14	17.7
• Intra-radicular	2	2.5
Root perforated by the canal	0	0
Thinning of lingual cortex	39	49.4
Perforation of lingual cortex	1	1.3
Root notching by the canal	6	7.6

listed in ([Table 3](#)). Cross tabulations were carried out for the loss of canal cortication in CBCT and the radiographic signs in the panoramic radiograph ([Table 4](#)). Most cases of the loss of canal cortication in CBCT (12 cases, 54%) showed root darkening in panoramic images. Loss of canal cortication was also observed in 7 cases (70%) of canal deviation, 7 cases (41.2%) of root deflection, 7 cases (43.8%) of canal narrowing, and 6 cases (50%) of root narrowing. Loss of canal cortication was least frequently observed in cases, which showed bifid apex in panoramic radiograph. Superimposition between the MTMs roots and IAC in the absence of the other seven panoramic signs showed loss of canal cortication in 3 cases. However, this finding was not statistically significant ( $p = 0.482$ ). Interruption of white line ([Fig. 3](#)) and deviation of the canal demonstrated a statistically significant association with the loss of canal cortication ( $p < 0.012$  and  $p < 0.004$ , respectively). No statistically significant association was observed for the other panoramic radiographic signs ( $p > 0.05$ ). The relationship between the patient age and loss of canal cortication was evaluated by t-test and showed non-significant relationship ( $p = 0.319$ ). We found no statistically significant relationship between gender and loss of canal cortication ( $P = 0.071$ ) ([Table 5](#)).

Results of Logistic regression analysis showed that (26.8%) of loss of canal cortication on CBCT images was predicted by interruption of white lines in panoramic radiograph after adjustment for deviation of the canal, root darkening, narrowing of canal, gender and patient's age. Model of fitness was valid ( $p < 0.013$ ) ([Table 6](#)).

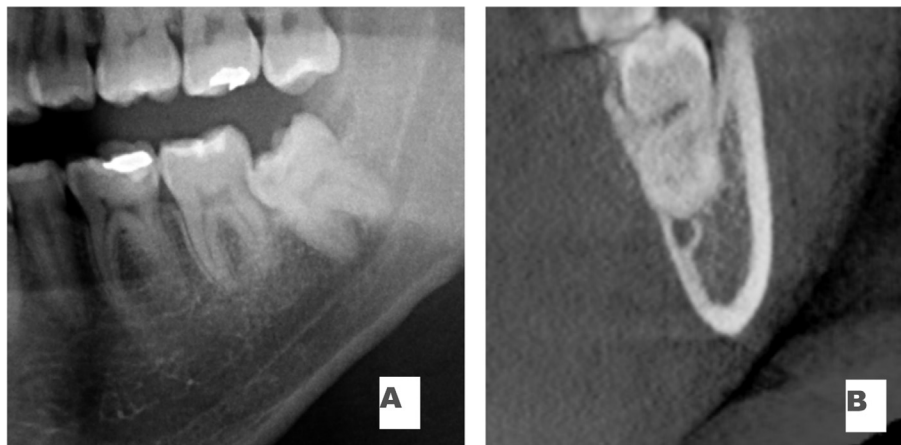


**Figure 2** Cross sectional view of loss of canal cortication on cone beam computer tomography (CBCT) images.

**Table 4** The relation between of the panoramic signs and inferior alveolar canal (IAC) cortication.†

Panoramic signs	Loss of canal cortication in CBCT		Chi-square value	P-value
	Yes (n = 22)	NO (n = 57)		
<b>Root darkening</b>				
Present (n = 52)	12 (54.5%) <sup>a</sup>	40 (70.2%)	1.724	0.147
Absent (n = 27)	10 (45.5%)	17 (29.8%)		
<b>Root narrowing</b>				
Present (n = 12)	6 (27.3%)	6 (10.5%)	3.456	0.07
Absent (n = 67)	16 (72.7%)	51 (72.7%)		
<b>Root deflection</b>				
Present (n = 17)	7 (31.8%)	10 (17.5%)	1.915	0.141
Absent (n = 62)	15 (68.2%)	47 (82.5%)		
<b>Bifid apex</b>				
Present (n = 12)	3 (13.6%)	9 (15.8%)	0.57	0.558
Absent (n = 67)	19 (86.4%)	48 (84.2%)		
<b>Canal Narrowing</b>				
Present (n = 16)	7 (31.8%)	9 (15.8%)	2.525	0.103
Absent (n = 63)	15 (68.2%)	48 (84.2%)		
<b>Interruption of white lines</b>				
Present (n = 9)	6 (27.3%)	3 (5.3%)	7.617	0.012
Absent (n = 70)	16 (72.7%)	54 (94.7%)		
<b>Canal deviation</b>				
Present (n = 10)	7 (31.8%)	3 (5.3%)	10.124	0.004
Absent (n = 69)	15 (68.2%)	54 (94.7%)		
<b>Super imposition in absence of other signs</b>				
Present (n = 67)	3 (13.6%)	10 (17.5%)	0.176	0.482
Absent (n = 12)	19 (86.4%)	47 (82.5%)		

<sup>a</sup> Percentage within loss of canal cortication.



**Figure 3** A. Interruption of white line in panoramic radiography. B. Loss of canal cortication in cone beam computer tomography (CBCT) cross sectional view.

**Table 5** The relationship between gender and loss of canal cortication.

Gender (n = 58)*	Number of mandibular third molars (n = 79)	Loss of canal cortication		Chi-square value	P-value
		Yes (n = 22)	No (n = 57)		
Female (n = 31)	38	14 (63.6%)	24 (42.1%)*	2.948	0.071
Male (n = 27)	41	8 (36.4%)	33 (57.9%)		

\* Percentage within thinning of lingual cortex.

\* n = number of patients.

**Table 6** Multiple logistic regression models for predicting loss of canal cortication based on panoramic signs.

Variables	Odds ratio	95% Confidence intervals	P-value*
Deviation of the canal	0.328	0.048–2.264	0.258
Interruption of white line	0.136	0.023–0.806	0.025
Root darkening	2.343	0.695–7.894	0.170
Narrowing of the canal	0.737	0.155–3.496	0.70
Gender	2.365	0.678–8.252	0.177
Age	0.979	0.920–1.642	0.509

\* Significant level  $p < 0.05$ .

**Table 7** The relation of the canal position and loss of canal cortication in CBCT.

Canal position	Number	Loss of canal cortication (n = 22)
Buccal	45	7 (31.8%) <sup>a</sup>
Lingual	18	10 (45.5%)
Intra-radicular	2	2 (9.1%)
Inferior	14	3 (13.6%)

<sup>a</sup> Percent within loss of canal cortication.

The Inferior alveolar canal was most frequently positioned buccal to the third molar in 45 (57%) of the cases while lingual course of the canal was seen in 18 (22.8%) of the cases. Inferior position of the canal was observed in 14 (17.7%) cases (Table 7).

Thinning of the lingual cortex was reported in 39 (49.4%) cases, with the canal most frequently located buccally to the roots of the MTM. No statistically significant association was observed between the canal positions and thinning of the lingual cortex (Table 8).

Table 9 shows the statistical relationship between the root darkening on panoramic view and thinning of lingual cortex in CBCT view. In twenty-three cases (59%) of thinning of lingual cortical plate observed in CBCT view, root darkening was detected in panoramic radiograph. However, this relationship was not statistically significant ( $p = 0.152$ ).

Table 10 shows the statistical relationship between the root darkening on panoramic view and notching of the root in CBCT view. Notching of the root by the IAC was seen in 6 CBCT views (7.6%), while, in four cases of the root grooving, root darkening was observed in panoramic radiograph. However, this relationship was not statistically significant ( $p = 0.668$ ).

## Discussion

The close anatomical relationship between the roots of the MTM and inferior alveolar canal can result in nerve injuries during the surgical removal of the tooth. Accurate radiographic examinations are essential to assess and estimate the possible risk of IAN injury. Panoramic radiography enable the oral and maxillofacial surgeons to initially examine the relationship of the MTM to the inferior alveolar canal, however, this radiographic method provides only a two-dimensional view of a three-dimensional structures. The buccolingual relationship between the lower third molar and the IAC cannot be evaluated in panoramic view.<sup>22</sup> CBCT was reported by many investigators to be more accurate imaging technique for the preoperative assessment of the relationship of MTMs to the IAC.<sup>22–24</sup>

Several studies highlighted the close relationship between the MTMs and IAC in the presence of high-risk radiographic signs on PAN and compared with the CBCT findings.<sup>11,18,24–27</sup>

In the present study, root darkening was the most frequent panoramic signs indicating a close contact between the roots of the MTM and IAC. This finding is in agreement with the results reported by other investigators.<sup>29,30</sup> While interruption of the canal white line is the least frequent panoramic sign this is in contrast with the findings of other studies.<sup>17,18,25,30</sup>

The frequency of loss of canal cortication in CBCT was found in 22 cases (27.8%) of the MTMs. This is lower than the 94% loss of canal cortication reported by Ohman et al.,<sup>15</sup> and 85% reported by Ghaeminia et al.,<sup>22</sup> and similar to findings reported by Tantanapornkul et al.<sup>19</sup>

Deviation of the canal was seen in 10 cases (12.7%) out of 79 cases. Nakamori et al.,<sup>18</sup> found a lower incidence of (2.7%), while Umar et al.,<sup>29</sup> reported a higher incidence of

**Table 8** The relationship between canal position and thinning of lingual cortex.

Canal position	Number	Thinning of lingual cortex		Chi-square value	P-value*
		Yes (n = 39)	No (n = 40)		
Buccal	45	26 (66.7%)*	19 (47.5%)	2.959	0.085
Lingual	18	7 (17.9%)	11 (27.5%)	1.024	0.312
Intra-radicular	2	0 (0.0%)	2 (5%)	2.001	0.157
Inferior	14	6 (15.4%)	8 (20%)	0.288	0.591

\* Percentage within thinning of lingual cortex.

\* Significant level  $p < 0.05$ .

**Table 9** The relationship between root darkening and thinning of lingual cortex.

Radiographic sign	Thinning of lingual cortex		Chi-square value	P-value*
	Yes (n = 39)	No (n = 73)		
Root darkening				
Present (n = 52)	23 (59%)*	29 (72.5%)	1.606	0.152
Absent (n = 27)	16 (41%)	11 (27.5%)		

\* Significant level  $p < 0.05$ .

\* Percentage within thinning of lingual cortex.

**Table 10** The relation between root darkening and notching of the root.

Radiographic sign	Notching of the root		Chi-square value	P-value*
	Yes (n = 6)	No (n = 73)		
Root darkening				
Present (n = 52)	4 (66.7%)*	48 (65.8%)	0.002	0.668
Absent (n = 27)	2 (33.3%)	25 (34.2%)		

\* Significant level  $p < 0.05$ .

\* Percentage within notching of the root.

canal deviation, which was seen in 15 (30%) out of 50 cases. In our study, Loss of canal cortication was seen in 70% of the cases in particular in association with deviation of the IAC and this result demonstrated a statistically significant correlation with the loss of canal cortication. This finding is consistent with the result of Nakamori et al.,<sup>18</sup> who reported statistically significant correlation between canal deviation and loss of canal cortication in CBCT. Similar result was also reported by Umar et al.<sup>29</sup> However, Monaco et al.,<sup>14</sup> and Jhamb et al.,<sup>31</sup> observed non-significant relationship between the two signs.

In the panoramic findings, interruption of the canal white line found in 9 cases (11.4%). This incidence was lower than those reported by Nakagawa et al.,<sup>11</sup> (57.5%) and Umar et al.,<sup>29</sup> (68%) and higher than that reported by Nakamori et al.,<sup>18</sup> (9.4%). Out of 9 cases showing interruption of canal white line in PAN, 6 cases (66.7%) showed loss of canal cortication in CBCT. Nakagawa et al.,<sup>11</sup> concluded that in 86% of cases in which the canal superior white line was interrupted on panoramic view, the CBCT images showed loss of canal cortication between the third molar root and IAC. Ghaeminia et al.,<sup>22</sup> reported a comparable high percentage of 88%. In our study, interruption of white line was significantly associated with loss of IAC cortication ( $p = 0.012$ ). This finding was in agreement with previous studies.<sup>11,14,27,29,31</sup>

Nakamori and co-workers,<sup>18</sup> found that 21 out of 43 cases of interruption of canal white line also showed contact relation between the root of MTM and IAC but their results were not statistically significant.

In the current study, loss of canal cortication was seen in 12 (23.07%) cases out of 52 showing root darkening and 7 (43.7%) cases out of 16 cases showing narrowing of the canal in panoramic views, however this relationship was not statistically significant. This result was not in agreement with findings reported by many investigators.<sup>1,14,29,31</sup>

During surgical extraction of MTMs, intraoperative IAN exposure has been linked to increased risk of nerve injuries and loss of canal cortication in the CBCT is a radiographic

sign that predisposes this exposure. In the present study, logistic regression analysis showed that (26.8%) of loss of canal cortication on CBCT images was predicted by interruption of white lines in panoramic radiograph after adjustment for deviation of the canal, root darkening, canal narrowing, gender and patient's age. This is in agreement with the finding of Nakagawa et al.,<sup>11</sup> which showed that interruption of white line on panoramic radiography was a predictor of increased risk of contact between the third molar and the mandibular canal on CBCT, even when the effects of tooth position, age, and gender were considered, likewise, Nakamori and co-workers,<sup>18</sup> indicated that when an attached relationship was recognized, narrowing of the canal became a powerful predictor for absence of cortication. Ohman et al.,<sup>15</sup> reported that a dark band is an indicator of root grooving by the inferior alveolar canal, although grooving can be seen in the absence of this panoramic sign. However, Tantanapornkul et al.,<sup>28</sup> concluded that this sign represents a cortical thinning or perforation of the lingual cortical plate in 80% of the cases rather than grooving of the tooth that observed in only 20% of the cases. Umar et al.,<sup>29</sup> confirmed this finding and attributed the root darkening not to loss of root structure but to thinning of a cortical plate. In our study, grooving of the root by the IAC was seen in 6 cases (7.6%), in 4 cases, it is associated with root darkening and in 2 cases the root darkening was absent, however, this relationship was not statistically significant. Thinning of the lingual cortex was seen in 39 (49.4%) cases, while perforation of the lingual cortex by the root of the MTM was observed in 1 case only. Twenty-three cases (44.2%) of the root darkening showed thinning of lingual cortical plate in CBCT view.

We found a non-significant correlation between root darkening in panoramic radiograph and thinning of the lingual cortex in CBCT view. This finding is critical for the oral surgeons during the third molar surgery to avoid lingual nerve injuries, fracture of the lingual cortex or displacement of the root accidentally into close anatomical spaces.

As determined on CBCT images, the Inferior alveolar canal was most frequently positioned buccally to the MTM root. This is in accordance with the reported findings of other investigators,<sup>13,14,32</sup> while others observed more lingually positioned canals.<sup>15,22</sup> An inter-radicular canal course was the least frequent position, which was observed in 2 (2.5%) cases only. Similar findings have been reported by previous studies.<sup>13,15,19</sup> Knowing the most common course of the mandibular canal is extremely important to the surgeons because multiple previous studies reported that the IAN was more frequently exposed following third molar extraction when the inferior alveolar canal was located lingually or at inter-radicular position in relation to MTM roots than in a buccal position.<sup>13,22,31</sup> Tay and Go<sup>33</sup> and Leung and Cheung<sup>34</sup> found about 20% increases in the risk IAN impairment following MTM extraction when the nerve visualized intraoperatively. In contrast to our findings Matzen et al.,<sup>35</sup> in a recent study reported that PAN and CBCT are not reliable risk factors for neurosensory disturbances of the IAN, and CBCT appears not to improve the risk assessment.

This is a retrospective study, which had several limitations: the panoramic radiographs were already taken and we had no role in minimizing any errors or controlling the quality of images, CBCT scans was done with standard settings, but the dataset could not be reoriented as suggested by Lubbers et al.,<sup>23</sup> who reported that oblique plane scanning, which needs a small number of slices with a relatively small volume, can be helpful if the IAC is difficult to visualize.

This study concluded that canal deviation and interruption of white line observed on PAN were associated with loss of canal cortication on CBCT, indicating a direct contact between the root of MTM and the IAC. Such findings on PAN required a further three-dimensional assessment by CBCT prior to the extraction. No statistically significant association was observed for the other panoramic radiographic signs. Prospective studies with larger sample size to confirm the findings of this study are warranted.

## Declaration of Competing Interest

None declared.

## Appendix A. Supplementary data

Supplementary data to this article can be found online at <https://doi.org/10.1016/j.jds.2019.08.006>.

## References

- Bui C, Seldin E, Dodson T. Types, frequencies, and risk factors for complications after third molar extraction. *J Oral Maxillofac Surg* 2003;61:1379–89.
- Chuang S, Perrott D, Susarla S, Dodson T. Age as a risk factor for third molar surgery complications. *J Oral Maxillofac Surg* 2007;65:1685–92.
- Phillips C, White Jr R, Shugars D, Zhou X. Risk factors associated with prolonged recovery and delayed healing after third molar surgery. *J Oral Maxillofac Surg* 2003;61:1436–48.
- Bienstock D, Dodson T, Perrott D, Chuang S. Prognostic factors affecting the duration of disability after third molar removal. *J Oral Maxillofac Surg* 2011;69:1272–7.
- Lopes V, Mumenya R, Feinmann C, Harris M. Third molar surgery: an audit of the indications for surgery, postoperative complaints and patient satisfaction. *Br J Oral Maxillofac Surg* 1995;33:33–5.
- Haug R, Perrott D, Gonzalez M, Talwar R. The American association of oral and maxillofacial surgeons age-related third molar study. *J Oral Maxillofac Surg* 2005;63:1106–14.
- Cheung L, Leung Y, Chow L, Wong M, Chan E, Fok Y. Incidence of neurosensory deficits and recovery after lower third molar surgery: a prospective clinical study of 4338 cases. *Int J Oral Maxillofac Surg* 2010;39:320–6.
- Smith W. The relative risk of neurosensory deficit following removal of mandibular third molar teeth: the influence of radiography and surgical technique. *Oral Surg Oral Med Oral Pathol Oral Radiol Endodontology* 2013;115:18–24.
- Valmaseda-Castellón E, Berini-Aytés L, Gay-Escoda C. Inferior alveolar nerve damage after lower third molar surgical extraction: a prospective study of 1117 surgical extractions. *Oral Surg Oral Med Oral Pathol Oral Radiol Endodontology* 2001;92:377–83.
- Gülicher D, Gerlach K. Sensory impairment of the lingual and inferior alveolar nerves following removal of impacted mandibular third molars. *Int J Oral Maxillofac Surg* 2001;30:306–12.
- Nakagawa Y, Ishii H, Nomura Y, et al. Third molar position: reliability of panoramic radiography. *J Oral Maxillofac Surg* 2007;65:1303–8.
- Susarla S, Dodson T. Preoperative computed tomography imaging in the management of impacted mandibular third molars. *J Oral Maxillofac Surg* 2007;65:83–8.
- Maegawa H, Sano K, Kitagawa Y, et al. Preoperative assessment of the relationship between the mandibular third molar and the mandibular canal by axial computed tomography with coronal and sagittal reconstruction. *Oral Surg Oral Med Oral Pathol Oral Radiol Endodontology* 2003;96:639–46.
- Monaco G, Montevecchi M, Bonetti G, Gatto M, Checchi L. Reliability of panoramic radiography in evaluating the topographic relationship between the mandibular canal and impacted third molars. *J Am Dent Assoc* 2004;135:312–8.
- Öhman A, Kivijärvi K, Blombäck U, Flygare L. Preoperative radiographic evaluation of lower third molars with computed tomography. *Dentomaxillofac Radiol* 2006;35:30–5.
- Rood J, Shehab B. The radiological prediction of inferior alveolar nerve injury during third molar surgery. *Br J Oral Maxillofac Surg* 1990;28:20–5.
- Sedaghatfar M, August M, Dodson T. Panoramic radiographic findings as predictors of inferior alveolar nerve exposure following third molar extraction. *J Oral Maxillofac Surg* 2005;63:3–7.
- Nakamori K, Fujiwara K, Miyazaki A, et al. Clinical assessment of the relationship between the third molar and the inferior alveolar canal using panoramic images and computed tomography. *J Oral Maxillofac Surg* 2008;66:2308–13.
- Tantanapornkul W, Okouchi K, Fujiwara Y, et al. A comparative study of cone-beam computed tomography and conventional panoramic radiography in assessing the topographic relationship between the mandibular canal and impacted third molars. *Oral Surg Oral Med Oral Pathol Oral Radiol Endodontology* 2007;103:253–9.
- Palma-Carrió C, García-Mira B, Larrabal-Morón C, Peñarocha-Diago M. Radiographic signs associated with inferior alveolar nerve damage following lower third molar extraction. *Med Oral Pathol Oral Cir Bucal* 2010;15:886–90.
- Huang C, Man Lui, Cheng D. Use of panoramic radiography to predict postsurgical sensory impairment following extraction



- of impacted mandibular third molars. *J Chin Med Assoc* 2015; 78:617–22.
22. Ghaemina H, Meijer GJ, Soehardi A, Borstlap WA, Mulder J, Berge SJ. Position of the impacted third molar in relation to the mandibular canal. Diagnostic accuracy of cone beam computed tomography compared with panoramic radiography. *Int J Oral Maxillofac Surg* 2009;38:964–71.
  23. Lübbers H, Matthews F, Damerau G, et al. Anatomy of impacted lower third molars evaluated by computerized tomography: is there an indication for 3-dimensional imaging? *Oral Surg Oral Med Oral Pathol Oral Radiol Endodontol* 2011; 111:547–50.
  24. Neves F, Souza T, Almeida S, Haiter-Neto F, Freitas D, Bóscolo F. Correlation of panoramic radiography and cone beam CT findings in the assessment of the relationship between impacted mandibular third molars and the mandibular canal. *Dentomaxillofac Radiol* 2012;41:553–7.
  25. Nakayama K, Nonoyama M, Takaki Y, et al. Assessment of the relationship between impacted mandibular third molars and inferior alveolar nerve with dental 3-dimensional computed tomography. *J Oral Maxillofac Surg* 2009;67: 2587–91.
  26. Harada N, Vasudeva S, Joshi R, et al. Correlation between panoramic radiographic signs and high-risk anatomical factors for impacted mandibular third molars. *Oral Surg* 2013;6:129–36.
  27. Peker I, Sarikir C, Alkurt MT, Zor ZF. Panoramic radiography and cone-beam computed tomography findings in preoperative examination of impacted mandibular third molars. *BMC Oral Health* 2014;14:71.
  28. Tantanapornkul W, Okochi K, Bhakdinaronk A, Ohbayashi N, Kurabayashi T. Correlation of darkening of impacted mandibular third molar root on digital panoramic images with cone beam computed tomography findings. *Dentomaxillofac Radiol* 2009;38:11–6.
  29. Umar G, Bryant C, Obisesan O, Rood J. Correlation of the radiological predictive factors of inferior alveolar nerve injury with cone beam computed tomography findings. *Oral Surg* 2010;3:72–82.
  30. Szalma J, Lempel E, Jeges S, Szabó G, Olasz L. The prognostic value of panoramic radiography of inferior alveolar nerve damage after mandibular third molar removal: retrospective study of 400 cases. *Oral Surg Oral Med Oral Pathol Oral Radiol Endodontol* 2010;109:294–302.
  31. Jhamb A, Dolas R, Pandilwar P, Mohanty S. Comparative efficacy of spiral computed tomography and orthopantomography in preoperative detection of relation of inferior alveolar neurovascular bundle to the impacted mandibular third molar. *J Oral Maxillofac Surg* 2009;67:58–66.
  32. Kaeppeler G. Conventional cross-sectional tomographic evaluation of mandibular third molars. *Quintessence Int* 2000;31: 49–56.
  33. Tay A, Go W. Effect of exposed inferior alveolar neurovascular bundle during surgical removal of impacted lower third molars. *J Oral Maxillofac Surg* 2004;62:592–600.
  34. Leung Y, Cheung L. Risk factors of neurosensory deficits in lower third molar surgery: a literature review of prospective studies. *Int J Oral Maxillofac Surg* 2011;40:1–10.
  35. Matzen L, Petersen L, Schropp L, Wenzel A. Mandibular canal-related parameters interpreted in panoramic images and CBCT of mandibular third molars as risk factors to predict sensory disturbances of the inferior alveolar nerve. *Int J Oral Maxillofac Surg* 2019;S0901–5027(19):31020–3.