

Transforming growth factor- β 3 promotes facial nerve injury repair in rabbits

YANMEI WANG^{1*}, XINXIANG ZHAO^{2*}, MUHTER HUOJIA³, HUI XU³ and YOUMEI ZHUANG³

Departments of ¹Nursing and ²Plastic Surgery, Gongli Hospital of Pudong New Area, Shanghai 200135;

³Department of Oral and Maxillofacial Surgery, People's Hospital of Xinjiang, Urumchi, Xinjiang 830001, P.R. China

Received January 23, 2015; Accepted September 25, 2015

DOI: 10.3892/etm.2016.2972

Abstract. The present study investigated the effects of transforming growth factor (TGF)- β 3 on the regeneration of facial nerves in rabbits. A total of 20 adult rabbits were randomly divided into three equal groups: Normal control (n=10), surgical control (n=10) and TGF- β 3 treatment (n=10). The total number and diameter of the regenerated nerve fibers was significantly increased in the TGF- β 3 treatment group, as compared with in the surgical control group (P<0.01). Furthermore, in the TGF- β 3 treatment group, the epineurial repair of the facial nerves was intact and the nerve fibers, which were arranged in neat rows, were morphologically intact with visible myelin swelling. However, in the surgical control group, the epineurial repair was incomplete, as demonstrated by: Atrophic nerve fibers, partially disappeared axons and myelin of uneven thickness with fuzzy borders. Electron microscopy demonstrated that the regenerated fibers in the TGF- β 3 treatment group were predominantly myelinated, with clear-layered myelin sheath structures and axoplasms rich in organelles. Although typical layered myelin sheath structures were observed in the surgical control group, the myelin sheaths of the myelinated nerve fibers were poorly developed and few organelles were detected in the axoplasms. Neuro-electrophysiological examination demonstrated that, as compared with the surgical control group, the latency period of the action potentials in the TGF- β 3 treatment group were shorter, whereas the stimulus amplitudes of the action potentials were significantly increased (P<0.01). The results of the present study suggest that TGF- β 3 may improve the regeneration of facial nerves following trauma or injury.

Introduction

The facial nerve is the longest peripheral nerve in the human body. Its anatomical structure is unique and its position, which is superficial and closely associated with the parotid gland, leaves it vulnerable to damage during an operation or as a result of trauma (1,2). Damage to the facial nerve can lead to paralysis of the muscles that control facial expressions (3), which may seriously affect the patients' quality of life and result in psychological stress for patients and their families. Therefore it is unsurprising that facial nerve defect repair is widely studied (4,5).

Current treatments for damaged facial nerves following facial nerve injury include surgical repair, catheter facial nerve repair and molecular repair (6). Most neurotrophic factors are capable of inducing axonal growth and current research is predominantly focused on three groups of neurotrophic factors which are involved in the regulation of endogenous repair processes: Neurotrophic factors, including insulin-like growth factor (IGF)-1, IGF-2 and BDNF, transforming growth factor (TGF)- β , glial cell-derived neurotrophic factor and IL-6 cytokines, including leukemia inhibitory factor (7,8). Treatment with exogenous IGF-1 and IGF-2 improves the rate of axonal regeneration, whereas the application of corresponding antibodies can block this effect (9). The underlying mechanism may involve IGF-mediated activation of RAS/MAPK and PI3K/Akt signaling pathways, thereby inhibiting the apoptosis of neurons and Schwann cells and promoting the growth of axon.

TGF- β superfamily consists of pleiotropic polypeptide growth factors with extensive biological activities, of which TGF- β 3 is a subtype. With the development of tissue engineering, an increasing number of studies have investigated the role of neural regulatory factors in the regeneration of injured facial nerves (10). However, the effects of TGF- β 3 on the repair of injured facial nerves, and the underlying mechanisms, are yet to be elucidated (11-16).

In the present study, a rabbit model was established with trauma sustained to the bilateral superior buccal branches of the facial nerve. In order to facilitate the interior administration of TGF- β 3 to investigate nerve regeneration, a nerve growth chamber was constructed using a silicone tube. Dynamic, continuous and comparative observations of the morphological changes of the repaired nerve were performed at various time

Correspondence to: Dr Muhter Huojia, Department of Oral and Maxillofacial Surgery, People's Hospital of Xinjiang, 91 Tianchi Road, Urumqi, Xinjiang 830001, P.R. China
E-mail: wangyanmeihsz@163.com

*Contributed equally

Key words: facial nerve injury, neural regeneration, transforming growth factor- β 3

points, utilizing various methods. Through a combination of neural electrical physiological detection and image analysis, the effects and possible mechanisms of TGF- β 3 on facial nerve injury repair were investigated.

Materials and methods

Reagents. Paraformaldehyde was obtained from Beijing Chemical Reagent Company (Beijing, China). The JEOL 1230 transmission electron microscope was purchased from JEOL, Ltd. (Tokyo, Japan). The operating microscope and BX26 optical microscope were purchased from Olympus Corporation (Tokyo, Japan). A Canon digital camera was obtained from Canon Inc. (D70; Tokyo, Japan) and the EM UC6 ultramicrotome was purchased from Leica Microsystems (Wetzlar, Germany).

Experimental animals and animal modeling. A total of 20 adult rabbits, weighing 2.5–3.0 kg, were provided by the Department of Experimental Animals of Xinjiang Medical University (Urumchi, China). The rabbits were maintained under standard conditions with *ad libitum* access to food and water. The present study was approved by the Experimental Animal Ethics Committee at Xinjiang Medical University.

Facial nerve trauma and repair models were established in 10 rabbits. Rabbits were anesthetized with 30 mg/kg pentobarbital via the ear vein and a transverse incision was subsequently made in the bilateral cheek to expose ~2 cm of the buccal branches of the facial nerve prior to the transection of ~5 mm of the superior buccal branches of facial nerve. A silicone chamber, to be used as a nerve conduit, was created using a surgical microscope (ASOM-4C; Chengdu Corder Optics & Electronics Co., Ltd., Chengdu, China). In order to form a nerve regeneration chamber (Fig. 1A), the broken ends of the facial nerve were embedded 1.5 mm into a sterile silicon tube (outer diameter, 3 mm; inner diameter, 2 mm; length, 10 mm). Suture fixation of both ends of the epineurium to the silica gel tube was performed using 10-0 thread. A collagen sponge was used for support and as a vehicle for TGF- β 3 implantation. Following this, the right silicone chambers were loaded with 10 μ l TGF- β 3 (50ng/ μ l) and were used as the TGF- β 3 treatment group (n=10); whereas the left chambers were filled with phosphate-buffered saline and used as the surgical control group (n=10). The wounds were subsequently sutured using 4-0 thread. A total of 10 rabbits were randomly assigned to the normal control group, and did not receive any treatment.

Examination of gross morphology. Preoperative and postoperative changes in the vibrissal movements of the rabbits were observed, including trembling symptoms. Gross morphology, anastomosis of neural connections, stump neuroma and scars on the buccal branches of the facial nerve were examined 12 weeks post-operation.

Hematoxylin and eosin (HE) staining. Rabbits were anaesthetized using 3% pentobarbital sodium and sacrificed via strangulation. The rabbits were perfused with 4% paraformaldehyde, via the heart, for fixation and proximal and distal allograft neural tissue samples (length, ~1 mm) were

subsequently collected from each group. Briefly, the buccal branch of the facial nerve was exposed. Subsequently, the facial nerve was dissected 5 mm from the distal end of the silicone tube and 5 mm from the proximal end of the silicone tube. Following removal of the silicone tube, the facial nerve specimens were harvested. Specimens were fixed with 4% paraformaldehyde, embedded in paraffin, sliced into sections and stained with HE. Subsequently, >20 fields in each specimen were randomly selected for observation of the regenerated nerve fibers. The number and diameter of regenerating nerve fibers in the cross-section of the regenerated nerve and the longitudinal section of the proximal anastomosis were observed using light microscopy (SZM-45B1; Zhong Tu Ao Si Micro-Optical Equipment Company, Shenzhen, China, Shenzhen, China).

Light microscopy and transmission electron microscopy examination. The neural tissue samples were fixed with 2.5% glutaraldehyde at 4°C for 6 h prior to immobilization with 1% osmic acid and subsequent gradient acetone dehydration. Following this, the tissues were washed with 0.1 M phosphate buffer solution, embedded overnight with anhydrous Epoxy resin 618 (Wuxi Resin Factory, Wuxi, China) and incubated in the dryer for pure embedding at 37°C for 2 h and 60°C for 48 h, until the resin had totally polymerized. Part of the embedded tissue was sliced into semi-thin sections and stained with toluidine blue (Shanghai Mai Ke Lin Biochemical Company, Shanghai, China). Ten sections of each specimen were used for examination of the regenerated nerve using light microscopy. Part of the embedded tissue was sliced into ultrathin sections, saturated with uranyl acetate for 30 min and stained with citric acid for 15 min. Subsequently >20 fields in each specimen were randomly selected for observation of regenerated nerve fibers. The ultrathin sections of the regenerated nerves were observed under a transmission electron microscope.

Electrophysiological examination. The compound muscle action potentials of the facial nerve were detected using an electromyogram evoked potential instrument (A3101-b; Shanghai Hai Shen Medical Electronic Instrument Co., Ltd., Shanghai, China), 12 weeks post-operation. The latency period and amplitude values of the facial nerve action potentials were recorded and analyzed using SPSS 16.0 software (SPSS, Inc., Chicago, IL, USA).

Statistical analysis. All data were analyzed by SPSS 16.0 software. Paired t-tests were performed to analyze the difference between the treatment and control groups. Data are presented as the mean \pm standard deviation. $P < 0.05$ was considered to indicate a statistically significant difference.

Results

Changes in gross morphology. In order to determine whether TGF- β 3 had an effect on nerve regeneration, the general condition and gross morphology of the rabbits in the various groups were observed. The general condition of the rabbits was observed immediately after surgery, various facial paralysis symptoms were detected in all of the rabbits with facial

nerve trauma, including: Varying degrees of photophobia, a pendulous ear on the operative side, 1-2 cm eyelid distance, a drooping upper lip, and a failure to completely close eyelids, even following stimulation (Fig. 1B).

A total of 12 weeks after the operation, the original incision was reopened under general anesthesia, in order to assess the repair of the nerve injury. The silicone tube was encapsulated by fibrous connective tissue in both the TGF- β 3 treatment and surgical control groups (Fig. 2A and B), as observed with the naked eye. Furthermore, when the connective tissue was dissected from the translucent silicone tubes, both ends of the nerve had successfully crossed the defect area and connected; however, the wall of the silica gel tube had no adhesion with the regenerated nerve and it was easy to separate them. In the TGF- β 3 treatment group, the diameters of the regenerated nerves were similar to those of the nerve stems in the distal and proximal ends. Furthermore, no neuroma was detected and the newly formed epineurium comprised of a complex network of blood vessels gray in color, and was firm and tough, as demonstrated by the visible tension caused by pulling with tweezers without snapping (Fig. 2C). In the surgical control group, the end of the regenerated nerve was slightly thicker and the nerve appeared delicate, with poor elasticity; therefore, it was easy to break (Fig. 2D). The results suggest that the general condition and gross morphology of the damaged facial nerves was improved following treatment with TGF- β 3.

Observation of the regenerated facial nerve using a light microscope. In order to analyze the effects of TGF- β 3 on the regeneration of facial nerves, the number and diameter of the regenerated nerve fibers were measured at 12 weeks post-operation. As outlined in Table I, the total number and diameter of the regenerated nerve fibers was significantly increased ($P < 0.01$) in the TGF- β 3 treatment group (1052.00 ± 144.34 root and 6.16 ± 0.45 cm), as compared with those in the surgical control group (555.30 ± 86.74 root and 3.59 ± 0.61 cm).

In the TGF- β 3 treatment group, the epineurium of the facial nerve was intact and the nerve fibers were morphologically intact and arranged in neat rows with visible myelin swelling. However, in the surgical control group, the epineurium was incomplete, atrophy was detected in the nerve fiber, the axons had partially disappeared, and the myelin was of uneven thickness with fuzzy borders.

In order to observe any pathological changes in the newly regenerated nerve fibers, the facial nerves were subsequently stained with HE and examined. As demonstrated in Fig. 3A, numerous regenerated nerve fibers were observed in the cross sections from the TGF- β 3 treatment group, and the majority of these fibers formed into bundles containing blood vessels. Furthermore, hypertrophy and hyperplasia of the Schwann cells was visible, the size of the regenerated fibers was not uniform, the nuclei were thick, and in the longitudinal sections, the regenerated nerve fibers twisted in parallel across the distal anastomosis. In the cross sections obtained from the surgical control group (Fig. 3B), minimal newborn nerve fibers and few myelin fibers were detected, in addition to fat cell infiltration and considerable scar tissue. In the longitudinal sections, the nerve fibers were arranged

Table I. Comparison of the total number and diameter of the regenerated nerve fibers at 12 weeks post-operation ($n=10$).

Group	Total number (root)	Diameter (μm)
TGF- β 3 treatment	1052.00 ± 144.34	6.16 ± 0.45
Surgical control	555.30 ± 86.74	3.59 ± 0.61
T-value	9.327	10.689
P-value	< 0.001	< 0.001

Data are presented as the mean \pm standard deviation. TGF, transforming growth factor.

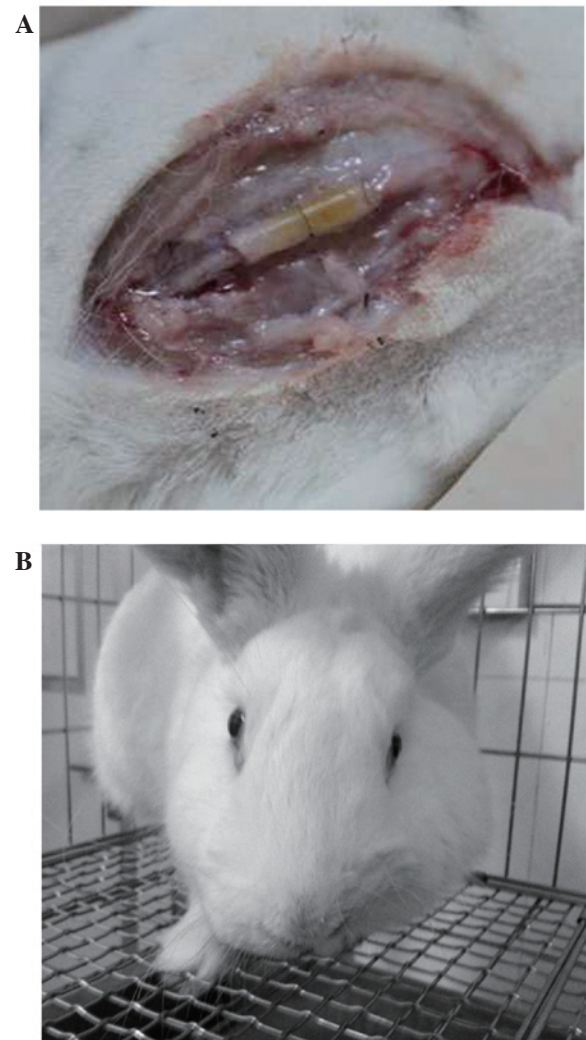


Figure 1. Representative nerve regeneration chamber and facial symptoms in a rabbit model for the regeneration of facial nerves. (A) To form the nerve regeneration chamber, both broken ends of the transected superior buccal branches of facial nerve were embedded 1.5 mm into a sterile silicon tube (outer diameter, 3 mm; inner diameter, 2 mm; length 10 mm). (B) Representative facial symptoms of a rabbit with facial nerve injury. Facial paralysis symptoms were observed.

in a disordered and discontinuous manner and some were partially dissolved. The regenerated nerve fibers with obvious distortions presented as spirals with substantial scar tissue. In addition, the axons were unevenly distributed and their

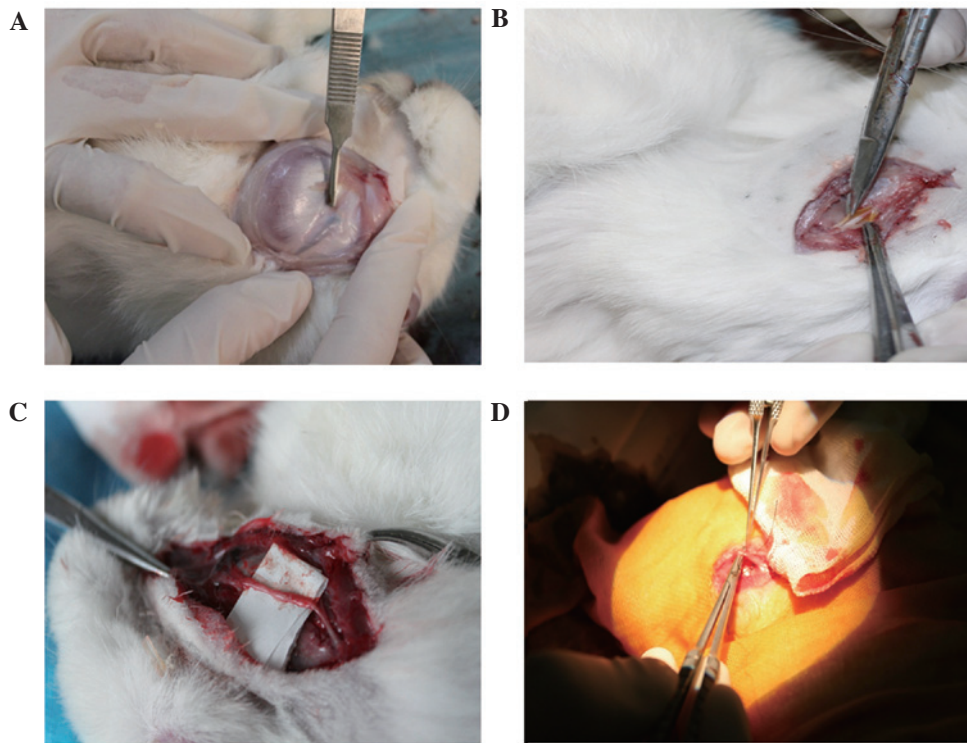


Figure 2. Gross morphological observations of the (A and B) nerve regeneration chamber and (C and D) regenerated facial nerve, as observed at 12 weeks post-operation. (A and C) Representative images of the transforming growth factor (TGF)- β treatment and (B and D) the surgical control groups.

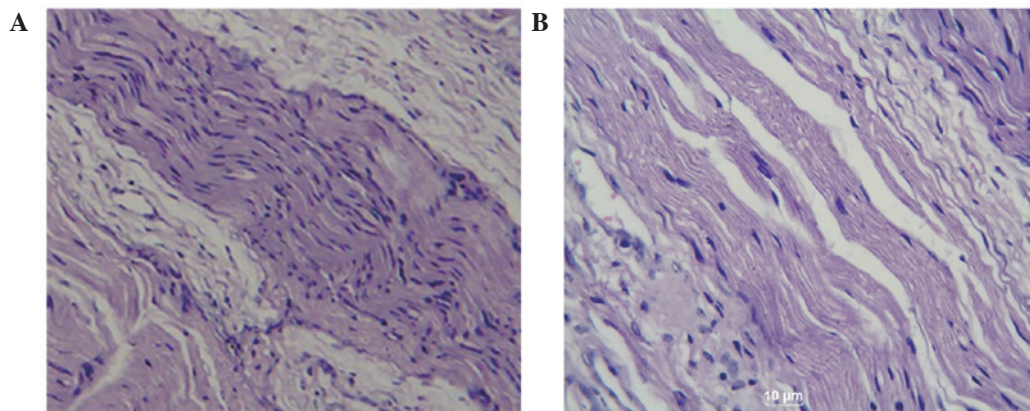


Figure 3. Histological observation of the regenerated facial nerves. Hematoxylin and eosin (HE) staining was performed in order to observe the regenerated facial nerves at 12 weeks post-operation. Representative HE staining images are shown (magnification, x40). (A) The transforming growth factor (TGF)- β treatment and (B) the surgical control groups.

numbers were significantly reduced, with no obvious myelin sheath. Collectively, these results suggest that TGF- β may effectively promote the repair of transected facial nerves.

Observation of the facial nerve under a transmission electron microscope. In order to analyze the structure of the regenerated nerve fiber, the regenerated facial nerve was observed under a transmission electron microscope. As outlined in Fig. 4A and B, the regenerated facial nerves in the TGF- β treatment group were predominantly myelinated nerves with regular form. Furthermore, the layered structure of the myelin sheath was clear with distinct dark and light banding and there were abundant organelles in the axoplasm.

Notably, most of the regenerated fibers formed into bundles with rich blood vessels; whereas in the surgical control group, nerve regeneration and repair only occurred in five injured facial nerves. The remaining facial nerve injuries demonstrated scar tissue and when the ultrathin sections were observed under a transmission electron microscope the regenerated nerve fibers were irregular in shape. In addition, the axoplasmic organelles were unclear, the lamellar structures were disordered, and myelin dysplasia and degeneration of the nerve fiber was observed (Fig. 4C and D). These results suggest that 12 weeks post-operation, the regenerated facial nerve fibers of rabbits in the experimental group were predominantly myelinated nerve fibers with a clear lamellar

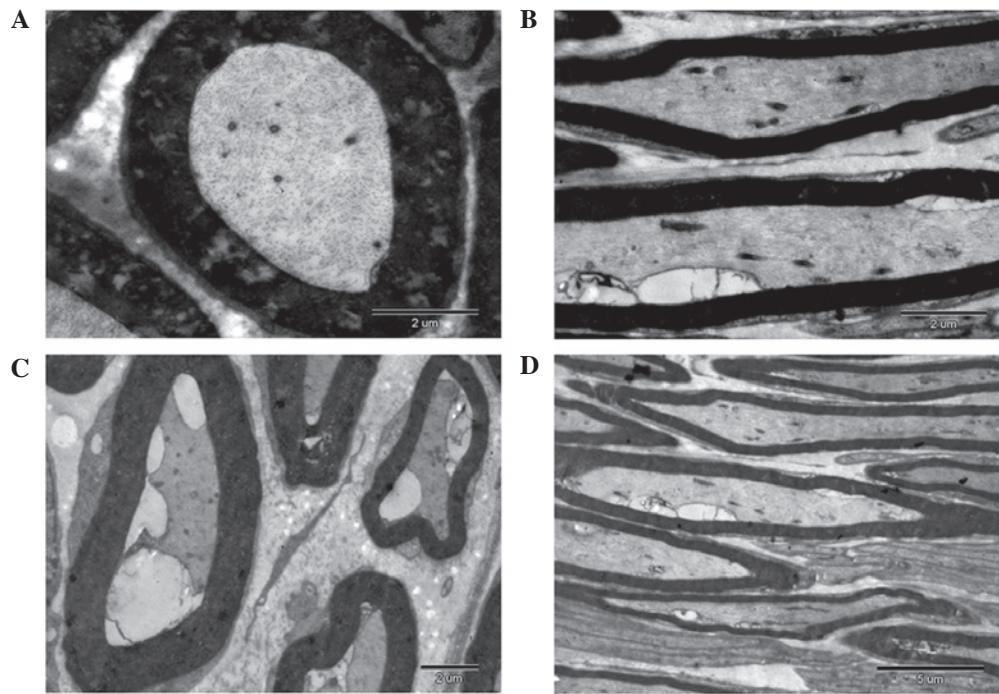


Figure 4. Observation of regenerated facial nerves under transmission electron microscope. At 12 weeks post-operation, semi-thin and ultra-thin sections of regenerated facial nerve tissues were observed under a transmission electron microscope. Representative images are shown (magnification, $\times 6,000$). (A) Cross section of the facial nerve in the transforming growth factor- $\beta 3$ treatment group. (B) Longitudinal section of facial nerve in the TGF- $\beta 3$ treatment group. (C) Cross section of the facial nerve in the surgical control group. (D) Longitudinal section of facial nerve in the surgical control group.

Table II. Comparison of the latency period and amplitude of action potentials at 12 weeks post-operation ($n=10$).

Group	Latency period (ms)	Amplitude (mV)
TGF- $\beta 3$ treatment	$2.35 \pm 0.41^{a,b}$	$8.60 \pm 1.87^{a,b}$
Surgical control	3.42 ± 0.56^a	4.62 ± 0.77^a
Normal control	1.47 ± 0.42	11.32 ± 5.36
T-value	8.596	23.731

Data are presented as the mean \pm standard deviation. ^a $P < 0.01$ vs. the normal control group; ^b $P < 0.01$ vs. the surgical control group. TGF, transforming growth factor.

structure and rich axoplasmic organelles, as compared with the control group.

Electrophysiological examination. To evaluate the functional recovery of the facial nerves, an electrophysiological examination was performed 12 weeks post-operation. In order to detect the compound muscle action potentials of the facial nerve, latency period and amplitude values were recorded and analyzed using an electromyogram evoked potential instrument. As shown in Table II, the action potential latency periods were increased in the surgical control (3.42 ± 0.56 msec) and TGF- $\beta 3$ treatment groups (2.35 ± 0.41 msec), as compared with the normal control groups (1.47 ± 0.42 msec). The latency periods of the action potentials in the TGF- $\beta 3$ treatment group were significantly decreased ($P < 0.01$), as compared with the surgical control group. As compared with the normal

control group (11.32 ± 5.36 mV), the amplitudes of the action potentials in the surgical control group (4.62 ± 0.77 mV) were significantly decreased ($P < 0.01$); whereas a significant increase ($P < 0.01$) was detected in the TGF- $\beta 3$ treatment group (8.60 ± 1.87 mV). These results suggest that administration of TGF- $\beta 3$ into the regeneration chamber following the transection of the superior buccal branches of the facial nerve may significantly promote the conduction velocity of the facial nerve.

Discussion

Regeneration of an injured nerve is a complex process and it is a comprehensive reflection of the reconstruction of neural pathways, recovery of metabolism and functional repair (17,18). Commonly used methods for the repair of nerves include: Autologous nerve transplantation, nerve allograft transplantation, end-to-end anastomosis, facial nerve transplantation, vascularized nerve graft and non-nervous tissue transplantation (19-21). End-to-end anastomosis cannot be performed when there is a large defect in the facial nerve, therefore the most effective method for the repair of facial nerves with larger defects is an autologous nerve transplantation (22,23). However, for peripheral nerve defects involving thick and long segments this method is not appropriate, as the autologous nerve graft source is difficult to acquire and the following problems may occur: Neuroma formation, scarring in the donor area, sensorimotor disorder and errors in the neural network (24,25). It has been suggested that nerve conduit technology may be an effective method to solve these problems; Lundborg *et al* (26) demonstrated that silicone tubes could be

used for nerve defect repair and this promoted the development of nerve catheter technology. Previous studies (27,28) have used nerve substitutes and various materials in the repair of facial nerve injury and have demonstrated that nerve catheter orientation and the nutrition of the regenerative microenvironment have a vital role in regeneration of the damaged nerve. Therefore, the use of nerve regeneration chambers to alter the regenerative microenvironment and the addition of nerve regeneration factors into the chamber is now widely used in neural regeneration (29,30).

In the present study, a silicone tube was used as a nerve conduit to simulate the epineurium, and a collagen sponge with a 3D network structure was used for support and as a vehicle for TGF- β 3 implantation. The nerve conduit provided a combination of nutrition, support and contact guidance as the chamber prevented the formation of scar tissue and the invasion of connective tissue, in addition to maintaining the stability of the microenvironment for nerve regeneration.

The results of the present study demonstrated that administration of TGF- β 3 into the regeneration chamber may effectively promote the growth and maturity of regenerating facial nerves. The repair effects demonstrated by the TGF- β 3 treatment group were significantly improved, as compared with the surgical control group. Therefore, the local application of TGF- β 3 may significantly increase the diameter of axons and nerve conduction velocity, and accelerate facial nerve fiber regeneration and myelination, thus promoting the overall repair of facial nerves.

In conclusion, TGF- β 3 may promote the regeneration of facial nerves following trauma; however, the process of facial nerve repair is rather complicated. Therefore, whether TGF- β 3 can be used clinically remains unknown and requires further investigation.

Acknowledgements

The present study was supported by the National Natural Science Foundation of China (grant no. 30960423).

References

- Malik TH, Kelly G, Ahmed A, et al: A comparison of surgical techniques used in dynamic reanimation of the paralyzed face. *Otol Neurotol* 26:284-291, 2005.
- Guntinas-Lichius O, Streppel M, and Stennert E: Postoperative functional evaluation of different reanimation techniques for facial nerve repair. *Am J Surg* 191:61-67, 2006.
- Yetiser S and Karapinar U: Hypoglossal-facial nerve anastomosis: a meta-analytic study [J]. *Annals of Otolaryngology & Laryngology* 116:542-549, 2007.
- Lloyd BM, Luginbuhl RD, and Brenner MJ: Use of motor nerve material in peripheral nerve repair with conduits. *Microsurgery* 27:138-145, 2007.
- Ignatiadis IA, Yiannakopoulos CK, and Barbitsioti AD: Diverse types of epineural conduits for bridging short nerve defects. An experimental study in the rabbit. *Microsurgery* 27:98-104, 2007.
- Serpe CJ, Byram SC, Sanders VM, and Jones KJ: Brain-derived neurotrophic factor supports facial motoneuron survival after facial nerve transection in immunodeficient mice. *Brain, Behavior, and Immunity* 19:946-949, 2005.
- Indrawattana N, Chen G, Tadokoro M, Shann LH, Ohgushi H, Tateishi T, Tanaka J and Bunyaratvej A: Growth factor combination for chondrogenic induction from human mesenchymal stem cell. *Biochem Biophys Res Commun* 320: 914-919, 2004.
- Saber SE: Tissue engineering in endodontics. *J Oral Sci* 51: 495-507, 2009.
- Chen SY, Li YX, Ma Xin, Chen JS, Zhou GY, and Gong ZX: Experimental study on the effect of extrinsic insulin-like growth factor-2 on the healing of skeletal muscle contusion. *Zhong Guo Yun Dong Yi Xue Za Zhi* 3: 23-26, 2002.
- Markou N, Pepelessi E, and Kotsovilis S: The use of platelet-rich plasma combined with demineralized freeze-dried bone allograft in the treatment of periodontal endosseous defects: a report of two clinical cases. *Journal of the American Dental Association* 141:967-978, 2010.
- Baardsnes J, Hinck CS, Hinck AP and O'Connor-McCourt MD: Tbetar-II discriminates the high- and low-affinity TGF-beta isoforms via two hydrogen-bonded ion pairs. *Biochemistry* 48: 2146-2155, 2009.
- Boillée S, Cadusseau J, Coulpier M, Grannec G and Junier P: Transforming growth factor alpha: A promoter of motoneuron survival of potential biological relevance. *J Neurosci* 21: 7079-7088, 2001.
- Caron PL, Fréchette-Frigon G, Shooner C, Leblanc V and Asselin E: Transforming growth factor beta isoforms regulation of Akt activity and XIAP levels in rat endometrium during estrous cycle, in a model of pseudopregnancy and in cultured decidual cells. *Reprod Biol Endocrinol* 7: 80, 2009.
- Memon MA, Anway MD, Covert TR, Uzumcu M and Skinner MK: Transforming growth factor beta (TGFbeta1, TGFbeta2 and TGFbeta3) null-mutant phenotypes in embryonic gonadal development. *Mol Cell Endocrinol* 294: 70-80, 2008.
- Jin EJ, Lee SY, Jung JC, Bang OS and Kang SS: TGF-beta3 inhibits chondrogenesis of cultured chick leg bud mesenchymal cells via downregulation of connexin 43 and integrin beta4. *J Cell Physiol* 214: 345-353, 2008.
- Sasaki R, Aoki S, Yamato M, Uchiyama H, Wada K, Okano T and Ogiuchi H: Neurosphere generation from dental pulp of adult rat incisor. *Eur J Neurosci* 27: 538-548, 2008.
- Shan ZQ, Wang XB, Zhao L and Yu GS: Anatomy and application of extracranial section of rat facial nerve. *Zhong Guo Jie Pou Xue Za Zhi* 28: 82-83, 2005 (In Chinese).
- Gallo D, Zannoni GF, Apollonio P, Martinelli E, Ferlini C, Passetti G, Riva A, Morazzoni P, Bombardelli E and Scambia G: Characterization of the pharmacologic profile of a standardized soy extract in the ovariectomized rat model of menopause: Effects on bone, uterus, and lipid profile. *Menopause* 12: 589-600, 2005.
- Liao JM, Xu DC and Zhong SZ: Research progress on repair donors of the facial nerve defects. *Lin Chuang Jie Pou Xue Za Zhi* 22: 222-223, 2004 (In Chinese).
- Koshima I, Nanba Y, Tsutsui T, Takahashi Y and Itoh S: New one-stage nerve pedicle grafting technique using the great auricular nerve for reconstruction of facial nerve defects. *J Reconstr Microsurg* 20: 357-361, 2004.
- Jin H and Hou LJ: Study on traumatic facial nerve injury: Recent progress. *Di Er Jun Yi Da Xue Bao* 29: 1248-1250, 2008 (In Chinese).
- Wang WH, Xu B, Zhu J and Xia B: Expressions of BCL-2 and P53 in neurons following facial nerve injury. *Xian Dai Kou Qiang Yi Xue Za Zhi* 23: 155, 2009 (In Chinese).
- Donzelli R, Maiuri F, Peca C, Cavallo LM, Motta G and de Divitiis E: Microsurgical repair of the facial nerve. *Zentralbl Neurochir* 66: 63-69, 2005.
- Malik TH, Kelly G, Ahmed A, Saeed SR and Ramsden RT: A comparison of surgical techniques used in dynamic reanimation of the paralyzed face. *Otol Neurotol* 26: 284-291, 2005.
- Guntinas-Lichius O, Streppel M and Stennert E: Postoperative functional evaluation of different reanimation techniques for facial nerve repair. *Am J Surg* 191: 61-67, 2006.
- Lundborg G and Hansson HA: Nerve regeneration through preformed pseudosynovial tubes. A preliminary report of a new experimental model for studying the regeneration and reorganization capacity of peripheral nerve tissue. *J Hand Surg Am* 5: 35-38, 1980.
- Huang XW, Tao ZZ, Cui YH and Zhang P: The study on facial nerve regeneration guided by chitin guidance channel. *Lin Chuang Kou Qiang Yi Xue Za Zhi* 19: 26-27, 2003 (In Chinese).
- Zhou CY and Luo WL: Preliminary experimental study on the facial nerve regeneration in silicone chamber: the influence of hepatocyte growth factor. *Chong Qing Yi Xue Za Zhi* 32: 299-300, 2003 (In Chinese).
- Luo WL and Zhang H: Study on role of thyroid hormone in repair of rabbit facial nerve injury. *Chong Qing Yi Xue Za Zhi* 36: 1121-1123, 2007 (In Chinese).
- Guo BF, Dong MM and Ren XH: Effect of neural stem cell transplantation on rabbit facial nerve defect repair. *Zhong Guo Er Bi Yan Hou Tou Jing Wai Ke* 9: 6-8, 2005 (In Chinese).