

Sewing needles in the lungs of children

Two case reports

Xicheng Deng, MD*, Peng Huang, MD, Jinghua Wang, MD, Liwen Yi, MD, Jian Liu, MD, Guangxian Yang, MD

Abstract

Rationale: Foreign bodies are common in children. However, it is uncommon to have a “sewing needle” penetrating the body percutaneously rather than via a natural orifice. Such cases have been reported from across the world, with needles being found in regions such as the cranium, abdomen, limbs, neck, scrotum, and buttocks. Few cases with a needle inserted in the lung have been reported.

Patient concerns: We present 2 cases where the needles were found in the chest wall/lung because of suspected child abuse. In the first case, foreign bodies were present in the chest wall and the lung. In the other case, the pointed end was oriented towards, and was very close to, the great arteries.

Diagnoses: Both cases were diagnosed incidentally when chest X-ray was being performed for other reasons.

Interventions: Surgery was indicated for both cases, and the needles were excised uneventfully.

Outcomes: The postoperative course in both cases was uneventful.

Lessons: It is worth noting that in both cases, neither the guardians nor the victims themselves could tell when and how the needles got lodged in the lungs. Collective information suggested that these 2 cases probably involved child abuse. Child abuse in China has long been underestimated and underrecognized. There is still much left to do to tackle this important issue, especially in rural areas.

Abbreviations: CT = computed tomography, CXR = chest X-ray.

Keywords: child abuse, foreign bodies, lung, sewing needles

1. Introduction

Foreign bodies are commonly found in children.^[1] However, it is uncommon to find a “sewing needle” penetrating the body percutaneously rather than via a natural orifice. Such cases have been reported from across the world, with needles being found in regions such as the cranium, abdomen, limbs, neck, scrotum, and buttocks.^[2–7] Most of the reported cases were related to child abuse.

Child abuse in China has long been underestimated and underrecognized, especially in rural areas. Abuse is common and is biased towards girls owing to traditional social and family value norms. Heavy labor work, physical punishment, and violence, as well as deprivation of educational opportunities remain an issue, especially in the inland countryside.

We present 2 rare cases, where the needles were found in the chest/lung of the children, as a result of suspected child abuse. Both guardians for the patients provided written informed consent for the publication of the respective cases.

1.1. Case 1

A 5-year-old girl was accompanied by her parents to the outpatient clinic of our hospital for an incidentally found foreign bodies in the chest. The day before coming to our hospital, she had gone to a local hospital for a cold. Chest X-ray (CXR) showed 2 needle-like foreign bodies in the right chest close to the spine and posterior chest wall (Fig. 1). Neither her parents nor her grandmother, who normally looked after her, had any idea about how or when these “needles” got in her body. She felt no pain or discomfort. There were no evident positive findings on physical examination. No scarring or bruising was observed at the surface of the posterior chest wall. A chest computed tomography (CT) was performed to confirm the positions of the foreign bodies and their relationships with the adjacent chest wall and the lung. The CT revealed that 1 needle was partly in the chest wall and partly in the lung, and the other was completely surrounded by the lung tissue.

Following consent from her parents, she was admitted to the department of cardiothoracic surgery for an elective operation for retrieval of the foreign bodies. The chest was opened through a small posterolateral incision in the 8th intercostal bed. The surgical findings were consistent with preoperative CXR and CT images. A 2.5-cm-long segment of the needle was lodged in the chest wall and adhesive tissue and the other 3-cm-long segment was completely surrounded by tissue in the right lower lobe (Fig. 2). We were able to piece them together into a complete

Editor: N/A.

The authors report no conflicts of interest.

Department of Cardiothoracic Surgery, Hunan Children's Hospital, Hunan, China.

* Correspondence: Xicheng Deng, Department of Cardiothoracic Surgery, Hunan Children's Hospital, No. 86 Ziyuan Road, 410007 Changsha, China (e-mail: justindxc@gmail.com).

Copyright © 2019 the Author(s). Published by Wolters Kluwer Health, Inc. This is an open access article distributed under the terms of the Creative Commons Attribution-Non Commercial-No Derivatives License 4.0 (CCBY-NC-ND), where it is permissible to download and share the work provided it is properly cited. The work cannot be changed in any way or used commercially without permission from the journal.

Medicine (2019) 98:15(e15186)

Received: 18 November 2018 / Received in final form: 26 February 2019 /

Accepted: 15 March 2019

<http://dx.doi.org/10.1097/MD.00000000000015186>

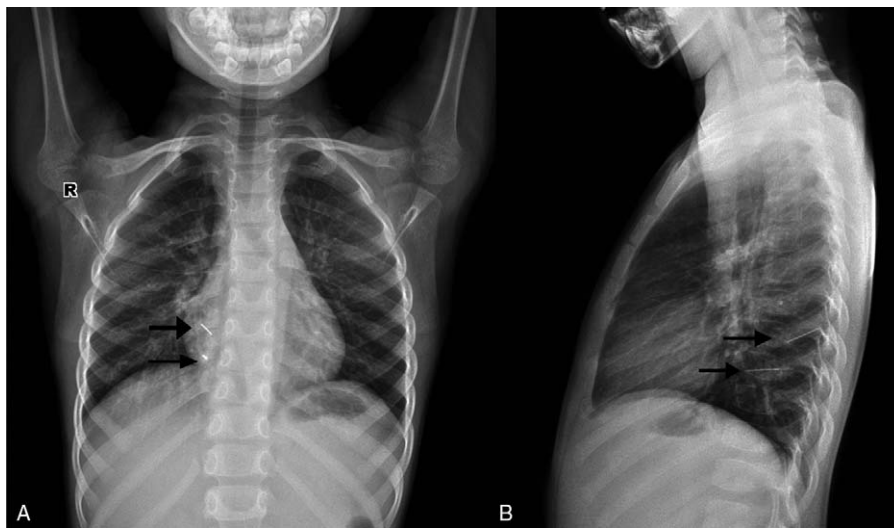


Figure 1. Chest X-ray images in coronal and sagittal views: case 1. Black arrows indicate the segments of the needle.

sewing needle. The segments were strongly attached to the surrounding tissue and severely rusty. The segments were successfully removed, and the patient recovered uneventfully and was discharged 3 days after the surgery.

1.2. Case 2

A 2-year-old girl was referred to our hospital for an incidentally found needle in the chest. In the morning of the presenting day she complained right arm pain without explicit reason. In a local hospital, she was examined with CXR and a needle-like foreign body was observed in the left upper chest (Fig. 3). Her parents had no idea about how or when this “needle” got into her body. She felt no pain or discomfort in the chest. There were no evident positive findings on physical examination except for a tiny little red dot-like papule in the left armpit. A chest CT was performed to confirm the position of the foreign body and its relationship with the adjacent chest wall, the lung, and great arteries. The

pointed end was oriented towards, and was very close to, the great arteries. Since it was an emergency case during midnight, there was no enhanced CT scan. Only a plain CT scan was performed.

Following consent from her parents, an emergency surgery for retrieval of the needle was performed. A small mid-axial incision was made at the level of the 3rd intercostal space. Careful exploration enabled the identification of the bottom end of the needle placed in the chest wall. The needle lay positioned perpendicular to the chest wall. An intraoperative decision was made to not enter the chest, but instead to excise the needle directly. The needle was taken out and inspected, and it was found to be intact. A chest drain was placed through the 6th intercostal space, in case of potential active bleeding from the great arteries. She was monitored closely in the intensive care unit upon return from the operating room. The patient recovered uneventfully and was discharged 7 days after the surgery.

2. Discussion

Foreign bodies, including needles, are common in children.^[1] However, it is uncommon to have a “sewing needle” penetrating the body percutaneously rather than through a natural orifice. Such cases have been reported from across the world with different lodging sites in the body, most frequently in the cranium, among other sites like abdomen, limbs, neck, scrotum, and buttocks etc.^[2–7] However, these are the first 2 cases to our knowledge where a needle was found in the chest/lung as a result of suspected child abuse. Besides the site of the needle, the ages of the patients were also quite different from the other cases reported. Usually, such cases were either as young as infants, especially in those infanticide ones,^[6] or came to a doctor as an adult for positive symptoms.^[7]

The patients in our cases were toddlers or preschoolers. It can be assumed that they were unable to consciously insert a needle into their own bodies. Moreover, although it is possible that the needles inadvertently penetrated them while they played, it is highly improbable their guardians were unaware that a needle had completely penetrated their body. In some cases, it is relatively easy to find out the cause, as exemplified by such events, in an




Figure 2. Retrieved needle segments from case 1. The arrow indicates the eye at one end and the arrow head indicates the pointed tip.

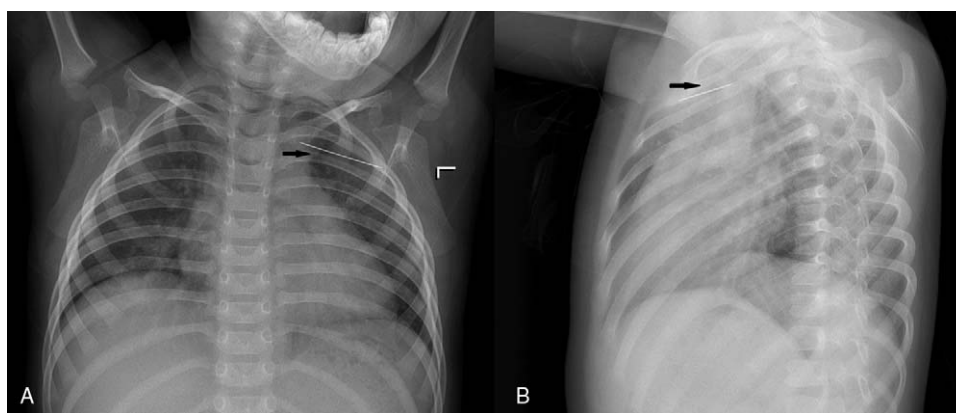


Figure 3. Chest X-ray images in coronal and sagittal views: case 2. Black arrows indicate the needle.

acute stage from child abuse. Children in abusive settings have symptoms and other indicative presentations like bruises on the skin. However, for the present cases which were in a chronic stage, we could only presume that the needles had been penetrated a long time ago, and this was supported by the presence of severe adhesions around the needle, and the broken and rusty nature of the needle. However, we were not able to specify the exact time of the incident, and neither did the parents have any idea about it.

If the patient is referred in the acute phase with signs and symptoms, it is better to take the needle out following a CT scan, under proper operative conditions. For a patient referred in a chronic stage, there are divergent viewpoints on surgical indication, especially for those without symptoms.^[8,9] For the first case, in view of potential inflammation and fibrotic reaction, and rust on needle leading to infection, we decided to take the parts of the needle out. For the second case, the close proximity to the great arteries mandated an emergency surgery. We had planned for potential difficulties in identifying the location of the needles, but they were soon found during the surgery. In the first case, we created a thoracotomy in the appropriate intercostal space, according to the CXR. The inflammation around the needle made it the location straightforward. In the second case, we only made a skin incision as per the CXR. It took approximately 10 minutes to dissect the subcutaneous tissue and muscle and identify the bottom of the needle.

It is reasonable to presume that the girls should have felt pain and cried regardless of the age when the needle was inserted. This therefore raises the question of guardian attendance. With regard to family and social background, both girls were from rural areas. The first girl was left behind by her migrant worker parents and cared for by her grandmother in the countryside as an infant. In the rural areas of China, residents have largely preserved a community/village living lifestyle. The tradition in China, which is maintained more typically in the countryside, is that boys are valued more than girls for socioeconomic reasons. This notion is especially true among older generations. Therefore, it makes girls more susceptible to child abuse than boys, as evidenced in the presented cases. Communication and close contact with other villagers or neighbors are frequent. Additionally, the use of

sewing needles in cities, in China, is rare compared to the relatively common use in the countryside. These factors could put rural children at higher risk for abuse than those living in cities.

Child abuse in China has long been underestimated and underrecognized. Though the recent Red-Yellow-Blue kindergarten abuse scandal^[10] has raised public awareness, there is still much left to do to tackle this issue, especially in rural areas.

Author contributions

Conceptualization: Xicheng Deng.

Investigation: Xicheng Deng, Peng Huang, Jinghua Wang, Liwen Yi, Jian Liu, Guangxian Yang.

Writing – original draft: Xicheng Deng.

Writing – review & editing: Xicheng Deng.

References

- [1] Green SS. Ingested and aspirated foreign bodies. *Pediatr Rev* 2015;36:430–6. quiz 37.
- [2] Alshamrani H, Bakhswain A, Habib Z, et al. Intra-abdominal insertion of sewing needles: a rare method of child abuse. *Ann Saudi Med* 2013;33:505–7.
- [3] Gaur MK, Gupta S. Life-threatening child abuse: penetrating injury of abdomen with sewing needles. *Indian Ped* 2017;54:514.
- [4] Amirjamshidi A, Abbassioun K, Amirjamshidi G. That is why people are frightened of needles!. *Childs Nerv Syst* 2009;25:907–8.
- [5] Fearn C, Kelly J, Habel J, et al. Needle injuries as a cause of non-accidental injury. *Arch Dis Child* 1997;77:187.
- [6] Lukefahr JL, Angel CA, Hendrick EP, et al. Child abuse by percutaneous insertion of sewing needles. *Clin Pediatr* 2001;40:461–3.
- [7] Tuncer N, Yayci N, Ekin G, et al. Intracranial sewing needle in a man with seizure: a case of child abuse? *Forensic Sci Int* 2007;168:V212–4.
- [8] Yolas C, Aydin MD, Ozdikici M, et al. Intracerebral sewing needle. *Pediatr Neurosurg* 2007;43:421–3.
- [9] Amirjamshidi A, Abbassioun K, Rahmat H. Minimal debridement or simple wound closure as the only surgical treatment in war victims with low-velocity penetrating head injuries. Indications and management protocol based upon more than 8 years follow-up of 99 cases from Iran-Iraq conflict. *Surg Neurol* 2003;60:105–10. discussion 10-1.
- [10] China child abuse claims: kindergarten company reveals more complaints. <https://www.theguardian.com/world/2017/nov/30/china-child-abuse-claims-kindergarten-company-ryb-education-more-complaints>. Accessed November 18, 2018.