

Available online at www.sciencedirect.com

ScienceDirect

journal homepage: www.elsevier.com/locate/radcr

Case Report

Hydrocalyx presenting as lumbar pain. A case report and review of the literature ☆☆☆

Klenam Dzefi-Tettey, MB ChB, FWACS, FGCP^{a,*}, Yaw Boateng Mensah, MB ChB, FWACS, FGCP^b, Josephine Mpomaa Kyei, BA(Nursing), MPHIL, PHD^c, Hafisatu Gbadamosi, MB ChB, MGCP, FWACS^a, Mathew Yamoah Kyei, MB ChB, FWACS, FGCS^d

^a Department of Radiology, Korle Bu Teaching Hospital, P.O. Box 77, Accra, Ghana

^b Department of Radiology, University of Ghana Medical School, P.O. Box 4236, Accra, Ghana

^c School of Nursing and Midwifery, University of Ghana, P.O. Box LG 43, Legon, Accra, Ghana

^d Department of Surgery and Urology, University of Ghana Medical School, P.O. Box 4236, Accra, Ghana

ARTICLE INFO

Article history:

Received 3 June 2021

Revised 15 August 2021

Accepted 16 August 2021

Keywords:

Hydrocalyx

Infundibulopelvic stenosis

Fraley's syndrome

Computed Tomography Urography

Calicocalicostomy

ABSTRACT

Hydrocalyx is an obstructed renal calyx from infundibulo-pelvic diminution or stenosis which leads to dilatation of the calyx. It becomes clinically important when associated with flank pains, haematuria, infection, renal impairment or stone formation. On intravenous urography the finding of a cystic dilatation of a calyx that communicates with the renal pelvis supports the diagnosis. This case is A 50-year-old man with recurrent flank pains who was diagnosed with left hydrocalyx on a Computed Tomography Urography (CT Urography). He opted for conservative management. Management of hydrocalyx can be conservative for patients without significant renal damage or symptoms and surgical with nephron sparing intent for those who have severe symptoms and complications.

© 2021 The Authors. Published by Elsevier Inc. on behalf of University of Washington.

This is an open access article under the CC BY-NC-ND license

(<http://creativecommons.org/licenses/by-nc-nd/4.0/>)

Introduction

Hydrocalyx is an obstructed renal calyx from infundibulo-pelvic diminution or stenosis which leads to dilatation of the calyx [1,2] It could be congenital or acquired. It was first described by Rayer in his "traite des Maladies de Reins" in 1841, but

the term hydrocalycosis was first used by KH Watkins, and Winsbury White in 1939 [3].

The clinical presentation is variable and uncharacteristic, it however becomes of concern when associated with flank pain, haematuria, infection, pyocalycosis, renal impairment or stone formation that may present as a curvilinear renal calcification [2,4–6].

☆ Acknowledgments: We thank the 50-year-old-man for allowing us to publish this case report.

☆☆ Competing Interest: The authors declare no conflict of interest

* Corresponding author.

E-mail addresses: k.dzefitettey@kbth.gov.gh (K. Dzefi-Tettey), ybmensah@yahoo.com (Y.B. Mensah), mamejossy@yahoo.com (J.M. Kyei), hafigbadamosi@yahoo.com (H. Gbadamosi), matkyei@yahoo.com (M.Y. Kyei).

<https://doi.org/10.1016/j.radcr.2021.08.042>

1930-0433/© 2021 The Authors. Published by Elsevier Inc. on behalf of University of Washington. This is an open access article under the CC BY-NC-ND license (<http://creativecommons.org/licenses/by-nc-nd/4.0/>)

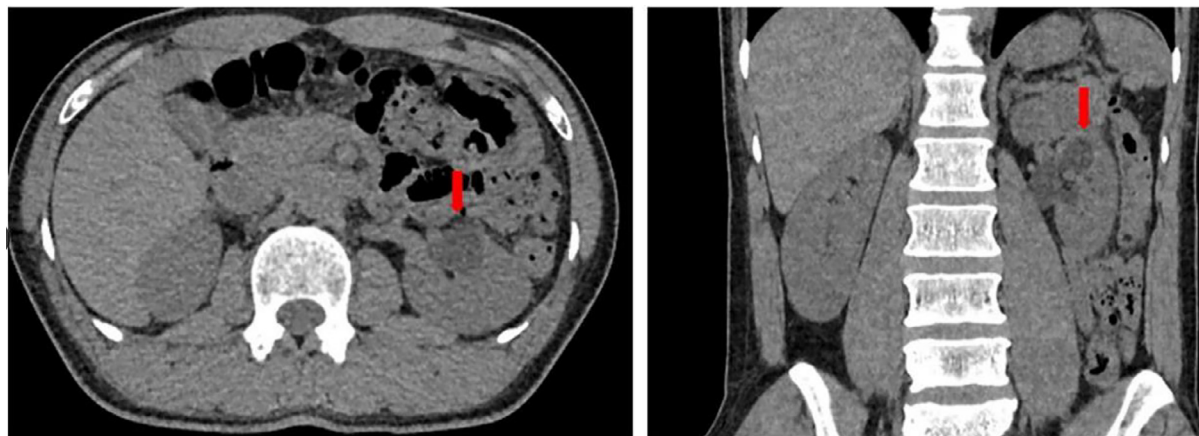


Fig. 1 – CT Urography (axial and coronal reformatted images), pre-contrast phase showing a well-defined hypodense lesion (red arrows) in the mid-polar region of the left kidney simulating a renal cyst. No associated calculi seen (Color version of the figure is available online.)

The investigation of the patient is aimed at diagnosing the condition bearing in mind other differentials like renal cyst, caliceal diverticular, and Fraley's syndrome.

Fraley's syndrome, a rare condition is upper pole caliectasia as a result of an anatomic variant of the renal vasculature leading to compression of the upper pole infundibulum with patients presenting as hematuria, and flank pain [7,8,14].

The treatment of hydrocalyx is observation when it is asymptomatic with no associated complication, and there is no significant danger of renal damage. Surgical intervention is indicated to improve the drainage of the caliectasis when there is pain, hydronephrosis or renal function is getting compromised [1,4] or if complicated by stone formation [5].

This case report is on an adult presentation of a mid-polar hydrocalyx presenting as recurrent flank pain. The patient has given written consent for publication.

Case report

A 50-year-old man presented with recurrent left flank pain of about 6 years duration. He had been evaluated in February 2015 with abdominal ultrasound and diagnosed as a simple renal cyst. Patient had been experiencing mild pain which worsened 2 weeks prior to the current presentation. It did not interfere with his daily activities. There were no aggravating factors. There was no haematuria, lower urinary tract symptoms, gastro-intestinal symptoms or history of trauma. He was not hypertensive or diabetic. Abdominal examination was essentially normal with no palpable left renal mass or costovertebral angle tenderness. A urine analysis was essentially normal with no hematuria or evidence of infection. The blood urea and creatinine were normal. The axial and coronal reformatted images of the pre-contrast phase of the Computerized Tomography Urography (CT Urography) showed a well-defined focal hypodense lesion (red arrows) in the mid-polar region of the left kidney simulating a solitary simple left renal cyst. No associated renal calculi were identified, Fig. 1. The corticomedullary phase also showed the well-defined hypodensity in

the mid-polar region of the left kidney which is illustrated by the red arrows in Fig. 2. The pyelogram phase revealed excretion of the intravenous contrast medium into the renal calyces and the well-defined hypodense lesion in the mid-polar region of the left kidney. This opacified lesion represents a focal dilatation of a mid-polar minor calyx measuring (1.9 × 1.5) cm which has subtle communication with the renal pelvis suggesting hydrocalyx, shown in Fig. 3 and illustrated by the red arrows. Delayed images acquired after 6 hours showed complete opacification and persistence of the excreted contrast medium in the dilated, mid-polar minor calyx in keeping with hydrocalyx (red arrows) Fig. 4. The rest of the collecting systems excreted the contrast medium completely.

Patient is currently being observed because his symptoms are mild and renal function is normal.

Discussion

Caliectasis can be congenital or acquired, single or multiple [1,2] Various presentations like flank pain, hematuria, recurrent infection, stone formation, pyocalicosis, and renal failure have been reported [2,4,5]. We presented a case of caliectasis presenting with left flank pain.

On intravenous urography, a cystic dilatation which communicates with the renal pelvis supports the diagnosis. The infundibulopelvic stenosis can also be visualized on retrograde pyelogram which is performed by introducing a catheter in the ureter with its tip positioned at the distal ureter and a water-soluble contrast medium instilled. The diagnosis in this patient was made during a CT Urography which is superior and now becoming the primary imaging modality of choice for investigating urinary tract abnormalities [9]. A standard technique of CT urography consists of precontrast, nephrographic, and pyelographic or excretory phases. Multi Detector CT Scanner was used and very thin 5 mm slice thickness images acquired. The Pre-contrast images were acquired from the upper abdomen to the pelvis, This initial phase is done to detect any urinary tract calculi and fat containing masses. In this case a well-defined hypodense mass of fluid attenuation was visualized in the mid-polar

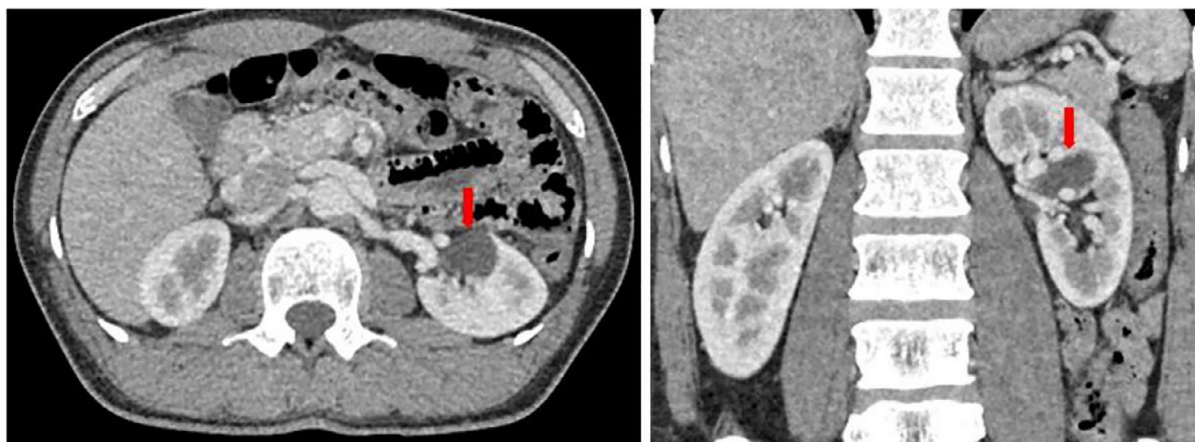


Fig. 2 – CT Urography (axial and coronal reformatted images), corticomedullary phase showing a hypodense lesion (red arrows) in the mid-polar region of the left kidney simulating a renal cyst. No vascular impressions seen (Color version of the figure is available online.)

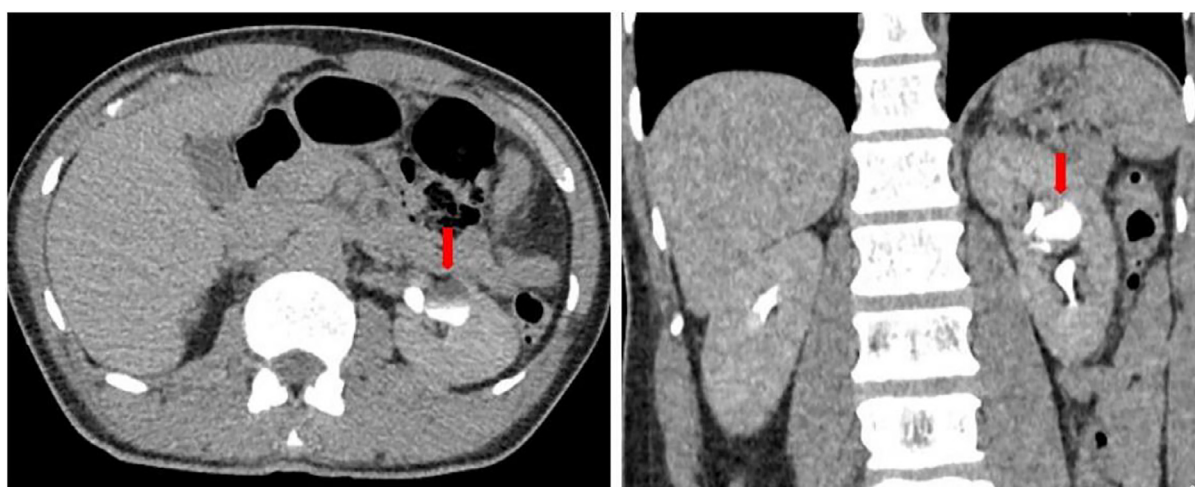

Fig. 3 – CT Urography (axial and coronal reformatted images) excretory phase showing excretion of contrast medium in the hypodense lesion in the mid-polar region of the left kidney which represents a focal dilatation of a mid-pole minor calyx (1.9 x 1.5) cm with subtle communication with the renal pelvis suggesting hydrocalyx (red arrows). The rest of the collecting system is unremarkable (Color version of the figure is available online.)

region of the left kidney simulating a renal cyst. After this, corticomedullary phase images were also acquired 30 seconds after intravenous administration of 100 mLs of 300 mg I/mL of nonionic contrast medium at the rate of 4 mL/s, during this phase the renal cortex enhanced briskly and the medulla enhances only minimally resulting in corticomedullary differentiation. Nephrographic phase images were then acquired after 100 seconds and imaging confined to the kidneys during this phase. These phases evaluate the renal parenchyma and have high sensitivity for renal masses. The hypodense lesion was well demonstrated. The excretory phase images were then acquired 15 minutes to evaluate the urothelium of the pelvicalyceal system, ureters, and the urinary bladder. This phase however showed excretion of contrast medium into the hypodense lesion in the mid-polar region of the left kidney which represents a focal dilatation of a mid-pole minor calyx with subtle communication with the renal pelvis suggesting hydrocalyx. Six hour delayed images

showed complete opacification and persistence of the excreted contrast medium within the dilated, mid-polar minor calyx in keeping with hydrocalyx [10].

Magnetic Resonance Urography (MR Urography) which can be done using either the Static-fluid technique or Excretory MR urography technique is also useful in surgical planning for selective calicocalicostomies [1].

The differential diagnosis that needed to be considered included a simple renal cyst, calyceal diverticulum, and Fraley's syndrome.

In the case of a simple renal cyst, the cyst does not communicate with the calyceal system. An abdominal ultrasound will show an anechoic lesion with thin walls. However, this modality may not be able to show if there is communication with an adjoining calyx. An intravenous urography and one with CT scan will reveal absence of contrast medium in the cyst cavity confirming no point of communication thus excluding calycosis.

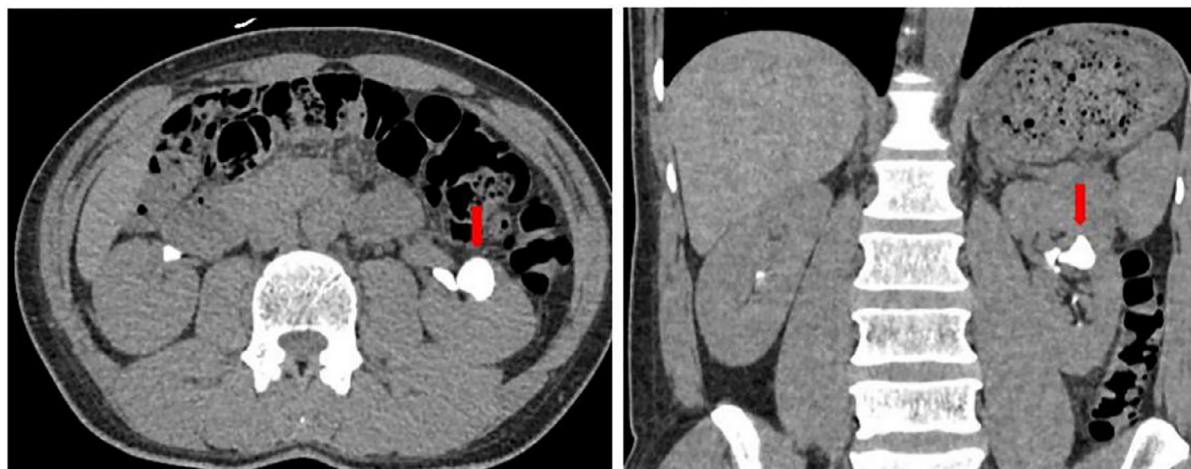


Fig. 4 – CT Urography (axial and coronal reformatted) 6 hour delayed images showing retention of contrast medium in the focally dilated minor calyx which communicates with the renal pelvis in keeping with a hydrocalyx.

A caliceal diverticulum is another important differential diagnosis caused by ventration of the collecting system or out pouching of a calyx, lying within the renal parenchyma, and communicating with the main collecting system but does not directly receive drainage from a renal papilla. Thus no impression of a renal pyramid and/or papilla is seen during an intravenous urography or CT urography as one visualizes the diverticulum. These studies thus may assist in differentiating between hydrocalyx and caliceal diverticulum though observed to be difficult in some situations [2].

Fraley's syndrome is hydrocalycosis of the upper renal pole calyx due to compression of the upper pole infundibulum by a variant of the renal vasculature (posterior segmental artery). This is therefore confined to the upper calyx. To identify the cause or associated vessel, intravenous urography may show a vascular impression on the superior infundibulum with secondary dilatation of the upper pole calyx [9]. Vascular studies such as renal arteriography or renal doppler ultrasonography may identify the associated vessels and so confirm the diagnosis [8,11].

In the case presented, there was a communication of the calycosis with the pelvicalyceal system thus excluding a renal cyst, there was no impression of a papilla excluding a calyceal diverticular, and the calycosis was confined to a mid-polar calyx excluding Fraley's syndrome and thus supporting the diagnosis of hydrocalycosis.

The management depends on the severity of the symptoms and renal damage. In the presence of minimal symptoms and essentially normal kidneys, conservative management with observation is preferred. This was the choice of our patient.

In the case of severe symptoms and complicated cases, surgical intervention is indicated. Surgical intervention is performed to halt or reduce progressive renal insufficiency [1]. There has been an evolution of interventions since its first report. The interventions (calyceal plasties) are aimed at improving the caliceal urine flow by connecting the stenosed calyx to a more patent calyx or reconstructing the narrow portion to achieve dilatation. This leads to un-impeded urine flow and so alleviates the symptoms and prevents re-stenosis [1,4]. Partial nephrectomy has been performed in the presence of pyocalycosis [6]. In the setting of multiple and mega-calycosis with significant re-

nal damage, simple nephrectomy of the affected kidneys is performed.

Laparoscopic nephron-sparing calycectomy is another treatment option [12]. It has been recommended that if laparoscopic ablation is considered, it should ablate all renal parenchyma draining into the affected calyx [2]. Intra renal surgery can also be performed using ureteroscopy with holmium: yttrium-aluminum-garnet (YAG) laser incision to treat infundibular stenosis [13].

In the case of Fraley's syndrome, infundibulo-infundibulostomy, Fraley's infundibulopyelostomy, a Heineke-Mikulicz-type infundibulorrhaphy combined with vasopexy, simple vasopexy, and ligation and division of minor arterial branch have been used [11].

A laparoscopic YV-infundibulo-pyeloplasty with vasculopexy of a posterior segmental renal artery has been reported by Armstrong et al [7]. This was performed without vascular clamping, was considered less destructive and offered significant advantages in terms of intraoperative visualization and perioperative patient morbidity [7].

Conclusion

Hydrocalycosis or hydrocalyx is a rare but important differential in evaluating a patient with flank pain. A careful observation of the calyceal configuration on CT urography assists in arriving at the diagnosis. In cases with no or minimal symptoms and no significant renal parenchymal damage, conservative management is preferred. Surgical intervention with nephron sparing intent (procedures), though evolving, is indicated in the presence of severe symptoms, and complications.

Patient consent

The patient has given consent for this publication.

REFERENCES

- [1] Bayne CE, Peters CA. Congenital infundibulopelvic stenosis: Indications for intervention, surgical technique, and review of literature. *J Pediatr Urol* 2016;12(6):389.e1–389.e5.
- [2] Stuart WJ. Caliceal diverticulum and hydrocalyx: laparoscopic management. *Urol Clin North Am* 2000;77(4):655–60.
- [3] Wilhelmi OJ. Hydrocalycosis. *J Urol* 1949;62(2):206–10. doi:10.1016/s0022-5347(17)68908-0.
- [4] Rigaud J, Catelinau X, Vasse N, Karan G, Buzelin JM, Buchet O. Lumbar pain and hydrocalyx. *Progres en urologie* 2011;11(3):498–501.
- [5] Ataka JH, Pikindil G, Alagol B, Inci O. A new cause of curvilinear renal calcification: calcified hydrocalycosis. *Eur J Radiol* 2000;35(1):16–19.
- [6] Taşkınlar H, Avlan D, Yiğit D, Naycı A. Pyocalycosis: a report of two cases of complicated hydrocalycosis. *Urol Int* 2014;92:119–21. doi:10.1159/000351006.
- [7] Armstrong JM, Soni SD, Link RE. Laparoscopic nephron-sparing treatment of upper pole infundibular obstruction due to fraley's syndrome. *Urol Case Rep* 2015;4:41–4. doi:10.1016/j.eucr.2015.09.003.
- [8] Huang WS, Wu CJ, Wang YF, Jen TK, Cherng SC. Fraley's syndrome seen on bone scintigraphy. *Ann Nucl Med Sci* 2000;13:71–4.
- [9] El-Ghar MA, Refaie H, Sharaf D, El-Diasty T. Diagnosing urinary tract abnormalities intravenous urography or CT urography? *Rep Medical Imaging* 2014;7:55–63.
- [10] Yuh BI, Cohan RH. Different phases of renal enhancement: Role in detecting and characterizing renal masses during helical CT. *AJR* 1999;173:747–55.
- [11] D'Amico A, Lusuuardi L, Ficarra V, Beltrami P, Malossini G, Tallarigo C, et al. Experience in the surgical treatment of Fraley's syndrome. *Eur Urol* 2000;38(4):410–14. doi:10.1159/000020316.
- [12] Porpiglia F, Bertolo R, Checcucci E, Amparore D, Manfredi M, Fiori C. Laparoscopic nephron-sparing calycectomy for treating fraley's syndrome. *Urol Int* 2018;100(2):134–8. doi:10.1159/000486628.
- [13] Kim HL, Gerber GS. Use of ureteroscopy and holmium: yttrium-aluminum-garnet laser in the treatment of an infundibular stenosis. *Urology* 2000;55(1):129–31. doi:10.1016/s0090-4295(99)00385-4.
- [14] Anastasov G, Petkov A. Hydrocalyx (Fraley's Syndrome). *Vutreshni bolesti* 1977;16(3):89–93.