

# Intramedullary cyst formation after removal of multiple intradural spinal arachnoid cysts: A case report

Edvin Zekaj, Christian Saleh, Domenico Servello

Department of Neurosurgery, IRCCS Galeazzi Hospital, Milan, Italy

E-mail: \*Edvin Zekaj - [ezekaj@yahoo.com](mailto:ezekaj@yahoo.com); Christian Saleh - [chs12us75010@yahoo.com](mailto:chs12us75010@yahoo.com); Domenico Servello - [servello@libero.it](mailto:servello@libero.it)

\*Corresponding author

Received: 01 May 16 Accepted: 18 May 16 Published: 07 July 16

## Abstract

**Background:** A rare cause of spinal cord compression is spinal arachnoid cysts. Symptoms are caused by spinal cord compression, however, asymptomatic patients have been also reported. Treatment options depend upon symptom severity and clinical course.

**Case Description:** We report the case of a 47-year-old patient who developed an intramedullary arachnoid cyst after removal of an intradural extramedullary cyst.

**Conclusion:** Surgery should be considered early in a symptomatic disease course. Longstanding medullary compression may reduce the possibility of neurological recovery as well as secondary complications such as intramedullary cyst formation.

**Key Words:** Complication, spinal arachnoid cyst, spinal cord compression

### Access this article online

#### Website:

[www.surgicalneurologyint.com](http://www.surgicalneurologyint.com)

#### DOI:

10.4103/2152-7806.185779

#### Quick Response Code:



## INTRODUCTION

Spinal arachnoid cysts are a rare cause of spinal cord compression.<sup>[1,3]</sup> Cysts may be located in the extradural space or less frequently they are located intradurally,<sup>[3]</sup> however, an intramedullary localization is a rare entity.<sup>[5]</sup> Clinical presentation is secondary to spinal cord compression, but asymptomatic patients have also been reported.<sup>[5]</sup> Several theories have been postulated regarding the possible etiology of intradural arachnoid cysts, such as congenital, post-inflammatory, post-hemorrhagic, and post-traumatic. Cysts can also be secondary to iatrogenic injuries or can be idiopathic.<sup>[4]</sup> With the widespread use of magnetic resonance imaging (MRI), the gold standard diagnostic examination is now spinal MRI. The optimal treatment can be determined only on the basis of radiological diagnosis. A wait-and-see attitude is reserved to asymptomatic patients, whereas surgical treatment is considered with the presentation of progressive neurological deficits, cyst enlargement, or bone erosions.<sup>[2]</sup> There are several surgical options to deal with a spinal cyst such as a total cyst excision when feasible, obliteration of the communicating pedicle for

extradural cyst, or partial cyst excision of cysts adherent to the spine or nerve roots.<sup>[2]</sup>

## CASE REPORT

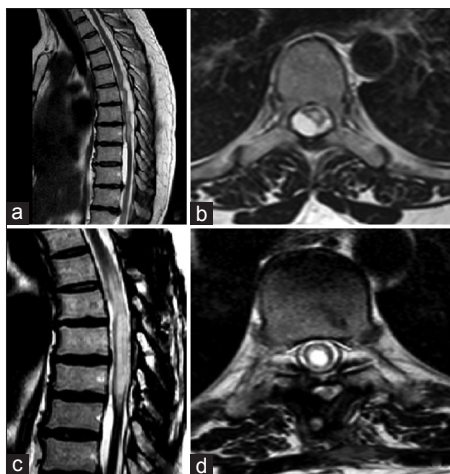We report a 47-year-old female patient with multiple intradural extramedullary spinal arachnoid cysts. The patient's symptoms started 3 years prior to the surgery with right dorsal radicular pain (D5-D6). She was admitted in a neurology department and was treated for herpes zoster with poor improvement of the pain. Two years after the first clinical symptoms, the patient presented with a progressive weakness of the left lower

This is an open access article distributed under the terms of the Creative Commons Attribution-NonCommercial-ShareAlike 3.0 License, which allows others to remix, tweak, and build upon the work non-commercially, as long as the author is credited and the new creations are licensed under the identical terms.

For reprints contact: [reprints@medknow.com](mailto:reprints@medknow.com)

**How to cite this article:** Zekaj E, Saleh C, Servello D. Intramedullary cyst formation after removal of multiple intradural spinal arachnoid cysts: A case report. *Surg Neurol Int* 2016;7:S473-4.

<http://surgicalneurologyint.com/Intramedullary-cyst-formation-after-removal-of-multiple-intradural-spinal-arachnoid-cysts-A-case-report/>

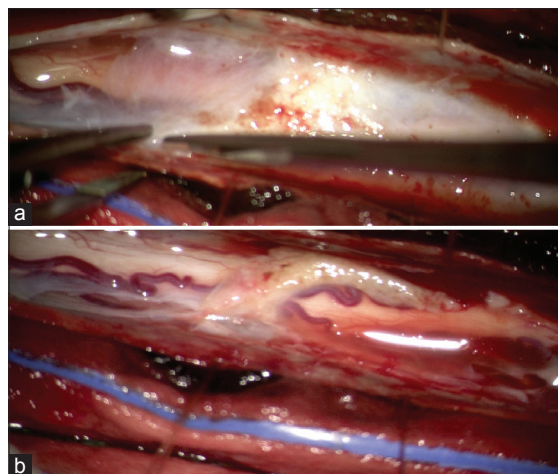


**Figure 1:** (a) Sagittal T2 dorsal magnetic resonance imaging (MRI) sequences showing multiple arachnoid cyst causing an important compression on spinal cord. (b) Axial T2 dorsal MRI sequences showing a cyst that compresses the spinal cord. (c) A sagittal T2 dorsal MRI showing cyst removal and intramedullary dilatation. (d) Axial T2 dorsal MRI showing intramedullary central canal dilatation

limb. The patient underwent a whole spine MRI where dorsal MRI showed multiple intradural arachnoid cysts which caused an important spinal cord compression [Figure 1a and b]. She was followed conservatively in another hospital in a neurosurgical ward. She came to our center 3 years after the appearance of the first symptoms for progression of the neurological deficit in the left lower limb (walking became more difficult) and for the increase in radicular pain at D5–D6 on the right side. We explained to the patient the disease and the treatment options, that is, a wait-and-see approach or a surgical procedure with a total or a partial cyst removal. After careful evaluation of the discussed treatment options, the patient chose the surgical approach. The surgical procedure was uneventful and consisted of a bilateral laminoplasty of D5–D9 with a near total removal of the cysts, leaving only a part of the cyst wall that was tightly attached to the spinal cord. Intraoperatively, a diffuse thickening of the arachnoid and diffuse calcification were seen [Figure 2a]. The aim of our procedure was to obtain a cranial-caudal liquoral communication, which was obtained at the end of the surgery when the spinal cord expanded [Figure 2b]. The patient reported a complete resolution of symptoms in her left lower limb, however, in the first months an important radicular dorsal pain on the right side persisted. The radicular pain responded well to lidocaine plaster. In the radiological follow-up after 3 and 9 months after the surgery, the dorsal MRI showed a dilatation of the central canal with a localized intramedullary arachnoid cyst [Figure 1c and d].

## DISCUSSION

To the best of our knowledge, this is the first report of intramedullary arachnoid cyst formation after removal of



**Figure 2:** Intraoperative photos obtained using operative microscope (Opmi Pentero). (a) Pre-removal arachnoid cyst. A diffuse thickening of arachnoid with calcification. (b) After removal of the arachnoid cyst, when the spinal cord expanded, we left only a part that was tightly attached to the spinal cord

an intradural extramedullary cyst. To date, the patient is without symptoms; we have decided to follow her up conservatively every 6 months using a spine MRI. Only in case of neurological worsening, we will adopt the surgical option. We think that the intramedullary cyst developed due to scar adhesions in the central medullary canal secondary to the long duration of the disease (more than 3 years).

The aim of our report is to bring attention to this rarely known disorder and to highlight that surgery should be proposed in patients with neurological deficits as soon as possible, considering longstanding medullary compression may on one side reduce the possibility of neurological recover and on the other because of a secondary complication such as intramedullary cyst formation. In this context, we believe that radiological follow-up with MRI has to be done at least once during the first year.

## Financial support and sponsorship

Nil.

## Conflicts of interest

There are no conflicts of interest.

## REFERENCES

1. Kazan S, Ozdemir O, Akyuz M, Tuncer R. Spinal intradural arachnoid cysts located anterior to the cervical spinal cord. Report of two cases and review of the literature. *J Neurosurg* 1999;91(2 Suppl):211-5.
2. Kumar S, Desai A, Bhatia L, Garg A. Multiple Spinal Arachnoid Cysts in a Child. *Pediatr Neurol* 2016;55:76-7.
3. Lee HJ, Cho DY. Symptomatic spinal intradural arachnoid cysts in the pediatric age group: Description of three new cases and review of the literature. *Pediatr Neurosurg* 2001;35:181-7.
4. Medved F, Seiz M, Baur MO, Neumaier-Probst E, Tuettenberg J. Thoracic intramedullary arachnoid cyst in an infant. *J Neurosurg Pediatr* 2009;3:132-6.
5. Novegno F, Umana G, Di Muro L, Fraioli B, Fraioli MF. Spinal intramedullary arachnoid cyst: Case report and literature review. *Spine J* 2014;14:e9-15.