

Pure Tethered Cervical Cord and Review of Literature

Abstract

Tethering of the spinal cord in the lumbosacral region with myelomeningocele is a well-known phenomenon. Only sporadic cases of tethering along the rest of the neuraxis, including the hindbrain, cervical, and thoracic spinal cord have been documented, always along with some associated congenital malformations (hydrocephalus, Chiari malformation, myelomeningocele, meningocele, hamartomatous stalk, spina bifida occulta, intramedullary lipoma, intradural fibrous adhesions, the fusion of the sixth and seventh cervical vertebrae, split cord malformation, or low-lying cord). In this report, 14-year-old male developed symptoms related to tethering of the cervical spinal cord, but without any associated congenital malformations, that is the pure tethered cervical cord. This causes his moribund status and makes the manuscript unique and contributes to the hitherto literature. The authors discuss the diagnosis, treatment, and postoperative course of this entity. The uniqueness in treatment is that we have operated the case without the help of intraoperative somatosensory evoked potentials and motor evoked potential from posterolateral approach under local anesthesia.

Keywords: Awake detethering, pure tethered cervical cord, single breadth count

Introduction

Tethering of the spinal cord in the lumbosacral region with or without myelomeningocele is a well-known phenomenon. Tethering along the rest of the neuraxis, including the hindbrain,^[1] cerebellar vermis,^[2] medulla^[3] cervical,^[4-10] and thoracic^[11] spinal cord have been documented. In literature, the tethered cervical cord is always associated with the various congenital malformations (hydrocephalus,^[12] Chiari malformation, myelomeningocele, meningocele, hamartomatous stalk, spina bifida occulta, intramedullary lipoma, intradural fibrous adhesions, the fusion of the sixth and seventh cervical vertebrae, split cord malformation, or low-lying cord). These cases are always operated on with the help of intraoperative somatosensory evoked potentials (SSEPs) and motor evoked potentials (MEPs) which correlated well with clinical improvement following surgery.^[9]

In this report, 14-year-old boy had pure cervical cord tether but without the involvement of associated congenital malformations causing moribund status. We have tackled this unusual case via posterolateral intradural approach without SSEP and MEP control, in local anesthesia, using a microscope to dissect and excise

the tethered cord successfully, being the unavailability of these modalities at very rural areas of a developing country like India.

Case Report

A 14-year-old male presented with dull moderate neck pain followed by bilateral (started from left side then to right side) 6 months later. The numbness was noted to be worse in the left hand. Symptoms were periodic but were getting progressively worse followed by gait disturbances in 2 months and then with quadriplegia since 10 days.

On neurological examination, Glasgow coma score was 15/15; bilateral pupils were normal in size and reacting to light. Physical examination revealed a good range of motion in his neck he had decreased power in the abduction of upper limb to power 2/5, bilateral, with no lower limb movements power 0/5 bilateral below T2. Sensory examination revealed pin prick and fine and crude touch normal up to T1, below that, no sensory sensations present. Bilateral planters were extensors. All lower limbs deep tendon reflexes were hyperactive and superficial reflexes were absent below T2. Single breadth count was at 19 per breadth.

This is an open access article distributed under the terms of the Creative Commons Attribution-NonCommercial-ShareAlike 3.0 License, which allows others to remix, tweak, and build upon the work non-commercially, as long as the author is credited and the new creations are licensed under the identical terms.

For reprints contact: reprints@medknow.com

How to cite this article: Tewari VK, Somvanshi R, Trivedi RB, Hussain M, Das Gupta HK, Dubey RS. Pure tethered cervical cord and review of literature. Asian J Neurosurg 2018;13:72-4.

**Vinod Kumar
Tewari,
Rituj Somvanshi¹,
Ravindra Bihari
Trivedi²,
Mazhar Hussain³,
H. K. Das Gupta⁴,
R. S. Dubey⁵**

Consultant Neurosurgeon,
Mayo Hospital, Vikas Khand I,
¹Consultant Anesthetist, Mayo
Hospital, Vikas Khand I,
²Consultant Radiologist, MVT
Diagnostics, Indiranagar,
³Director And Neurosurgeon,
Sahara Hospital, ⁴Consultant
Urologist, Neuro Center, PSS
Complex, Vishal Khand III,
Gomti Nagar, ⁵Director, General
Surgeon, Samarpan Hospital,
Lucknow, Uttar Pradesh, India

Address for correspondence:
Dr. Vinod Kumar Tewari,
Mayo Hospital Vikas Khand I,
Lucknow - 226 010,
Uttar Pradesh, India.
E-mail: drvinodtewari@gmail.
com

Access this article online

Website: www.asianjns.org

DOI: 10.4103/1793-5482.224834

Quick Response Code:



Patient underwent posterior laminectomy and also the release of suspected arachnoid cyst from the posterior approach at some remote hospital but due to deterioration, he was referred to us.

Plain cervical spine X-ray revealed no cervical vertebra fusion.

Magnetic resonance imaging (MRI) revealed a space-occupying lesion in an anterior part of the cervical cord, extramedullary intradural up to the caudal border of C4 vertebral body. This lesion is continuous with the cerebrospinal fluid (CSF) circulation of cranial cavity from above. There was a band from caudal border of C4 vertebral body to the middle of C4 vertebral body. No post contrast enhancement of the band noted. Cord was seen tethered to the band [Figures 1 and 2]. The spinal cord above C4 was showing stretched and compressed dorsally, with CSF collection. Below C4 spinal cord was seen normal. Brain MRI revealed no hydrocephalus, Chiari malformation at the craniovertebral junction, split cord malformation, or low-lying cord at the lumbosacral region or other anomaly.

The utility of spinal diffusion tensor MRI^[13] is well-known in tethered cord cases but we don't have this facility in our setup.

Preoperative preparation

Due to the posterolateral (right) displacement of compressed cord, limited anterior operative window and the disease started from the left side, we thought of left posterolateral approach because we needed ample space to open the dura and detether it. We did not have intraoperative SSEP and MEP^[11] machines therefore, we decided to operate under local anesthesia and mild IV sedation.

Operative procedure

The patient was positioned semiprone. After giving local anesthesia from occiput to C6 level, a midline incision,

oriented vertically, was given passing the skin from occiput down to the C6 level. The laminectomy had already been done previously from C3 to C5, we extended from a caudal part of C2 to C6 in vertical alignment and more wide lateral dissection of lamina was carried out. Dura was opened in the usual fashion in the midline. After applying holding sutures to the left portion of the cut dura the cervical cord hung downward due to gravity, and thus we reached anterior to cord safely. We tapped the CSF from the vent made earlier at the anterior portion and extended the vent cranially and tangentially to completely open it. Now the microscope was adjusted over tether which revealed whitish fibrous tissues that connected the ventral cervical cord to the ventral dura overlying middle of C4 vertebral body thus stretching it (the cervical cord). These fibrous tissues were taut, further confirming the suspicion of tethered cord. All were subsequently excised and the spinal cord was detethered with each and every time talking to the patient and asking him to move upper limbs and single breadth counts such that we traced the tether up to the maximum of the contralateral side. The dura was repaired and the overlying layers closed without drainage tube. Immediate intraoperative recovery on operation table was noted in the form of increased single breadth count to 32 per breadth.

Discussion

Despite the paucity of reported cases, (Eller *et al.*, 1987) (Pang and Dias, 1993) (Myles, 2002) (Meyer, 2003) it is evident that tethered cervical cord is usually associated with cervical myelomeningocele and meningocele. A taut fibro-neurovascular stalk that extends from the dorsal column of the cord to the dorsal dura of the sac, named limited dorsal myeloschisis, an additional embryological defect (Pang and Dias 1993).

The tethered cervical cord is also due to a hamartomatous stalk in a young adult.^[7] A case of the congenital tethered cervical spinal cord was also presented in a young adult in whom metrizamide computerized tomography was the most

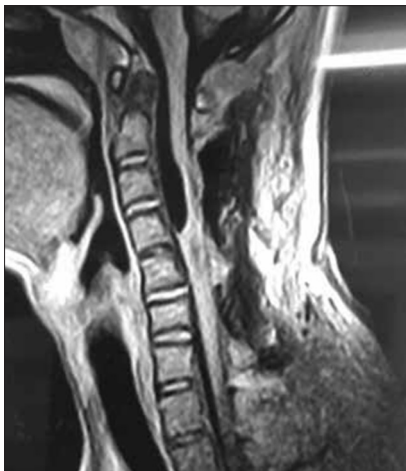


Figure 1: T1 magnetic resonance imaging sagittal – band from caudal of C4 vertebral body to the middle of C4 vertebral body

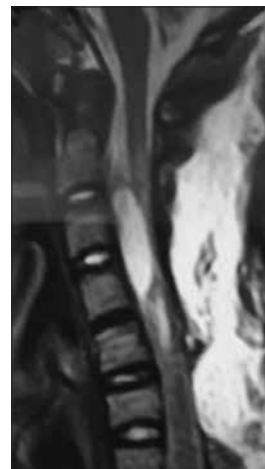

Figure 2: T2 magnetic resonance imaging sagittal

useful imaging technique for identifying the tethered spinal cord. Intraoperative SSEPs correlated well with clinical improvement following surgery.^[9] However our hospital, not being equipped with Intraoperative SSEP and MEP, so we operated under local anesthesia.

Furthermore, a case is reported of the so-called tethered cervical spinal cord syndrome presenting as multiradicular pain on an upper limb in a 45-year-old woman, in whom spina bifida occulta (C6) was associated with an intramedullary lipoma, intradural fibrous adhesions and the fusion of the sixth and seventh cervical vertebrae. In this case, mere surgical release of the tether was ineffective, and the patient underwent a posterior rhizotomy for pain relief.^[10]

In our case which seems to be a pure form of ventral tethered cervical cord the clinical deterioration started since 14th year of age and that too took only 6 months to the moribund status within 10 days. This case was not associated with any form of hydrocephalus, Chiari malformation, myelomeningocele, meningocele, hamartomatous stalk, spina bifida occulta, intramedullary lipoma, intradural fibrous adhesions, the fusion of the sixth and seventh cervical vertebrae, split cord malformation or low-lying cord. This shows this case of the tethered cervical cord is in pure form which was unusual as for as earlier published data is reviewed. The tether has displaced cord caudally as the patient was growing from childhood to young age thus stretching whole of the cord and forming a pseudocyst formation at the local site, which was continuous with the cranial CSF circulation giving suspicion of an arachnoid cyst.

The patient showed immediate intraoperative recovery in the form of increased single breadth count to 32 per breadth and in the first postoperative day to 45 per breadth.

Conclusions

Tethered cord should be highly suspected in cervical arachnoid cyst with or without meningocele or meningomyelocele with intact neurology, especially, if the pseudocyst is continuous with the CSF circulation cranially. The release of cord tethering can be done in local anesthesia without the help of SSEP and MEP.

Financial support and sponsorship

Nil.

Conflicts of interest

There are no conflicts of interest.

References

1. Kernan JC, Horgan MA, Piatt JH. Tethered hindbrain. Case report. *J Neurosurg* 1996;85:713-5.
2. Comey CH, Albright AL. Symptomatic tethering of the cerebellar vermis: Case report. *Neurosurgery* 1994;34:177-80.
3. Muroi A, Fleming KL, McComb JG. Split medulla in association with multiple closed neural tube defects. *Childs Nerv Syst* 2010;26:967-71.
4. Smith KA, Rekatte HL. Delayed postoperative tethering of the cervical spinal cord. *J Neurosurg* 1994;81:196-201.
5. Pang D, Dias MS. Cervical myelomeningocele. *Neurosurgery* 1993;33:363-72.
6. Andro C, Pecquery R, De Vries P, Forlodou P, Fenoll B. Split cervical spinal cord malformation and vertebral dysgenesis. *Orthop Traumatol Surg Res* 2009;95:547-50.
7. Perrini P, Scollato A, Guidi E, Benedetto N, Buccoliero AM, Di Lorenzo N. Tethered cervical spinal cord due to a hamartomatous stalk in a young adult. Case report. *J Neurosurg* 2005;102 2 Suppl:244-7.
8. Hart DJ, Apfelbaum RI. Anterior cervical spinal cord tethering after anterior spinal surgery: Case report. *Neurosurgery* 2005;56:E414.
9. Eller TW, Bernstein LP, Rosenberg RS, McLone DG. Tethered cervical spinal cord. Case report. *J Neurosurg* 1987;67:600-2.
10. Roth-Vargas AA, Rossitti SL, Balbo RJ, Oliveira MA. So-called tethered cervical spinal cord. *Neurochirurgia (Stuttg)* 1989;32:69-71.
11. Myles LM, Steers AJ, Minns R. Cervical cord tethering due to split cord malformation at the cervico-dorsal junction presenting with self-mutilation of the fingers. *Dev Med Child Neurol* 2002;44:844-8.
12. Pettorini BL, Massimi L, Cianfoni A, Paternoster G, Tamburini G, Di Rocco C. Thoracic lipomeningocele associated with diastematomyelia, tethered spinal cord, and hydrocephalus. Case report. *J Neurosurg* 2007;106 5 Suppl: 394-7.
13. Schmidt NO, Raimund F, Förster AF, Matschke J, Regelsberger J, Fiehler J, *et al.* Congenital cervical tethered cord in an adult: Utility of spinal diffusion tensor MR imaging. *Cent Eur Neurosurg* 2011;72:208-10.