

The 71st Annual Meeting Special Topics—Part I: Long-Term Functional Outcome of Epilepsy Surgery

Which is the Most Appropriate Disconnection Surgery for Refractory Epilepsy in Childhood?

Haruhiko KISHIMA,^{1,2} Satoru OSHINO,^{1,2} Naoki TANI,¹ Yomoyuki MARUO,^{1,2}
Shayne MORRIS,^{1,2} Hui MING KHOO,^{1,2} Takufumi YANAGISAWA,^{1,2}
Kuriko SHIMONO,^{2,3} Takeshi OKINAGA,^{2,3} Masayuki HIRATA,^{1,2}
Amami KATO,⁴ and Toshiki YOSHIMINE^{1,2}

*Departments of ¹Neurosurgery and ³Pediatrics, Osaka University
Graduate School of Medicine, Suita, Osaka;*

²Epilepsy Center, Osaka University Hospital, Suita, Osaka;

⁴Department of Neurosurgery, Kinki University School of Medicine, Osaka-Sayama, Osaka

Abstract

Children with unilobar or multilobar pathology issuing in refractory epilepsy are potential candidates for surgical treatment. Extensive surgery results in good seizure control, but it also increases the risk of neurological deficits as well as motor and mental problems. We reviewed the cases of 19 children with refractory epilepsy treated surgically at Osaka University Hospital. Four of the 19 patients underwent temporal disconnection, 2 underwent occipital lobectomy, 4 underwent temporoparietooccipital disconnection, 6 underwent functional hemispherotomy, and 3 underwent corpus callosotomy. A good surgical outcome, i.e., Engel's class I or II, was achieved in 12 (63%) of the 19 patients. Excellent surgical outcomes and satisfactory motor and mental development were achieved in 4 patients who underwent temporoparietooccipital disconnection. The outcomes of functional hemispherectomy were also satisfactory. The outcomes of temporal disconnection and corpus callosotomy were poor in comparison to outcomes of the other procedures. We believe that better surgical outcomes would have been achieved with temporoparietooccipital disconnection in some cases treated by temporal disconnection or occipital resection. Adequate extensive surgical procedures should be considered for refractory childhood epilepsy arising from unilobar or multilobar pathology.

Key words: refractory epilepsy, childhood, disconnection surgery, unilobar, multilobar

Introduction

Children with unilobar or multilobar pathology issuing in refractory epilepsy are potential candidates for surgical treatment, and good seizure control is usually obtained by such treatment.³⁾ Different surgical procedures are considered because of the variant epileptogenic pathologies as well as differences in patients' motor and mental development. Relatively wide resection or extensive disconnection is thought to result in optimum seizure control, but these procedures increase the risk of neurological

deficits as well as motor and mental problems. Thus, the surgical procedure for epilepsy must be selected by taking the pathology, semiology, developmental status, and age of the patient into consideration. The most aggressive surgery for refractory epilepsy in childhood is hemispherotomy, and this procedure is widely applied in such cases.²⁾ Hemimegalencephaly and Rasmussen's encephalitis are indications for hemispherotomy. Temporoparietooccipital disconnection (posterior quadrantectomy) has recently been reported to bring about excellent seizure control when the epileptogenic focus is located in the occipital, temporal, or parietal lobe.^{4,12)} Other disconnection and resection surgeries are also applicable for patients

Table 1 Temporal disconnection

Patient	Age (years)/sex	Etiology	Semiology	Outcome	F/U (years)	F/U comment
T1	14.8/M	FCD	CPS	IVa	2.2	Entered high school
T2	14.9/M	Porencephaly	CPS	IIa	3.7	Entered high school
T3	2.1/F	FCD	West	IIa	6.2	Mental retardation
T4	2.1/M	FCD	West	IIIa	10.2	Borderline development

Outcome is expressed as Engel's classification. CPS: complex partial seizures, F: female, FCD: focal cortical dysplasia, F/U: follow up, M: male, West: West syndrome.

with refractory epilepsy. In addition, corpus callosotomy is suitable for palliative care. Evaluation of the patient's developmental status and the potential surgical outcome is necessary when identifying a surgical candidate and selecting the appropriate procedure.⁹⁾ To best understand the implications of the various surgical options, we retrospectively evaluated outcomes, complications, and postoperative developmental status in patients who had undergone unilobar or multilobar disconnection or resection surgery for refractory childhood epilepsy.

Patients and Methods

I. Patients

Our study subjects were 19 children (9 girls and 10 boys) with refractory epilepsy who underwent unilobar or multilobar disconnection surgery, occipital lobectomy, or corpus callosotomy between 2000 and 2011 and were followed up for more than 1 year. These patients were identified through medical records, from which we also obtained our study data. Age of the patients at the time of surgery ranged from 0.4 to 14.9 years, with an average of 5.1 years. The epilepsies resulted from developmental malformation (n = 12), including focal cortical dysplasia (FCD) (n = 9), hemimegalencephaly (n = 2), polymicrogyria (n = 1), porencephaly (n = 3), Aicardi syndrome (n = 1), cerebral hemiatrophy (n = 1), Sturge-Weber syndrome (n = 1), and an unknown cause (n = 1). The epilepsies manifested as West syndrome (n = 11), complex partial seizures (n = 6), and secondary generalized seizures (n = 2). We obtained information regarding the presurgical evaluations, surgical procedures, postoperative outcomes, and neurological deficits in each case. We also investigated the developmental outcomes, including motor and mental function. Postoperative seizure outcomes were assessed according to the Engel's classification.

II. Selection of the surgical procedures

The surgical procedures varied by case. The area of disconnection was determined on the basis of epileptic

semiology and magnetic resonance imaging (MRI), 18F-fluorodeoxy glucose (FDG)-positron emission tomography (PET), magnetoencephalography (MEG), electroencephalography (EEG), electrocorticography (ECoG), and video-EEG. Of these examinations, MRI was the most important for selecting the surgical procedure. Preoperative neurological deficits, motor and mental development, and age of the patient were also taken into consideration for selection of the surgical procedure.

Temporal disconnection was performed in 4 patients for whom MRI revealed a temporal lobe abnormality (Table 1). Three (Patients T1, T3, and T4) of the 4 patients had MRI abnormalities suggesting unilateral FCD. FDG-PET revealed temporal lobe hypometabolism in Patients T1 and T3. Video-EEG monitoring of Patient T1 suggested ictal onset in the temporal lobe. EEG in Patients T3 and T4 showed hypersarrhythmia. In the remaining patient (Patient T2), MRI revealed porencephaly of the left middle fossa and atrophy of the temporal lobe. Chronic intracranial ECoG monitoring showed spikes arising from the left lateral temporal lobe, with some arising from the left occipital lobe; however, ictal ECoG was not obtained. In consideration of the patient's age (14.9 years) and intelligence (normal) and to avoid hemianopsia, temporal disconnection rather than temporoparietooccipital disconnection was performed. Two patients underwent occipital lobectomy (Table 2). The indication for this procedure was unilateral, localized anatomic, metabolic, and electrophysiologic abnormalities in the occipital lobe. In both patients, MRI revealed occipital lobe abnormalities suggesting FCD. In Patient O1, FDG-PET revealed hypometabolism in the right occipital lobe, and EEG showed hypersarrhythmia. In Patient O2, although EEG revealed spikes arising from the occipital and temporal lobes, intracranial ECoG showed the epileptic onset zone to be in the right occipital lobe.

Four patients underwent temporoparietooccipital disconnection (Table 3). The basic indication for this procedure was generation of the seizures in

the temporo-occipital region with diffuse spread to the parietal lobe but not the frontal lobe. The frontal lobe of all 4 patients appeared normal upon MRI and FDG-PET. In Patient PQ1, MRI revealed porencephaly in the territory of the right middle cerebral artery. FDG-PET revealed hypometabolism of the right hemisphere, except in the frontal lobe. EEG showed hypsarrhythmia. Temporoparietooccipital disconnection was applied in this case to preserve the patient's frontal lobe. In Patient PQ2, MRI suggested FCD in the left occipital lobe. FDG-PET revealed hypometabolism not only in the left occipital lobe but also in the temporal lobe. Video-EEG monitoring revealed spastic seizures that followed rhythmic slow waves arising from the left occipital and posterior temporal lobes. In Patient PQ3, MRI suggested FCD in the left temporal and occipital lobes. Ictal single-photon emission computed tomography with N-isopropyl[¹²³I]-p-iodoamphetamine (IMP-SPECT) revealed increased cerebral blood flow in the left parietal, occipital, and temporal lobes,

and interictal FDG-PET revealed hypometabolism in these regions. In Patient PQ4, MRI suggested FCD in the left temporal lobe, and FDG-PET showed hypometabolism in the temporal and parietal lobes. Video-EEG suggested the epileptic focus to be in the left temporal lobe, and ECoG revealed a left temporo-parietal focus.

Functional hemispherotomy was performed in 6 patients (Table 4). Hemimegalencephaly was diagnosed by MRI in 2 of the 6 patients (Patients H4 and H6). Sturge-Weber syndrome with angiomas covering the whole hemisphere was diagnosed in 1 patient (Patient H3). Aicardi syndrome with agenesis of the corpus callosum was diagnosed in Patient H1; MRI showed right hemi-atrophy but an almost anatomically normal left hemisphere. In Patient H2, MRI suggested FCD in the occipital lobe, and FDG-PET revealed hypometabolism involving the whole hemisphere. Functional hemispherotomy was performed in this patient. In Patient H5, MRI showed typical left cerebral hemiatrophy. FDG-PET

Table 2 Occipital lobectomy

Patient	Age (years)/sex	Etiology	Semiology	Outcome	F/U (years)	F/U comment
O1	2.1/M	FCD	West	Ic	8.4	Autism
O2	7.4/F	FCD	CPS	IId	8.8	Borderline development

Outcome is expressed as Engel's classification. CPS: complex partial seizures, F: female, FCD: focal cortical dysplasia, F/U: follow up, M: male, West: West syndrome.

Table 3 Temporoparietooccipital disconnection

Patient	Age (years)/sex	Etiology	Semiology	Outcome	F/U (years)	F/U comment
PQ1	1.6/F	Porencephaly	West	Ia	1.2	Walks independently
PQ2	1.1/M	FCD	West	Ia	1.7	Walks independently
PQ4	9.9/M	Polymicrogyria	CPS	IIC	6.6	Autism
PQ4	8.8/M	FCD	CPS	Ia	6.8	Borderline development

Outcome is expressed as Engel's classification. CPS: complex partial seizures, F: female, FCD: focal cortical dysplasia, F/U: follow up, M: male, West: West syndrome.

Table 4 Functional hemispherotomy

Patient	Age (years)/sex	Etiology	Semiology	Outcome	F/U (years)	F/U comment
H1	0.6/F	Aicardi Syndrome	West	IIIa	3.8	Cannot walk
H2	0.9/M	FCD	West	Ia	6	Walks with support
H3	0.4/F	S-W	West	Ia	6.8	Walks independently
H4	2.8/M	HME	sGTC	Ia	7.8	Walks independently
H5	1.6/F	Cerebral hemiatrophy	West	IIIa	8.3	Walks independently
H6	0.9/F	HME	West	Ia	8.9	Walks independently

Outcome is expressed as Engel's classification. F: female, FCD: focal cortical dysplasia, F/U: follow up, HME: hemimegalencephaly, M: male, sGTC: secondary generalized tonic-clonic seizures, S-W: Sturge-Weber syndrome, West: West syndrome.

Table 5 Corpus callosotomy

Patient	Age (years)/sex	Etiology	Semiology	Outcome	F/U (years)	Follow-up comment
C1	8.8/F	Unknown	sGTC	IV	1.0	1p36 deletion syndrome
C2	1.0/F	Unknown	West	IIIa	5.8	Bilateral focus
C3	13.0/M	Porencephaly	CPS	IIIa	7.4	Bilateral focus

Outcome is expressed as Engel's classification. CPS: complex partial seizures, F: female, F/U: follow up, M: male, sGTC: secondary generalized tonic-clonic seizures, West: West syndrome.

showed hypometabolism only in the left hemisphere. Thus, left functional hemispherotomy was performed in this patient.

Corpus callosotomy was performed in 3 patients (Table 5). Patient C1 was diagnosed with 1p36 deletion syndrome, and MRI revealed right cerebral hemiatrophy. However, EEG showed bilateral frontal synchronized spike and wave discharges. The patient's motor function was nearly normal. Because of the seizure etiology and the patient's age (8.8 years), total corpus callosotomy rather than functional hemispherotomy was performed. Patient C2 was diagnosed with West syndrome; MRI revealed bilateral brain atrophy, and EEG showed bilateral synchronized spikes. Patient C3 suffered from complex partial seizures; MRI revealed porencephaly of the left frontal and temporal lobes. EEG suggested the epileptic focus to be in the right hemisphere. To localize the epileptogenic focus, total corpus callosotomy was performed.

III. Surgical procedures

For temporal lobe disconnection in this patient series, the disconnection line was approximately 5–6 cm from the temporal tip and hippocampus, the lower part of the amygdala and uncus were removed to disconnect surrounding brain tissues. The occipital lobe was removed rather than disconnected because of its small volume. Hemispherotomy, vertical parasagittal functional hemispherotomy in particular, was performed as described by Delalande et al.⁶⁾ temporoparietooccipital disconnection was performed as described by Daniel et al.,⁴⁾ who referred to the procedure as functional posterior quadrantectomy (Fig. 1). This procedure is used to disconnect the temporal lobe, occipital lobe, and posterior part of the parietal lobe, preserving the primary sensory cortex. Corpus callosotomy was performed in the manner described by Joseph et al.¹⁰⁾ with a neuronavigation system.

Results

As noted above, 4 of the 19 patients underwent temporal disconnection, 2 underwent occipital lobectomy, 4 underwent temporoparietooccipital disconnection, 6 underwent functional hemispherotomy, and 3 underwent corpus callosotomy. In the patient with Sturge-Weber syndrome (Patient H3) who underwent functional hemispherotomy, hydrocephalus was noted after 6 months, and a ventriculoperitoneal shunt was fashioned. No other persistent surgical complication was observed. Outcomes are described per procedure in Tables 1–5.

I. Results of temporal disconnection

Postoperative outcomes in the 4 patients who underwent temporal disconnection were as follows: Engel's class IIa (n = 2), class IIIa (n = 1), and class IVa (n = 1) (Table 1). The class IVa patient (Patient T1) underwent additional disconnection surgery that extended to the occipital lobe 1 year after the initial surgery, and he has been seizure-free for 14 months. The two early adolescents (Patients T1 and T2) showed normal development before surgery. Postoperatively, they both entered high school with no neurologic deficit except quadrantanopsia. Two patients (Patients T3 and T4) underwent surgery at approximately age 2. Both of them showed mental retardation before surgery. Although both showed signs of mental retardation, their motor and mental development improved.

II. Results of occipital lobectomy

The two patients who underwent occipital disconnection showed hemianopsia postoperatively, but their motor function was not affected. For one patient (Patient O1), the postoperative outcome was Engel's class Ic, and the patient's mental development was somewhat below normal (borderline category). Postoperative outcome in the other case (Patient O2) was Engel's class IIc with only nocturnal seizures. This patient's mental development was also borderline (Table 2).

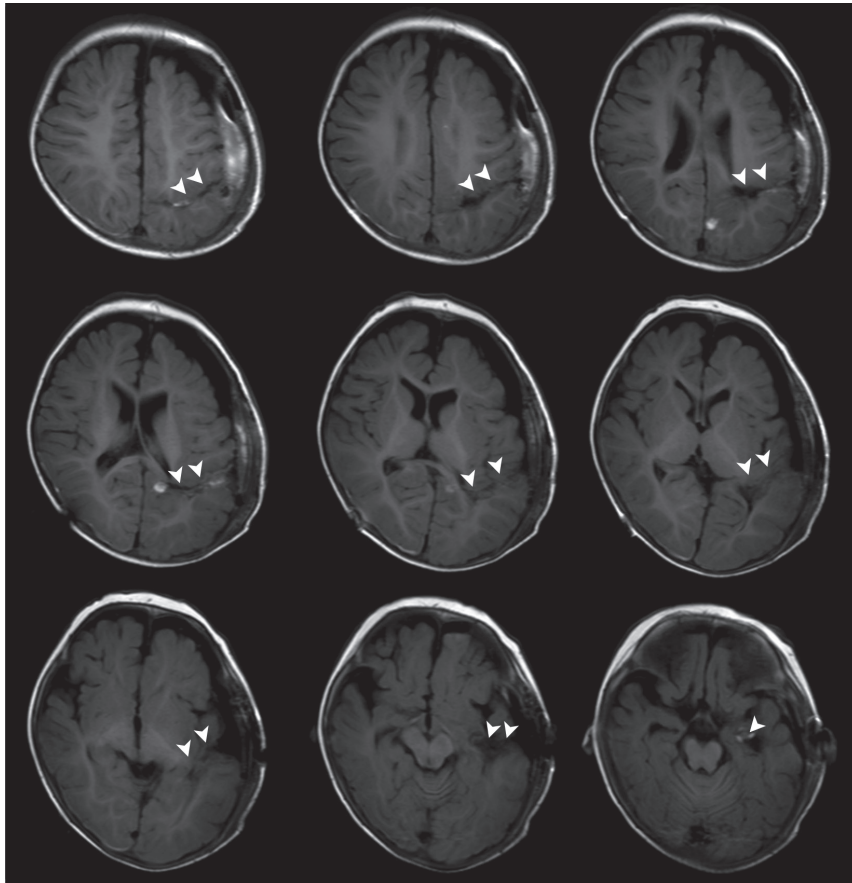


Fig.1 Magnetic resonance images of temporoparietooccipital disconnection (Patient PQ2). Arrow heads indicate the disconnection line.

III. Results of temporoparietooccipital disconnection

Two of the 4 patients who underwent temporoparietooccipital disconnection were less than 2 years old at the time of surgery (Patients PQ1 and PQ2), and the other 2 patients were 8 and 9 years of age (Patients PQ3 and PQ4, respectively) (Table 3). Three patients (Patients PQ1, PQ2, and PQ4) were seizure-free (Engels's class Ia) after surgery, and the fourth patient (PQ3) reached Engel's class IIc. The 4 patients showed no motor weakness and were able to walk independently. However, these patients often avoided use of the upper extremity contralateral to the affected side of the brain. Each of these 4 patients was able to use the contralateral arm and hand but with some hesitation; use of the other arm and hand was quite natural. Postoperative verbal function seemed to depend on the preoperative function in the two older children. Patient PQ3 was diagnosed with autism and patient PQ4 with borderline mental development. The two very young children (Patients PQ1 and PQ2) have been followed up for less than

2 years. At present, they can use only a few words, but their word comprehension has improved.

IV. Results of functional hemispherotomy

Four of the 6 patients who underwent functional hemispherotomy (Patients H2, H3, H4, and H6) were seizure-free after surgery (Table 4). Two patients, the patient with Aicardi syndrome (Patient H1) and the patient with cerebral atrophy (Patient H5), reached Engel class IIIa. In Patient H5, incomplete disconnection was detected postoperatively. Four patients (Patients H3, H4, H5, H6) were able to walk during the follow-up period, but their lower extremities contralateral to the affected side of the brain showed some spasticity. Patient H1 showed some symptoms of Aicardi syndrome; she was not able to walk, and she appeared to be severely mentally retarded. Patient H2 was able to stand up independently and walk with support. All 6 patients showed slight to severe mental retardation.

V. Results of corpus callosotomy

Total corpus callosotomy was performed in all 3 patients treated by callosotomy (Table 5). Patient C1 showed no improvement (Engel class IV) after the surgery. The outcome for Patients C2 and C3 was Engel class IIIa. These 3 patients showed severe to moderate mental retardation before surgery, and their mental status did not change much after surgery.

Discussion

In this study, we reviewed the outcomes of disconnection surgery performed in childhood for refractory epilepsy. The surgical procedure in each of the 19 cases was determined on the basis of presurgical seizure semiology, neuroimaging, and neurophysiologic findings as well as motor and mental development. Thus, the surgical procedures varied from temporal disconnection to occipital lobectomy to temporoparietooccipital disconnection to hemispherotomy to corpus callosotomy. Frontal lobe disconnection and frontoparietal disconnection are variant procedures that were not applied in our patient series. Frontal lobectomy or disconnection is only rarely applied to refractory epilepsy in childhood.^{5,11,13} Thus, frontal lobe pathology in the childhood that necessitate frontal lobe disconnection or frontoparietal disconnection may be rare.

The outcomes achieved in our series were good. Engel's class I or II was achieved in 63% of cases. Because the number of cases was limited in this study, statistical analysis is not informative. However, outcomes were poorer in the cases of temporal disconnection than in the other cases. Temporal disconnection is reported to yield excellent outcomes for adult patients with intractable epilepsy.^{1,5} Complete freedom from seizures was not achieved in any of our patients who underwent temporal disconnection; however, one of the four patients became seizure-free after additional temporal disconnection. In the early adolescents, extensive disconnection was not advisable because these patients showed normal development and motor function preoperatively. Thus, temporal disconnection was performed rather than temporoparietooccipital disconnection in these two cases. In such cases, the dominancy of verbal function must be considered before temporal disconnection. In the two very young children with EEG-determined hypsarrhythmia, more extensive disconnection, such as temporoparietooccipital disconnection, might have yielded better surgical outcomes because the focus of the remaining seizures was thought to be posterior to the disconnection line.

Outcomes of occipital lobectomy were somewhat

satisfactory, although the procedure was performed in only 2 patients. Mental development in these 2 patients was in borderline. Nocturnal seizures remained in 1 patient (Patient O2). Postoperative EEG showed the focus of the remaining seizures to be the ipsilateral temporal lobe. Thus, temporoparietooccipital disconnection might have yielded complete freedom from seizures in this patient.

Outcomes of temporoparietooccipital disconnection were satisfactory, as previously reported.^{4,12} All patients who underwent either occipital lobectomy or temporoparietooccipital disconnection were able to walk almost normally, and they had no motor weakness. However, they tended to avoid using the contralateral upper extremity. Autism and mental problems were recognized in the patients who underwent temporoparietooccipital disconnection. We believe occipital lobectomy or temporoparietooccipital disconnection can bring about satisfactory seizure outcomes and development in carefully selected patients.

Posterior quadrantic dysplasia is thought to be one of the causes of refractory epilepsy,³ and temporoparietooccipital disconnection is applied in such cases. Furthermore, occipital-plus resection is reported to achieve better outcomes than other multilobar epilepsy surgeries.¹³ An interesting neural cell migration pattern in the unborn child has been reported.⁷ In line with these findings, we conclude that occipital disconnection and temporoparietooccipital disconnection are reasonable surgical procedures for patients with FCD in temporal or occipital regions. In retrospect, we realize that temporoparietooccipital disconnection could have been applied in some of our temporal disconnection and occipital lobectomy cases and that the procedure would have brought about better seizure control.

Surgical outcomes after hemispherotomy were satisfactory in 4 patients and unsatisfactory in 2 patients. These outcomes matched previously reported outcomes.⁶ In 1 patient, the poor outcome was attributed to incomplete disconnection detected upon postoperative MRI and to a bilateral abnormality detected upon preoperative MRI. The other patient had Aicardi syndrome, which is an X-linked dominant inheritance disorder. There was some systemic abnormality in this case, and the patient's postoperative motor and mental development were poor compared to those in the other hemispherotomy cases. Such cases might fall outside the indications for functional hemispherotomy. Freedom from seizures was achieved in the other 4 patients. The patients who underwent hemispherotomy showed slight to severe mental retardation. Four patients were able to walk independently, one could stand up and walk

with help, and the Aicardi syndrome patient could not walk. All 6 patients showed some weakness in the contralateral upper extremity along with lower extremity spasticity. This suggests that functional hemispherotomy yields the most satisfactory seizure outcome but that it does not yield the best motor and mental function.

Corpus callosotomy was performed for our patients with suspected bilateral frontal epileptogenesis even without drop attacks. However, satisfactory outcomes were not achieved by corpus callosotomy alone. Corpus callosotomy can localize the epileptogenic focus, and freedom from seizures can be achieved with corpus callosotomy alone in some patients.⁸⁾ Thus, we suppose that corpus callosotomy can serve as an additional and palliative procedure for patients with suspected bilateral pathologies or drop attacks.

Surgery should be carefully considered for refractory childhood epilepsy arising from a unilobar or multilobar pathology. Extensive disconnection will bring about optimum seizure control in such cases, but it will also lead to motor and mental problems.^{9,11)} In conclusion, we must take seizure control, motor development, and mental status into account in selecting the most appropriate disconnection surgical procedure.

Conflicts of Interest Disclosure

None of the authors have personal, financial, or institutional interest in any of the drugs, materials, or devices noted herein. Those who are members of the Japan Neurosurgical Society (JNS) have registered online Self-reported COI Disclosure Statement Forms through the JNS website.

References

- 1) Chabardès S, Minotti L, Hamelin S, Hoffmann D, Seigneuret E, Carron R, Krainik A, Grand S, Kahane P, Benabid AL: [Temporal disconnection as an alternative treatment for intractable temporal lobe epilepsy: techniques, complications and results]. *Neurochirurgie* 54: 297–302, 2008 (French)
- 2) Cook SW, Nguyen ST, Hu B, Yudovin S, Shields WD, Vinters HV, Van de Wiele BM, Harrison RE, Mathern GW: Cerebral hemispherectomy in pediatric patients with epilepsy: comparison of three techniques by pathological substrate in 115 patients. *J Neurosurg* 100 (2 Suppl Pediatrics): 125–141, 2004
- 3) D'Agostino MD, Bastos A, Piras C, Bernasconi A, Grisar T, Tsur VG, Snipes J, Juhasz C, Chugani H, Guerrini R, Cross H, Andermann E, Dubeau F, Montes J, Olivier A, Andermann F: Posterior quadrantic dysplasia or hemi-hemimegalencephaly: a characteristic brain malformation. *Neurology* 62: 2214–2220, 2004
- 4) Daniel RT, Meagher-Villemure K, Farmer JP, Andermann F, Villemure JG: Posterior quadrantic epilepsy surgery: technical variants, surgical anatomy, and case series. *Epilepsia* 48: 1429–1437, 2007
- 5) De Ribaupierre S, Delalande O: Hemispherotomy and other disconnective techniques. *Neurosurg Focus* 25: E14, 2008
- 6) Delalande O, Bulteau C, Dellatolas G, Fohlen M, Jalin C, Buret V, Viguier D, Dorfmueller G, Jambaqué I: Vertical parasagittal hemispherotomy: surgical procedures and clinical long-term outcomes in a population of 83 children. *Neurosurgery* 60: ONS19–32; discussion ONS32, 2007
- 7) Hatten ME: New directions in neuronal migration. *Science* 297: 1660–1663, 2002
- 8) Iwasaki M, Uematsu M, Sato Y, Nakayama T, Haginoya K, Osawa S, Itabashi H, Jin K, Nakasato N, Tominaga T: Complete remission of seizures after corpus callosotomy. *J Neurosurg Pediatr* 10: 7–13, 2012
- 9) Iwatani Y, Kagitani-Shimono K, Tominaga K, Okinaga T, Mohri I, Kishima H, Kato A, Sanefuji W, Yamamoto T, Tatsumi A, Murata E, Taniike M, Nagai T, Ozono K: Long-term developmental outcome in patients with West syndrome after epilepsy surgery. *Brain Dev* 34: 731–738, 2012
- 10) Joseph JR, Viswanathan A, Yoshor D: Extraventricular corpus callosotomy. *J Neurosurg* 114: 1698–1700, 2011
- 11) Kim SK, Wang KC, Hwang YS, Kim KJ, Chae JH, Kim IO, Cho BK: Epilepsy surgery in children: outcomes and complications. *J Neurosurg Pediatr* 1: 277–283, 2008
- 12) Mohamed AR, Freeman JL, Maixner W, Bailey CA, Wrennall JA, Harvey AS: Temporoparietooccipital disconnection in children with intractable epilepsy. *J Neurosurg Pediatr* 7: 660–670, 2011
- 13) Sarkis RA, Jehi L, Najm IM, Kotagal P, Bingaman WE: Seizure outcomes following multilobar epilepsy surgery. *Epilepsia* 53: 44–50, 2012

Address reprint requests to: Haruhiko Kishima, MD, PhD, Department of Neurosurgery, Osaka University Graduate School of Medicine, 2-2 Yamadaoka, Suita, Osaka 565-0871, Japan.
e-mail: hkishima@nsurg.med.osaka-u.ac.jp