

[CASE REPORT]

Rapidly Progressive Multiple Cavity Formation in Necrotizing Pneumonia Caused by Community-acquired Methicillin-resistant *Staphylococcus aureus* Positive for the Panton-Valentine Leucocidin Gene

Yuki Takigawa¹, Keiichi Fujiwara¹, Takashi Saito², Takamasa Nakasuka¹, Taichi Ozeki¹,
Sachi Okawa¹, Kenji Takada¹, Yoshitaka Iwamoto¹, Hiroe Kayatani¹, Daisuke Minami¹,
Ken Sato¹, Miki Nagao³ and Takuo Shibayama¹

Abstract:

A 66-year-old man was transferred to our hospital for pneumonia that was resistant to sulbactam/ampicillin and levofloxacin therapy. Chest computed tomography showed the rapidly progressive formation of multiple cavities. Methicillin-resistant *Staphylococcus aureus* (MRSA) was isolated, and the patient was diagnosed with necrotizing pneumonia caused by community-acquired MRSA (CA-MRSA). The MRSA strain had type IV staphylococcus cassette chromosome *mec* and genes encoding Panton-Valentine leucocidin (PVL). CA-MRSA necrotizing pneumonia with the PVL gene is rare; only three cases have been previously reported in Japan. We administered anti-MRSA antibiotics and the patient achieved complete clinical and radiological improvement.

Key words: community-acquired methicillin-resistant *Staphylococcus aureus* (CA-MRSA), Panton-Valentine leukocidine (PVL) gene, necrotizing pneumonia, multiple cavity formation, influenza

(Intern Med 58: 685-691, 2019)

(DOI: 10.2169/internalmedicine.1454-18)

Introduction

Infections with community-acquired methicillin-resistant *Staphylococcus aureus* (CA-MRSA) have been reported since the late 1990s (1). Naimi et al. (2) defined CA-MRSA as follows: 1) an MRSA infection identified within 48 hours of admission to a hospital; 2) without a history of hospitalization, surgery, dialysis, or residence in a long-term care facility within one year of the MRSA culture date; 3) without a permanent indwelling catheter or percutaneous medical device present at the time of culture; and 4) without a known positive culture for MRSA prior to the study period. CA-MRSA most commonly produces skin and soft-tissue infections, and severe and life-threatening infections such as sepsis, meningitis and necrotizing pneumonia are relatively

rare (3). Necrotizing pneumonia is a severe form of lung disease associated with the formation of abscesses and cavitation within the lung parenchyma, and has a high mortality rate. In addition, severe necrotizing pneumonia caused by CA-MRSA, in particular the strain producing Panton-Valentine leukocidin (PVL), is associated with a very high fatality rate (4).

We describe a case of necrotizing pneumonia caused by CA-MRSA with the PVL gene and the rapidly progressive formation of multiple cavities in the bilateral lung fields. The disease progression was stopped by the immediate administration of vancomycin (VCM).

Case Report

A 66-year-old man noted an influenza-like illness in Feb-

¹Department of Respiratory Medicine, National Hospital Organization Okayama Medical Center, Japan, ²Department of Infectious Diseases, National Hospital Organization Okayama Medical Center, Japan and ³Department of Clinical Laboratory, Kyoto University Hospital, Japan
Received: April 26, 2018; Accepted: July 3, 2018; Advance Publication by J-STAGE: October 17, 2018
Correspondence to Dr. Keiichi Fujiwara, kfujiwara0827@yahoo.co.jp

Table 1. Laboratory Findings on Admission to Our Hospital.

Hematology		LDH	188 U/L	KL-6	69.0 U/mL
WBC	14,000 / μ L	ALP	556 U/L	SP-A	84.9 ng/mL
Seg	77.0 %	γ -GTP	362 U/L	SP-D	36.9 ng/mL
Stab	8.0 %	TP	5.3 g/dL	RF	5 U/mL
Mon	5.0 %	ALB	1.8 g/dL	ANA	<x40
Lym	10.0 %	CRE	0.84 mg/dL	PR3-ANCA	<0.6 U/mL
Eos	0.0 %	BUN	16 mg/dL	MPO-ANCA	<1.0 U/mL
Bas	0.0 %	Na	131 mEq/L	Mycoplasma Ab	<x40
RBC	387 $\times 10^4$ / μ L	K	3.9 mEq/L	Cryptococcus Ag	(-)
Hgb	12.7 g/dL	Cl	97 mEq/L	Aspergillus Ag	>5.0
Hct	34.9 %	Serology		Candida Ag	(-)
PLT	42.0 $\times 10^4$ / μ L	CRP	19.14 mg/dL	β -D-glucan	13.4 pg/mL
ESR	71 mm/h	PCT	2.43 ng/mL	T-SPOT	
Biochemistry		BNP	37.0 pg/mL	ESAT-6	0 spot
T-Bil	1.2 mg/dL	CEA	2.1 ng/mL	CFP-10	0 spot
AST	36 U/L	CA19-9	2.9 U/mL	Influenza A	(-)
ALT	42 U/L	sIL-2R	2,475.0 U/mL	Influenza B	(-)

ruary 2017. The patient was a farmer and a current heavy smoker (96 pack-years). He had never traveled abroad, had no recent contact with foreigners, and had a history of pneumonia and acute renal failure in his teens and twenties, respectively. He had been healthy and had no medical problems until twelve days before his admission to our hospital, when he noted fever, cough and arthralgia. He had not previously been vaccinated for influenza. He was first diagnosed with type-A influenza and treated with oseltamivir in a nearby clinic. His high fever continued and his dyspnea gradually progressed after several days; thus, he was admitted to a nearby hospital. Computed tomography (CT) scans of the chest showed bilateral multiple granular shadows and patchy opacities. MRSA was detected in a sputum culture obtained on admission. He was treated with antibiotics (sulbactam/ampicillin, SBT/ABPC; and levofloxacin). Although his C-reactive protein (CRP) level was reduced (from 40.0 to 23.0 mg/dL), the bilateral consolidation on chest X-ray films worsened. Thus, he was transferred to our hospital due to progressive and refractory pneumonia.

On admission to our hospital, the patient was conscious and his vital signs were as follows: temperature, 38.2 °C; blood pressure, 149/79 mmHg; heart rate, 118 beats/minute; respiratory rate, 20 breaths/minute. The oxygen saturation was 98% under 3 L/min of oxygen inhalation. A physical examination revealed no abnormal findings except for faint coarse crackles in the bilateral lungs. No wounds were observed on his body, arms, or legs. A laboratory analysis revealed leukocytosis with predominant neutrophils and hypoalbuminemia, and his CRP level was elevated at 19.14 mg/dL (shown in Table 1). His procalcitonin level was 2.43 ng/mL, and his soluble interleukin 2 receptor (sIL-2R) was also elevated (2,475.0 U/mL; normal range, <500 U/mL). The levels of rheumatoid factor, antinuclear antibodies, and anticytoplasmic antibodies were all within the normal ranges. A chest X-ray film showed bilateral infiltration, which had progressed in comparison to the X-ray films ob-

tained at the previous hospital (Fig. 1). In addition, chest CT showed the rapidly progressive formation of multiple cavities and surrounding ground-glass opacities with bilateral pleural effusion in the bilateral lungs, whereas the CT scans obtained at the former hospital showed only patchy opacity, small nodules, and no cavities (Fig. 2).

As the SBT/ABPC regimen used at the former hospital seemed to be somewhat effective, we began treatment with it again. The formation of multiple cavities shown by CT scans suggested different possible diagnoses, including multiple lung abscesses, invasive pulmonary aspergillosis, cryptogenic organizing pneumonia, granulomatosis with polyangiitis, septic embolism, and pulmonary malignancies. The patient's blood culture sets were negative. Echocardiography showed no vegetation in the cardiac valves and deep vein thrombosis was not observed on endovascular echography, indicating that septic embolism was unlikely. On day two, we performed bronchoscopy for the suctioning of purulent sputum, biopsy, and brushing cytology. This was performed by endobronchial ultrasonography with a guide-sheath method. A specimen was obtained from the area of consolidation in the left lingular lobe. We detected a large number of grapelike clusters of gram-positive cocci by gram staining, and a cytological examination showed neutrophils with phagocytosis of bacterium. A histopathological examination showed necrosis with inflammatory exudate surrounding the neutrophils, fibrin deposition, and some immature fibrosis, indicating pulmonary abscesses.

On day four, the patient was treated with VCM at a starting dose of 1,000 mg/day, which was subsequently increased to 1,500 mg/day according to its trough value (final concentration, 17.4 μ g/mL). MRSA isolated from sputum was sensitive to trimethoprim/sulfamethoxazole, erythromycin (EM), minocycline (MINO), and clindamycin (CLDM), as well as VCM (minimal inhibitory concentration, MIC \leq 1 μ g/mL). Furthermore, type IV staphylococcus cassette chromosome *mec* (SCC*mec*) and genes encoding Panton-

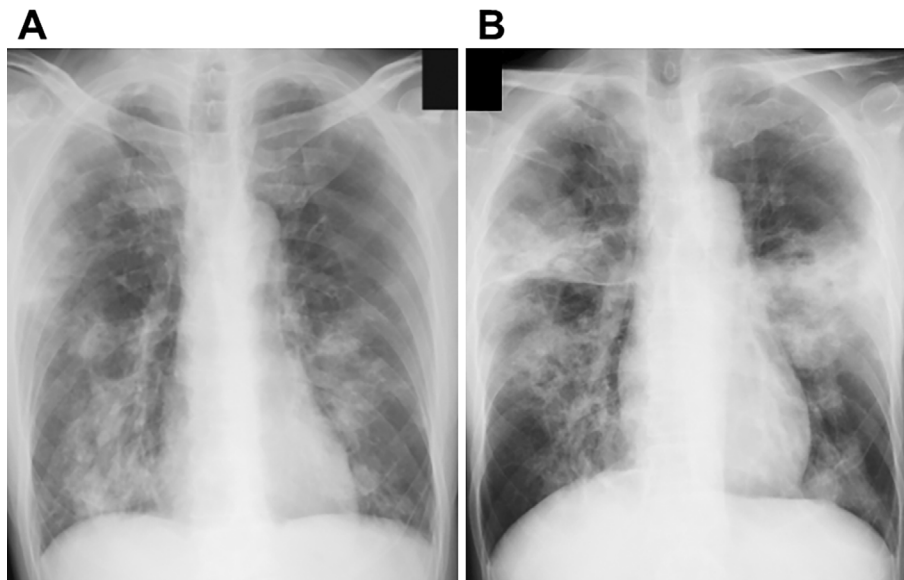


Figure 1. Chest X-ray films obtained in the former hospital (A) and on admission to our hospital in February 2017 (B). Bilateral infiltrates, mainly in middle field, progressed rapidly within about one week.

Valentine leucocidin (PVL) were identified by a polymerase chain reaction (5) of the strain of MRSA isolated from the patient's sputum. These molecular characteristics of the strain were compatible with CA-MRSA. Considering the definition established by Naimi et al. (2), we diagnosed the present case with necrotizing pneumonia due to CA-MRSA.

The administration of VCM reduced the patient's temperature, white blood cell count, and serum level of CRP. The patient's oxygenation status also resolved, and the pulmonary opacities on the patient's chest X-ray film improved (Fig. 3). On the 27th day of admission, we changed VCM to linezolid (MIC 2 µg/mL) due to drug-induced fever. On the 30th and 40th days of admission, we confirmed that the patient's sputum was not positive for any strains of bacteria, including MRSA, and the patient discharged from the hospital on the 41st day of admission with the complete improvement of his general condition. Chest CT scans at six months after treatment showed the disappearance of the multiple cavities.

Discussion

Community-acquired pneumonia (CAP) is most commonly caused by *Streptococcus pneumoniae*. *Staphylococcus aureus* (SA) pneumonia is the third-most common cause of CAP, reportedly causing 4.2% of all cases of CAP in Japan (6). Furthermore, CAP caused by MRSA is reported to cause 28.4% of all cases of SA pneumonia. We diagnosed the present case with necrotizing pneumonia caused by CA-MRSA, as the case met all of the criteria for the CA-MRSA definition indicated by Naimi et al. (2), and the patient had no specific medical history. Skin and soft tissue infections are often caused by CA-MRSA, whereas respiratory or urinary tract infections are less likely to be caused by

community-acquired strains (3, 7). In addition, there have been several reports of necrotizing pneumonia induced by CA-MRSA. Table 2 shows all of the cases of CA-MRSA necrotizing pneumonia reported in Japan. The first report, published in 2008 by Tomita et al., was the first of only eight reported cases (8). All but one case (Case 7, Table 2) showed consolidation, and radiology demonstrated cavity formation in six cases. Two patients died despite the administration of anti-MRSA agents and intensive care. These patients had bilateral lesions, and MRSA was isolated from blood samples, which are suggested to be factors that predict a poor prognosis in patients with CA-MRSA necrotizing pneumonia.

It has been shown that methicillin-susceptible *Staphylococcus aureus* strains become MRSA strains through the acquisition of the SCCmec element carrying the *mecA* gene, which is responsible for methicillin resistance (9). It is also reported that, in Japan, healthcare-associated MRSA (HA-MRSA) is likely to have SCCmec type II, while CA-MRSA is more likely to have type IV (10). Similarly, in the United States and Europe, CA-MRSA is likely to have SCCmec type IV. SCCmec type IV is known to have the PVL gene, which is a toxin that is known to cause white blood cell destruction (11). As shown in Table 2, among the reported cases of necrotizing pneumonia caused by CA-MRSA, only two adult cases and one pediatric case were shown to have the PVL gene. Interestingly, these two adult cases were not Japanese (one was African-American, and the other Vietnamese), whereas the present case was a native-born Japanese individual with no history of any recent contact with foreigners. Considering that only 2.3% of SCCmec type IV strains in Japan have PVL (12), the present case is thought to be quite rare.

Prior respiratory tract infection, especially infection

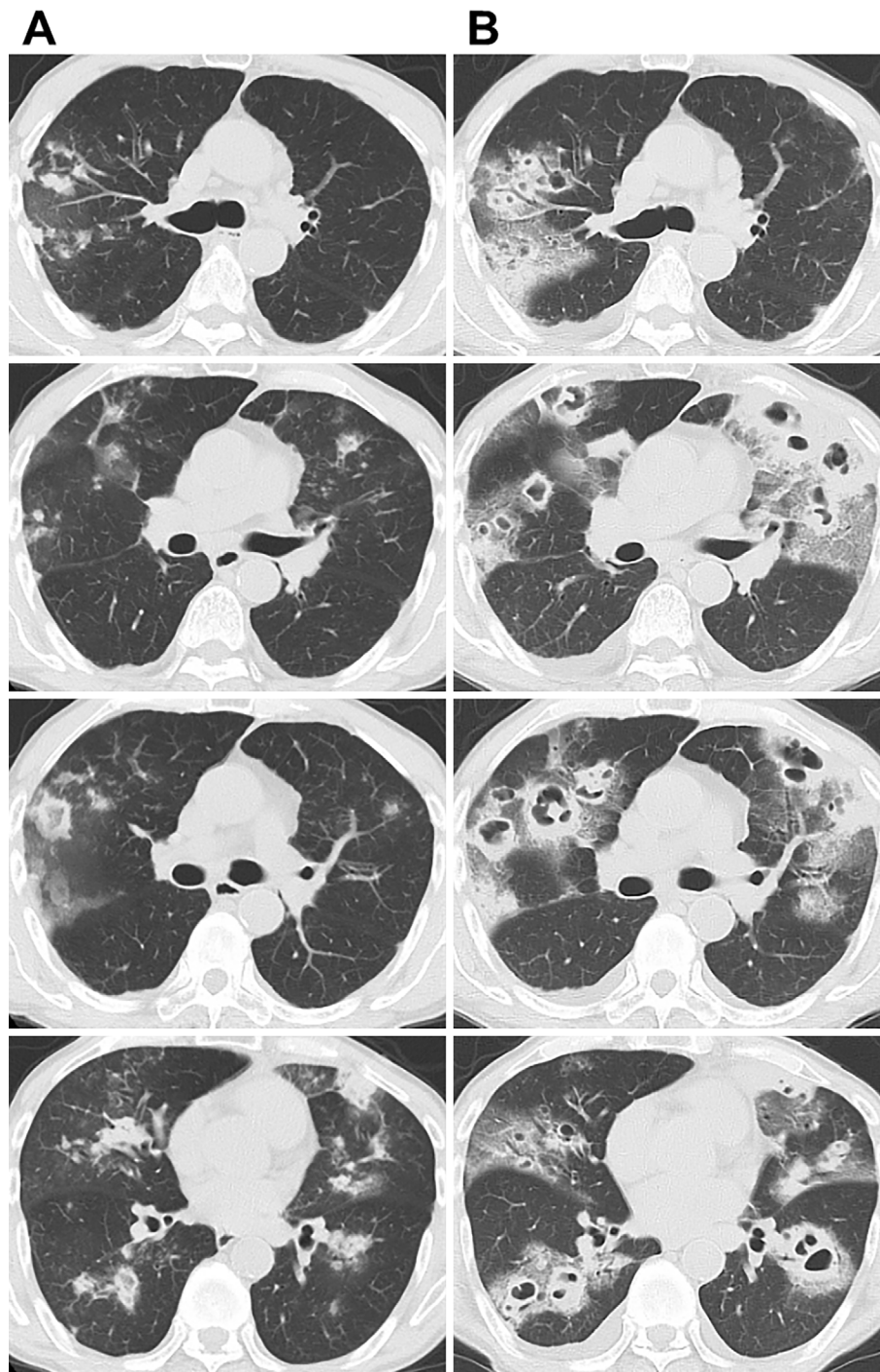


Figure 2. Chest computed tomography on admission at the previous hospital showed bilateral multiple patchy shadows and ground-grass opacities (A). Rapidly progressive consolidations and the formation of cavities with bilateral pleural effusion were seen on chest CT scans obtained on admission to our hospital after a short period of time (B).

caused by influenza, is likely to precede CA-MRSA necrotizing pneumonia. Cheng et al. reported a fatal adult case of CA-MRSA infection associated with the H1N1 influenza virus (13). In Japan, a case of toxic shock syndrome associated with the 2009 H1N1 influenza virus pandemic and CA-MRSA infection in a 16-year-old Vietnamese girl was reported by Kashiwada et al. (Case 4, Table 2) (14). Our case also had a history of influenza infection. Viral infections and other types of infection damage epithelial cells in the air-

way, resulting in the easy engraftment of PVL-positive MRSA to the basement membrane (15). Subsequently, PVL can cause pulmonary necrosis through tissue destruction with the infiltration of neutrophils and macrophages. CA-MRSA necrotizing pneumonia with the PVL gene is reported to be associated with rapid tissue destruction and cavity formation. As indicated in Table 2, two of three PVL-positive CA-MRSA cases showed cavity formation in the bilateral lung fields. The radiological findings in our case

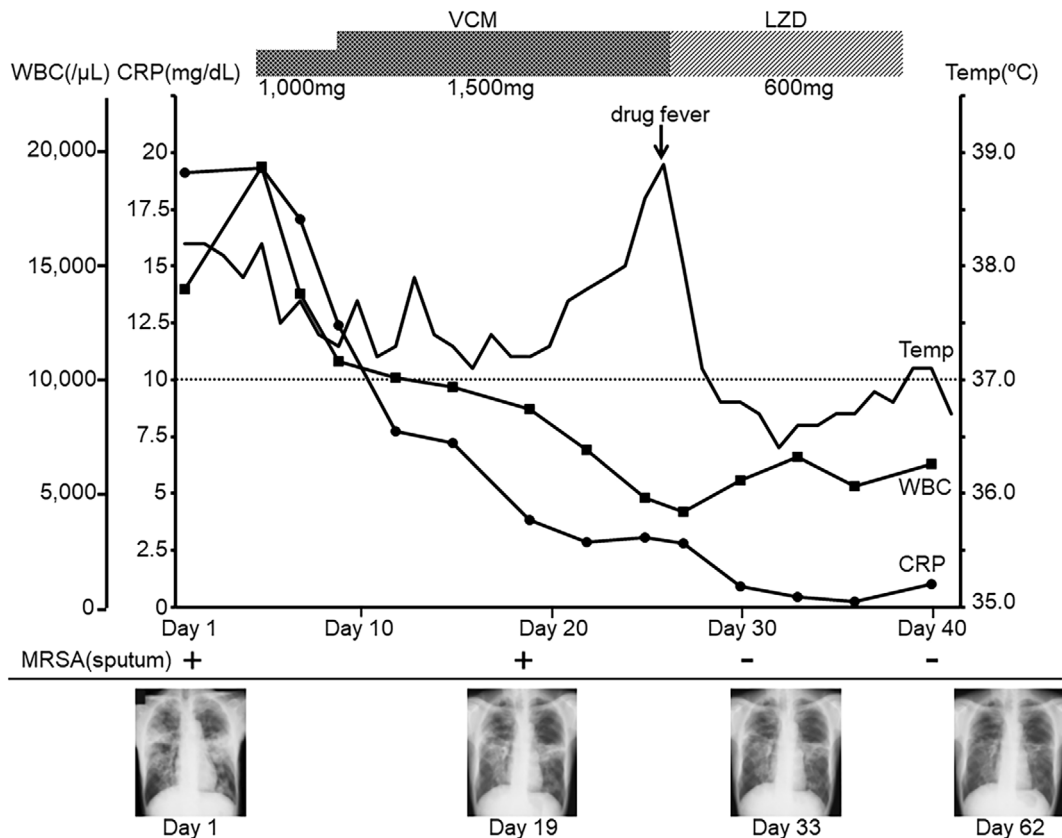


Figure 3. The clinical course after admission to our hospital. The patient was treated with vancomycin, which was subsequently escalated according to its trough value. Although low-grade fever continued, inflammatory markers, including the leukocyte count and serum level of CRP, gradually improved. On day 27, we changed vancomycin to linezolid because of drug-associated fever. At approximately one month after admission, MRSA was no longer detected in the patient's sputum and the bilateral multiple consolidations and cavities had improved. Anti-MRSA agents were stopped and he was discharged from our hospital.

were typical of and compatible with PVL-positive MRSA necrotizing pneumonia. The prior influenza infection was considered to be a trigger for the development of necrotizing pneumonia.

As shown in Table 1, our patient had an elevated serum *Aspergillus* antigen level. It was therefore important to exclude invasive pulmonary aspergillosis as a potential cause of the aggressive cavity formation in the bilateral lungs. Certain food products and antibiotics have been associated with false-positive reactions in Pastorex *Aspergillus* latex agglutination tests (16). In particular, a number of false-positives have been reported in patients treated with piperacillin/tazobactam (17). ABPC, which is obtained from the genus *Penicillium*, which contains galactofuran-bearing molecules in the cell wall could also cause a false-positive reaction in a *Aspergillus* antigen test (18). Thus, in the present case, we considered the *Aspergillus* antigen positivity of the present case to represent a false-positive result and attributed it to the administration of SBT/ABPC in the previous hospital.

CA-MRSA isolates are generally sensitive to various antibiotics other than β -lactams (19). In the present case,

MRSA isolated from the sputum and bronchial scrapings displayed sensitivity to trimethoprim/sulfamethoxazole, EM, CLDM, and MINO, which are usually resisted by HA-MRSA (19). These findings suggested the possibility of CA-MRSA infection, and the susceptibility profile in our case was similar to a case of CA-MRSA necrotizing pneumonia with PVL that was reported by Ito et al. (20). In contrast, six of the eight cases listed in Table 2 had MRSA isolates that were resistant to EM, whereas all cases, including our own, showed susceptibility to MINO (data not shown). According to a previous report, some cases of CA-MRSA infection showed resistance to macrolide antibiotics (19). Thus, if antimicrobial susceptibility testing shows a different profile from HA-MRSA, the possibility of CA-MRSA infection should be considered.

In conclusion, CA-MRSA pneumonia, especially with PVL production, should be suspected, even in healthy patients, when they show the rapidly progressive formation of multiple cavities. As CA-MRSA producing PVL has a very high fatality rate (21), immediate treatment with anti-MRSA agents is critical for halting the progression and preventing a fatal outcome.

Table 2. Case Series of Necrotizing Pneumonia Induced by CA-MRSA Reported from Japan.

No	Year	Age	Sex	Nationality	Past History	Consolidation	Cavity	Pleural Effusion	Bilaterality	Specimen	PVL	Therapy	Outcome	Ref.
1	2008	89	M	Japanese	Gastric cancer Ileus Pneumonia	+	+	+	No	Sputum	-	TEIC	Dead	[8]
2	2008	15	M	Japanese	Clavicle fracture MSSA infection Piriformis peri	+	+	+	No	Sputum	-	TEIC	Alive	[8]
3	2009	1	M	Japanese	None	+	-	+	Yes	Blood Effusion	+	VCM	Dead	[20]
4	2012	16	F	Vietnamese	None	+	+	-	Yes	Sputum	+	LZD CLDM	Alive	[14]
5	2013	54	F	Japanese	ITP	+	+	-	Yes	BALF Sputum	-	TEIC VCM	Alive	[22]
6	2013	31	M	African-American	None	+	+	-	Yes	Sputum Blood	+	VCM	Alive	[23]
7	2014	45	M	Japanese	Liver cirrhosis	-	-	-	No	Sputum	NA	LZD TEIC	Alive	[24]
8	2017	78	M	Japanese	Hypertension Diabetes	+	+	-	Yes	Sputum Blood	-	LZD TEIC CLDM	Dead	[25]
9	Present Case	66	M	Japanese	Pneumonia Renal Failure	+	+	+	Yes	Sputum Tissue	+	VCM LZD	Alive	

ITP: idiopathic thrombocytopenic purpura, MSSA: methicillin-sensitive *Staphylococcus aureus*, BALF: bronchial alveolar lavage fluid, N/A: not available, TEIC: teicoplanin, VCM: vancomycin, LZD: linezolid, CLDM: clindamycin

The authors state that they have no Conflict of Interest (COI).

References

- David MZ, Daum RS. Community-associated methicillin-resistant *Staphylococcus aureus*: epidemiology and clinical consequences of an emerging epidemic. *Clin Microbiol Rev* **23**: 616-687, 2010.
- Naimi T, LeDell K, Como-Sabetti K, et al. Comparison of community- and health care-associated methicillin-resistant *Staphylococcus aureus* infection. *JAMA* **290**: 2976-2984, 2003.
- Stryjewski ME, Chambers HF. Skin and soft-tissue infections caused by community-acquired methicillin-resistant *Staphylococcus aureus*. *Clin Infect Dis* **46**: S368-S377, 2008.
- Dickson RP, Martinez SM, Ortiz JR. A case of rapidly progressive necrotizing pneumonia caused by community-acquired methicillin-

- resistant *Staphylococcus aureus*. *Respir Care* **53**: 1223-1226, 2008.
5. Zhang K, McClure JA, Elsayed S, Louie T, Conly JM. Novel multiplex PCR assay for simultaneous identification of community-associated methicillin-resistant *Staphylococcus aureus* strains USA 300 and USA400 and detection of *mecA* and Panton-Valentine leukocidin genes, with discrimination of *Staphylococcus aureus* from coagulase-negative staphylococci. *J Clin Microbiol* **46**: 1118-1122, 2008.
 6. The Japanese Respiratory Society Guidelines for the Management of Pneumonia in Adults 2017. 9-33, 2017 (in Japanese).
 7. Yamamoto T, Taneike I, Nakagawa S, Iwakura N. Emergence of Panton-Valentine leukocidin positive community-acquired methicillin-resistant *Staphylococcus aureus*: status of infection and bacteriological features. *Nihon Kagakuryouhou Gakkai Zasshi (Jpn J Chemother)* **52**: 635-653, 2004 (in Japanese, Abstract in English).
 8. Tomita Y, Kawano O, Ichiyasu H, et al. Two cases of severe necrotizing pneumonia caused by community-acquired methicillin-resistant *Staphylococcus aureus*. *Nihon Kokyuki Gakkai Zasshi (Ann Jpn Respir Soc)* **46**: 395-403, 2008 (in Japanese, Abstract in English).
 9. Chongtrakool P, Ito T, Ma XX, et al. *Staphylococcus cassette chromosome mec (SCCmec)* typing of methicillin-resistant *Staphylococcus aureus* strains isolated in 11 Asian countries: a proposal for a new nomenclature for SCCmec elements. *Antimicrob Agents Chemother* **50**: 1001-1012, 2006.
 10. Yamaguchi T, Okamura S, Miura Y, Koyama S, Yanagisawa H, Matsumoto T. Molecular characterization of community-associated methicillin-resistant *Staphylococcus aureus* isolated from skin and pus samples of outpatients in Japan. *Microb Drug Resist* **21**: 441-447, 2015.
 11. Vandenesch F, Naimi T, Enright MC, et al. Community-acquired methicillin-resistant *Staphylococcus aureus* carrying Panton-Valentine leukocidin gene: worldwide emergence. *Emerg Infect Dis* **9**: 978-984, 2003.
 12. Yanagihara K, Araki N, Watanabe S, et al. Antimicrobial susceptibility and molecular characteristic of 857 methicillin-resistant *Staphylococcus aureus* isolates from 16 medical centers in Japan (2008-2009): Nationwide survey of community-acquired and nosocomial MRSA. *Diagn Microbiol Infect Dis* **72**: 253-257, 2012.
 13. Cheng VC, Lau YK, Lee KL, et al. Fatal co-infection with swine origin influenza virus A/H1N1 and community-acquired methicillin-resistant *Staphylococcus aureus*. *J Infect* **59**: 366-370, 2009.
 14. Kashiwada T, Kikuchi K, Abe S, et al. Staphylococcal enterotoxin B toxic shock syndrome induced by community-acquired methicillin-resistant *Staphylococcus aureus* (CA-MRSA). *Intern Med* **51**: 3085-3088, 2012.
 15. Labandeira-Rey M, Couzon F, Boisset S, et al. *Staphylococcus aureus* Panton-Valentine leukocidin causes necrotizing pneumonia. *Science* **315**: 1130-1133, 2007.
 16. Zandijk E, Mewis A, Magerman K, Cartuyvels R. False-positive results by the platelia *Aspergillus* galactomannan antigen test for patients treated with amoxicillin-clavulanate. *Clin Vaccine Immunol* **15**: 1132-1133, 2008.
 17. Orlopp K, von Lilienfeld-Toal M, Marklein G, et al. False positivity of the *Aspergillus* galactomannan Platelia ELISA because of piperacillin/tazobactam treatment: does it represent a clinical problem? *J Antimicrob Chemother* **62**: 1109-1112, 2008.
 18. Fortún J, Martín-Dávila P, Alvarez ME, et al. False-positive results of *Aspergillus* galactomannan antigenemia in liver transplant recipients. *Transplantation* **87**: 256-260, 2009.
 19. Yamamoto T, Takano T, Nishiyama A, Iwao Y, Hung WC. *Staphylococcus aureus* (methicillin resistant *S. aureus*: MRSA). *Nihon Rinsho (Jpn J Clin Med)* **70**: 205-212, 2012 (in Japanese, Abstract in English).
 20. Ito T, Nonoyama K. PVL yousei CA-MRSA shouni jyushou haien nihondenodaichirei. *Kansenseigyō* **5**: 163-166, 2009 (in Japanese).
 21. Panchabhai TS, Khabbaza JE, Raja S, Mehta AC, Hatipoğlu U. Extracorporeal membrane oxygenation and toilet bronchoscopy as a bridge to pneumonectomy in severe community-acquired methicillin-resistant *Staphylococcus aureus* pneumonia. *Ann Thorac Med* **10**: 292-294, 2015.
 22. Saito M, Oikawa T, Nakagawa K, Mizuno S, Osanai K, Toga H. A case of lung abscess caused by community-acquired methicillin-resistant *Staphylococcus aureus*. *Nihon Kokyuki Gakkai Zasshi (Ann Jpn Respir Soc)* **2**: 295-299, 2013 (in Japanese, Abstract in English).
 23. Iwanaga N, Fukuda Y, Nakamura S, et al. Necrotizing pneumonia due to femoral osteomyelitis caused by community-acquired methicillin resistant *Staphylococcus aureus*. *Intern Med* **52**: 1531-1536, 2013.
 24. Hoshi S, Mouri T, Nasu G, Andou T, Oikawa M. A case of community-acquired MRSA causing pulmonary abscess, complicated with abscesses in the thoracic wall and in the iliopsoas muscle. *Kagaku Ryooho No Ryouiki* **30**: 789-798, 2014 (in Japanese).
 25. Kodaka N, Niitsuma K, Yamagishi T, Kurose Y, Nakano C, Matsuse H. A case of necrotic pneumonia caused by community-acquired methicillin-resistant *Staphylococcus aureus*. *Nihon Kokyuki Gakkai Zasshi (Ann Jpn Respir Soc)* **6**: 160-164, 2017 (in Japanese, Abstract in English).

The Internal Medicine is an Open Access journal distributed under the Creative Commons Attribution-NonCommercial-NoDerivatives 4.0 International License. To view the details of this license, please visit (<https://creativecommons.org/licenses/by-nc-nd/4.0/>).