

There is No “Axillary Tail”: Rethinking the Assumption of James Spence

David Teplica, MD, MFA*†‡
 Emmett Cooney*§
 Eileen Jeffers, BA*
 Michael Sayers, BS*

Summary: Widely quoted, “the axillary tail of Spence” refers to a contiguous extension of adipose angling superolaterally from the primary breast into the axilla. Described anecdotally in 1871, the “tail of Spence” has been considered important to the fields of general surgery, oncology, plastic surgery, and anatomy ever since. Despite the ubiquitous presence of the concept in literature, clinical discussions, and educational settings, we argue against the very existence of Spence’s “tail.” While pinch-testing and topographically mapping 316 consecutive patients in preparation for breast and gynecomastia surgery, we found a consistent pattern of focal fat mounds without continuity between breast and axilla. The absence of an uninterrupted superolateral tail was reaffirmed while analyzing 20 research participants who were pinch-tested with calipers and topographically mapped, specifically to define fat pad anatomy. We documented that the axillary breast mound was always distinct from the primary breast and that all women and many men had an additional “lateral chest wall tail” that never angled toward the axilla. In most, rolling the shoulder girdle anteriorly created a visible groove between the axillary mound and the primary breast, with little or no pinchable fat beneath that crease. With all deference to Spence, we have established that the outer half of the chest is consistently defined by three focal adipose structures—an axillary mound, the primary breast mound, and a previously unnamed “lateral chest wall tail”—with no anatomic evidence of an “axillary tail” of fat extending superolaterally from breast to axilla. (*Plast Reconstr Surg Glob Open* 2022;10:e4086; doi: 10.1097/GOX.0000000000004086; Published online 9 February 2022.)

INTRODUCTION

Relatively few individuals were accorded the honor of a medical eponym. Regarding anatomy of the breast, those memorialized in this way include surgeon and anatomist Sir Astley Cooper for the “ligaments of Cooper,”¹ Rudolf “Virchow’s node” for lymphatic drainage that includes the superomedial breast,² and Scottish surgeon James Spence for his “axillary tail of Spence.” Following his tenure as president of the Royal College of Surgeons in Edinburgh, Spence described “...an undefined tail-like projection creeping up from the breast

towards the axilla” which he spoke of earlier, but first published in his 1871 volume *Lectures on Surgery*.³ In a paragraph discussing when a surgeon should not operate on breast carcinoma, Spence mentioned that when an ill-defined “tail” extends into the axilla (written as if he were referring to direct extension of tumor into the axilla, with no mention of benign fat or breast tissue), then one should not operate on that cancer. He never diagrammed or published the anatomy of the “tail.” Contemporaries who wrote of Spence’s concept were similarly vague about incidence of the finding and anatomy of the “tail.” A year before Spence published his own lectures, Bell clearly wrote in 1870 that Spence’s “tail” was not always present, mentioning that Spence used it to describe the path of infected lymphatic channels and nodes, although Bell never described his interpretation of the anatomic makeup of Spence’s concept.⁴ Curiously, in 1892 Stiles wrote that breast ducts extended all the way into the axilla on the basis of Spence’s claim, without providing anatomic evidence or mentioning either direct extension of tumor, or infection, or a “tail” of adipose.⁵ Therefore, the published record shows that Spence’s contemporaries could not find a tail in many

From *The 803 Foundation, Chicago, Ill.; † Section of Plastic & Reconstructive Surgery, Department of Surgery, The University of Chicago, Chicago, Ill.; ‡ The Kinsey Institute, Indiana University, Bloomington, Ind.; and §Biology Department, The Morrissey College of Arts and Sciences, Boston College, Chestnut Hill, Mass.

Received for publication November 19, 2021; accepted November 29, 2021.

Copyright © 2022 The Authors. Published by Wolters Kluwer Health, Inc. on behalf of The American Society of Plastic Surgeons. This is an open-access article distributed under the terms of the [Creative Commons Attribution-Non Commercial-No Derivatives License 4.0 \(CCBY-NC-ND\)](https://creativecommons.org/licenses/by-nc-nd/4.0/), where it is permissible to download and share the work provided it is properly cited. The work cannot be changed in any way or used commercially without permission from the journal.

DOI: 10.1097/GOX.0000000000004086

Disclosure: The authors have no financial interest to declare in relation to the content of this article.

patients and did not agree on its basic anatomic configuration or contents. Nonetheless, over subsequent years, surgeons somehow adopted a romantic concept of the “axillary tail of Spence” as normal human anatomy, composed of fat, through which some ducts and the lymphatic drainage system travel—without much proof from actual healthy anatomic data. With widespread acceptance 150 years later, students still find it mentioned in most general surgery textbooks, though Brunnicardi et al helped shift the narrative in 2006 in Schwartz’s *Manual of Surgery*, stating that the “tail” extends laterally.⁶ Despite the recent movement to de-eponymize medicine,⁷ the “axillary tail of Spence” remains in use, likely because of its presumed relevance in the management of breast cancers.^{8,9} However, we believe there is inadequate data in either the original anecdotal mention, in contemporaneous written accounts, or in the more recent described variations to support that the “tail of Spence” exists at all, let alone that it represents normal human anatomy.

BASIS FOR OUR HYPOTHESIS

For more than 24 years, the senior author and his clinical and research teams have been using pinch-distraction to topographically map the shapes and volumes of subcutaneous fat pads onto the surface of the skin,¹⁰ as seen in [Figure 1](#). This has served to define and quantify actual underlying anatomy in patients undergoing breast and body contouring procedures and in research participants as part of anatomic investigations. Informed by the pattern of lipohypertrophy seen in chronic survivors of HIV,¹¹ our healthy research participants were all discovered to have a strikingly consistent pattern of focal fat pad anatomy, even if less obvious than in the chronic HIV survivors. That insight became the foundation for several recent publications^{12,13} and now provides the basis for evaluating the veracity of Dr. Spence’s historic anecdotal mention. We showed that focal fat mounds consistently run down the anterior torso from axilla to groin in a configuration matching the curvilinear path of the mammary ridges seen in all placental mammal embryos.^{14,15} The superior-most of these is the axillary breast mound, followed by the primary breast, usually with a distinct projecting “lateral chest wall tail.” Just inferior and medial to these, an “anterior inferior chest wall mound” overlies costal cartilages and completes the series of four pairs of variably sized accessory breast mounds normally present on the chest ([Fig. 2](#)).

MATERIALS AND METHODS

In 1997, the senior author began pinch-testing fat pads on patients’ torsos by gently distracting skin and fat off the underlying muscle fascia to determine the shape and thickness of each focal adipose mound. Then, the findings were topographically mapped onto the skin surface in preparation for body contouring procedures, and each patient underwent highly standardized rotational photography of the torso with images captured at 45 degree increments to memorialize the findings.¹⁶ [Figure 3](#) shows a typical woman who has undergone distraction pinch-testing, topographic contour mapping of focal fat pads,

Takeaways

Question: Does the historical “axillary tail of Spence” really exist in human anatomy?

Findings: By pinch-testing 316 patients and 20 research participants, we determined that the anatomic fatty structure called the “axillary tail” was not present in any individual. Instead, anatomy of the superolateral chest is composed of three fatty foci: the axillary mound, primary breast mound, and “lateral chest wall tail.”

Meaning: By describing the true anatomy of the breast and the surrounding fatty mounds, physicians and surgeons can better care for individuals with benign and malignant diseases in the region. We support elimination of the anatomically inaccurate term “axillary tail of Spence” from medical parlance.

and highly standardized rotational imaging of the body in preparation for surgery the next morning, shown here at the 45 degree station.

We retrospectively evaluated all surgical cases since 2008 and excluded from analysis all individuals who presented for secondary care or breast implants. Of the remaining 316 consecutive patients, those who had chest procedures were analyzed (138 women and 178 men). Our patient population is strikingly diverse for age, gender, ethnicity, sexuality, hormonal station, gender identity, and states of disease or health.

In addition, we included data from 20 healthy lean individuals who participated in our recent study to define mammary ridge focal fat pad anatomy.¹³ Each research participant was pinch-tested using distraction technique and a Harpenden Skinfold Caliper (John Bull, British Indicators, Ltd., West Sussex, UK), topographically mapped, and photographed with the same methodology used for patients. Then, a rectilinear grid was mapped onto the anterior torsos of each to permit quantification of pinch-thickness over the entire region. [Figure 4](#) shows a representative participant from the earlier study, also providing data for this current analysis.

RESULTS

We reviewed the baseline unmarked, highly standardized, rotational images of the torsos of patients and study participants, as well as their standardized mapped images. We failed to uncover a single instance when a fatty extension of the upper-outer breast angled superiorly into the axilla, either in cases of male gynecomastia or in women undergoing breast procedures ([Figs. 5, 6](#)). Instead, when fullness was present, 100% exhibited a lateral chest wall tail extending from the primary breast laterally, then posteriorly. Among lean individuals, pinch-testing done between the axillary mound and primary breast was “skin on skin,” with no significant subcutaneous fullness between the mounds. In those with moderate generalized subcutaneous fullness or thicker accessory breast mounds, rolling the shoulder girdle anteriorly (at full exhalation without pectoral contraction) usually

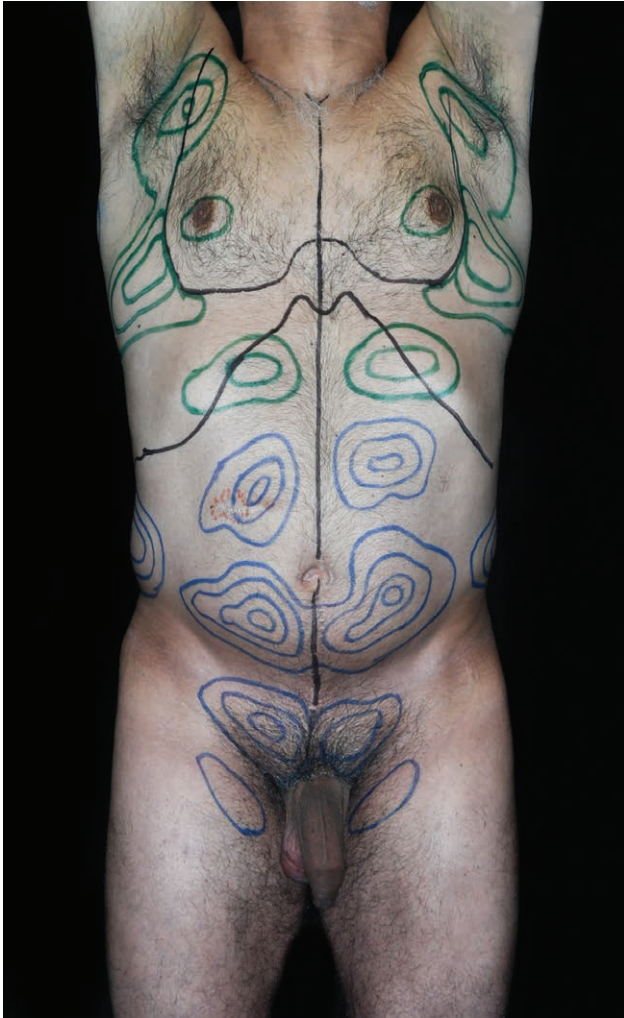


Fig. 1. Pinch-distraction of subcutaneous fat away from the underlying muscle fascia allows topographic mapping of actual fatty thicknesses onto the overlying skin surface. Shown here is a Hispanic homosexual man with contour rings in 1 cm increments of pinch-thickness above this patient’s baseline 1 cm of subcutaneous fullness. This typical pattern of paired focal mounds runs along the curvilinear path from axilla to groin, consistent with the lines of embryological mammary ridges. Although less evident in healthy individuals, the pattern can be easily identified in those with lipohypertrophy due to chronic HIV as seen here. Note the triad of focal regions of adiposity on the upper-outer chest bilaterally, contour mapped in green. A fourth accessory breast mound is consistently present on the anterior inferior chest wall below the primary breast mound. Mapped in blue are the four remaining mounds along the curvilinear line of the embryological mammary ridges: upper abdominal mounds, lower abdominal mounds, pubic mounds, and the anteromedial thigh mounds. All eight paired foci have the potential to enlarge massively in HIV lipohypertrophy.

resulted in a groove between axilla and breast, with little or no pinchable subcutaneous fat beneath the crease, as demonstrated in [Figure 7](#). No person mapped or pinched had a continuous extension of fat connecting the breast with the axilla.

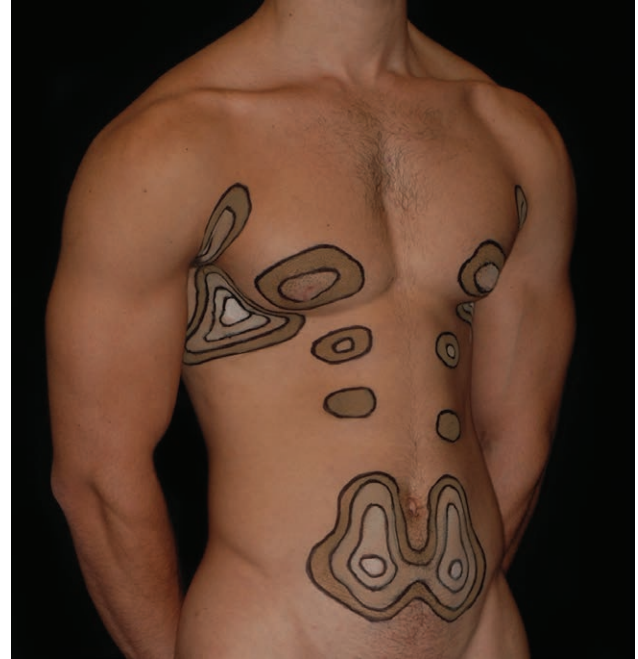

Fig. 2. A healthy Middle Eastern medical model is graphically plotted with a meta-analysis of loci and thicknesses of lipohypertrophy gleaned from 500 consecutive HIV patients. Their fat mounds and the typical relative thicknesses are shown as contour projections with tiers representing one cm increments of adipose thickness above baseline. Note the defined axillary mound, the primary (subareolar) breast, the orientation of the lateral chest wall tail, and the paired anterior inferior chest wall mounds atop costal cartilages. Also plotted are the consistent upper and lower abdominal mounds. This pattern (albeit with widely varying proportions) seems to represent normal human anatomy, as it is seen in all genders, ages, sexualities, states of disease and health, and in all ethnicities. Importantly, we have never found a fatty mound in any other location than these on the anterior torso.

DISCUSSION

Our anatomic evidence suggests “the axillary tail of Spence” does not exist as originally mentioned or subsequently described. Although they can be small, we instead found consistent and distinct bilateral axillary mounds and lateral chest wall tails—two pairs of accessory breast mounds (with or without normal ductal elements) superior and lateral to the primary breast, respectively. In our sample of 336 individuals analyzed, we identified approximately 10 patients whose mounds could be called small “axillary breasts,” having other vestigial mammary elements, including forme fruste nipples, diminutive areolae, and/or overlying clusters of hair. Several of these had palpable ductal elements, though none had symptoms or pathological findings.

Although the laterally oriented focal fat has been called the “lateral chest wall roll,”¹⁷ the term “lateral chest wall tail” is the appropriate moniker, as the focal fat always abuts the primary breast just lateral to the lateral border of the pectoral muscle. The feature then tapers in width and volume down to nothing as it wraps posterolaterally, as mapped in a South Asian woman ([Fig. 8](#)) and an elderly man of Russian heritage ([Fig. 9](#)). We have never

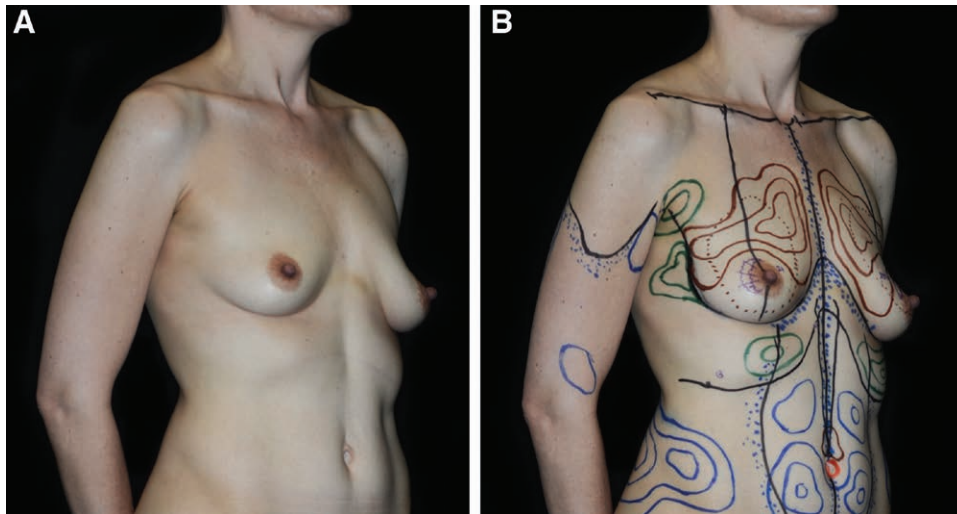


Fig. 3. This peri-menopausal woman of Irish extraction presented for anatomically based circumferential liposuction with harvest of particulate fat for immediate grafting of the breasts. She is shown preoperatively in A and topographically mapped in B. Note the separate and distinct pinch-mapped accessory breast mound of the axilla, lateral chest wall tail, and anterior inferior chest wall, delineated with green concentric contour rings. The breasts are topographically mapped with brown contour rings where fat transfer would add superior fill. Unrelated to the chest concerns, this patient is also mapped for anatomically based circumferential lipectomy of the arms and lower torso; anatomic boundaries were marked in black, focal fat pads were mapped with blue concentric contour rings, and blue stippling denoted areas where fullness was to be removed below baseline thickness to create subtle troughs of muscular definition. Repaired during the same procedure was an umbilical hernia documented here in orange.

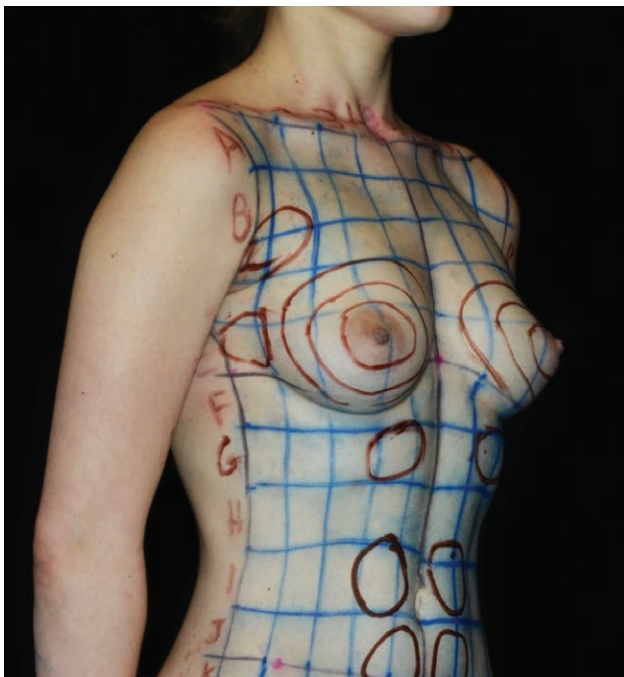


Fig. 4. A bisexual woman of British descent was grid mapped and pinch-tested with calipers for a recent study to define the paired focal fat pads along the embryological mammary ridge. Once thickness of subcutaneous fat was determined for each grid cell, brown ink was used in this study to plot those areas of focal adipose fullness back onto the surface of the body. As illustrated, the axillary mound, primary breast, lateral chest wall tail, and the anterior inferior chest wall mound represent distinct foci of breast fat, whether primary or accessory.

seen a distinct, tubular “roll” on the chest wall that was not a tapering extension. The tail appears physiologically distinct from the primary breast, as we have documented in many clinical situations that enlargement of either the primary breast or the lateral tail can occur without growth of the other.

In patients with higher fat content, anterior rolling of the shoulder girdle usually results in a crease between the axillary mound and primary breast, with little to no pinchable fat atop the pectoralis. In obese individuals as well as those with genetic or disease-based hypertrophy of the accessory breasts, the mounds are more difficult to distinguish visually, though pinch-distraction and/or anterior shoulder rotation usually permit identification of a separating crease between the mounds. We caution that indiscriminate pinch-testing of a large swath of subcutaneous tissue or pinching across mounds can result in a myriad of shapes that confuse analysis, as depicted in [Figure 10](#). Instead, knowledge of focal fat pad anatomy permits pinch-testing between specific adipose mounds to confirm they are separate.

From an oncological perspective, the numerous reports of breast cancers arising in various accessory breast mounds include those originating within the “axillary tail of Spence.” We suggest these are likely *de novo* tumors arising within ductal or parenchymal elements of axillary breasts (more complete embryologic expressions of simple fatty mounds), for which there are many additional reports, historic and recent,¹⁸ or that the tumors were simply located near the outer perimeter of the upper-outer quadrant. From a surgical oncology perspective,

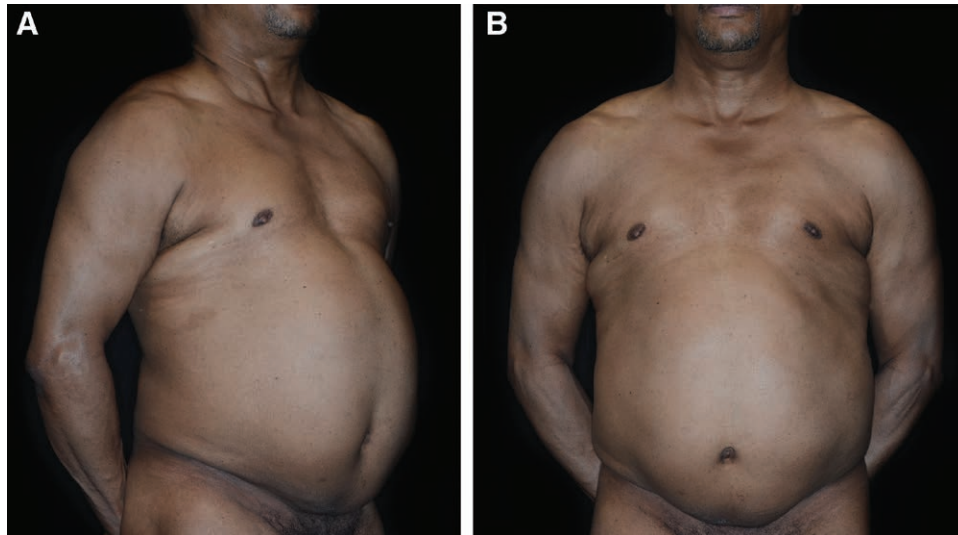


Fig. 5. Hypertrophic superolateral chest wall fat pads and intervening creases are particularly evident in this post-andropausal and diabetic African American man. Hypertrophic findings in the 45 degree (A) and 0 degree (B) rotational views represent the typical anatomy seen to a greater or lesser degree across our entire patient population and among all healthy lean research participants as well. Note that this patient exhibits hypertrophy of the lateral chest wall tails without significant enlargement of the primary breast mounds. It appears focal fat pads enlarge or decrease in size with aging, changes of hormonal station, or due to disease, but that the basic anatomic arrangement of the mounds is not altered by any of those processes.

our findings do not alter how mastectomy should be performed, as it is widely acknowledged that lymphatic drainage of the breast extends into the axilla along the same path as Spence’s presumed “tail.” Therefore, resection should continue to remove the primary breast and axillary fat, whether that fat exists as a “tail” or form-fruste separate breast mound along the mammary ridge. Our

findings may have more of an impact on reconstructive care, when knowledge of normal anatomy will enhance the ability to generate symmetry or to shift a woman’s anatomy to a more youthful (less postmenopausal) configuration by addressing each mound independently.

Most would acknowledge that the size of any individual’s body is partially under that person’s control, based upon caloric intake and burn. However, as our group previously demonstrated using a monozygotic twin research model, human body shape appears to be almost entirely genetically based.¹⁹ In that study, we identified fat pad asymmetries that were either directly concordant or mirrored within any twin pair and concluded that body shape must be genetically encoded as nothing environmental can create mirrors. As body shape is primarily determined by the relative fullness and configuration of each of the focal fat pads in any given individual, these factors (also called “proportionality”) must be “anatomically predetermined” if twins have the same or mirrored shape. In contrast, gaining and losing weight only temporarily changes the size of adipose foci. Our data also show that aging, changes of hormonal station, and severe systemic disease can all permanently change the relative fullness of focal fat pads and therefore one’s shape. However, the basic anatomic arrangement of the focal mounds (the common human pattern for fat pad arrangement) is unaltered. It appears that anatomy is fixed for any given stage in life and that the wide variations in thickness of fat pads account for the extreme diversity of human phenotypes. Applying this concept to the accessory breast mounds described in this current project, all individuals analyzed showed the same fixed adipose foci on the upper-outer chest, albeit with different thicknesses and a wide array of phenotypes.

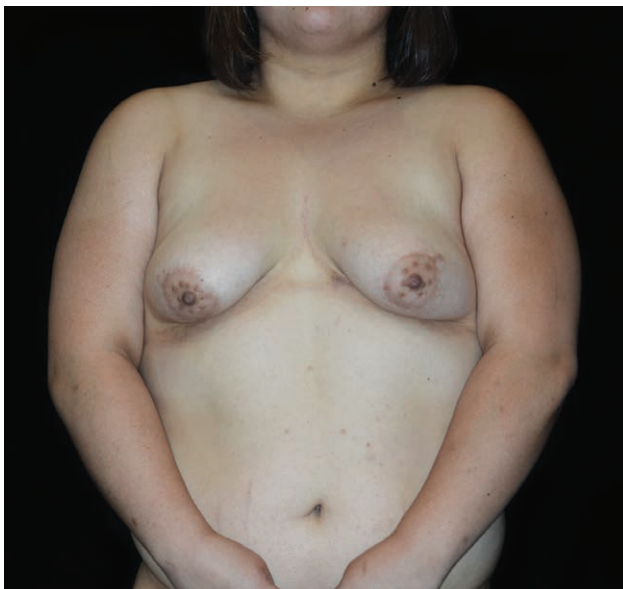

Fig. 6. A 20-year-old woman of Southeast Asian descent exhibits cushingoid features, but still has the same pattern of fullness in the accessory breasts, as well as a groove of hollowness between the primary breasts and the axillary mounds when the arms are partially rolled forward.

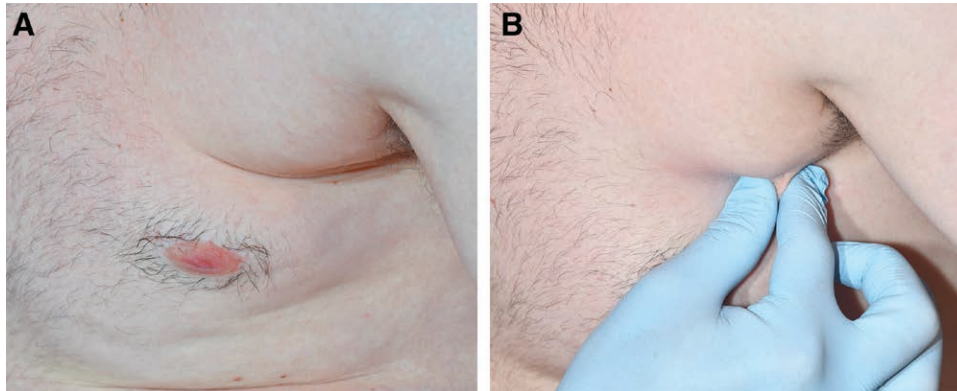


Fig. 7. Pictured is a lean young male medical model of northern European extraction, photographed at the 315 degree rotational station, at full exhale, without pectoral muscle contraction, with arms placed in the anatomic position, and with shoulder girdle rolled anteriorly. Note the crease between the small axillary mound and the primary breast mound (A). Pinch-distraction of the subcutaneous tissues off the underlying pectoralis muscle fascia along the crease shows only skin-on-skin content, without contiguous or adherent adipose between the mounds (B). This finding is consistent and negates the possibility of a continuous “axillary tail” of fat traveling into the axilla.

Only recently was it proven that eight pairs of fatty foci—likely adult vestiges of primordial teats—run along the paths of the embryological mammary ridges.¹³ We contend that it would have been nearly impossible for Spence to deduce the local fatty anatomy of the chest in 1871, without the broader understanding of fat pad anatomy made possible by accurate calipers and pinch-distraction methods, modern topographic mapping techniques, and standardized digital photography to accurately document findings. Also, before the advent of worldwide travel and easy access to extreme social diversity, Spence could not have easily recognized that a defined pattern of focal fat pad anatomy is consistently present, regardless of age, gender, sexuality, ethnicity, hormonal station, or states of disease or health.

Although our findings clash with the well-entrenched supposition of an “axillary tail of Spence,” we argue that an improved understanding of actual baseline anatomy is

imperative to provide a rational foundation upon which future medical treatments and surgical procedures can be based. In any scientific discipline, skepticism and a logical approach to question unsupported concepts are essential. We contend that longstanding beliefs based upon historical, anecdotal mentions should always be reexamined.

Further work is needed to correlate our clinical findings with cadaveric anatomic dissection and histopathology. In addition, re-evaluation of imaging studies should be undertaken with these new clinical anatomic insights, including determining whether any breast ductal tissue crosses the consistently lean crease that exists between the primary breast and the axillary mound.

CONCLUSIONS

With more than 20 years of pinch-testing and topographic mapping of focal fat, we have never identified a single “axillary tail” that angles superiorly from the primary breast into the axilla. Instead, our study participants showed that a clear pattern of accessory breasts is consistently present, comprising the entirety of focal adipose anatomy on the upper-outer chest, representing normal human anatomy. Even lean individuals almost always exhibit a small but defined axillary mound, separate primary breast, and a “lateral chest wall tail” that wraps posterolaterally. These fixed anatomic structures can enlarge as fat content increases, obscuring focality, but remaining anatomically and physiologically distinct. When the shoulder is rolled anteriorly, a deep groove often forms between the mounds, with little or no pinchable fat beneath that crease. It has been well-established that the lymphatic drainage channels do indeed follow the path mentioned by James Spence, but we have demonstrated that neither fatty anatomy nor significant volumes of breast tissue do so. Therefore, to improve the dialog about actual anatomy of the chest and with all respect due to an esteemed historic colleague, we suggest the term “axillary tail” be retired from the medical lexicon.

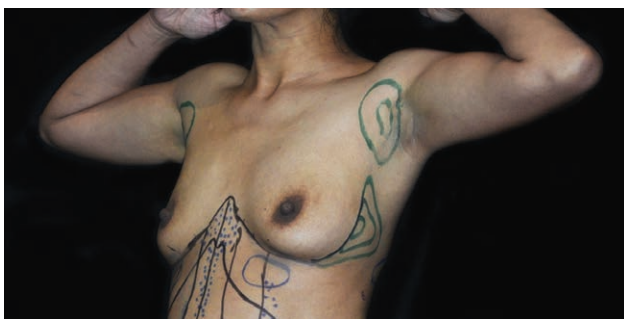


Fig. 8. This South Asian woman was mapped using pinch-distraction technique preoperatively. She exhibits small axillary breasts with benign palpable ductal elements and the typical pattern of tapering fullness of the lateral chest wall tail, as it wraps posterolaterally. Also marked in blue on her left side is a slightly enlarged anterior inferior chest wall accessory breast mound. Below the frame of this image, her abdomen was also mapped in preparation for anatomically based circumferential liposuction of the full torso.

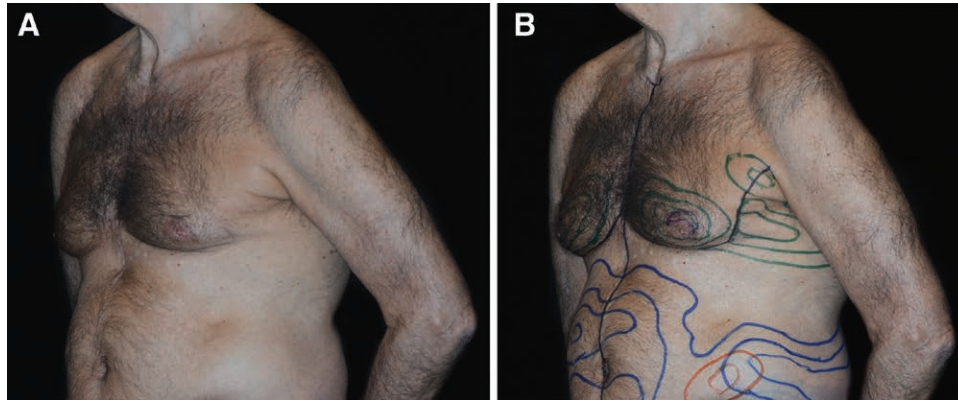


Fig. 9. An elderly heterosexual gentleman of Russian and Eastern European heritage exhibits the same pattern of creases and accessory breast mounds as the others in our sample. Shown unmarked (A) and after topographic pinch mapping (B), in preparation for anatomically based correction of gynecomastia. Also seen, though unrelated to the chest issues are blue contour rings for liposuction of the torso and orange rings documenting the subcutaneous location and relative volume of a penile pump reservoir to be avoided during the case.

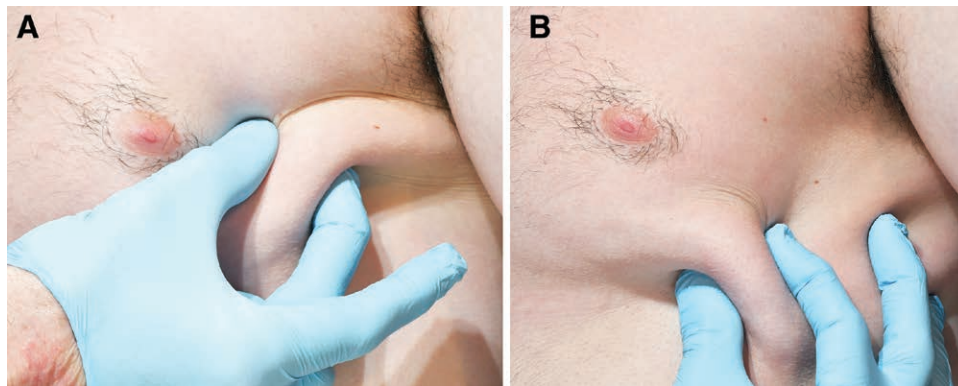


Fig. 10. This composite image shows two errors of pinch-testing that ignore the underlying fat pad anatomy. A, A wide swath of generalized subcutaneous fat is drawn together in a way that bridges two distinct accessory breasts. By doing so, the fat appears as a single roll that angles superolaterally, giving the false impression of an “axillary tail.” However, despite our best efforts, this “tail” could not be pinched to angle into the axilla as Spence contended, but never described. B, A wide swath of subcutaneous fat is pinched orthogonally to the mammary line, giving the false impression of an “inferolateral tail,” which no one has suggested exists.

David Teplica, MD, MFA
 803 W Hutchinson St
 Chicago, IL 60613
 E-mail: doctor@davidteplica.com

provided valuable administrative support throughout the duration of article preparation. Steve Goudy, MBA coordinated administrative aspects of this project, and Jamey Srock and Linda Goudy provided valuable editorial assistance.

ACKNOWLEDGMENTS

We thank the American Institute of Bisexuality of Los Angeles, California for critical financial support for our projects that allowed us to define the anatomic correlates of gender and sexuality, leading to elucidation of the fat pad anatomy of the chest. John Sylla of Los Angeles has provided important ongoing guidance and encouragement. Virginia J. Vitzthum, PhD of the Department of Anthropology at Indiana University provided the calipers used for data collection and gave important insights regarding pinch-testing. No individuals from these supporting sources had any role in background research, project direction, or preparation of the final article or its content. Florence Hlivko of Johnstown, Pennsylvania

REFERENCES

1. Cooper AP. Plate IV: Ligaments suspensoria and sections. In: Cooper AP, ed. *On the Anatomy of the Breast*. London: Longman, Orme, Green, Brown, and Longmans;1840.
2. Virchow R. Zur diagnose der krebse im unterleibe. *Medizinische Reform*. 1848;45:248.
3. Spence J. Lecture XX: Malignant tumours—Brief outline of the varieties of carcinoma, namely, scirrhus, colloid cancer, and epithelial cancer—characters, causes, and symptoms of carcinoma: Its diagnosis prognosis, and treatment. In: Spence J, ed. *Lectures on Surgery*. Edinburgh: Adam and Charles Black; 1871;1:131.
4. Bell J. Notes on excision of the mamma. *Edinb Med J*. 1871;16:687–691.

5. Stiles HJ. Contributions to the surgical anatomy of the breast and axillary lymphatic glands. *Edinb Med J.* 1892;38:26–42.
6. Brunnicardi FC, Andersen DK, Billiar TR, et al. Chapter 16: the breast. In: Bland KI, Beenken SW, Copeland EE, eds. *Schwartz's Manual of Surgery*. 8th ed. McGraw-Hill; 2006:344.
7. Burdan F, Dworżański W, Cendrowska-Pinkosz M, et al. Anatomical eponyms – unloved names in medical terminology. *Folia Morphol (Warsz.)*. 2016; 75:413–438.
8. Ampil F, Caldito G, Henderson B, et al. Carcinoma of the axillary tail of Spence: a case series. *Anticancer Res.* 2012; 32: 4060–4067.
9. Desai AA, Hoskin TL, Day CN, et al. Effect of primary breast tumor location on axillary nodal positivity. *Ann Surg Oncol.* 2018; 25:3011–3018.
10. Teplica D, Cooney E, Kirklys M, et al. Cartography and topographic mapping: the historical basis for the standardization of anatomic analysis and surgical mark-making to improve outcomes in body contouring. *Plast Reconstr Surg.* 2022;148:(In Press).
11. Teplica D. Discussion: Autologous fat grafting and dermal fillers for HIV-associated facial lipodystrophy: A comparison of safety, efficacy, and long-term treatment outcomes. *Plast and Reconstr Surg.* 2013;131:507–509.
12. Bank J, Teplica D. Anatomy of flank adipose: the Y configuration and hip extension and their effects on the perception of gender. *Plast Reconstr Surg.* 2020;146:836e–838e.
13. Teplica D, Kovich G, Srock J, et al. Newly identified gross human anatomy: eight paired vestigial breast mounds run along the embryological mammary ridges in lean adults. *Plast Reconstr Surg Glob Open.* 2021;9:e3863.
14. Netter FH, Geschickter CF. Anatomy and pathology of the mammary gland. In: Netter, FN, Oppenheimer, E, eds. *The CIBA Collection of Medical Illustrations*. Rochester, NY: The Case-Hoyt Corporation; 1977;2:250.
15. Cunningham MD, Acker D, ed. *Animal Science and Industry*. Hoboken, N.J.: Pearson Prentice Hall; 2005.
16. Teplica D, Schulman D, Masri V. Highly standardized rotational photography of the torso. *J Biocommun.* 2020;44:7–9.
17. Evans G, ed. *Operative Plastic Surgery*. Oxford, UK: Oxford University Press; 2019:149.
18. Khan RN, Parvaiz MA, Khan AI, et al. Invasive carcinoma in accessory axillary breast tissue: a case report. *Int J Surg Case Rep.* 2019;59:152–155.
19. Teplica D. The genetic basis of body shape: lessons from mirror twins and high-definition digital photography. *Virtual Mentor.* 2010;12:412–417.