



# Cholangioscopy in primary sclerosing cholangitis: a case series of benign features

Sooraj Tejaswi, MD, MSPH, FASGE,<sup>1</sup> Thomas W. Loehfelm, MD, PhD,<sup>2</sup> Kristin A. Olson, MD<sup>3</sup>

**Background and Aims:** Cholangioscopy is useful in establishing a visual diagnosis of cholangiocarcinoma (CCA), but this is harder to achieve in primary sclerosing cholangitis (PSC) because of the stricture-forming nature of the disease. Furthermore, it can be harder to differentiate malignant from benign features of the underlying inflammation. This case series demonstrates the varied features of nonmalignant inflammatory findings in PSC.

**Methods:** A single experienced endoscopist performed cholangioscopy for PSC cases referred for ERCP.

**Results:** Cholangioscopy in these 5 cases without CCA demonstrated the features of acute and chronic inflammation, acute inflammatory mass, dominant stricture, acute cholangitis in a duct with features of chronic inflammation with a large pigmented stone, and fibrostenotic disease. Cholangioscopic maneuvers such as advancement across strictures after balloon dilation, targeted mucosal biopsy, and electrohydraulic lithotripsy (EHL) of impacted stones are demonstrated. The relevant radiographic and histopathologic features of the disease accompany each case description. Regarding long-term prognosis, 1 case of acute inflammatory mass and a case of worsening liver function required a liver transplant evaluation, whereas the other 3 cases remain stable.

**Conclusions:** Cholangioscopic features of benign disease in PSC are varied. Knowledge of these features is essential in differentiating between benign and malignant findings. These features, combined with biopsy and cytology evaluation, can help in tailoring management in patients with benign PSC. (VideoGIE 2021;6:431-7.)

PSC is a chronic inflammatory disease characterized by intrahepatic and extrahepatic bile duct strictures. PSC is associated with a high risk of CCA, which is strongly suspected in the presence of a dominant stricture. However, the majority of dominant strictures do not progress to CCA.<sup>1,2</sup> Therefore, accurate differentiation of benign and malignant strictures in PSC is crucial. Brush cytology of strictures is the most common modality used to differentiate benign and malignant strictures, but it is hampered by a low diagnostic yield.<sup>3</sup> Although it is not considered standard of care, cholangioscopy aids in establishing a visual diagnosis based on characteristic visual features and offers the ability to obtain targeted biopsy specimens for confirmation.<sup>1,4</sup> It is important to be cognizant of the features of benign disease in PSC in order to differentiate benign inflammatory findings from those of malignancy.

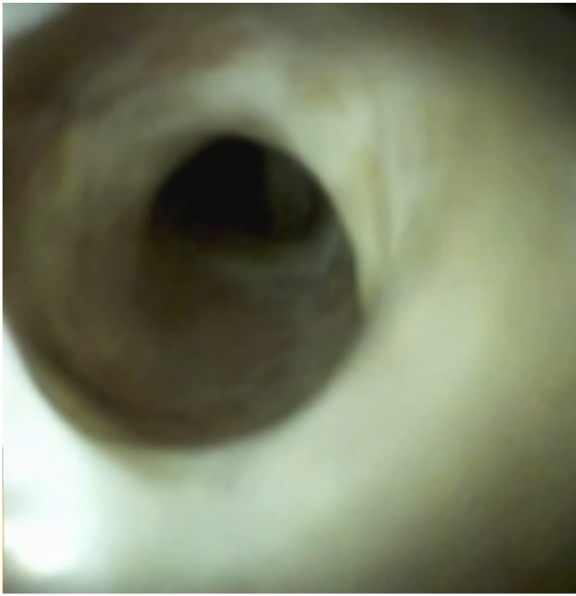In this case series, we present the cholangioscopic features of benign PSC.

## DESCRIPTION OF TECHNIQUE

All procedures were performed using the duodenoscope (Olympus TJF-180, Olympus America, Inc, Center

Valley, Pa) and the third-generation single operator cholangioscope (SpyScope DSII Access and Deliver Catheter, Boston Scientific Corp, Natick, Mass). Intraductal biopsies were performed using the SpyBite or SpyBite Max forceps, depending on the width of the bile duct lumen.

The technique of cholangioscopy in PSC is similar to non-PSC cases, with the following exceptions. Advancement of the cholangioscope under direct visualization should be performed with caution. This helps in avoiding mucosal trauma that can obscure the visual features of PSC and thereby increase the need for irrigation, which can increase the intraductal pressure and the risk of cholangitis.<sup>5</sup> Balloon dilation followed by cholangioscope advancement can be successful if a stricture is too narrow to navigate. A 4-mm dilation balloon is usually adequate to allow for cholangioscope advancement. Impacted pigmented stones can be encountered proximal to strictures in the common bile duct (CBD) or the common hepatic duct (CHD). In addition, intraductal stones might not be seen on preprocedure cross-sectional imaging.<sup>6</sup> Care should be taken to minimize irrigation to avoid displacing pigmented stones proximally into the intrahepatic ducts.<sup>7</sup> It is preferable to examine as much of the biliary tree as possible before undertaking interventions such as stricture dilation, cytology brushings,



**Figure 1.** Fibrostenotic stricture in distal common bile duct in case number 1.

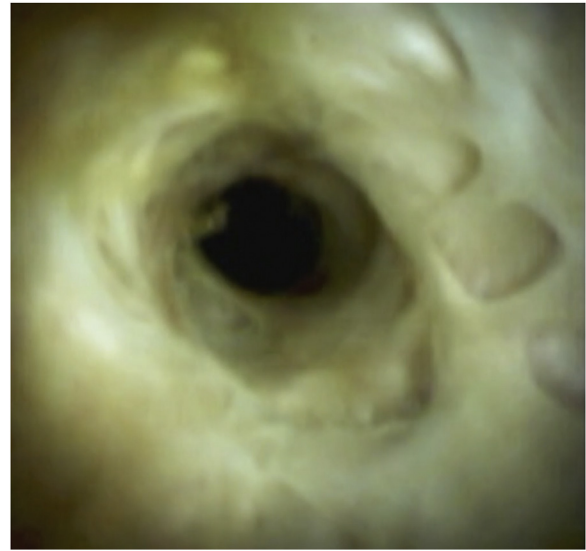
and forceps biopsy. Detailed examination of the extrahepatic duct and hilum is key because CCA predominantly affects this region.<sup>8,9</sup> Targeted biopsy specimens should be obtained from any suspicious lesions.

Cytology brushing should be obtained from all strictures. In our experience, brush cytology was diagnostic in some cases of nondiagnostic biopsy. In addition, it is our practice to perform fluorescent in situ hybridization (FISH) analysis on brushings obtained from strictures.<sup>1</sup> Cholangitis has been reported in 0.25% to 8% of patients with PSC undergoing ERCP and in up to 11% of patients undergoing cholangioscopy.<sup>6</sup> All patients should be given periprocedural antibiotic prophylaxis.<sup>1</sup> It is our practice to prescribe antibiotics for 3 to 5 days postprocedure to prevent cholangitis. In our case series, patients with known cholangitis were treated with antibiotics for 10 to 14 days. All patients received rectal indomethacin 100 mg suppository to prevent post-ERCP pancreatitis, unless contraindicated.<sup>1</sup>

In general, we avoided placing stents across strictures because of the higher rate of adverse events reported with stent placement.<sup>10</sup> However, when patients had incomplete clearance of pigmented stones proximal to a dominant stricture, we placed small-caliber plastic stents (5F Cook Geenan or 7F Cook Cotton Leung, Cook Medical, Bloomington, Ind) and repeated ERCP within 1 to 2 weeks to remove the stent and clear the duct. Long-term stent placement carries a higher risk of stent occlusion and cholangitis in PSC and is not associated with additional benefit when balloon dilation is performed.<sup>11</sup>

## VIDEO DESCRIPTION

Case number 1 is a 20-year-old African American man with hyperbilirubinemia and a history of extrahepatic duct stric-



**Figure 2.** Chronic inflammation in mid-common bile duct in case number 1.

ture that had been balloon dilated to 4 mm followed by CBD stent placement. He presented with significant cholestasis (total bilirubin 8.1 mg/dL, alkaline phosphatase [ALP] 722 U/L, aspartate aminotransferase [AST] 191 U/L, and alanine aminotransferase [ALT] 79 U/L). CA 19-9 was mildly elevated (81.8 U/L) ([Video, Part 1](#) available online at [www.giejournal.org](http://www.giejournal.org)). Magnetic resonance imaging (MRI) showed segmental dilation of the intrahepatic and extrahepatic biliary tree, with bilomas containing layering debris.

Cholangioscopy showed a tortuous and narrow distal duct with pale mucosa ([Fig. 1](#)). Concentric fibrosis and multiple pseudodiverticula were seen in the mid-CBD and CHD extending up to the hilum ([Fig. 2](#)). A small amount of sludge was noted in the CHD and hilum.

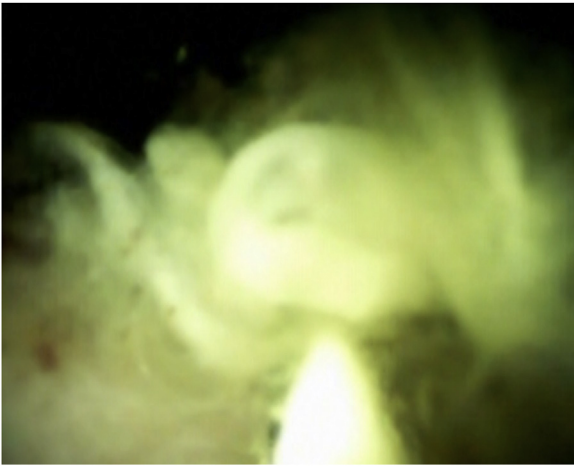The patient went on to develop radiographic features of compensated cirrhosis but is currently stable. Liver function tests (LFTs) 6 years after cholangioscopy showed persistent but milder cholestasis (total bilirubin 2.2 mg/dL, ALP 740 U/L, AST 178 U/L, and ALT 124 U/L). CA 19-9 is not elevated (34.5 U/L).

Case number 2 is a 30-year-old Asian man with worsening right upper quadrant pain and significant cholestasis (total bilirubin 8.5 mg/dL, ALP 1111 U/L, AST 94 U/L, and ALT 108 U/L). CA 19-9 was not elevated (28.5 U/L) ([Video, Part 2](#) available online at [www.giejournal.org](http://www.giejournal.org)). MRI showed multifocal intrahepatic strictures with intrahepatic and extrahepatic bile duct dilation.

Cholangioscopy was performed with freehand cannulation and showed pale mucosa with papillary projections in the distal CBD. The hilum and intrahepatic ducts showed pale mucosa with faint concentric rings.

The patient was referred for a liver transplant evaluation because of worsening liver disease.

Case number 3 is a 70-year-old white man with decompensated cirrhosis and acute cholangitis with a large porta



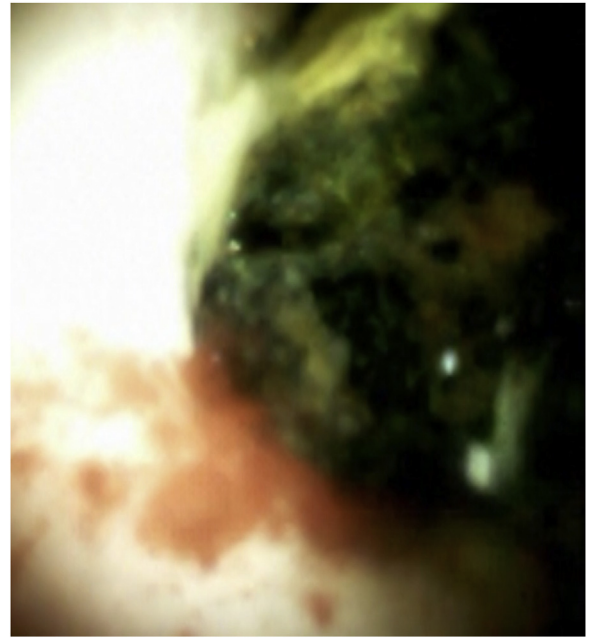**Figure 3.** Purulence in the common hepatic duct stricture in case number 3.

hepatis pigmented stone noted on imaging. LFTs showed cholestasis. CA 19-9 was not elevated (Video, Part 3 available online at [www.giejournal.org](http://www.giejournal.org)). MRI showed biliary ductal dilation at the hilum with hepatolithiasis.

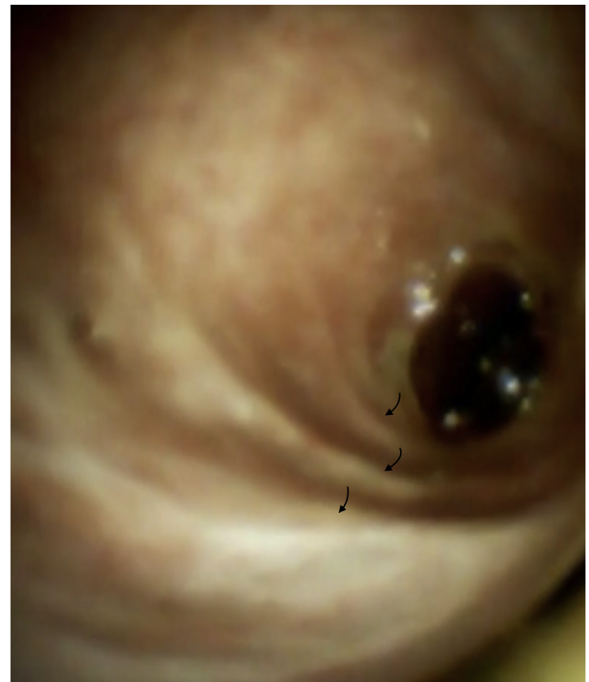Cholangioscopy showed pus emanating from beneath an obstructing black pigmented stone at the hilum (Figs. 3 and 4). EHL tunneled through the large stone, after which balloon and basket sweeps led to stone extraction and duct clearance. The hilum and the rest of the extrahepatic duct were examined after stone clearance and showed scattered plugs of purulence and mucosal erythema, which was most likely a consequence of interventions performed during the procedure. Concentric fibrotic rings were seen in the extrahepatic duct (Fig. 5).

LFTs normalized in this patient after stone clearance, and he did not need repeat ERCP. However, his cirrhosis has progressed over the years.

Case number 4 is a 71-year-old white man with fatigue, new-onset cholestasis, and a normal CA 19-9 level (Video, Part 4 available online at [www.giejournal.org](http://www.giejournal.org)). MRI showed a mild narrowing of the CHD with beading of the intrahepatic ducts. Cholangioscopy showed a dominant stricture in the CHD through which pigmented stone fragments were emanating (Fig. 6). This stricture was dilated with a 6-mm balloon. Cholangioscopy was performed after dilation and showed mucosal trauma and fragments of crushed pigmented stone along the wall of the CHD (Fig. 7). In the mid-CBD, a semicircular fibrotic ring was seen. Cytology brushings showed atypical cells. Cholangioscopy was repeated 10 months later and showed mild erythema of the hilum and chronic inflammation in the form of mucosal scars in the mid-CBD. Atypical cells were noted once again on cytology brushings. Hence, cholangioscopy was repeated again 2 months later and showed an ulcer in the CHD with surrounding erythema (Fig. 8). Biopsy specimens of the erythematous area showed acute inflammation, with no evidence of



**Figure 4.** Common hepatic duct stone in case number 3.



**Figure 5.** Concentric fibrotic rings (black arrows) in the mid-distal common bile duct in case number 3.

dysplasia or cancer. Cytology brushings and FISH analysis were negative. The duct distal to this area of acute inflammation showed chronic inflammatory changes with mucosal scarring. The patient is clinically stable without evidence of disease progression at 8 months since the last cholangioscopy.



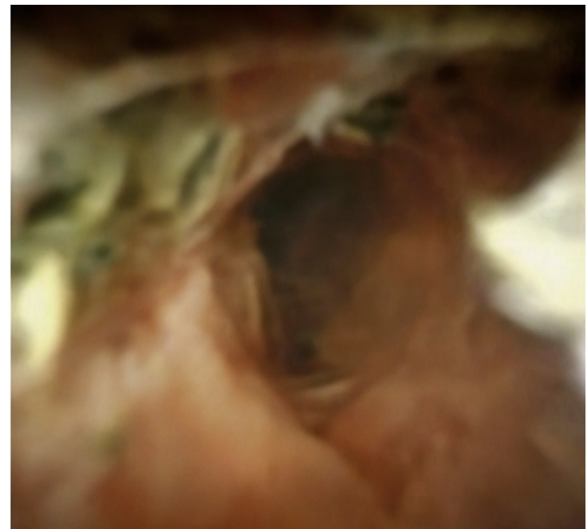**Figure 6.** Dominant stricture in the common hepatic duct in case number 4.

Case number 5 is a 28-year-old white woman with dominant strictures of the right hilum and mid-CBD requiring repeated balloon dilation who presented with mild cholangitis and worsening cholestasis (total bilirubin 3.6 mg/dL, ALP 281 U/L, AST 109 U/L, and ALT 138 U/L). CA 19-9 was <2.0 U/L (Video, Part 5 available online at [www.giejournal.org](http://www.giejournal.org)).

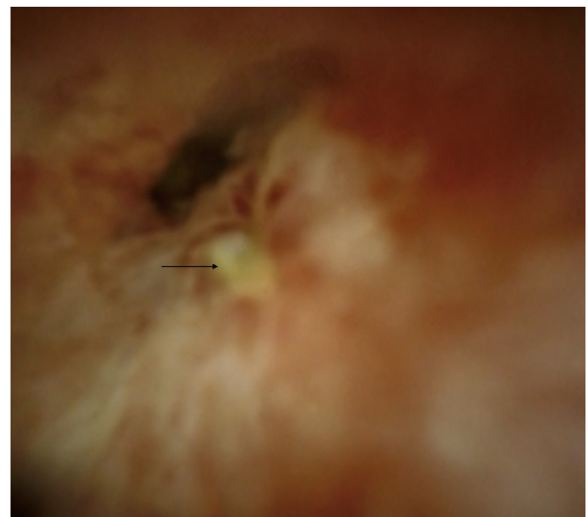Serial CT images over a decade showed persistent enhancement and chronic thickening of the extrahepatic duct wall progressing to pronounced segmental thickening of the mid-CBD in 2019. MRI showed mild narrowing of the common hepatic duct, with a stricture in the mid- to distal CBD.

The first cholangioscopy showed a small amount of pus and dominant stricture in the mid- to distal CBD, which could not be traversed with the cholangioscope. This stricture was dilated with a 6-mm balloon over a guidewire. Cholangioscopy after dilation showed mucosal trauma from the balloon dilation, mucosal erythema, and fine nodularity. Polypoid masses were noted in the CHD. Biopsy specimens of this area showed acute and chronic inflammation with ulceration. The hilum showed erythema and nodularity. The intrahepatic ducts could not be intubated because of severe inflammation and luminal narrowing. Cytology brushings and FISH analysis were negative for malignancy.

After 4 more ERCPs with balloon dilations of the dominant strictures in the CBD and the right hilum, the next cholangioscopy was performed 6 months later. The distal CBD stricture was persistent, but the cholangioscope could be maneuvered past it without the need for balloon dilation. A polypoid mobile mass was seen in the region of the CHD where multiple smaller polypoid growths had been seen previously. The mass felt soft and mobile to biopsy (Fig. 9). Histopathology of the mass revealed granulation tissue with acute and chronic inflammation,



**Figure 7.** Postdilation appearance of dominant stricture in the common hepatic duct with crushed pigmented stones along the duct wall in case number 4.

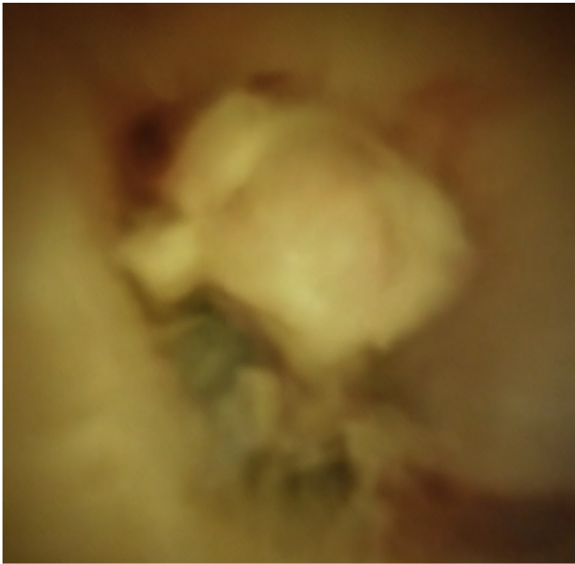


**Figure 8.** Ulcer with surrounding erythema in the common hepatic duct in case number 4.

but no malignancy. Biopsy specimens of the other areas of the extrahepatic duct and hilum showed acute and chronic inflammation.

Cholangioscopy was repeated at 2, 4, and 11 months and showed no change in the nature or size of the CHD mass, with biopsy specimens continuing to show acute inflammation without evidence of malignancy. Cytology and FISH analysis also showed no malignancy.

This patient did not respond to serial dilations or a trial of stent placement. Because of persistent right upper quadrant pain and cholestasis, she was referred for liver transplant evaluation.



**Figure 9.** Inflammatory mass in the common hepatic duct in case number 5.

## CONCLUSIONS

Cholangioscopy is safe and feasible in PSC. It can help in differentiating between benign and malignant features in PSC, especially when evaluating dominant strictures of the extrahepatic duct, based on a combination of characteristic morphologic features, targeted biopsy, brush cytology, and FISH analysis.

In this case series, we demonstrate the benign features of PSC, which can be broadly categorized as acute inflammation, chronic inflammation, and fibrostenosis (Fig. 10). This categorization of cholangioscopic findings is dynamic because 1 patient with chronic inflammation and fibrostenotic disease was noted to develop acute inflammatory changes. We also noted an overlap of acute and chronic inflammation in some patients. Acute cholangitis can be seen in all 3 categories but was more commonly noted in patients with fibrostenotic disease with pigmented stones proximal to the stricture.

An inflammatory mass formation was noted in 1 patient with persistent acute inflammation. This patient did not respond to serial dilations or a trial of stent placement and had persistent right upper quadrant pain and cholestasis. The patient was referred for liver transplant evaluation. An inflammatory mass can be differentiated from CCA based on its characteristics: It is soft and mobile and demonstrates stability of morphologic characteristics on serial examinations. Serial targeted biopsies should be obtained to rule out malignant transformation.

Some cases of dominant strictures in this case series required balloon dilation to facilitate cholangioscopic examination. No malignant features were noted in the dominant strictures, reiterating the fact that the majority of

dominant strictures do not harbor malignancy. Nevertheless, due diligence should be exercised in ruling out CCA by routinely obtaining targeted biopsies, cytology, and FISH evaluation.

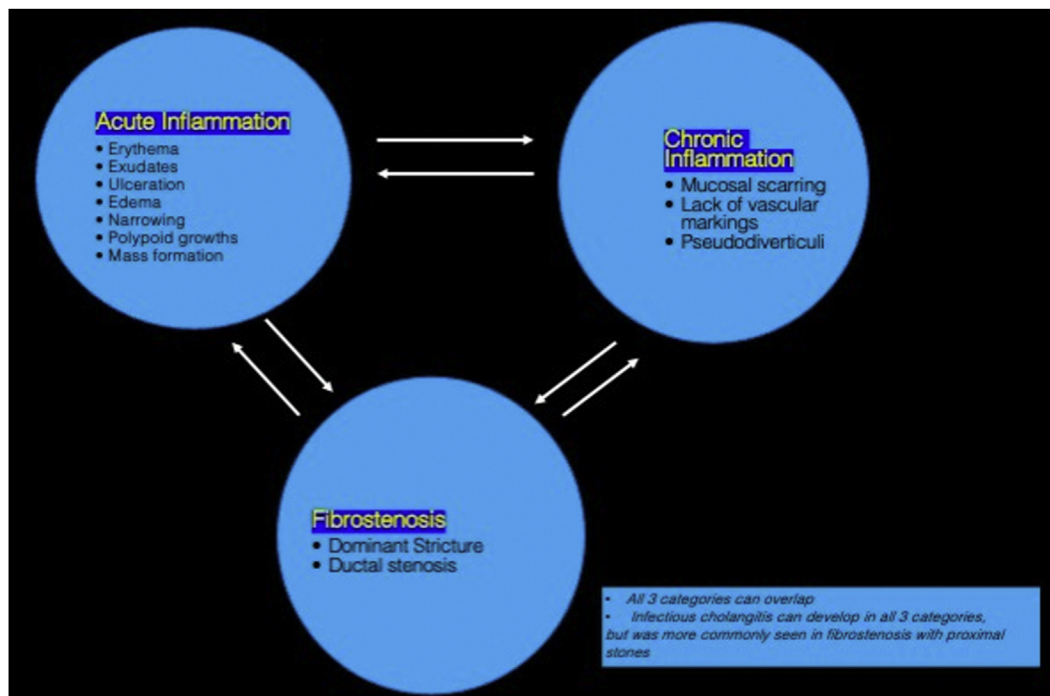
We also demonstrate the morphology of acute cholangitis, which needs to be differentiated from inflammatory exudates. Purulence is yellow and appears as long strands or plugs. It is viscous and not easily suctioned. Inflammatory exudate is whitish and scant in comparison, and it can be easily suctioned. It is our practice to minimize irrigation to the least possible amount in the setting of acute cholangitis to prevent worsening cholangitis. It is prudent to abort cholangioscopy in this setting and treat the cholangitis with antibiotics, unless the acute cholangitis is due to an obstructing pigmented stone that needs EHL clearance.

Pigmented stones can be encountered in PSC, especially proximal to dominant strictures. It is important to minimize irrigation of the duct, so as to not displace the stone(s) proximal to an inaccessible high-grade stricture.

Pigmented stones noted proximal to strictures in patients with prior sphincterotomies are most likely a consequence of biliary stasis and disruption of the sphincter of Oddi, leading to ascending cholangitis. A combination of balloon dilation and EHL, followed by balloon and basket sweeps, may be required to achieve stone clearance. In our practice, we perform cholangioscopy in PSC with saline solution irrigation in anticipation of the need for EHL. Incomplete stone clearance was one of the reasons we performed short-term stent placement in our case series. We chose 5F to 7F stents in our case series to reduce the likelihood of irritating the mucosa in an already inflamed duct, and we removed the stents within 1 to 2 weeks.

Based on this small study sample, we hypothesize that balloon dilation is less likely to be beneficial in patients with acute inflammatory narrowing of the hilum and the extrahepatic duct. Patients with persistent active inflammation not amenable to endoscopic intervention may benefit from a liver transplant evaluation when they have ongoing symptoms such as pruritus and recurrent cholangitis, or worsening cholestasis. Fibrostenotic disease responded well to balloon dilation. Therefore, accurate characterization of cholangioscopic findings as acute inflammation, chronic inflammation, or fibrostenotic disease can help tailor management in PSC without features concerning for malignancy.

The existing literature on cholangioscopy using the latest generation of cholangioscopes in PSC is sparse. We present one of the first video descriptions of the benign findings of PSC to complement our previous video description of cholangiocarcinoma and dominant strictures in PSC.<sup>4</sup> Sound knowledge of the morphologic characteristics of benign and malignant features is required when undertaking cholangioscopy in PSC. It is our hope that our video case series contributes toward



**Figure 10.** Proposed classification of endoscopic disease activity in PSC.

this goal. The newer-generation cholangioscope with superior image quality and maneuverability holds the promise of better endoscopic characterization of benign PSC to allow for tailored management and accurate differentiation of benign and malignant disease.

In conclusion, we summarize our experience by proposing the following steps to perform cholangioscopy safely and effectively in PSC:

1. Review cross-sectional imaging with an experienced radiologist prior to the ERCP with cholangioscopy in order to:
  - Create a roadmap.
  - Identify hilar and/or extrahepatic duct strictures needing balloon dilation.
  - Identify stones needing clearance in the hilum and/or extrahepatic duct.
  - Study the intrahepatic ductal anatomy. If the cholangiogram is of good quality, it can preclude contrast injection during ERCP and thereby reduce the risk of cholangitis.
2. Use normal saline solution for irrigation during cholangioscopy in anticipation of potential EHL.
3. Minimize irrigation of the duct to prevent severe cholangitis and proximal displacement of stones.
4. Evaluate for features of acute inflammation, chronic inflammation, and fibrostenosis, and categorize accordingly.
5. Consider obtaining intraductal biopsies for histologic confirmation of disease category.
6. When suspicious lesions are encountered, perform a thorough examination to establish a visual diagnosis. After this, obtain targeted biopsies of suspicious-appearing lesions, along with brushings for cytology and FISH analysis.
7. If pus is encountered, consider aborting the cholangioscopy and treat the cholangitis with antibiotics, unless the goal of the procedure is to clear impacted stones needing EHL.
  - Balloon dilation of stricture(s) should be performed as needed even if cholangioscopy is aborted, followed by tissue acquisition by cytology brushings. Additional brushings for FISH can improve diagnostic yield of strictures, and it is our practice to do so.
8. Administer prophylactic antibiotic for each procedure, and additionally consider a postprocedural course of antibiotic to prevent cholangitis.
9. If preprocedural cross-sectional imaging has not been performed or if the images are not available for review, the intrahepatic ducts may be opacified by contrast injection via the cholangioscope positioned at the CHD. This can be done after cholangioscopic examination of the extrahepatic duct.
10. If a stricture does not allow for safe passage of the cholangioscope, 4-mm balloon dilation is usually sufficient to accomplish this.
11. Administer rectal indomethacin for each procedure, unless contraindicated.

12. Follow the patient closely after cholangioscopy for any procedure-related adverse events such as cholangitis.

## DISCLOSURE

*All authors disclosed no financial relationships.*

*Abbreviations: ALP, alkaline phosphatase; ALT, alanine aminotransferase; AST, aspartate aminotransferase; CBD, common bile duct; CCA, cholangiocarcinoma; CHD, common hepatic duct; EHL, electrohydraulic lithotripsy; FISH, fluorescent in situ hybridization; LFTs, liver function tests; MRI, magnetic resonance imaging; PSC, primary sclerosing cholangitis.*

## REFERENCES

1. Aabakken L, Karlsen TH, Albert J, et al. Role of endoscopy in primary sclerosing cholangitis: European Society of Gastrointestinal Endoscopy (ESGE) and European Association for the Study of the Liver (EASL) clinical guideline. *Endoscopy* 2017;49:588-608.
2. Boonstra K, Weersma RK, van Erpecum KJ, et al. Population-based epidemiology, malignancy risk, and outcome of primary sclerosing cholangitis. *Hepatology* 2013;58:2045-55.
3. Yan S, Tejaswi S. Clinical impact of digital cholangioscopy in management of indeterminate biliary strictures and complex biliary stones: a single-center experience. *Ther Adv Gastrointest Endosc* 2019;12:2631774519853160.
4. Tejaswi S, Olson KA, Loehfelm T. Cholangioscopy in primary sclerosing cholangitis: a case series of dominant strictures and cholangiocarcinoma. *VideoGIE* 2021;6:277-81.
5. Fung BM, Fejleh MP, Tejaswi S, et al. Cholangioscopy and its role in primary sclerosing cholangitis. *Eur Med J Hepatol* 2020;8:42-53.
6. Heif M, Yen RD, Shah RJ. ERCP with probe-based confocal laser endomicroscopy for the evaluation of dominant biliary stenoses in primary sclerosing cholangitis. *Dig Dis Sci* 2013;58:2068-74.
7. Navaneethan U, Jegadeesan R, Nayak S, et al. ERCP-related adverse events in patients with primary sclerosing cholangitis. *Gastrointest Endosc* 2015;81:410-9.
8. Awadallah N, Chen YK, Priaka C, et al. Is there a role for cholangioscopy in patients with primary sclerosing cholangitis? *Am J Gastroenterol* 2006;101:284-91.
9. DeOliveira ML, Cunningham SC, Cameron JL, et al. Cholangiocarcinoma: thirty-one-year experience with 564 patients at a single institution. *Ann Surg* 2007;245:755-62.
10. Kaya M, Peterson BT, Angulo P, et al. Balloon dilation compared to stenting of dominant strictures in primary sclerosing cholangitis. *Am J Gastroenterol* 2001;96:1059-66.
11. Ponsioen CY, Lam K, van Milligen de Wit AW, et al. Four years experience with short-term stenting in primary sclerosing cholangitis. *Am J Gastroenterol* 1999;94:2403-7.

Division of Gastroenterology & Hepatology, University of California Davis School of Medicine, Sacramento, California (1), Department of Radiology, University of California Davis School of Medicine, Sacramento, California (2), Department of Pathology and Laboratory Medicine, University of California Davis School of Medicine, Sacramento, California (3).

If you would like to chat with an author of this article, you may contact Dr Tejaswi at [soorajt@gmail.com](mailto:soorajt@gmail.com).

Copyright © 2021 American Society for Gastrointestinal Endoscopy. Published by Elsevier Inc. This is an open access article under the CC BY-NC-ND license (<http://creativecommons.org/licenses/by-nc-nd/4.0/>).

<https://doi.org/10.1016/j.vgie.2021.05.008>

## Facebook

Follow *VideoGIE* on Facebook to receive the latest news, updates, and article links. Visit <https://www.facebook.com/videoiejournal/> and keep checking back to view our most recent posts.