

A Rare Case of Extensive Pemphigus Vegetans

Abstract

Pemphigus vegetans is a rare variant of pemphigus vulgaris characterized by pustules and/or papillomatous vegetations, preferentially affecting intertriginous and periorificial areas. It has two subtypes: Hallopeau variant and Neumann variant. Cerebriform tongue, a morphology with typical pattern of sulci and gyri over dorsum of the tongue, is a well-known sign in pemphigus vegetans. We are presenting an unusual case of pemphigus vegetans with extensive involvement of mucosae, trunk, extremities including both extensors and flexural areas with verrucous paronychia and fissured tongue. During clinical exam we recognized multiple cutaneous vesicles, erosions and ulcers on mucosal sites. Clinical, histopathological, and direct and indirect immunofluorescence findings were compatible with pemphigus vegetans. Patient had completed her family so treated with intravenous dexamethasone-cyclophosphamide pulse (DCP) regimen with excellent response.

Keywords: Extensor involvement, fissured tongue, paronychia, pemphigus vegetans, unusual presentation

Introduction

Pemphigus vegetans is the rarest form of pemphigus vulgaris comprising only 1%-2% of all cases and considered as a benign subset.^[1] It exhibits vesicles, bullae, pustules and erosions that consequently form vegetating masses particularly in the flexures. It has two subtypes: Neumann and Hallopeau variants. The former is a belligerent non-healing bullous disorder contradictory to self remitting benign variant of Hallopeau. These bullous and pustular variants described by Neumann and Hallopeau reflect the clinical spectrum of pemphigus vegetans itself.^[2] Hallopeau type, initially characterized by pustular lesions that, after rupturing, merge and gradually evolve into vegetating erosions. The disease typically affects the axilla, inframammary, inguinocrural, intergluteal folds, where semi-occlusion, maceration, and mixed infections continuously incite exudation and granulation tissue formation (wet pemphigus vegetans). In non-intertriginous locations, the vegetating buttons can dry out to change into warty, fissured, painful, seborrheic keratosis-like lesions (dry pemphigus vegetans).^[3] We herein report an unusual case of pemphigus vegetans which needs

documentation because of extensive involvement.

Case Report

A 30-year-aged Hindu female from the remote village of Himachal, hospitalized for painful oro-genital ulcerations with brownish black thick, raised itchy lesions over abdomen and back, limbs, axillae, groin and perianal region for past 2 years. The skin lesions started with itching followed by eruption of clear fluid filled blisters which used to rupture quickly and resulted into crusted erosions. Subsequently crusted lesions transformed into thick, elevated, moist vegetating masses in 2-3 weeks duration. Few areas revealed pustules in between verrucous plaques. She was treated with multiple courses of antibiotics, without much relief at peripheral health facilities. The lesions progressively increased in size and disseminated over trunk, extremities, perianal area as well as genital mucosa and digital involvement. Past history did not suggest sexually transmitted disease and drug rash or familial affliction.

Mucocutaneous examination revealed well-defined, multiple, skin colored to dark brown, elevated, indurated, plaques of variable size approximately 1 × 1 cm to 10 × 18 cm with verrucous, vegetating

This is an open access journal, and articles are distributed under the terms of the Creative Commons Attribution-NonCommercial-ShareAlike 4.0 License, which allows others to remix, tweak, and build upon the work non-commercially, as long as appropriate credit is given and the new creations are licensed under the identical terms.

For reprints contact: reprints@medknow.com

How to cite this article: Verma GK, Tegta GR, Sharma A, Kaur M, Sharma S. A rare case of extensive pemphigus vegetans. Indian Dermatol Online J 2020;11:87-90.

Received: February, 2019. **Revised:** April, 2019.

Accepted: April, 2019. **Published:** September, 2019.

Ghanshyam K. Verma,
Gita R. Tegta,
Anuj Sharma,
Mohitpreet Kaur,
Sudarshan Sharma¹

Departments of Dermatology,
Venereology and Leprosy and
¹Pathology, Indira Gandhi
Medical College, Shimla,
Himachal Pradesh, India

Address for correspondence:

Dr. Ghanshyam K. Verma,
Departments of Dermatology,
Venereology and Leprosy,
Indira Gandhi Medical
College, Shimla - 171 001,
Himachal Pradesh, India.
E-mail: drshyamverma77@
gmail.com

Access this article online

Website: www.idoj.in

DOI: 10.4103/idoj.IDOJ_83_19

Quick Response Code:



moist surface over abdomen [Figure 1a], inframammary region, back, [Figure 1b] both arms [Figure 2], axillae, perianal area [Figure 3a], third and fourth digits of right hand [Figure 3b], groin, thighs [Figure 4]. Some plaques were of annular in shape with central clearing. Lesions over labia majora and perianal region showed evidence of fissuring and oozing. Few vesicular lesions and erosions were present over upper back.

Palate, tongue and gingivae revealed multiple painful erosion and ulcers with erythematous base and regular margins. Tongue was fissured and cerebriform [Figure 5]. Genital mucosa also revealed multiple erosions. Nasal and ocular mucosae were spared.

Subungual hyperkeratosis, discolored and thin nail plate with verrucous paronychia and flaccid bullae on third and fourth digits were also seen.

General physical and systemic examination revealed nothing abnormal.

Complete blood count demonstrated peripheral eosinophilia (25%), ESR and C-reactive protein levels

were normal. KOH examination of exudate, urine, stool analysis, X-ray chest and thyroid function tests did not reveal any abnormality. HIV serology and VDRL tests were non-reactive. Nicolsky's sign was positive over trunk. Tzanck smear showed acantholytic cells and eosinophils. Gram staining of exudate revealed mixed infiltrate predominantly eosinophils with no bacteria and staining for acid bacilli was negative. Direct immunofluorescence revealed intercellular immunoglobulin G (IgG) deposits in epidermis [Figure 6]. Indirect immunofluorescence revealed IgG autoantibodies directed against desmoglein (Dsg) 3.

Histopathological examination showed stratified squamous epithelium with marked hyperkeratosis, mild acanthosis, papillomatosis, spongiosis with vacuolar degeneration of basal layer and focal supra-basal cleft formation [Figure 7] with acantholytic cells and eosinophilic exocytosis. Dermis revealed mild focal perivascular lymphocytic infiltrate mixed with eosinophils.

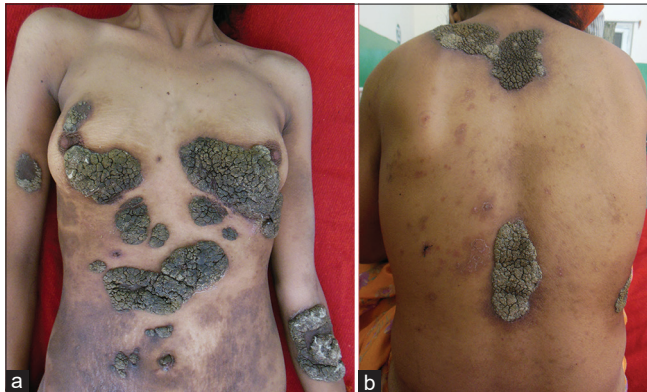


Figure 1: (a, b) hyperkeratotic verrucous, vegetating plaques over (a) abdomen and (b) back

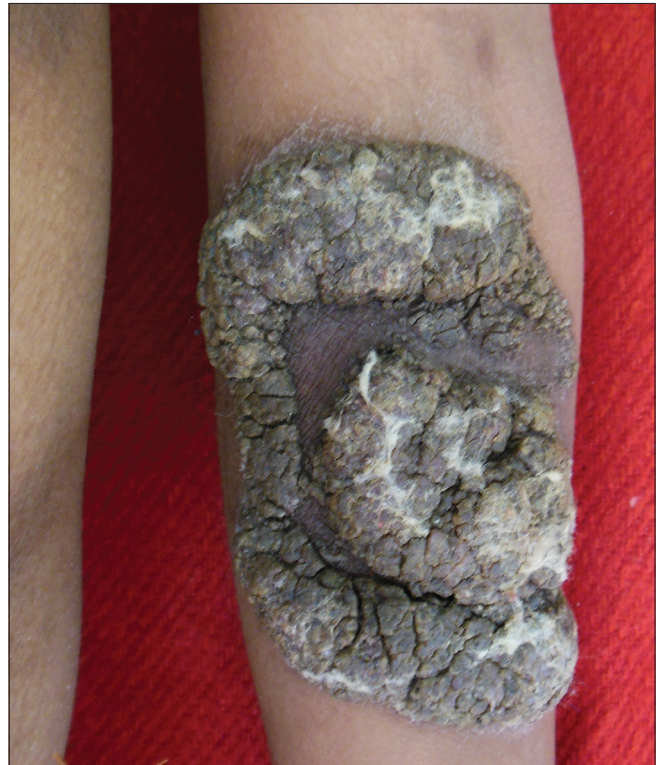

Figure 2: Large annular hyperkeratotic verrucous plaque over forearm

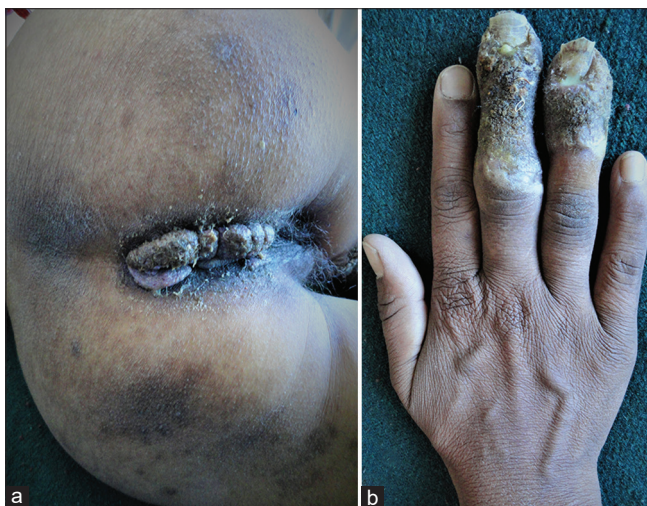

Figure 3: (a) Vegetative hyperkeratotic verrucous plaque over perianal area (b) paronychia of third and fourth digits

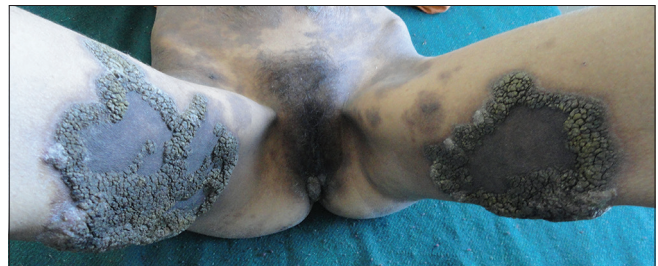

Figure 4: Perineal involvement with vegetative hyperkeratotic verrucous plaque over thighs

The investigations associated with the patient's clinical profile confirmed the diagnosis of pemphigus vegetans Neumann type. She was treated with intravenous dexamethasone-cyclophosphamide pulse (DCP) as the patient had completed her family of two children, consisting of 100 mg dexamethasone with 500 mg of cyclophosphamide on day 2 along with topical clobetasol ointment. The pulse therapy was repeated at 4 weeks intervals. In the intervening period, patient was given daily oral cyclophosphamide 50 mg. After two DCP pulses, patient had significant regression of lesions. Complete

clearance with residual hyperpigmentation was achieved after five DCP pulses [Figure 8]. DCP was continued for nine pulses but now she is lost to follow up.

Discussion

Pemphigus vegetans is a rare skin disease, speculated to be a reactive pattern of skin to an autoimmune insult of

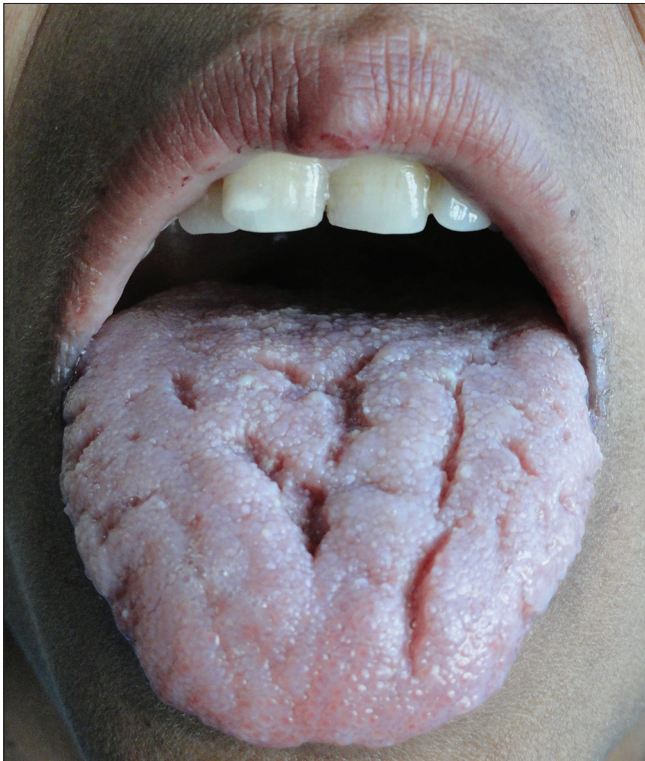

Figure 5: Fissured tongue

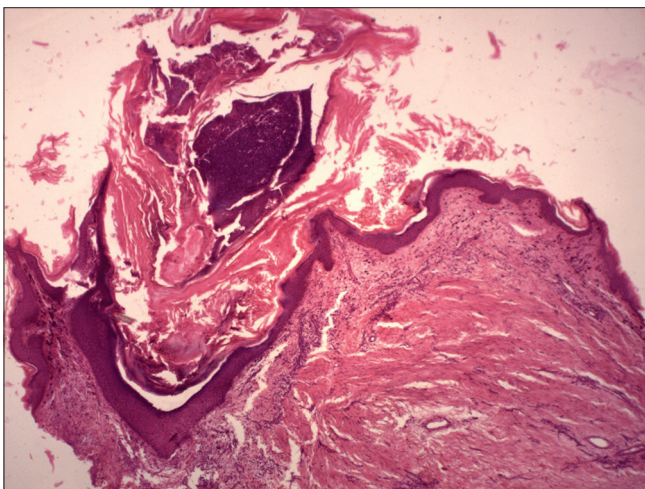


Figure 7: Hyperkeratosis, mild acanthosis, papillomatosis, spongiosis, focal supra-basal cleft formation with acantholytic cells (H and E stain $\times 10$)

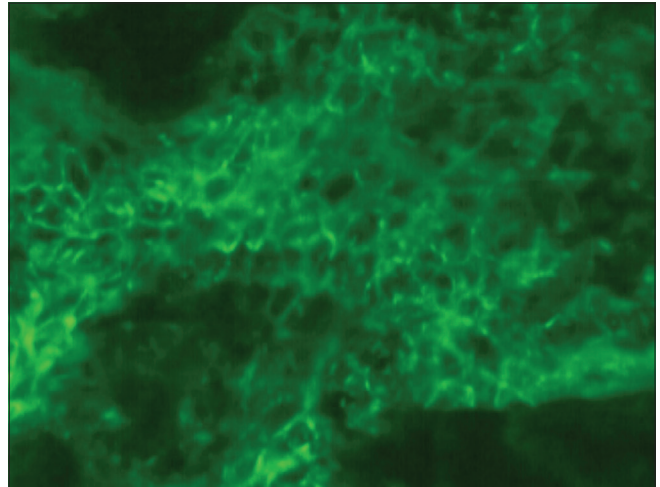


Figure 6: Direct immunofluorescence with fishnet pattern intercellular immunoglobulin G (IgG) deposits in epidermis

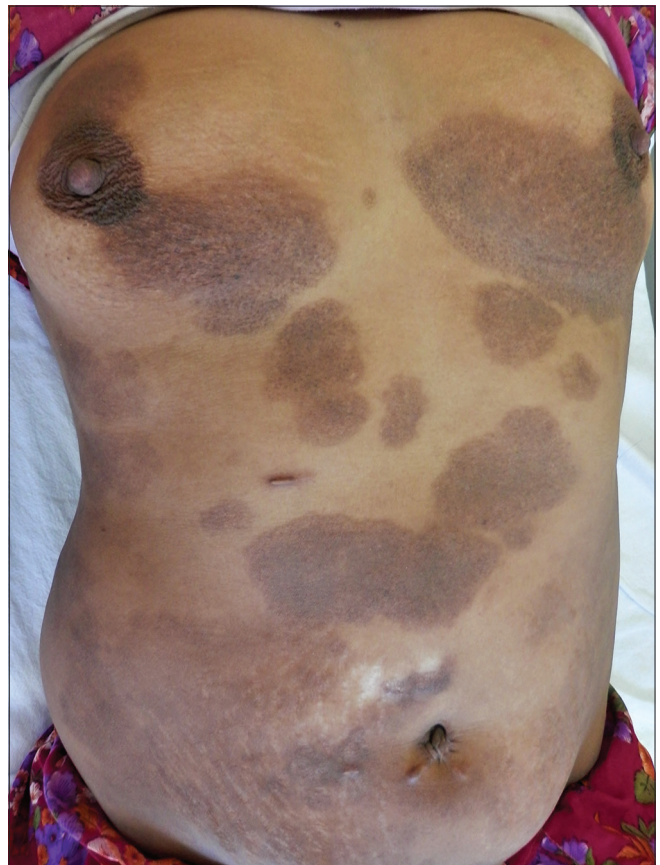

Figure 8: Complete clearance of lesions with residual hyperpigmentation achieved after five DCP pulses

pemphigus vulgaris.^[4] It is clinically characterized by vesicles, erosions results in thick hyperkeratotic masses especially in the intertriginous regions with involvement of oral mucosa invariably.^[5] It was first described by Neumann in 1876. Literature describes two subtypes: the Neumann type and the Hallopeau type. Neumann type has clinically unremitting and prolonged course, responding less to therapy. The skin lesions are vesicles, bullae forming vegetating masses studded with pustules along with oral erosions. Verrucous masses limited to the oral cavity followed by a rapid spread to the lips with only symptom of burning and itching have been reported.^[6] In rare instances, the lesions over tongue may persist for years and without recurrence of lesions on any part of the body.^[7] The Hallopeau is a milder form beginning with pustules and ultimately forming vegetating plaques.^[8] It may have spontaneous remission. Ulcerative patches around the mouth that gradually extended into his nose with scattered patches over the scalp and glans penis with oozing of pus, are also reported as unusual presentations.^[9] Cases have been described with lesions over lips, tongue, nose, nail folds, feet, perianal region and groin.^[2,6-8,10] Cerebriform tongue also seen in the present case has been quoted as an eponymous sign, a clinical sign or a clue for pemphigus vegetans in cases of bullous dermatoses of flexures.^[11]

The standard treatment of this disease is with systemic steroids in the form of oral prednisolone or injectable dexamethasone on daily basis or DCP therapy.^[1,5,9]

Our patient had most of the lesions over the extensors rather than flexures which were different from the usual presentation. To the best of our knowledge to date no such case with an extensive involvement had been described with excellent response to DCP regimen.

Declaration of patient consent

The authors certify that they have obtained all appropriate patient consent forms. In the form the patient(s) has/have given his/her/their consent for his/her/their images and

other clinical information to be reported in the journal. The patients understand that their names and initials will not be published and due efforts will be made to conceal their identity, but anonymity cannot be guaranteed.

Financial support and sponsorship

Nil.

Conflicts of interest

There are no conflicts of interest.

References

1. Jain VK, Jindal N, Imchen S. Localised pemphigus vegetans without mucosal involvement. *Indian J Dermatol* 2014;59:210.
2. Downie JB, Dicostanzo DP, Cohen SR. Pemphigus vegetans-Neumann variant associated with intranasal heroin abuse. *J Am Acad Dermatol* 1998;39:872-5.
3. Ruocco V, Ruocco E, Caccavale S, Gambardella A, Lo Schiavo A. Pemphigus vegetans of the folds (intertriginous areas). *Clin Dermatol* 2015;33:471-6.
4. Nanda S, Grover C, Garg VK, Reddy BS. Pemphigus vegetans of Hallopeau. *Indian J Dermatol* 2005;50:166-7.
5. Augusto de Oliveira M, Martins E, Martins F, Lourenço S, Gallottini M, Ortega KL. Oral pemphigus vegetans: A case report. *Dermatol Online J* 2012;18:10.
6. Woo TY, Solomon AR, Fairley JA. Pemphigus vegetans limited to the lips and oral mucosa. *Arch Dermatol* 1985;121:271-2.
7. Bhargava P, Kuldeep CM, Mathur NK. Isolated pemphigus vegetans of the tongue. *Indian J Dermatol Venereol Leprol* 2001;67:267.
8. Almeida HL Jr, Neugebauer MG, Guarenti IM, Aoki V. Pemphigus vegetans associated with verrucous lesions: Expanding a phenotype. *Clinics* 2006;61:279-82.
9. Dhamija A, D'souza P, Meherda A, Kothiwala RK. Pemphigus vegetans: An unusual presentation. *Indian Dermatol Online J* 2012;3:193-5.
10. Ma DL, Fang K. Hallopeau type of pemphigus vegetans confined to the right foot: Case report. *Chin Med J* 2009;122:588-90.
11. Premalatha S, Jayakumar S, Yesudian P, Thambiah AS. Cerebriform tongue: A clinical sign in pemphigus vegetans. *Br J Dermatol* 1981;104:587-91.