



Pseudoangiomatous stromal hyperplasia causing massive unilateral breast enlargement—a case report

Arjuna Brodie, Ahmed Elatawy, Kelly Lambert

Department of Breast Surgery, University Hospitals of Leicester, Leicester, UK

Correspondence to: Arjuna Brodie. Department of Breast Surgery, University Hospitals of Leicester, Leicester, UK. Email: arjuna.brodie@nhs.net.

Background: Pseudoangiomatous stromal hyperplasia (PASH) is an uncommon mesenchymal benign breast neoplasm. PASH may present as a rapidly growing mass in pre-menopausal women. It is important to rule out other causes of a breast lump including fibroadenoma, hamartoma, phyllodes tumour and invasive adenocarcinoma. To our knowledge this is the largest case of PASH tumour in the English literature and the first to be managed with mastectomy and immediate breast implant reconstruction.

Case Description: A 45-year-old woman with a history of bilateral breast augmentation for cosmesis and no other co-morbidities, presented with gross asymmetry between her right and left breasts on 13th December 2020. She complained about pain and the noticeable difference in clothing. She underwent triple assessment (history and examination, imaging, and biopsy). Bilateral mammograms showed the right breast had a possible mass. On ultrasound imaging there was evidence of extensive ill-defined hypoechoic changes. Core biopsies and a vacuum assisted core biopsy were taken from the mass and came back as PASH/fibrocystic change on 12th January 2021. Surgical options were discussed, and after some consideration she decided on mastectomy and immediate implant reconstruction on 15th March 2021. She underwent the operation on 9th September 2021 and the specimen weight was 1.911 kg and measured 27 cm × 22.6 cm × 7.4 cm which is the largest reported PASH tumour. She made an uncomplicated recovery and was seen in clinic 4 weeks later and was happy with the cosmetic outcome. PASH can present as incidental microscopic foci in biopsies to diffuse enlargement of the breast. PASH has no specific radiological or diagnostic features, therefore is diagnosed based on histology. PASH is not associated with an increased risk of malignancy and the management is dependent on the presentation. When PASH is discovered incidentally or is asymptomatic it can be followed up with serial mammography to assess growth. If there are any suspicious features or discordance following triple assessment or symptoms such as discomfort surgical excision is indicated.

Conclusions: PASH should be considered as part of the differential diagnosis for rapid breast enlargement. Treatment options should be discussed early with the patient to prevent progression. For rapid breast enlargement mastectomy and immediate reconstruction should be considered and discussed with the patient.

Keywords: Pseudoangiomatous stromal hyperplasia (PASH); breast tumour; mastectomy; case report

Received: 09 December 2021; Accepted: 14 February 2022; Published: 30 April 2022.

doi: 10.21037/tbcr-21-37

View this article at: <https://dx.doi.org/10.21037/tbcr-21-37>

Introduction

Pseudoangiomatous stromal hyperplasia (PASH) is an uncommon mesenchymal benign breast neoplasm (1). It was first studied by Vuitch *et al.* in 1986 in 9 patients who presented with palpable, grossly circumscribed, non-haemorrhagic breast masses (2). On histological examination,

the masses were composed of mammary stromal proliferations with complex anastomosing channels lined with slender spindle cells stimulating vascular channels (3). Therefore, the histological appearance resembles, without constituting, an angiomatous proliferation (3). Vuitch *et al.* highlighted the importance of distinguishing this

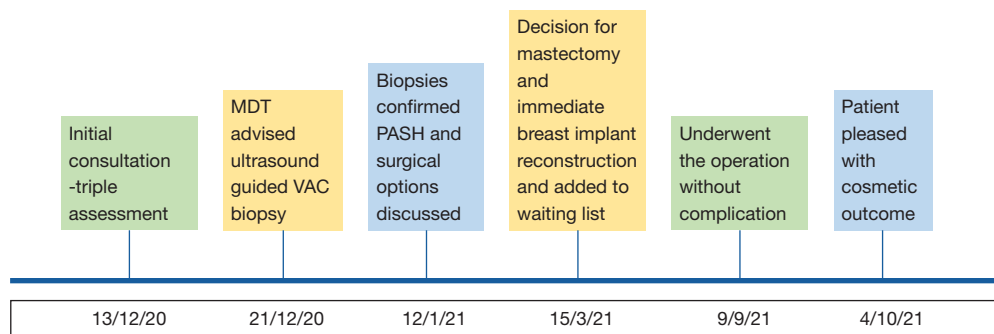


Figure 1 Timeline of events from second presentation to breast care services in 2020 to post-operative clinic appointment. MDT, multidisciplinary team meeting; VAC biopsy, vacuum assisted core biopsy; PASH, pseudoangiomatous stromal hyperplasia.

benign lesion from other vascular lesions such as low grade angiosarcoma (2). PASH may also present as a rapidly growing, rubbery, single, mobile mass in pre-menopausal women and as a result is most frequently misdiagnosed as a fibroadenoma (3,4). It is important to rule out other benign and malignant causes of a breast lump including hamartoma, phyllodes tumour and invasive adenocarcinoma (3-5).

Whilst PASH is relatively uncommon with less than 200 cases documented in the English literature (3). It can be found incidentally at biopsy for other breast lesions, with a reported incidence of 23% of 200 breast specimens resected for various benign or malignant conditions and in 24-47% of men with gynecomastia (3,6).

PASH usually presents in women between 30 and 40 years of age, although the reported age range is 14-86 years old (1,3). Masses vary in size with diameters usually ranging between 1-12 cm, with the largest reported case being 20 cm × 23 cm (3,7). We report a case of a 45-year-old woman who presented with asymmetrical, gross enlargement of her right breast and had a histological confirmed diagnosis of PASH. Discussions were had with the patient regarding the need for surgical intervention as well as the different surgical interventions available. The patient subsequently opted for right breast mastectomy with immediate breast implant reconstruction. Previous case reports have described predominantly excision biopsy as surgical treatment options for PASH with some reporting mastectomy, but there is a paucity on data regarding mastectomy and immediate breast implant reconstruction for PASH (3-6,8). Powell *et al.* described 40 cases of PASH seen in women with the majority being treated with excisional biopsy and one woman requiring bilateral mastectomies (9). Bowman *et al.* similarly described 24 cases of PASH retrospectively with the patients treated

with excision biopsy or observational surveillance (10). Our case highlights mastectomy and immediate breast implant reconstruction, which is usually reserved for malignant breast cancer, as being a suitable treatment option to treat PASH which is a benign tumour. We present the following case in accordance with the CARE reporting checklist (available at <https://tbc.amegroups.com/article/view/10.21037/tbc-21-37/rc>).

Case presentation

A 45-year-old woman first presented to breast care services via a general practitioner (GP) referral complaining of breast asymmetry in 2014. She had a history of bilateral breast augmentation in 2011 for cosmesis and no other significant past medical history. At that time, she was seen by a consultant breast surgeon who took a detailed history and examination and requested imaging including mammography and ultrasound of both breasts. The patient likely had a degree of asymmetry prior to her breast augmentation and that this was a long-standing issue. This was based on the history given by the patient and that her right breast implant was smaller than her left on mammography. This was most likely because of her previous plastic surgeon attempting to correct the asymmetry with breast implants. The consultant breast surgeon was satisfied there was no evidence of breast abnormality on examination and her implants looked intact on imaging. Therefore, she was discharged from the breast clinic and advised if unhappy with the cosmetic outcome of her previous breast augmentation to seek advice from her plastic surgeon.

The patient later presented to breast care services on 13th December 2020 due to gross asymmetry between her right and left breasts (see *Figure 1* for a timeline). The patient

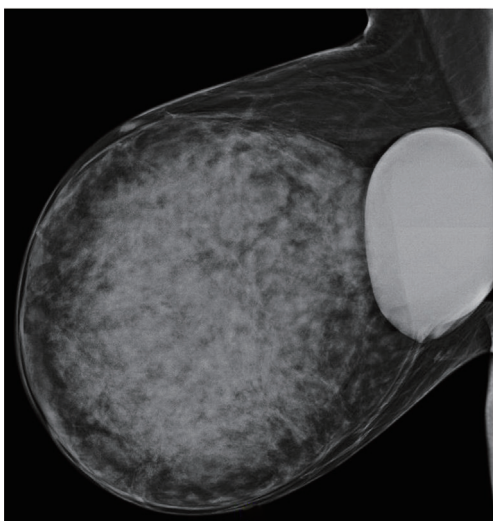

Figure 2 Right breast mammogram, mediolateral oblique view, showing implant and large PASH lesion. PASH, pseudoangiomatous stromal hyperplasia.

explained over the preceding 6 months her right breast had dramatically increased in size and was painful and heavy. In addition, there was a noticeable difference in size between her breasts when wearing clothing. The patient particularly mentioned it made it difficult for her to wear suitable clothing for the gym for which she used to be a regular attendee. Patient was seen by a consultant breast surgeon and underwent triple assessment (history and examination, imaging and biopsy). All procedures performed in this study were in accordance with the ethical standards of the institutional and/or national research committee(s) and with the Helsinki Declaration (as revised in 2013). Written informed consent was obtained from the patient for publication of this case report and accompanying images. A copy of the written consent is available for review by the editorial office of this journal.

Imaging

Bilateral mammograms were done and compared with the previous 2014 films. These showed long standing gross asymmetry of the glandular tissue with the right breast showing a possible mass. The right implant was again noted to be smaller than the left and there was no obvious evidence of implant rupture (see *Figure 2*).

On ultrasound imaging of the right breast the implant appeared intact. There was evidence of extensive ill-defined

hypoechoic changes seen in the right upper midline. Calcifications were noted in this area with evidence of some related variable size cystic changes. Similar changes were noted in the right lower midline (U=4). The ultrasound appearance was suspicious.

Histology

Patient initially had two core biopsies from her right breast with one biopsy from the upper midline showing PASH and the other from the lower inner quadrant within normal limits. Therefore, she was discussed at multidisciplinary team meeting (MDT) on 21st December 2020 and decision made for ultrasound guided vacuum assisted core biopsy for a larger tissue sample from the upper midline. This biopsy also came back as PASH/fibrocystic change. She was again discussed at the MDT who were satisfied that representative sampling had been achieved and no further sampling was needed. The MDT also agreed with the patient that surgery to correct the asymmetry was warranted.

Management

The patient was seen in clinic on 12th January 2021 and informed of the biopsy results and surgical options were discussed including breast reduction surgery as well as skin sparing or skin reducing mastectomy and to upsize her breast implant to fill the gap. The risks of breast implants were also discussed with the patient including encapsulation, rupture and implant associated lymphoma. It was also explained, if the patient opted for breast reduction surgery there was the possibility the PASH could regrow and she may need further surgery. The patient wanted time to consider these options and was seen back in clinic on 15th March 2021. Over this time the right breast had continued to grow with a mid-clavicle to nipple distance of 36 cm on the right and 26 cm on the left and a breast width of 26 cm on the right and 18 cm on the left. The heaviness of the right breast and the effects on the skin were making surgery more urgent and because of the progression in the changes, mastectomy and implant reconstruction was deemed her best option and she was added to the waiting list. However, due to the COVID-19 pandemic and its impact on surgical provision there were issues with booking a reconstructive case as cancer cases were prioritised. Therefore, it was on 9th September 2021 she underwent a right breast mastectomy and immediate implant reconstruction with biomesh (see *Figures 3-6*). The surgery went as planned and there were

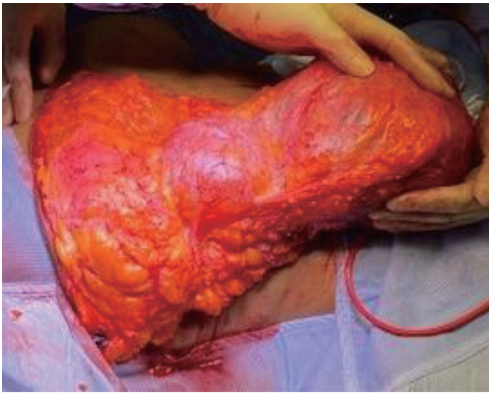


Figure 3 Intraoperative picture showing the PASH tumour on the right and the original breast implant centrally. PASH, pseudoangiomatous stromal hyperplasia.

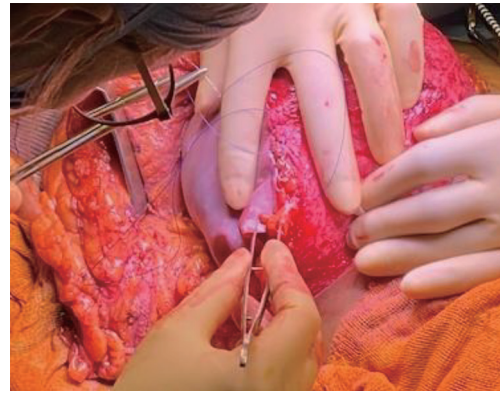

Figure 5 Intraoperative picture of the implant with the biomesh.

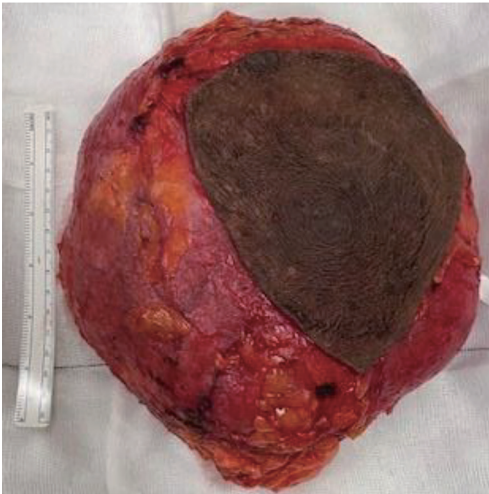

Figure 4 Picture of the excised PASH tumour with a 15-cm ruler as a reference. PASH, pseudoangiomatous stromal hyperplasia.

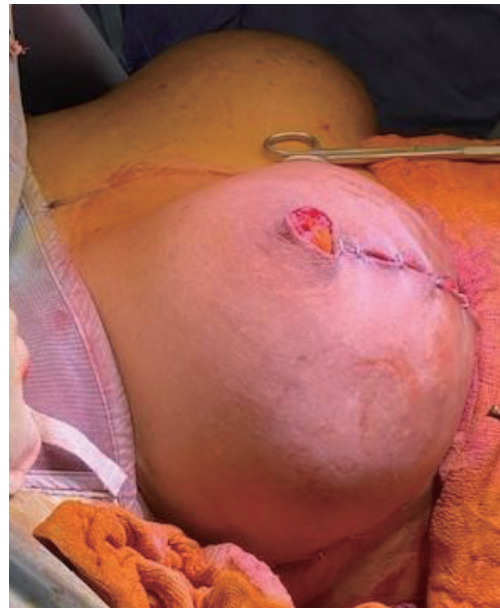

Figure 6 Skin closed with wound clips with implant in place. The size is very similar on the right as the left.

no adverse or unanticipated events. The specimen weight of the mastectomy was 1.911 kg and she had a 650 cc gel breast implant. The right mastectomy specimen comprised fibrofatty tissue measuring 27 cm × 22.6 cm × 7.4 cm and the histology revealed that most of the tumour was benign PASH with some fat necrosis but no atypia seen. To our knowledge this is the largest reported PASH tumour in the English literature. The patient made a good recovery post-surgery and was discharged the following day from hospital. At her follow up clinic appointment 4 weeks after the operation, her wounds had healed well and there had

been no complications. The patient was very pleased with the symmetry of her two breasts and the cosmetic outcome of the surgery, and this allowed her to regain confidence in her appearance and clothing choices. The next step will be to undergo nipple reconstruction.

Discussion

PASH is a benign proliferation of the mammary stromal tissue. This lesion is characterised by complex inter-anastomosing slit like spaces which are lined by spindle

cells in the breast parenchyma (4,8). PASH has a broad clinicopathological spectrum from incidental microscopic foci in breast biopsies to diffuse enlargement of the breast (5). This case demonstrates the massive breast enlargement PASH can cause and therefore, the need to make a prompt diagnosis and treatment options. In this case, the patient noted significant breast enlargement in a short period of time which influenced the treatment options available to her.

It is uncommon for PASH to present as a discrete palpable breast lump and is more often identified incidentally on breast biopsy (3,4,6). However, clinically PASH can present as a solitary firm, mobile, palpable lump (4). It is important to correctly identify PASH as it can be misdiagnosed as other benign tumours such as fibroadenoma or phyllodes tumour and must be differentiated from angiosarcoma which is a malignant tumour (2,4). Making the correct diagnosis promptly will mean there are no delays if treatment is required.

There are suggestions that there is a hormonal component related to PASH. Multiple studies have reported the stromal cells in PASH tumours to be positive for progesterone receptor (5,9-12).

PASH has no radiological specific or diagnostic features (13). On mammography the most common finding is a well-defined, uncalcified mass with regular borders (4,13). Similar in appearance to a fibroadenoma or hamartoma (14). On ultrasound PASH usually shows as a hypoechoic discrete mass with benign features (13).

Definitive diagnosis of PASH is therefore based on histology. Cytology is non-specific so core biopsy is required for pre-operative diagnosis or in some instances the final diagnosis is only made after excision biopsy (7). On histology PASH can be differentiated from angiosarcoma by its lack of invasive features, necrosis, atypia or mitoses, and negative staining for endothelial immunomarkers (e.g., CD31) (2-5).

PASH is not associated with an increased risk of malignancy and the management is dependent on the presentation (15). When PASH is discovered incidentally or is asymptomatic and the diagnosis is confirmed histologically, close surveillance is not necessarily needed but it can be followed up with serial mammography to assess interval growth (4,10,14). If there are any suspicious features or discordance following triple assessment surgical excision is indicated (3-5,8). In addition, tumours which are symptomatic or rapidly enlarging or patients choice should also be considered for surgical excision (4,5,8). For large PASH tumours mastectomy may be required, such as in this reported case (8). The recurrence rates of PASH after excision are reported to range from

15% to 22% (3). The main reasons for recurrence are due to incomplete excision, multiple lesions that were not all excised, or new growth of PASH (3).

As already mentioned, the number of cases reported in the literature regarding palpable tumour forming PASH is low. To our knowledge this is the largest reported case of PASH (27 cm × 22.6 cm × 7.4 cm). There are also no reported cases of PASH resulting in mastectomy with immediate breast implant reconstruction. Therefore, our case shows that this a viable treatment option and should be discussed with the patient. However, the limitation of this report is that this is an exceptional case whereby the patient experienced massive enlargement of her breast over a relatively short period of time. More data is required regarding patients with a PASH tumour and the rate of growth over time to aid decision making on the best treatment options.

Conclusions

The fact PASH does not have any clinical or radiological identifiable features unique to itself makes the diagnosis more challenging. Therefore, it is important to consider PASH as one of the differentials for a palpable breast lump and should be one of the top differentials as a cause for rapid single breast enlargement. Given imaging characteristics are not specific the diagnosis must be made histologically. Confirmation of diagnosis is only made if there is concordance with the results of the triple assessment. The management options include close imaging surveillance if required for small asymptomatic tumours to mastectomy for large symptomatic tumours. In this case we have reported PASH causing massive breast enlargement requiring mastectomy and immediate breast reconstruction. Though PASH is not associated with increased risk of malignancy the symptoms of pain and heaviness caused by the enlarged breast as well as the cosmetic asymmetry warranted such a radical treatment option. It is important to note from this case the rapid progression of the breast enlargement the patient noticed. This meant surgical intervention became more pressing and limited the treatment options suitable for this patient. Therefore, in similar instances treatment should not be delayed and the option of mastectomy and immediate breast implant reconstruction should be discussed with the patient.

Acknowledgments

Funding: None.

Footnote

Reporting Checklist: The authors have completed the CARE reporting checklist (available at <https://tbc.amegroups.com/article/view/10.21037/tbc-21-37/rc>).

Conflicts of Interest: All authors have completed the ICMJE uniform disclosure form (available at <https://tbc.amegroups.com/article/view/10.21037/tbc-21-37/coif>). The authors have no conflicts of interest to declare.

Ethical Statement: The authors are accountable for all aspects of the work in ensuring that questions related to the accuracy or integrity of any part of the work are appropriately investigated and resolved. All procedures performed in this study were in accordance with the ethical standards of the institutional and/or national research committee(s) and with the Helsinki Declaration (as revised in 2013). Written informed consent was obtained from the patient for publication of this case report and accompanying images. A copy of the written consent is available for review by the editorial office of this journal.

Open Access Statement: This is an Open Access article distributed in accordance with the Creative Commons Attribution-NonCommercial-NoDerivs 4.0 International License (CC BY-NC-ND 4.0), which permits the non-commercial replication and distribution of the article with the strict proviso that no changes or edits are made and the original work is properly cited (including links to both the formal publication through the relevant DOI and the license). See: <https://creativecommons.org/licenses/by-nc-nd/4.0/>.

References

1. Testori A, Alloisio M, Errico V, et al. Pseudoangiomatous stromal hyperplasia - a benign and rare tumor of the breast in an adolescent: a case report. *J Med Case Rep* 2017;11:284.
2. Vuitch MF, Rosen PP, Erlandson RA. Pseudoangiomatous hyperplasia of mammary stroma. *Hum Pathol* 1986;17:185-91.
3. Jaunoo SS, Thrush S, Dunn P. Pseudoangiomatous stromal hyperplasia (PASH): a brief review. *Int J Surg* 2011;9:20-2.
4. Vo QD, Koch G, Girard JM, et al. A Case Report: Pseudoangiomatous Stromal Hyperplasia Tumor Presenting as a Palpable Mass. *Front Surg* 2015;2:73.
5. Bourke AG, Tiang S, Harvey N, et al. Pseudoangiomatous stromal hyperplasia causing massive breast enlargement. *BMJ Case Rep* 2015;2015:bcr2014204343.
6. Estes A, Cao L, Miller ME. Pseudoangiomatous stromal hyperplasia: overview and clinical management. *Ann Breast Surg* 2020;4:22.
7. Sasaki Y, Kamata S, Saito K, et al. Pseudoangiomatous stromal hyperplasia (PASH) of the mammary gland: report of a case. *Surg Today* 2008;38:340-3.
8. Masannat YA, Whitehead S, Hawley I, et al. Pseudoangiomatous stromal hyperplasia: a case report. *Case Rep Med* 2010;2010:549643.
9. Powell CM, Cranor ML, Rosen PP. Pseudoangiomatous stromal hyperplasia (PASH). A mammary stromal tumor with myofibroblastic differentiation. *Am J Surg Pathol* 1995;19:270-7.
10. Bowman E, Oprea G, Okoli J, et al. Pseudoangiomatous stromal hyperplasia (PASH) of the breast: a series of 24 patients. *Breast J* 2012;18:242-7.
11. Ibrahim RE, Sciotto CG, Weidner N. Pseudoangiomatous hyperplasia of mammary stroma. Some observations regarding its clinicopathologic spectrum. *Cancer* 1989;63:1154-60.
12. Anderson C, Ricci A Jr, Pedersen CA, et al. Immunocytochemical analysis of estrogen and progesterone receptors in benign stromal lesions of the breast. Evidence for hormonal etiology in pseudoangiomatous hyperplasia of mammary stroma. *Am J Surg Pathol* 1991;15:145-9.
13. Cohen MA, Morris EA, Rosen PP, et al. Pseudoangiomatous stromal hyperplasia: mammographic, sonographic, and clinical patterns. *Radiology* 1996;198:117-20.
14. Ferreira M, Albarracin CT, Resetskova E. Pseudoangiomatous stromal hyperplasia tumor: a clinical, radiologic and pathologic study of 26 cases. *Mod Pathol* 2008;21:201-7.
15. Degnim AC, Frost MH, Radisky DC, et al. Pseudoangiomatous stromal hyperplasia and breast cancer risk. *Ann Surg Oncol* 2010;17:3269-77.

doi: 10.21037/tbc-21-37

Cite this article as: Brodie A, Eltatawy A, Lambert K. Pseudoangiomatous stromal hyperplasia causing massive unilateral breast enlargement—a case report. *Transl Breast Cancer Res* 2022;3:19.