



Received: 2015.08.16  
Accepted: 2016.04.24  
Published: 2016.11.07

**Authors' Contribution:**

- A** Study Design
- B** Data Collection
- C** Statistical Analysis
- D** Data Interpretation
- E** Manuscript Preparation
- F** Literature Search
- G** Funds Collection

## The Slowly Enlarging Ventriculus Terminalis

Joel Woodley-Cook<sup>1</sup>, Magdalena Konieczny<sup>1</sup>, Julian Spears<sup>2</sup>

<sup>1</sup> Department of Diagnostic Imaging, The Scarborough Hospital, Scarborough, ON, Canada

<sup>2</sup> Department of Neurosurgery, St. Michael's Hospital, Toronto, ON, Canada

**Author's address:** Joel Woodley-Cook, Department of Diagnostic Imaging, The Scarborough Hospital, Scarborough, ON, Canada, e-mail: jwoodleycook@gmail.com

**Background:**

A cerebral spinal fluid (CSF) cavity within the conus medullaris has been described by the term *ventriculus terminalis* (VT) or *the fifth ventricle*. The finding of a VT on MRI imaging of the lumbar spine is often incidental but may be found in patients with low back pain or neuromuscular deficits. These lesions, when identified, are thought to regress or remain stable in terms of size, although some have been described to enlarge in the presence of post-traumatic meningeal hemorrhages or deformities of the vertebral canal.

**Case Report:**

We describe a case of a slowly growing VT in a patient with progressing lower limb weakness without any history or imaging findings of trauma or spinal canal abnormalities.

**Conclusions:**

We present an intriguing case of a slowly growing VT in a woman with progressive neurological symptoms. Surgical fenestration provided complete symptomatic relief and follow-up imaging two years after surgery demonstrated no evidence of recurrence. This, to our knowledge, is the first described case of a slowly enlarging VT independent of any other imaging findings.

**MeSH Keywords:**

Cerebral Ventricles • Neuroradiography • Neurosurgery • Spinal Cord Compression

**PDF file:**

<http://www.polradiol.com/abstract/index/idArt/895669>

### Background

The term ventriculus terminalis (VT), or *fifth ventricle*, has been given to a cerebral spinal fluid (CSF) cavity within the conus medullaris. The VT has been described as a normal structure during embryonal development but its persistence into adulthood is exceptionally rare with approximately 30 cases described in the literature [1]. These lesions, when identified, are thought to regress or remain stable in term of size, although some have been described to enlarge in the presence of post-traumatic meningeal hemorrhages or deformities of the vertebral canal [2,3]. These lesions are thought to form during embryogenesis through secondary neurulation of the caudal spinal cord [2]. VTs are occasionally identified in association with caudal regression of the spinal cord or a tethered spinal cord. Histologically, these lesions are simple CSF-filled cavities within the conus medullaris enclosed by ependymal tissue without any gliosis or neoplastic cells.

VTs are most commonly diagnosed in patients under five years old, although they can occur at any age [2]. Males and females are affected equally and VTs usually remain stable

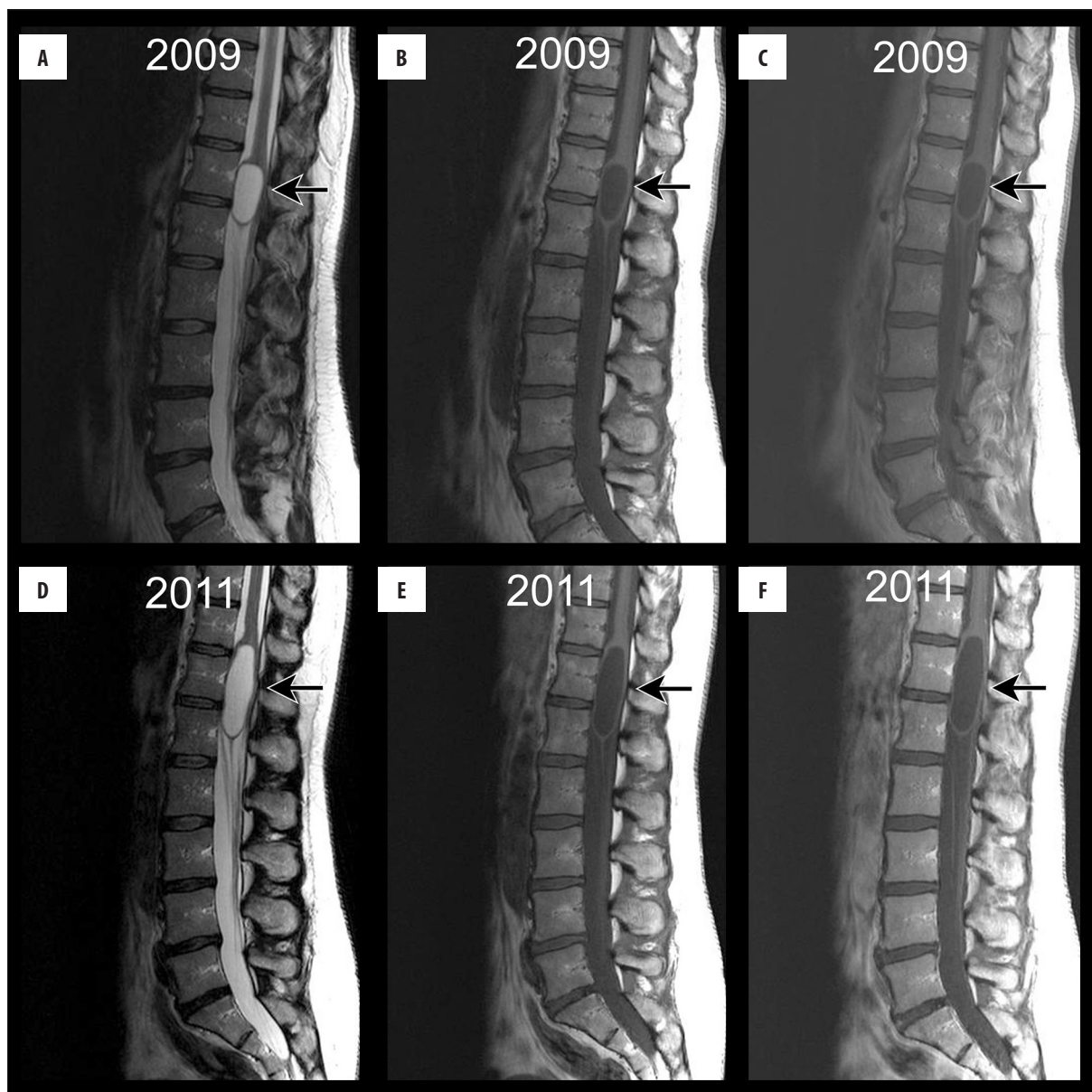
in size or regress with age. These lesions are usually incidentally discovered on imaging and do not typically require treatment if asymptomatic. Surgical decompression is a common method of treatment for symptomatic VTs often characterized by cyst fenestration with or without shunting to the subarachnoid space, pleural cavity, or peritoneal cavity.

We describe a case of a slowly growing VT in a patient with progressing lower limb weakness without any history or imaging findings of trauma or spinal canal abnormalities. This, to our knowledge, is the first described case of a slowly enlarging VT independent of any other imaging findings.

### Case Report

Our institution does not require ethics board approval for case reports.

A 47-year-old female presented to the emergency department with bilateral lower limb numbness. Physical examination revealed mild bilateral lower extremity paresthesias



**Figure 1.** Sagittal MRI images of the lumbar spine from 2009 (A–C) and 2011 (D–F) showing interval growth of the ventriculus terminalis (arrow) as a T2-hyperintense conus medullaris lesion without any surrounding cord edema (A, D) that is T1-hypointense (B, E) with rim enhancement on post-gadolinium T1-weighted images (C, F).

with normal power, reflexes and rectal tone. She was managed conservatively but her symptoms of lower extremity numbness progressed for over two years and she began experiencing bilateral lower limb weakness. She was seen in the clinic and her physical examination now revealed worsening bilateral lower extremity paresthesias and symmetric bilateral power loss with normal reflexes.

MRI performed two years apart demonstrated a slowly growing intramedullary T2-hyperintense well-circumscribed cystic mass within the conus medullaris of the spinal cord without any surrounding cord edema (Figure 1A [2009] and Figure 1D [2011], arrow). On T1-weighted imaging, this mass was hypointense (Figure 1B [2009] and Figure 1E [2011], arrow) with rim-enhancement following intravenous gadolinium administration (Figure 1C [2009]

and Figure 1F [2011], arrow). Given the lack of internal enhancement, lack of cord edema, and slow progressive growth of this cystic lesion with an otherwise normal vertebral column, a diagnosis of VT was made.

With the aid of intraoperative ultrasound, the patient underwent dorsal bilateral T12-L1 laminectomies and median longitudinal myelotomy with fenestration of the cystic mass in her conus. Approximately 15 mL of clear fluid resembling CSF was drained. There were no intraoperative complications. Neuropathology of fluid and a 1-mm sample of tissue revealed fibrous tissue with a single-layered membrane of flattened arachnoid cells. There was no evidence of neoplasm.

Following surgical drainage, she made a satisfactory recovery, which included one month of physiotherapy, and is symptom-free three years following surgery.

## Discussion

The ventriculus terminalis (also known as the terminal ventricle and the fifth ventricle) is an ependymal-lined cystic cavity within the conus medullaris thought to result from canalization and retrogressive differentiation during embryonic development [4]. It is also postulated that a VT could be a sequela of inflammation, vascular pathology, cord compression, or cord ischemia [5]. Asymptomatic VTs have been discovered in up to 2.6% of pediatric patients less than 5 years of age [6] and have been associated with Chiari malformations, tethered cord syndrome, sacral lipomas, spinal dysraphism, and lipomyelomeningoceles [4]. An isolated VT is rarely discovered in the adult population [2,7].

A VT on imaging of the lumbar spine may be found incidentally in patients with low back pain or neuromuscular deficits [3]. On imaging, the VT is an ovoid, smooth-walled, well-defined, non-enhancing cyst located within the conus medullaris. Internal non-enhancing septations have been described, but are exceedingly rare [8]. There is characteristically a lack of surrounding cord edema. These lesions resemble CSF signal on all MRI sequences in that they are hypointense on T1-weighted imaging, isointense on proton density-weighted imaging, and hyperintense on T2-weighted imaging. A lack of intracystic and surrounding cord enhancement is also characteristic. The surrounding cord usually demonstrates no abnormality such as edema or enhancement. A differential diagnosis based on imaging appearance in an adult includes hydrosyringomyelia, ependymoma, hemangioblastoma, and astrocytoma. There is paucity of literature describing enlarging VTs, which makes our report unique. Differential diagnosis of a VT includes syringohydromyelia, which would be

expected to recur on follow-up imaging after surgical treatment due to underlying subarachnoid obstruction. There is one reported case of a non-enhancing cystic astrocytoma of the conus [9], which would lend one to closely follow cystic lesions of the conus both clinically and radiographically to assess for worsening symptoms or growth/surrounding cord changes, respectively.

Management of the VT remains controversial with some surgeons selecting conservative treatment with serial imaging, while others prefer managing these lesions surgically based on neurological symptoms [2,8,10,11]. Cyst fenestration has been shown to result in complete clinical recovery in 52% of cases and partial recovery in 43% [12]. Intraoperative assessment of cyst contents typically reveals transparent liquid similar to normal CSF, suggesting preserved turnover of cystic contents with the surrounding CSF [3]. In our case, the patients' progressive symptoms combined with the radiologic growth of the conus lesion, prompted surgical management, which revealed an arachnoid-lined cyst containing fluid resembling CSF, concordant with typical VT neuropathology described in the literature.

## Conclusions

We presented an intriguing case of a slowly growing VT in a woman with progressive neurological symptoms. Surgical fenestration provided complete symptomatic relief and follow-up imaging two years after surgery demonstrated no evidence of recurrence. Although the MRI findings were classic for VT, its growth raised concerns of a neoplastic entity, which proved negative on pathology. To our knowledge, we are the first to report a case of an enlarging VT successfully treated with surgical fenestration.

## Conflict of interest

No potential conflict of interest relevant to this article was reported.

## References:

- Suh SH, Chung TS, Lee SK et al: Ventriculus terminalis in adults: Unusual magnetic resonance imaging features and review of the literature. *Korean J Radiol*, 2012; 13: 557–63
- Celli P, D'Andrea G, Trillo G et al: Cyst of the medullary conus: malformative persistence of terminal ventricle or compressive dilatation? *Neurosurg Rev*, 2002; 25: 103–6
- Liccardo G, Ruggeri F, De Cerchio L et al: Fifth ventricle: An unusual cystic lesion of the conus medullaris. *Spinal Cord*, 2005; 43: 381–84
- Ganau M, Talacchi A, Cecchi PC et al: Cystic dilation of the ventriculus terminalis. *J Neurosurg Spine*, 2012; 17: 86–92
- Nassar SI, Correll JW, Housepian EM: Intramedullary cystic lesions of the conus medullaris. *J Neurol Neurosurg Psychiatry*, 1968; 31: 106–9
- Coleman LT, Zimmerman RA, Rorke LB: Ventriculus terminalis of the conus medullaris: MR findings in children. *Am J Neuroradiol*, 1995; 16: 1421–26
- Matsubayashi R, Uchino A, Kato A et al: Cystic dilatation of ventriculus terminalis in adults: MRI. *Neuroradiology*, 1998; 40: 45–47
- Dullerud R, Server A, Berg-Johnsen J: MR imaging of ventriculus terminalis of the conus medullaris. A report of two operated patients and a review of the literature. *Acta Radiol*, 2003; 44: 444–46
- Seo HS, Kim JH, Lee DH et al: Nonenhancing intramedullary astrocytomas and other MR imaging features: A retrospective study and systematic review. *Am J Neuroradiol*, 2010; 31: 498–503
- de Moura Batista L, Acioly MA, Carvalho CH et al: Cystic lesion of the ventriculus terminalis: Proposal for a new clinical classification. *J Neurosurg Spine*, 2008; 8: 163–68
- Brisman JL, Li M, Hamilton D, Mayberg MR, Newell DW: Cystic dilation of the conus ventriculus terminalis presenting as an acute cauda equina syndrome relieved by decompression and cyst drainage: Case report. *Neurosurgery*, 2006; 58: E585; discussion E585
- Borius PY, Cintas P, Lagarrigue J: [Ventriculus terminalis dilatation in adults: A case report and review of the literature]. *Neurochirurgie*, 2010; 56: 386–90