



## Case report

# Antegrade cystoscopy – An innovative approach to managing acute urinary retention following vulvar reconstruction flap stenosis

Surbhi Agrawal<sup>a</sup>, Caroline Brandon<sup>a</sup>, Ghadir Salame<sup>a,b,\*</sup>

<sup>a</sup> New York University Langone Health, 550 First Avenue, New York, NY 10016, USA

<sup>b</sup> Perlmutter Cancer Center, 160 E. 34<sup>th</sup> Street, New York, NY 10016, USA

## ARTICLE INFO

## Keywords

Antegrade cystoscopy  
Fasciocutaneous skin flaps  
Suprapubic catheter  
Urethral meatal scarring  
Urinary retention  
Vulvectomy

## ABSTRACT

Vulvar reconstruction can be performed following radical vulvectomy and is known to be associated with urologic complications. We describe the use of antegrade cystoscopy to manage acute urinary retention secondary to an obliterated urethral meatus following radical vulvectomy and reconstruction for radiation dermatitis. Antegrade cystoscopy was performed by applying the surgical concepts for suprapubic catheterization and general laparoscopy. Antegrade cystoscopy is a simple and safe approach for female patients with distorted pelvic anatomy from radical surgery and reconstructions for vulvar cancer.

## 1. Introduction

Vulvar reconstruction can be performed following radical vulvectomy for primary surgical management of vulvar cancer or to manage the sequelae of primary radiation therapy, such as vulvar radionecrosis (Roberts et al., 1991).

Known complications of vulvar reconstructive flaps include dehiscence, infection, necrosis, stenosis, and urologic difficulties (Di Donato et al., 2017). During reconstruction, the distal urethra and meatus can be affected from either the partial urethrectomy that is performed at the time of vulvectomy or the postoperative healing process. Limited evidence indicates that the incidence of urologic symptoms range from 1.4% to 3.6% after vulvar reconstruction, and includes complications such as urinary tract infections and incontinence (Di Donato et al., 2017).

The incidence of urinary retention has not been reported, nor the management of such a complication after vulvar reconstruction. If the urethral meatus is identifiable, urinary retention can be managed with catheterization to allow bladder drainage. When the urethral meatus is not identifiable or patent due to severe flap stenosis, aside from suprapubic catheterization, little is described regarding minimally invasive techniques to safely evaluate the meatus and relieve obstruction. We describe a simple surgical approach for this rare and challenging complication.

## 2. Case presentation

We present the case of a 63-year-old woman with acute urinary retention following vulvectomy and fasciocutaneous flap creation for the management of sequelae of primary radiation therapy for vulvar squamous cell carcinoma (SCC).

Briefly, the patient presented with severe vulvar pain, irritation, dysuria, and difficulty emptying her bladder following primary radiation therapy for vulvar SCC treated at an outside hospital four years prior. After ruling out recurrent malignancy and failing conservative therapies, including topical creams and hyperbaric oxygen, the patient was counseled regarding her options for management of radiation-induced dermatitis (Fig. 1a). She underwent a radical vulvectomy with transposition fasciocutaneous skin flaps in V-Y configuration (Fig. 1b).

On postoperative day 29, she presented with oliguria and pain, and was found to have tachycardia, hypotension, leukocytosis and elevated creatinine consistent with urosepsis in the setting of indwelling catheter. Work up also revealed bilateral hydronephrosis. Therefore, she underwent bilateral percutaneous nephrostomy (PCN) tube placement and removal of indwelling urethrovaginal catheter. Following recovery, she was discharged home for ambulatory ureteral stent placement and removal of both PCN tubes with urology.

The patient returned for planned cystoscopy with retrograde pyelogram with the urology team. However, on examination, no discernable urethral meatus was identified due to severe scarring between the vulvar

\* Corresponding author at: Perlmutter Cancer Center, NYU Langone Health, 160 E. 34<sup>th</sup> Street, New York, NY 10016, USA.

E-mail address: [Ghadir.Salame@nyulangone.org](mailto:Ghadir.Salame@nyulangone.org) (G. Salame).

<https://doi.org/10.1016/j.gore.2020.100675>

Received 4 October 2020; Received in revised form 9 November 2020; Accepted 12 November 2020

Available online 19 November 2020

2352-5789/© 2020 The Authors.

Published by Elsevier Inc.

This is an open access article under the CC BY-NC-ND license

(<http://creativecommons.org/licenses/by-nc-nd/4.0/>).

flaps, preventing safe cystoscopic entry (Fig. 2). An antegrade nephrostogram was performed and showed resolution of the hydronephrosis with bilateral ureteral drainage to the bladder, so the PCN tubes were removed. The patient was able to void postoperatively and was discharged home.

Three months later she presented to the emergency room in acute urinary retention. On exam, no urethral meatus was identified; thus, no urethrovaginal foley catheter could be placed. An extensive discussion regarding management of outlet obstruction took place, including the insertion of a suprapubic tube, replacement of PCN tubes, or antegrade cystoscopy with urethrotomy and insertion of indwelling foley catheter. The patient opted to undergo the latter procedure, which is described below.

Following general anesthesia, the patient was placed in dorsal lithotomy position. Slight Trendelenburg was applied. After appropriate skin prep and draping, an exam under anesthesia was performed. Findings included complete obliteration of the urethral meatus by cicatrix between the skin flaps and near complete obliteration of the vaginal introitus. Thus, an antegrade cystoscopy approach was pursued. A Veress needle was inserted 4 cm superior to the pubic symphysis. Clear yellow urine was aspirated, confirming intra-vesical placement. The skin incision was extended to 5 mm and a 5 mm laparoscopic trocar was placed in lieu of the Veress. The bladder was drained through the port and a 5 mm laparoscope with CO<sub>2</sub> gas insufflation was introduced and used to visualize the bladder neck. Insufflation pressure was kept to 8 mmHg. The laparoscope was passed beyond the bladder neck along the urethra until *trans*-illumination was noted at the perineum in the area of fibrotic scar between the two flaps. A cruciate incision was made transperineally directly overlying the laparoscope's tip, and the scope punctured through to perform the urethrotomy. A 16 French foley catheter was then threaded into the urethra as the laparoscopic camera retreated, confirming placement in the bladder. The trocar and instruments were removed. The abdominal incision was re-approximated with 3–0 Vicryl suture and skin glue.

Postoperatively, the patient was examined in the clinic and excellent healing at the external urethral meatus was noted. The foley catheter was removed four weeks after her surgery with instructions to perform timed voiding every four hours to prevent agglutination. Shortly after, the patient left the country, but through personal communication, reports emptying her bladder well, without the need to strain for over one year postoperatively.

### 3. Discussion

This is an innovative approach to the management of acute urinary retention in the setting of an obliterated external urethral meatus. While antegrade cystoscopy is not novel, this is the first report discussing the application of this technique in acute urinary retention secondary to flap stenosis after vulvar reconstruction resulting in complete obliteration of the urethral meatus.

The antegrade cystoscopic approach has mostly been described in limited case series of male patients with urethral strictures. Goel et al.

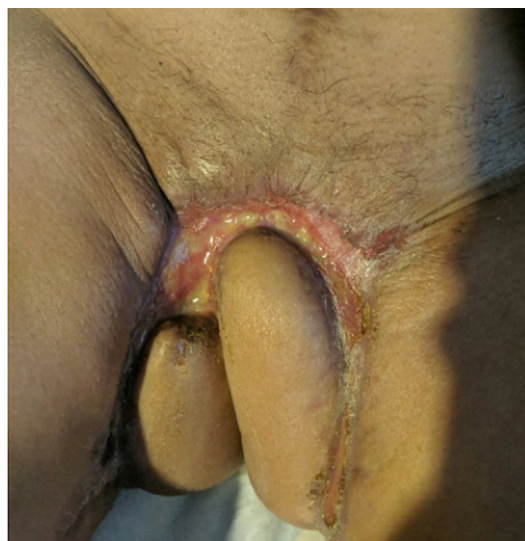

Fig. 2. Anatomical distortion following flap healing and cicatrix formation.

describe how the suprapubic tract was dilated and antegrade cystoscopy was performed to assist with visualization of urethral strictures in five male patients in whom the strictures could not be safely approached in a retrograde manner (Goel et al., 2009). With 43 male patients, Hosseini et al. explain how they used antegrade cystoscopy to perform retrograde urethrotomy under direct visualization for male patients with obliterative urethral strictures (Hosseini et al., 2008). However, in the rare case of female hypospadias, Prakash et al. describe using antegrade cystoscopy in an 11-year-old female child with urinary retention to identify and cannulate the urethral meatus successfully (Prakash et al., 2016).

In all of the aforementioned studies, a pre-existing suprapubic channel was used to perform antegrade cystoscopy. In our patient, antegrade cystoscopy was deemed to be a safe approach by applying the same surgical principles as for placement of a suprapubic catheter. Suprapubic catheter placement is considered to be a safe, simple procedure, which is associated with few and rare complications (Ahluwalia et al., 2006).

First, in the setting of suprapubic entry into a distended bladder, there is minimal risk of bowel injury due to the full bladder displacing bowels away from the bladder entry site (Jacob et al., 2012). Second, with continuous drainage of urine through a foley catheter preventing bladder distention, the bladder epithelium should re-approximate and heal by secondary intention for defects less than 1 cm (Gomez et al., 2004). Therefore, the 5 mm bladder entry site for antegrade cystoscopy should heal without incident, as it did in this patient. Finally, this case employed surgical tools and techniques that are part of a gynecologic oncologist's diverse repertoire, making this a low-risk approach.

Additional case considerations include postoperative management to promote urethral healing and to prevent recurrence. Regarding length of

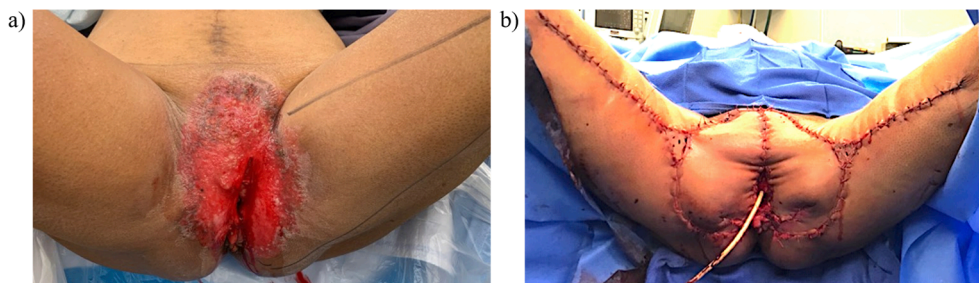


Fig. 1. (a) Radiation-induced dermatitis as seen prior to vulvar reconstruction. (b) Reconstruction of vulva with V-Y advancement fasciocutaneous flaps following radical vulvectomy.

bladder catheterization, evidence extrapolated from patients who have undergone urethroplasty suggest a foley should remain in situ at least two to three weeks postoperatively (Tritschler et al., 2013). Another strategy that may work is topical steroids. While there is extremely limited data to support this from studies on hypospadias repairs in infants, it is the mainstay of therapy for lichen sclerosis, which can also lead to local perineal scarring and urinary symptoms (Potts et al., 2016).

In summary, this report describes a new approach to the management of acute urinary retention in a woman with vulvar flap stenosis and urethral meatus obliteration. Antegrade cystoscopy is a safe and straightforward surgical technique that surgeons may employ to address acute urinary retention that cannot safely be evaluated from a retrograde approach due to distorted anatomy.

#### Informed consent

Written informed consent was obtained from the patient for publication of this case report and accompanying images.

#### Authors' contributions

Patient care and study conception: GS, CB

Manuscript writing: SA

Acquisition of data: SA, CB

Manuscript editing and review: SA, CB, GS

Final approval: All authors.

#### Declaration of Competing Interest

The authors have no conflicts of interest.

#### References

- Ahluwalia, R.S., Johal, N., Kouriefs, C., Kooiman, G., Montgomery, B.S., Plail, R.O., 2006. The surgical risk of suprapubic catheter insertion and long-term sequelae. *Annals Roy. College Surg. England*. 88 (2), 210–213.
- Di Donato, V., Bracchi, C., Cigna, E., Domenici, L., Musella, A., Giannini, A., Lecce, F., Marchetti, C., Panici, P.B., 2017. Vulvo-vaginal reconstruction after radical excision for treatment of vulvar cancer: Evaluation of feasibility and morbidity of different surgical techniques. *Surg. Oncol.* 26 (4), 511–521.
- Goel, A., Gupta, A., Dalela, D., 2009. Antegrade urethrogram: A technique to visualize the proximal bulbous urethral segment in anterior urethral stricture. *Indian J. Urol.: IJU: J. Urol. Soc. India* 25 (3), 415.
- Gomez, R.G., Ceballos, L., Coburn, M., Corriere Jr, J.N., Dixon, C.M., Lobel, B., McAninch, J., 2004. Consensus statement on bladder injuries. *BJU Int.* 94 (1), 27–32.
- Hosseini, S.J., Kaviani, A., Vazirnia, A.R., 2008. Internal urethrotomy combined with antegrade flexible cystoscopy for management of obliterative urethral stricture. *Urol. J.* 5 (3), 184–187.
- Jacob, P., Rai, B.P., Todd, A.W., 2012. Suprapubic catheter insertion using an ultrasound-guided technique and literature review. *BJU Int.* 110 (6), 779–784.
- Potts, B.A., Belsante, M.J., Peterson, A.C., 2016. Intraurethral steroids are a safe and effective treatment for stricture disease in patients with biopsy proven lichen sclerosis. *J. Urol.* 195 (6), 1790–1796.
- Prakash, G., Singh, M., Goel, A., Jhanwar, A., 2016. Female hypospadias presenting with urinary retention and renal failure in an adolescent: uncommon and late presentation with significant hidden morbidity. *Case Rep.*, 2016, bcr2016215064.
- Roberts, W.S., Hoffman, M.S., LaPolla, J.P., Ruas, E., Fiorica, J.V., Cavanagh, D., 1991. Management of radionecrosis of the vulva and distal vagina. *Am. J. Obstetr. Gynecol.* 164 (5), 1235–1238.
- Tritschler, S., Füllhase, C., Stief, C., Roosen, A., 2013. Management of urethral strictures: practical guidelines. *Der Urologe. Ausg. A.* 52 (5), 677–681.