



## Case report

# A favorable clinical effect of an expectorant in allergic bronchopulmonary mycosis caused by *Schizophyllum commune*



Haruki Kobayashi <sup>a,\*</sup>, Tetsuhiko Taira <sup>a</sup>, Kazushige Wakuda <sup>a</sup>, Toshiaki Takahashi <sup>a</sup>, Masahiro Endo <sup>b</sup>

<sup>a</sup> Division of Thoracic Oncology, Shizuoka Cancer Center, Shizuoka, Japan

<sup>b</sup> Division of Diagnostic Radiology, Shizuoka Cancer Center, Shizuoka, Japan

## ARTICLE INFO

## Article history:

Received 11 May 2016

Received in revised form

8 July 2016

Accepted 11 July 2016

## Keywords:

*Schizophyllum commune*

Allergic bronchopulmonary mycosis

Mucus plug

Expectorant

## ABSTRACT

An 80-year-old Japanese woman with wet cough and dyspnea was diagnosed with pneumonia at a clinic. Antibiotics did not improve her symptoms; therefore, she was referred to our hospital one month after symptom onset. Chest radiograph findings revealed complete collapse of the left lung. Bronchoscopy showed white mucus plug in the left main bronchus, which could not be removed. She was initially treated with bromhexine. Subsequently, culture results of the mucus plug specimen obtained during bronchoscopy yielded *Schizophyllum commune*. After three weeks, improvement of the collapsed lung was observed on chest radiograph.

© 2016 The Authors. Published by Elsevier Ltd. This is an open access article under the CC BY-NC-ND license (<http://creativecommons.org/licenses/by-nc-nd/4.0/>).

## 1. Introduction

*Schizophyllum commune* is a common species of fungus (mushroom) that colonizes diverse trees and rotting wood worldwide. Inhalation exposure to this environmental fungus is possible during usual activities of daily living. In 1994, Kamei reported the first case of allergic bronchopulmonary mycosis (ABPM) caused by *S. commune* infection [1]. Recently, an increasing number of cases of ABPM and mucoid impaction of the bronchi (MIB) secondary to *S. commune* infection has been reported, most of which were from Japan [2]. Some reports have indicated good response to treatment with antifungal drugs and/or corticosteroids; however, many patients develop resistance to such therapy [3–6]. Therefore, there remain many unclear aspects on the treatment, as well the risk factors and pathogenesis, of ABPM and MIB caused by *S. commune*.

Herein, we report the first case of a favorable clinical effect of an expectorant agent against ABPM. This report may contribute to the improvement of treatment of ABPM caused by *S. commune*.

## 2. Case report

An 80-year-old Japanese female, with a 48-pack years smoking history, presented to a clinic complaining of wet cough and breathing difficulty. She had a past history of tuberculosis, but there was no history or symptoms suggestive of asthma. Chest radiograph revealed left lower lobe collapse (Fig. 1). She was hospitalized after being diagnosed with pneumonia and treated with antibiotics (ampicillin/sulbactam). However, the initial treatment was ineffective, and radiograph findings progressively worsened within weeks. Therefore, she was transferred to our hospital for evaluation and treatment at one month after symptom onset.

Upon examination, SpO<sub>2</sub> was 89% at room air. Laboratory test showed elevated eosinophil count at 651/μL. Additionally, chest radiograph and computed tomography (CT) findings revealed complete collapse of the left lung with hyperattenuated mucoid (HAM) impaction (Fig. 2). Bronchoscopy showed a white, rubbery, thick mucus plug in the left main bronchus, which could not be removed by forceps or suction (Fig. 3). The findings on pathologic examination were eosinophilic infiltration without Charcot-Leyden crystals on Hematoxylin and Eosin stain and presence of fungal mycelium on Grocott stain. Culture of the small pieces of the mucus plug obtained during bronchoscopy yielded *S. commune*.

The patient was treated with an expectorant agent, bromhexine 8 mg three times daily, after the bronchoscopy. Three weeks

\* Corresponding author. Division of Thoracic Oncology, Shizuoka Cancer Center, 1007 Shimonagakubo, Nagaizumi-cho Sunto-gun, Shizuoka, 411-8777, Japan. Tel.: +81 55 989 5222; fax: +81 55 989 5783.

E-mail address: [h.kobayashi@sccr.jp](mailto:h.kobayashi@sccr.jp) (H. Kobayashi).

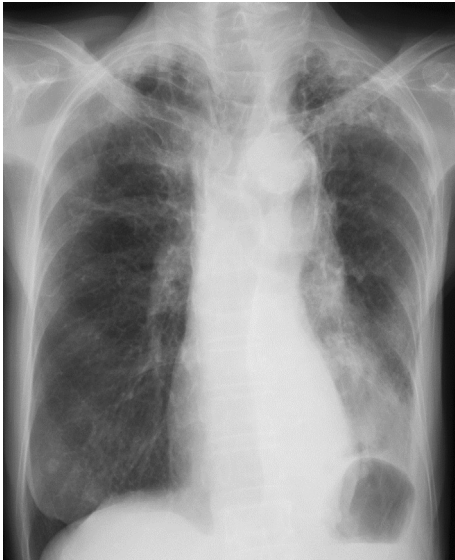

Fig. 1. Chest radiograph on the first visit shows left lower lobe collapse.

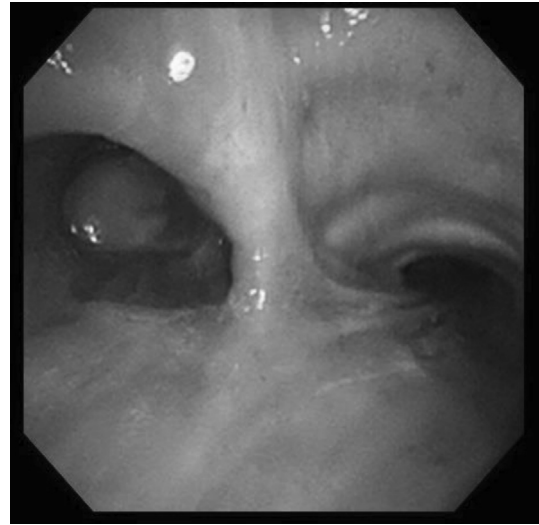


Fig. 3. Bronchoscopy findings show white mucus plug in left main bronchus.

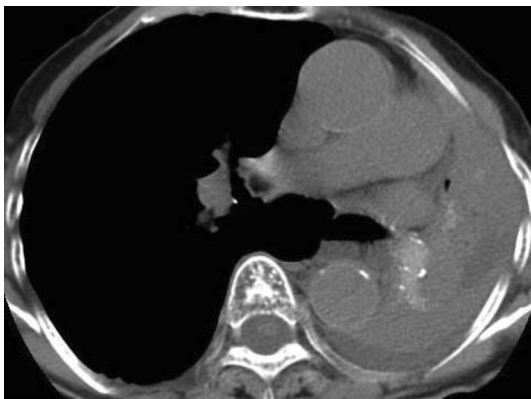

Fig. 2. Chest computed tomography obtained upon admission shows complete collapse of the left lung with hyperattenuated mucoid impaction.

later, chest radiographic findings revealed improvement of the collapsed left lung (Fig. 4A). Two months later, while she was completely recuperating from wet cough and breathing difficulty, SpO<sub>2</sub> increased to 97% at room air and chest CT showed complete recovery of the collapsed lung, but with central bronchiectasis seen (Fig. 4B). Subsequently, she has returned to the clinic for follow-up and has continued bromhexine treatment successfully for more than 20 months. There were no adverse effects of bromhexine.

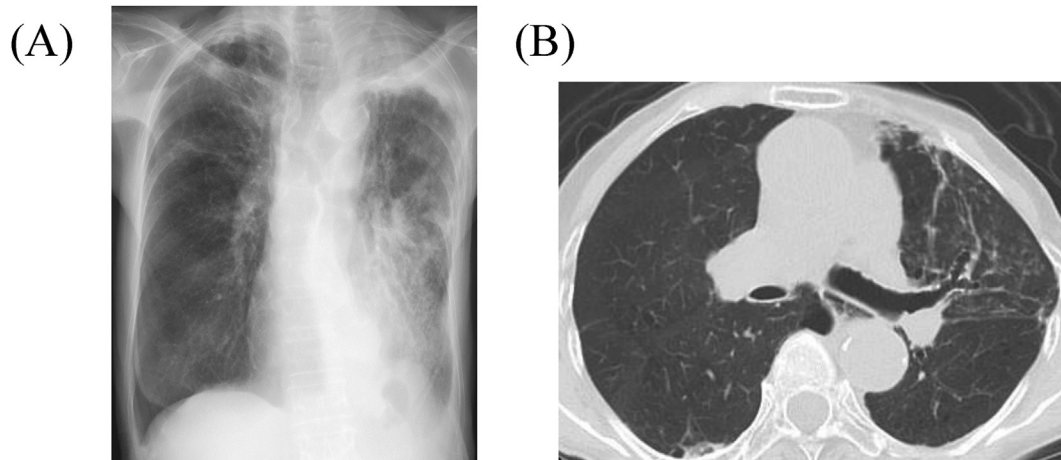
### 3. Discussion

Antifungal drugs and/or corticosteroids are frequently the first choice of treatment for ABPM. According to the previously reported 18 cases of ABPM and MIB secondary to *S. commune* in Japan [1,3–16], patients were initially treated with antifungal drug (n = 6); systemic corticosteroid (n = 1); combination of antifungal drugs and systemic corticosteroids (n = 4), with the addition of inhaled corticosteroids (n = 3); bronchoscopic drainage (n = 1), with the addition of inhaled corticosteroids (n = 1); and combination of systemic and inhaled corticosteroids (n = 2). To the best of our knowledge, this was the first report of a favorable clinical effect

of an expectorant agent alone in a patient with ABPM secondary to *S. commune* infection.

The efficacy of bromhexine is as follows: 1) promoting serous secretion, 2) dissolving content of acid glycoprotein fibers, and 3) increasing the ciliary movement. In addition, it has been reported that expectorant agents have anti-inflammatory effects [17,18]. Therefore, a possible explanation for the efficacy of bromhexine in this case was that the activated ciliary movement and reduced inflammation facilitated removal of the dissolved mucoid impaction. Expectorants have less adverse effects and cost less compared with antifungal drugs and systemic corticosteroids. Based on these results, expectorant agents may be considered a routine add-on therapy to anti-fungal drugs and/or corticosteroids in patients with ABPM secondary to *S. commune* in order to obtain better response in the clinical setting.

There are no established diagnostic criteria for ABPM, especially ABPM secondary to *S. commune* infection. However, the diagnostic criteria for allergic bronchopulmonary aspergillosis (ABPA) are generally accepted for ABPM by replacing *Aspergillus fumigatus* with *S. commune*. In other words, the diagnostic criteria for ABPM caused by *S. commune* should include the clinical, serologic, pathologic, microbiologic, and imaging findings that are used for the diagnosis of ABPA. Katzenstein [19] and Bosken [20] have mentioned the importance of mucus plugs. Specifically, detecting an MIB that includes eosinophilic infiltration and fungus may be designated as ABPM. The present case was characterized by eosinophilic infiltration and the presence of *S. commune* in the mucus plugs. Therefore, we diagnosed as ABPM caused by *S. commune*. Goyal et al. revealed that HAM impaction on chest CT was seen in ABPA [21], which is characterized to be denser than skeletal muscle on CT. The possible reason for development of HAM is the presence of calcium salts and metals (e.g., ions of iron and manganese), hemorrhagic products, or desiccated mucus [21–24]. HAM has been reported to be encountered in 18.7–30% of patients with ABPA [22,25,26], which is considered to be risk factor for relapse [25]. Uruga et al. first reported HAM caused by *S. commune* in 2010 [6]. Central bronchiectasis is also known to be a feature of ABPA on CT scan [27]. In addition, some reports revealed that central bronchiectasis was seen in ABPM caused by *S. commune* [2,5], through a mechanism mediated by T helper 2-type immune responses and fungal proteases [28–30]. These CT scan findings



**Fig. 4.** (A) Chest radiograph three weeks after initiation of bromhexine treatment shows improvement of the collapsed lung. (B) Chest computed tomography two months after initiation of bromhexine treatment shows central bronchiectasis and recovery of the collapsed lung.

were seen in our present case. Therefore, these characteristic CT findings may lead to a diagnosis of ABPM caused by *S. commune*.

The Rosenberg and Patterson criteria [27], in which *S. commune* replaces *A. fumigatus*, are most widely used for the diagnosis of ABPM caused by *S. commune*. The primary criteria include 1) episodic bronchial obstruction, 2) peripheral blood eosinophilia, 3) immediate skin reactivity to *S. commune* antigen, 4) precipitating antibodies against *S. commune* antigen, 5) elevated serum IgE concentration, 6) history of pulmonary infiltrates, and 7) central bronchiectasis. The secondary criteria include 1) *S. commune* in sputum, 2) history of expectoration of brown plugs, and 3) arthus reactivity to *S. commune* antigen. The presence of  $\geq 6$  primary criteria was reported by Agarwal et al. to have a 100% sensitivity and 100% specificity [31], whereas Ishiguro et al. reported a sensitivity of 57.1% and specificity of 100%. This difference in sensitivity of the criteria between the two studies may be accounted for by the varying characteristics of patients with asthma in the study by Ishiguro et al. In two other studies on patients with ABPM caused by *S. commune*, Kamei et al. reported that only 30% had bronchial asthma [32], whereas Glancy et al. reported that 74% had bronchial asthma [33]. Therefore, the present criteria may have low sensitivity for the diagnosis of ABPM caused by *S. commune*.

The diagnosis of ABPM was not made until culture of the mucus plug obtained during bronchoscopy revealed *S. commune*. Initially, our impression was a non-infectious mucus plug. For this reason, all diagnostic blood tests (serum IgE value, serum IgE antibody against *S. commune*, and serum precipitating or IgG antibody against *S. commune*), pulmonary function test, and treatment (antifungal drugs and/or corticosteroids) for ABPM were not performed. This was also the reason the patient was treated with bromhexine alone. Surprisingly, bromhexine was able to exert a therapeutic effect in this patient with ABPM secondary to *S. commune* infection by allowing drainage of the rubbery thick mucus plug that could not be removed by bronchoscopy.

In summary, we experienced a favorable clinical effect of an expectorant agent against ABPM due to *S. commune*. Expectorant agents, such as bromhexine, should be routinely used in the clinical setting as an add-on therapy that can work synergistically with antifungal drugs and/or corticosteroids in patients with ABPM caused by *S. commune*.

#### Conflict of interest

None.

#### Acknowledgements

The authors thank Katsuhiko Kamei of the Division of Clinical Research, Medical Mycology Research Center, Chiba University for the identification of *S. commune*.

#### References

- [1] K. Kamei, H. Unno, K. Nagao, T. Kuriyama, K. Nishimura, M. Miyaji, Allergic bronchopulmonary mycosis caused by the basidiomycetous fungus *Schizophyllum commune*, *Clin. Infect. Dis.* 18 (3) (1994) 305–309.
- [2] A. Chowdhary, H.S. Randhawa, S.N. Gaur, K. Agarwal, S. Kathuria, P. Roy, C.H. Klaassen, J.F. Meis, *Schizophyllum commune* as an emerging fungal pathogen: a review and report of two cases, *Mycoses* 56 (1) (2013) 1–10.
- [3] Y. Amemiya, R. Shirai, I. Tokimatsu, H. Oka, A. Iwata, S. Otani, K. Umeki, H. Sakashita, H. Ishii, Y. Gendo, K. Kishi, K. Hiramatsu, J. Kadota, Allergic bronchopulmonary mycosis induced by *Schizophyllum commune*—case report and review of the literature, *Nihon Kokyuki Gakkai Zasshi* 47 (8) (2009) 692–697.
- [4] T. Ishiguro, N. Takayanagi, K. Harasawa, Y. Yoshii, A. Matsushita, K. Yoneda, Y. Miyahara, N. Kagiya, D. Tokunaga, F. Aoki, H. Saito, M. Ubukata, K. Kurashima, T. Yanagisawa, Y. Sugita, Y. Kawabata, K. Kamei, Mucoid impaction of the bronchi caused by *Schizophyllum commune* which developed after discontinuation of itraconazole administration, *Nihon Kokyuki Gakkai Zasshi* 47 (4) (2009) 296–303.
- [5] A. Masunaga, K. Morimoto, T. Ando, S. Ikushima, T. Takemura, M. Oritsu, Three cases of allergic bronchopulmonary mycosis due to *Schizophyllum commune*, *Nihon Kokyuki Gakkai Zasshi* 48 (12) (2010) 912–917.
- [6] H. Uruga, A. Imafuku, S. Hanada, H. Takaya, A. Miyamoto, H. Sugimoto, N. Morokawa, A. Kurosaki, T. Fujii, K. Kishi, A case of allergic bronchopulmonary mycosis caused by *Schizophyllum commune* presenting with hyperattenuated mucoid impaction, *Nihon Kokyuki Gakkai Zasshi* 48 (10) (2010) 749–754.
- [7] K. Tomita, I. Hashizume, N. Kasamatsu, A. Nakamura, S. Hanzawa, S. Momiki, K. Sasaki, K. Okamoto, T. Ozawa, K. Kamei, Allergic bronchopulmonary mycosis caused by *Schizophyllum commune*, *Nihon Kyobu Shikkan Gakkai Zasshi* 34 (7) (1996) 804–809.
- [8] R. Amitani, K. Nishimura, A. Niimi, H. Kobayashi, R. Nawada, T. Murayama, H. Taguchi, F. Kuze, Bronchial mucoid impaction due to the monokaryotic mycelium of *Schizophyllum commune*, *Clin. Infect. Dis.* 22 (1) (1996) 146–148.
- [9] S. Yamashina, Case of allergic bronchopulmonary mycosis caused by *Schizophyllum commune*, *Jpn. J. Antibiot.* 50 (1) (1997) 51–53 discussion 54, 75–6.
- [10] Y. Miyazaki, H. Sakashita, T. Tanaka, K. Kamei, K. Nishimura, Y. Yoshizawa, Mucoid impaction caused by monokaryotic mycelium of *Schizophyllum commune* in association with bronchiectasis, *Intern. Med.* 39 (2) (2000) 160–162.
- [11] Y. Itou, S. Sasaki, S. Watanabe, T. Kawamura, Y. Nakahara, Y. Mochizuki, K. Kamei, A case of mucoid impaction of bronchi (MIB) due to *Schizophyllum commune*, *Nihon Kokyuki Gakkai Zasshi* 39 (4) (2001) 266–270.
- [12] A. Yamasaki, K. Nishimura, H. Sano, K. Tomita, H. Chikumi, M. Watanabe, Y. Hitsuda, E. Shimizu, A case of allergic bronchopulmonary mycosis caused by *Schizophyllum commune*, *Arerugi* 51 (5) (2002) 439–442.
- [13] T. Kawano, H. Matsuse, K. Iida, Y. Kondo, I. Machida, S. Saeki, S. Tomari, Y. Miyazaki, S. Kohno, Two cases of allergic bronchopulmonary mycosis

- caused by *Schizophyllum commune* in young asthmatic patients, *Nihon Kokyuki Gakkai Zasshi* 41 (3) (2003) 233–236.
- [14] T. Ishiguro, N. Takayanagi, D. Tokunaga, K. Kurashima, A. Matsushita, K. Harasawa, K. Yoneda, N. Tsuchiya, S. Yamaguchi, Y. Miyahara, R. Yano, H. Saito, M. Ubukata, T. Yanagisawa, Y. Sugita, Y. Kawabata, Pulmonary *Schizophyllum commune* infection developing mucoid impaction of the bronchi, *Yale J. Biol. Med.* 80 (3) (2007) 105–111.
- [15] T. Ishiguro, N. Takayanagi, A. Saito, K. Akiyama, M. Wakayama, K. Shibuya, Y. Shimizu, Y. Sugita, K. Kamei, Allergic bronchopulmonary mycosis due to *Schizophyllum commune* and *Aspergillus fumigatus*, *Nihon Kokyuki Gakkai Zasshi* 49 (8) (2011) 612–618.
- [16] F. Kato, N. Kasamatsu, H. Kasai, R. Nishimura, T. Ogasawara, I. Hashizume, A case of mucoid impaction of bronchi caused by *Schizophyllum commune*, *Jpn. Soc. Respir. Endosc.* 34 (1) (2012) 38–43.
- [17] K. Takeda, Y. Shiraishi, S. Matsubara, N. Miyahara, H. Matsuda, M. Okamoto, A. Joetham, E.W. Gelfand, Effects of combination therapy with montelukast and carbocysteine in allergen-induced airway hyperresponsiveness and airway inflammation, *Br. J. Pharmacol.* 160 (6) (2010) 1399–1407.
- [18] A. Maccio, C. Madeddu, F. Panzone, G. Mantovani, Carbocysteine: clinical experience and new perspectives in the treatment of chronic inflammatory diseases, *Expert Opin. Pharmacother.* 10 (4) (2009) 693–703.
- [19] A.L. Katzenstein, A.A. Liebow, P.J. Friedman, Bronchocentric granulomatosis, mucoid impaction, and hypersensitivity reactions to fungi, *Am. Rev. Respir. Dis.* 111 (4) (1975) 497–537.
- [20] C.H. Bosken, J.L. Myers, P.A. Greenberger, A.L. Katzenstein, Pathologic features of allergic bronchopulmonary aspergillosis, *Am. J. Surg. Pathol.* 12 (3) (1988) 216–222.
- [21] R. Goyal, C.S. White, P.A. Templeton, E.J. Britt, L.J. Rubin, High attenuation mucous plugs in allergic bronchopulmonary aspergillosis: CT appearance, *J. Comput. Assist. Tomogr.* 16 (4) (1992) 649–650.
- [22] P.M. Logan, N.L. Muller, High-attenuation mucous plugging in allergic bronchopulmonary aspergillosis, *Can. Assoc. Radiol. J.* 47 (5) (1996) 374–377.
- [23] W. Kopp, R. Fotter, H. Steiner, F. Beaufort, H. Stammberger, Aspergillosis of the paranasal sinuses, *Radiology* 156 (3) (1985) 715–716.
- [24] W.P. Dillon, P.M. Som, G.D. Fullerton, Hypointense MR signal in chronically inspissated sinonasal secretions, *Radiology* 174 (1) (1990) 73–78.
- [25] R. Agarwal, D. Gupta, A.N. Aggarwal, A.K. Saxena, A. Chakrabarti, S.K. Jindal, Clinical significance of hyperattenuating mucoid impaction in allergic bronchopulmonary aspergillosis: an analysis of 155 patients, *Chest* 132 (4) (2007) 1183–1190.
- [26] T. Franquet, N.L. Muller, A. Gimenez, P. Guembe, J. de La Torre, S. Bague, Spectrum of pulmonary aspergillosis: histologic, clinical, and radiologic findings, *Radiographics* 21 (4) (2001) 825–837.
- [27] M. Rosenberg, R. Patterson, R. Mintzer, B.J. Cooper, M. Roberts, K.E. Harris, Clinical and immunologic criteria for the diagnosis of allergic bronchopulmonary aspergillosis, *Ann. Intern. Med.* 86 (4) (1977) 405–414.
- [28] H.F. Kauffman, Immunopathogenesis of allergic bronchopulmonary aspergillosis and airway remodeling, *Front. Biosci.* 8 (2003) e190–e196.
- [29] A.P. Knutsen, C. Bellone, H. Kauffman, Immunopathogenesis of allergic bronchopulmonary aspergillosis in cystic fibrosis, *J. Cyst. Fibros.* 1 (2) (2002) 76–89.
- [30] B. Chauhan, A. Knutsen, P.S. Hutcheson, R.G. Slavin, C.J. Bellone, T cell subsets, epitope mapping, and HLA-restriction in patients with allergic bronchopulmonary aspergillosis, *J. Clin. Investig.* 97 (10) (1996) 2324–2331.
- [31] R. Agarwal, D. Maskey, A.N. Aggarwal, B. Saikia, M. Garg, D. Gupta, A. Chakrabarti, Diagnostic performance of various tests and criteria employed in allergic bronchopulmonary aspergillosis: a latent class analysis, *PLoS One* 8 (4) (2013) e61105.
- [32] K. Kamei, H. Unno, J. Ito, K. Nishimura, M. Miyaji, Analysis of the cases in which *Schizophyllum commune* was isolated, *Jpn. J. Med. Mycol.* 40 (1999) 175–181.
- [33] J.J. Glancy, J.L. Elder, R. McAleer, Allergic bronchopulmonary fungal disease without clinical asthma, *Thorax* 36 (5) (1981) 345–349.