


REVIEW

Surgical anatomy of the mid-vagina

Bernard T. Haylen MB, BS, MD, FRANZCOG, FRCOG, CU¹ | **Dzung Vu MB, BS, MD, FRANCO (Hon)²** |**Audris Wong MB, BCh, BAO, FRANZCOG, FRCOG, MRCPI³** |**Sarah Livingstone MB, BS, FRANZCOG⁴**

¹Department of Gynaecology, University of New South Wales, Sydney, New South Wales, Australia

²Department of Anatomy, University of Notre Dame, Sydney, New South Wales, Australia

³Department of Obstetrics & Gynaecology, Gold Coast University Hospital, Southport, Queensland, Australia

⁴Department of Gynaecology, St Vincent's Hospital, Darlinghurst, Sydney, New South Wales, Australia

Correspondence

Bernard T. Haylen, MB, BS, MD, FRANZCOG, FRCOG, CU, Department of Gynecology University of New South Wales Sydney, Australia.
Email: bernard@haylen.co

Abstract

Aim: The mid-vagina (MV) represents Level II of the vagina. The surgical anatomy of the MV has not been recently subject to a comprehensive examination and description. MV surgery involving anterior and posterior colporrhaphy represents a key part of surgery for a majority of pelvic organ prolapse (POP).

Methods: Literature review and surgical observations of many aspects of the MV were performed including MV length and width; MV shape; immediate relationships; histological analysis; anterior and posterior MV prolapse assessment and anterior MV surgical aspects. Unpublished pre- and postoperative quantitative data on 300 women undergoing posterior vaginal compartment repairs are presented.

Results: The MV runs from the lower limit of the vaginal vault (VV) to the hymen. Its length is a mean of 5 cm. Its shape in section overall is a compressed rectangle. Its longitudinal shape is created by its anterior and posterior walls being inverse trapezoid in shape. Histology comprises three layers: (i) mucosa; (ii) muscularis; (iii) adventitia. MV prolapse staging uses pelvic organ prolapse quantification (POP-Q). Anterior MV prolapse can be quantitatively assessed using POP-Q while posterior MV prolapse can be assessed with POP-Q or PR-Q. Around 50% of both cystocele and rectocele are due to VV defects. POP will increase anterior MV width and length. Native tissue anterior colporrhaphy is the current conventional repair with mesh disadvantages outweighing advantages. Posteriorly, Level II (MV) defects are far smaller (mean 1.3 cm) than Level I (mean 6.0 cm) and Level III (mean 2.9 cm).

Conclusion: An understanding of the surgical anatomy of the MV can assist anterior and posterior colporrhaphy. In particular, if VV support is employed, the Level II component of a posterior repair should be relatively small.

KEYWORDS

mid-vagina, surgical anatomy

1 | INTRODUCTION

The middle section of the vagina (mid-vagina [MV]) is otherwise known as Level II of the vagina¹ (Figure 1). The surgical anatomy of the MV has not been recently subject to a comprehensive examination and description. The MV commences posteriorly at the lower end of the vaginal vault (VV), that is, 2.5 cm down the posterior wall from the vaginal apex in the posterior fornix.^{1,2} It ends at the posterior aspect of the hymen, the latter included in Level II. The posterior mid-vaginal length (PMVL) should be the same before and after hysterectomy² as the uterus enters and is removed via the anterior fornix, with no significant immediate impact on the posterior compartment.²

The mean total vaginal length (TVL—posterior fornix to the posterior aspect of the hymen) has been noted to be 7.5 cm in a series of 300 consecutive women undergoing posterior repair.³ Thus, the mean PMVL is 5.0 cm (7.5–2.5 cm). The PMVL represents 66.6%, that is, two thirds of the TVL. The total posterior vaginal length

(TPVL—vaginal apex to anterior perineum) is a mean of 9.2 cm³ as it includes a mean of 1.8 cm for the length of the posterior vestibule.⁴ The MV (Level II) is thus the longest of the three vaginal sections.

Post-hysterectomy, the anterior vaginal length (AVL) is that between the anterior fornix next to the cervix down to the anterior aspect of the hymen.^{3,5} Post-hysterectomy, the AVL is that between the anterior aspect of the vaginal cuff and the anterior aspect of the hymen.

AVL is on average 6.1±1.3 cm in women with normal support and lengthened in women with a cystocele.⁵ As around 1.0–1.5 cm of the upper anterior vagina is involved in the makeup of the anterior fornix, that is, Level I vagina (VV²), the effective anterior mid-vaginal length (AMVL) would be close to 5.0 cm, similar to the PMVL.

There are different methods of assessing vaginal width. Using magnetic resonance imaging (MRI) studies, vaginal width was noted to be largest in the proximal vagina (3.25 cm), decreasing as it passed through the pelvic diaphragm (2.78 cm), and smallest at the introitus

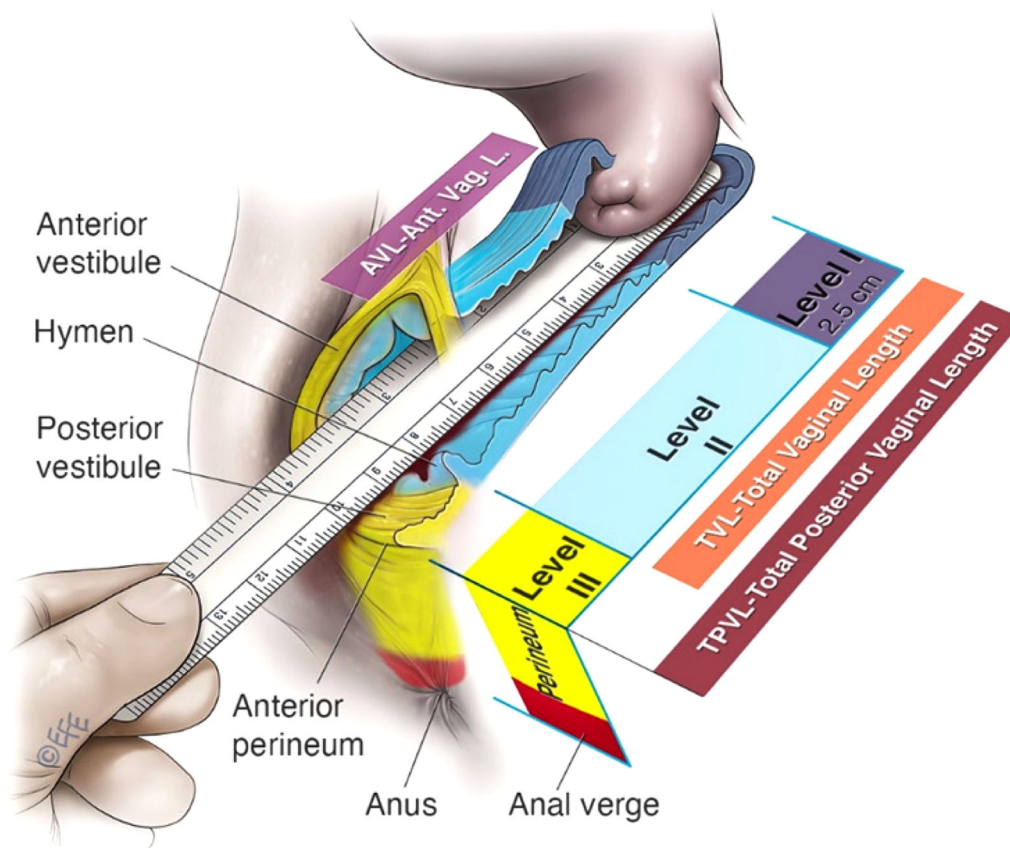


FIGURE 1 The mid-vagina is Level II of the vagina¹

(2.6 cm).⁶ Using vinyl polysiloxane casts, vaginal widths were found to be between 4.8 and 6.3 cm.⁷ A simple digital intraoperative assessment (lithotomy position) would support the width of the anterior and posterior walls being around two fingers (3.5 cm wide approximately) at the level of the hymen (inferior aspect of Level II). It expands to 2 ½ fingers (4.5 cm wide approximately) in the upper part of the MV. The lateral walls are around 1½ fingers (or 2.5 cm) in an anteroposterior direction (Figure 2).

2 | GROSS ANATOMY OF THE MV

The vagina has been referred to as a fibromuscular “tube,”⁸ the latter defined as something “long, hollow and cylindrical and here flexible.”⁹ From the measurements above, we see the vagina, not as a “tube,” but rather as a “compressed rectangle” (Figure 2). All walls are compressed, unlike the VV, which can be kept partially open by the presence of the cervix (Figure 1). As noted above, the anterior and posterior walls widen more proximally, similar to an inverse trapezoid (Figure 3), as has been described for the shape of the perineum.⁴

These clinical findings agree with previous MRI findings^{10–12} that the anterior vaginal wall is trapezoid in shape with the narrow part at the pubis. We suggest the posterior wall is also inverse trapezoid in shape, narrow close to the hymen, and gradually widening up to the border with the VV (Figure 3). We support the theory¹² that this proximal widening is due, in part, to the influence of the VV supports, the cardinal and uterosacral ligaments (CL and USL)^{2,12} and in part to the bulk of the cervix pre-hysterectomy.

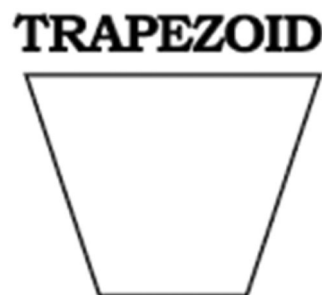

FIGURE 3 Inverse trapezoid

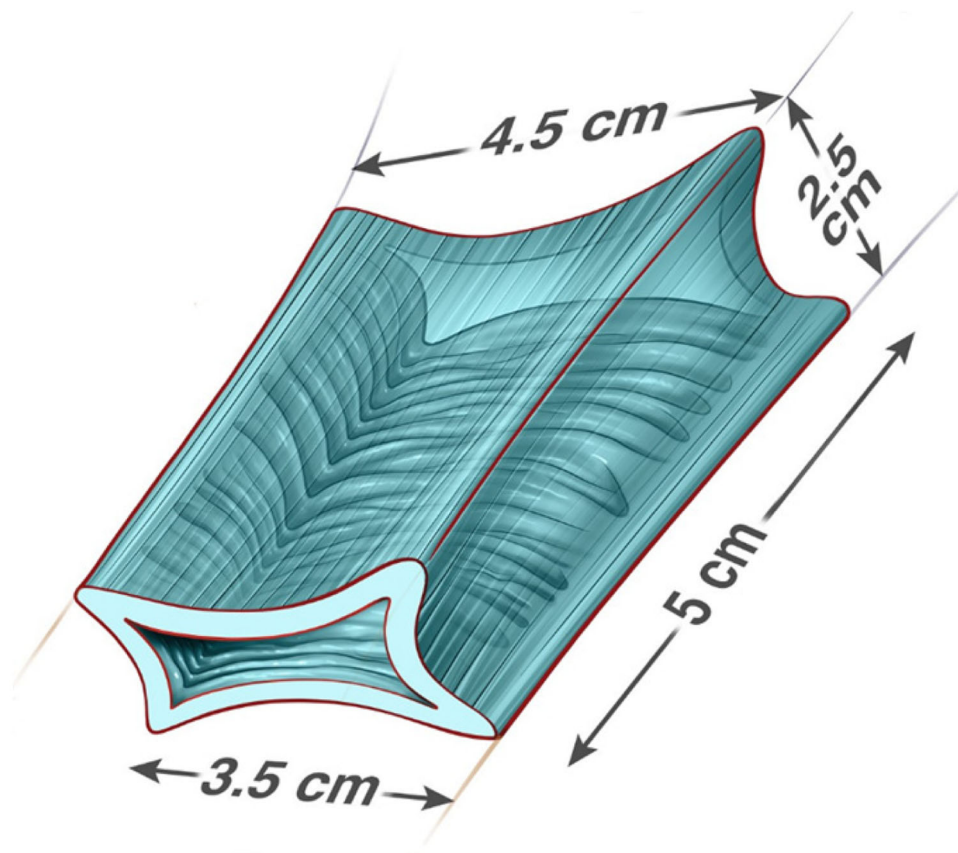


FIGURE 2 Compressed rectangular shape of the mid-vagina with trapezoid shape for the anterior and posterior vaginal walls: (i) supero-inferior length a mean 5 cm; (ii) superior width (adjacent to Level I—VV) is around 4.5 cm; (iii) inferior width (adjacent to the hymen and Level III) is around 3.5 cm. Hymen is not included in the figure

The vagina comes from the Latin for “sheath,” an organ of copulation that receives the penis during sexual intercourse.¹³ The MV thus provides a major role in accommodating the penis during copulation. The average length of the erect penis is 13.0–14.0 cm (5.1–5.5 in.)¹⁴ The TVL was reported by Masters and Johnson¹⁵ to be 7–8 cm (identical to the 7.5 cm TVL above) increasing by around 53% to 11–12 cm in the stimulated state.

3 | RELATIONSHIPS OF THE MV (Figures 4-6)

Anterior vaginal wall: Is in direct contact with the bladder base, bladder neck, and urethra.

Posterior vaginal wall: Is in direct contact with the rectum.

Lateral vaginal walls: Interface with the pelvic floor. Musculofascial extensions from the levator ani support the MV.

4 | HISTOLOGY OF THE MV⁸

The MV is a fibromuscular structure with three layers: (i) mucosa; (ii) muscularis; (iii) adventitia. It is kept moist by mucus produced by the cervical glands. The histology is non-controversial (Figure 7).

• Mucosa⁸: Contains numerous transverse folds (rugae). Layers are: (a) Stratified squamous nonkeratinized

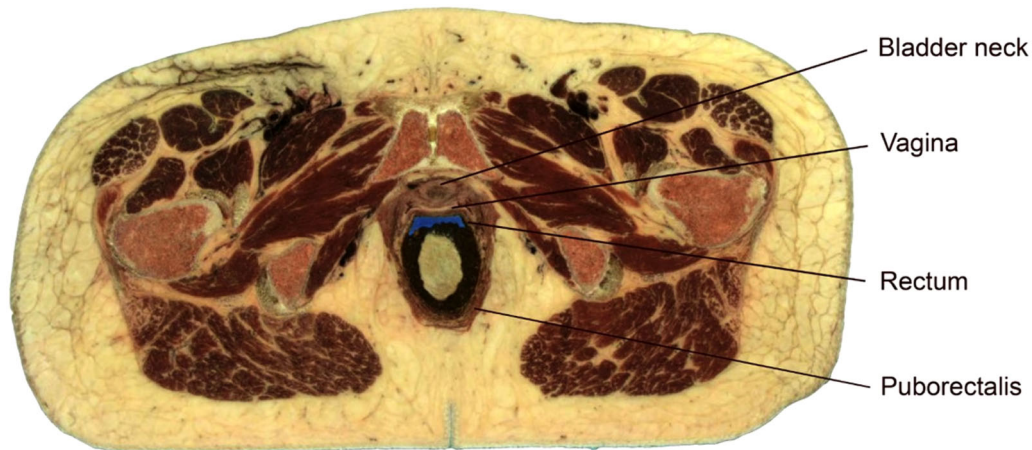


FIGURE 4 Axial view of the pelvis (Visible Human Project, National Library of Medicine, NLM. USA—with permission)

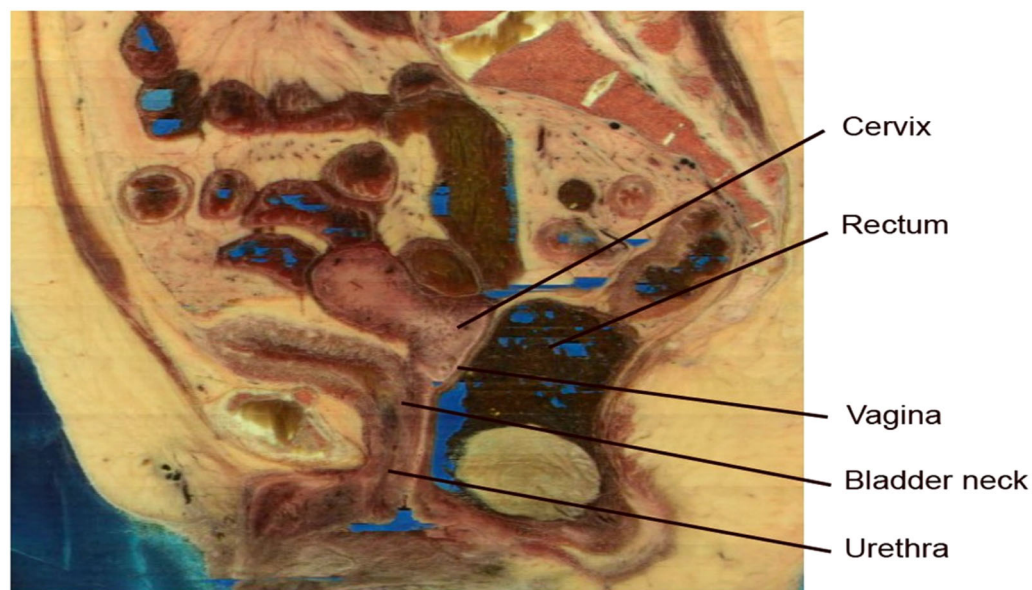


FIGURE 5 Sagittal view of the pelvis (Visible Human Project, National Library of Medicine, NLM. USA—with permission)

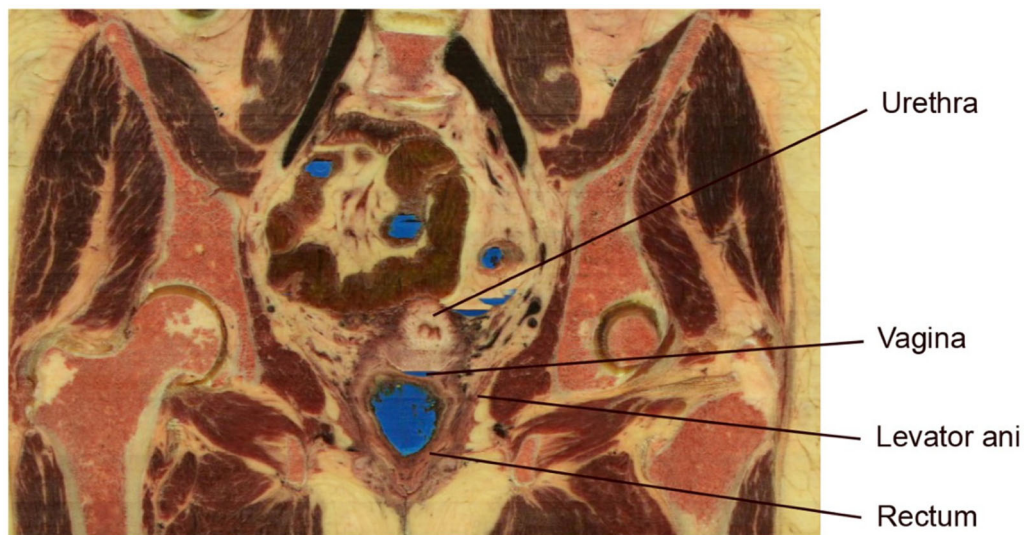


FIGURE 6 Coronal view of the pelvis (Visible Human Project, National Library of Medicine, NLM. USA—with permission)

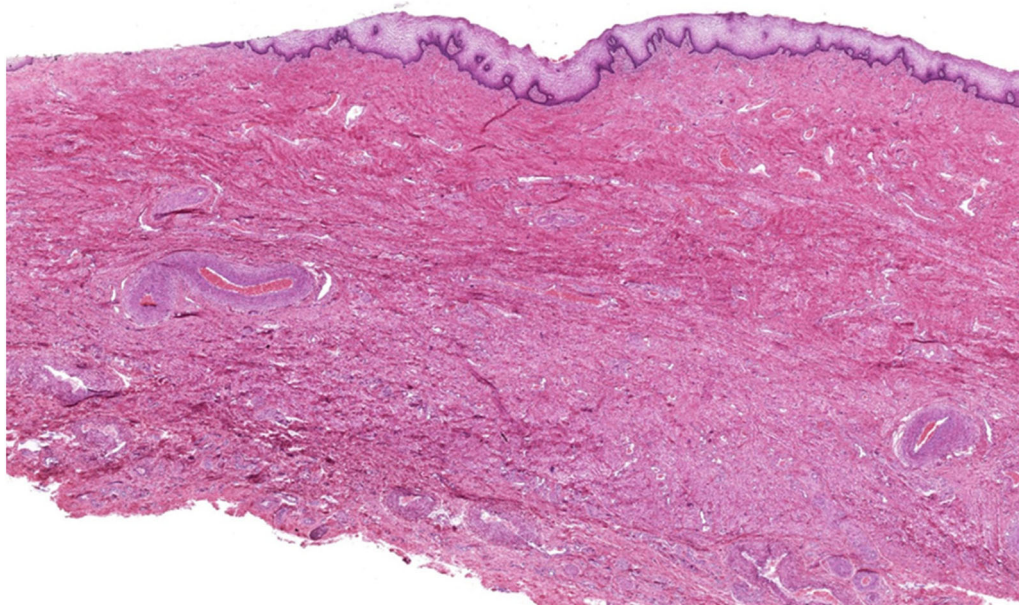


FIGURE 7 Vaginal histology⁸: “HistologyGuide. com. T. Clark Brelje and Robert L. Sorenson, University of Minnesota, Minneapolis, MN” (with permission from Dr Brelje)

epithelium with estrogen promoting the storage of glycogen in the upper and middle layers; (b) Lamina propria: dense irregular connective tissue rich in collagen and connective tissue. No glands are present.

- Muscularis⁸: Composed of two indistinct layers of smooth muscle: (a) Inner circular layer; (b) Outer much thicker longitudinal layer.

- Adventitia⁸: Inner layer of dense connective tissue and outer layer of loose connective tissue.

The vaginal wall is only a few mm thick, 2.5–3.5 mm in one series where measurement was by ultrasound.¹⁶ One study denied the MV was thinner in

the presence of POP¹⁷ though another series shows a thinning from POP Stage I to II, then and an increase in thickness to Stage III.¹⁶ This is however strong. The combined muscularis and adventitia layers can support an additional layer of plicatory sutures during anterior colporrhaphy. This would occur after the insertion of the prevesical plicatory sutures and before vaginal skin closure. This would reduce the tension on the skin closure both intraoperatively and postoperatively. The first author has found it a useful additional surgical step, to increase the anterior colporrhaphy from two to three layers.

5 | MID-VAGINAL PROLAPSE

The MV is where all aspects of POP are first revealed. The two aspects of POP arising in the MV are cystocele anteriorly and rectocele posteriorly. These MV defects, being closer to the vaginal introitus, naturally are generally more obvious than Level I defects (uterine and VV prolapse). Studies have shown that around half of the cystocele¹² and 55% of rectocele is due to vaginal vault descent.³ Other clinical studies support these findings.^{18,19} Level I descent can be more difficult to assess clinically; traction of the Level I areas under anesthetic can be more accurate.

Gross staging of MV prolapse can be obtained clinically using the POP-Q^{1,20} (Figure 8)

Stage 0: No prolapse is demonstrated.

Stage I: Most distal portion of the prolapse is more than 1 cm above the level of the hymen.

Stage II: The most distal portion of the prolapse is situated between 1 cm above the hymen and 1 cm below the hymen.

Stage III: The most distal portion of the prolapse is more than 1 cm beyond the plane of the hymen but everted at least 2 cm less than the total vaginal length.

Stage IV: Complete eversion or eversion at least within 2 cm of the total length of the lower genital tract is demonstrated.

6 | ANTERIOR MID-VAGINAL POP ASSESSMENT^{1,20} — CYSTOCELE^{1,2}

There is only one schema for quantifying anterior MV prolapse—POP-Q.^{1,20} This can be used either clinically or intraoperatively with the limitation that no instrumentation can be used clinically (Figures 9A, B).

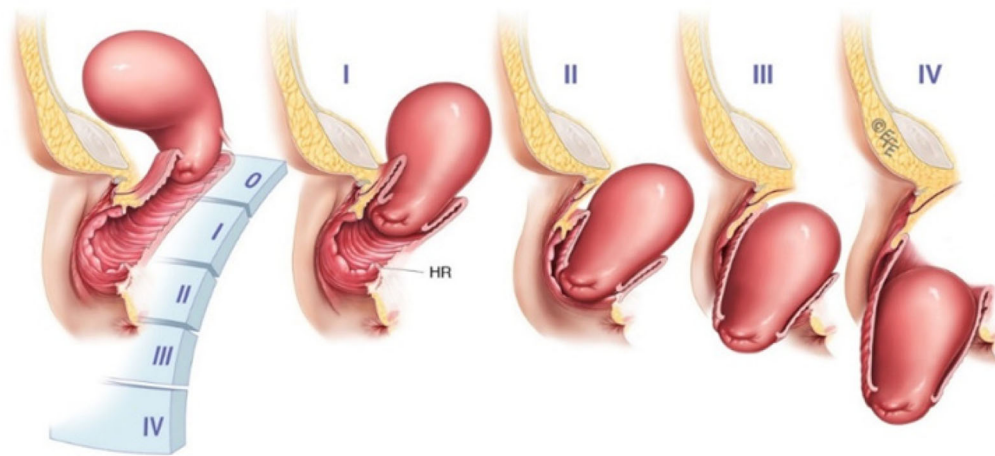


FIGURE 8 POP-Q staging of mid-vaginal prolapse

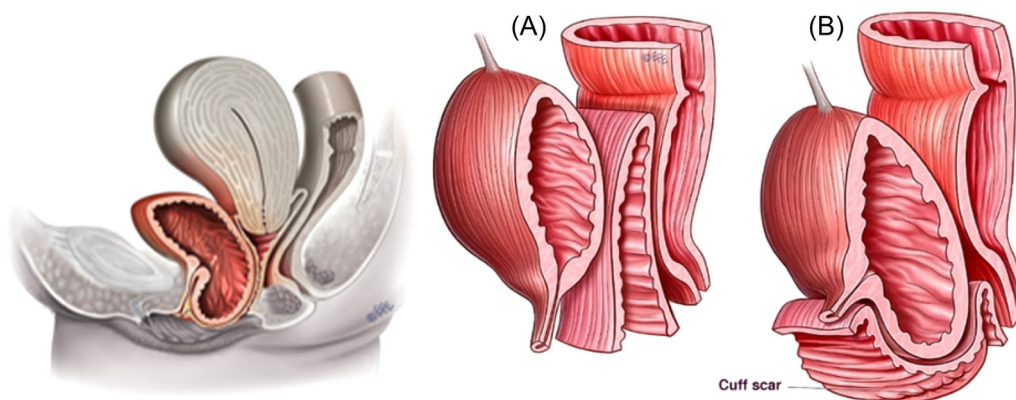


FIGURE 9 (A) (Left)¹ cystocele seemingly without major uterine or vaginal vault descent¹; (B) (Far right)² cystocele largely related to vaginal vault descent (NB cuff scar)^{1,2}

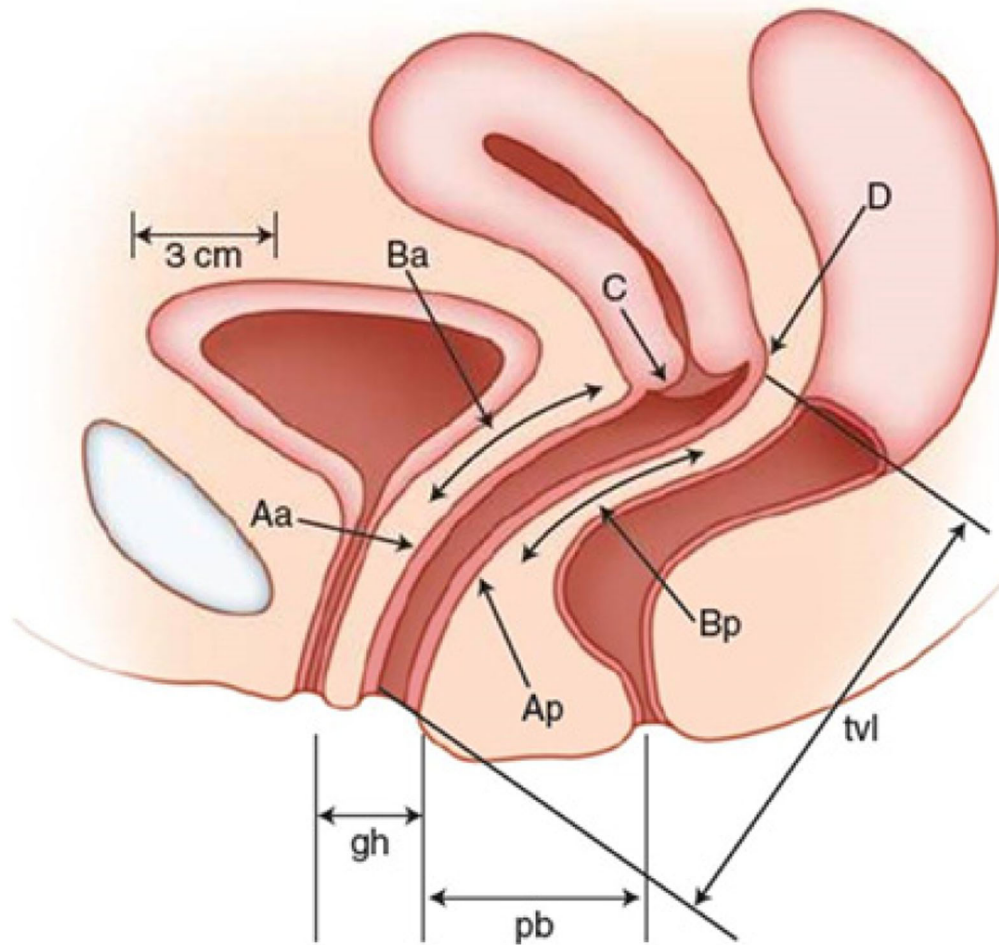


FIGURE 10 POP-Q Schema¹: (Anteriorly) Points Aa and Ba as well as Point C are relevant to anterior mid-vaginal prolapse; (Posteriorly) Points Ap and Bp as well as Point C are relevant to posterior mid-vaginal prolapse

- **Point Aa:**^{1,20} A point located in the midline of the anterior vaginal wall three 3 cm proximal to the external urethral meatus (shortened definition).
- **Point Ba:**^{1,20} A point that represents the most distal (i.e., most dependent) position of any part of the upper anterior vaginal wall from the vaginal cuff or anterior vaginal fornix to Point Aa (shortened definition).
- **Point C:**^{1,20} A point that represents either the most distal (i.e., most dependent) edge of the cervix or the leading edge of the vaginal cuff (hysterectomy scar) after total hysterectomy (Figure 10).

- **Point Ap:**^{1,20} A point located in the midline of the posterior vaginal wall 3 cm proximal to the hymen (shortened definition).
- **Point Bp:**^{1,20} A point that represents the most distal (i.e., most dependent) position of any part of the upper posterior vaginal wall from the vaginal cuff or posterior vaginal fornix to Point Ap (shortened definition) (Figures 11A, B).

7 | POSTERIOR MID-VAGINAL POP ASSESSMENT—RECTOCELE^{1,2}

There are two schemas for assessing posterior MV prolapse: (i) POP-Q^{1,20} and (ii) PR-Q^{3,21}

7.1 | PR-Q assessment (intraoperative)^{1,3,21}

- **MVL (vaginal vault undisplaced)**^{1,3,21}: Laxity of the vaginal mucosa (anterior traction) midpoint in the vagina super-posteriorly and in the midline with the VV held in an undisplaced position (similar to that after VV fixation).

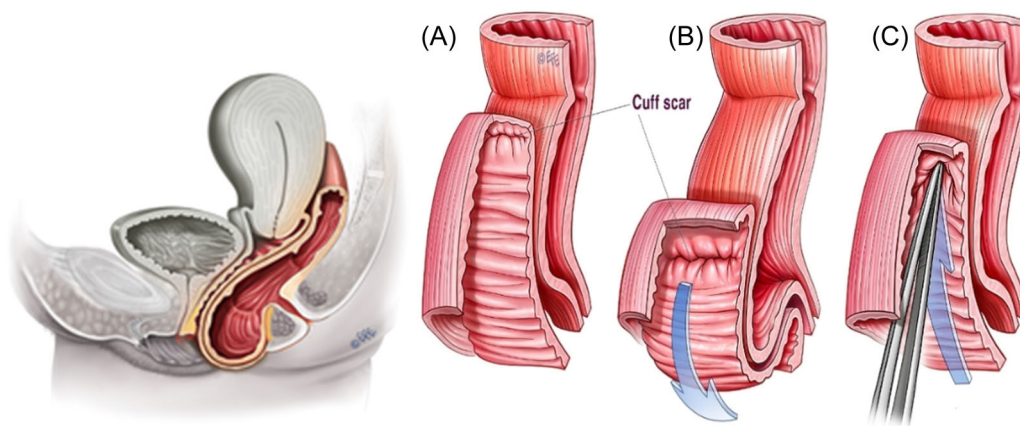


FIGURE 11 (A) (Left¹) Rectocele seemingly without major uterine or vaginal vault descent; (B) (Right middle²) Rectocele largely related to vaginal vault descent (NB: cuff scar)

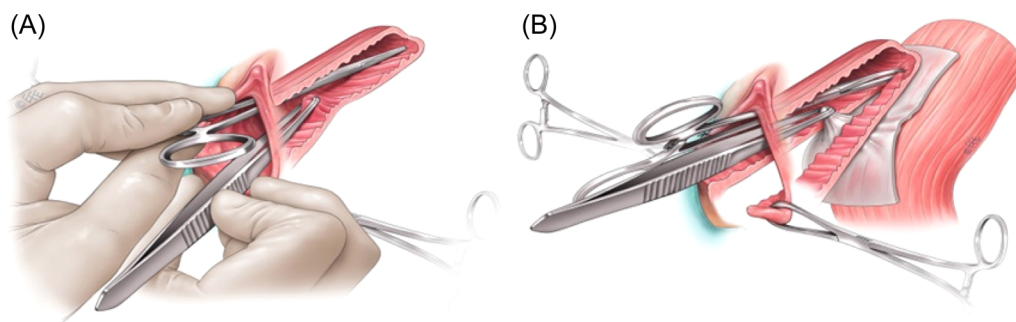

FIGURE 12 (A) (Left)^{1,3,21}: Mid-vaginal laxity (vaginal vault undisplaced), (B) (right)^{1,3,21}: Recto-vaginal fascial laxity

- *Recto-vaginal fascial laxity (RVFL)*^{1,3,21}: Laxity of the rectovaginal fascia (anterior traction) midpoint in the vagina super-posteriorly (mucosa opened) and in the midline with the vaginal vault held in an undisplaced position (Figures 12A, B).

8 | SURGICAL ASPECTS OF ANTERIOR MID-VAGINAL POP DEFECTS

Anterior colporrhaphy involves the reduction of the bulk of the prolapse (tissue reduction). There are not the convenient ligaments (e.g., sacrospinous ligament—SSL) that can be used for posterior repairs, though anterior approaches incorporating the SSL²² or USL are being used.²³ These techniques can provide combined Level I and II support. Native tissue surgery involving a multilayer repair is, however, the traditional and still most popular approach.¹ The excision of the redundant anterior vaginal wall is generally considered as part of the tissue reduction process.

Section 8 of Haylen et al.¹ contains a summary of current surgical techniques for repairing anterior MV

POP defects.¹ Newer techniques for anterior colporrhaphy are regularly trialed.^{24,25}

For around 15 years from 2005, mesh was employed in an attempt to enhance the strength of the anterior colporrhaphy. It is not a feature of this article to explore this aspect except to note two summary conclusions. The first of these is that “polypropylene anterior compartment mesh offers improved objective and subjective outcomes compared with native tissue repair; however, these benefits must be considered in the context of increased morbidity associated with the mesh.”²⁶ A second conclusion is this, “current evidence does not support the use of a mesh repair compared with a native tissue repair for anterior compartment prolapse owing to increased morbidity.”²⁷

As noted above and by Weber and Walters,²⁸ the vagina has three layers: mucosa, muscularis, and adventitia; there is no vaginal “fascia.” Vaginal support is provided by the underlying levator ani muscles and by lateral connective-tissue attachments at the arcus tendineus fasciae pelvis or “white line.” Dissection during anterior colporrhaphy splits vaginal muscularis, and repair involves plication of the muscularis and adventitia (not vaginal “fascia”) in the midline.^{28,29} Paravaginal

repair restores the lateral attachments to the pelvic sidewall at the white line.²⁸

Cystocele formation increases the AVL (Figure 1).¹⁰ Similarly repair of cystocele repair reduces the AVL by 28% in one series.¹⁰ It also appears to increase the MV width by 28% from 3.2 ± 0.9 cm in those with normal support to 4.1 ± 1.0 cm in those with prolapse.³⁰

There appears to be a dearth of studies of the anatomical effects of anterior colporrhaphy using POP-Q quantitative markers.

A recent review³¹ of 40 randomized controlled trial on anterior colporrhaphy showed not only wide differences in each step of the procedure but also in perioperative care, anesthesia, anatomical structures used, and surgeons' experience, all important factors influencing the outcome of the operation. Standardization of surgery is cited as important with exact and reproducible descriptions of the procedure and assessments of surgical performance.³¹ We believe this is possible in the posterior compartment, as discussed below.

9 | SURGICAL ASPECTS OF POSTERIOR MID-VAGINAL DEFECTS

There are more definitive quantitative data on the effects on posterior MV POP defects (rectocele) by posterior native tissue vaginal repair, with and without VV

support. Mesh is also currently not recommended in the posterior compartment.³²

Table 1 outlines the preoperative³ and postoperative (unpublished) data from a cross-sectional study of 300 consecutive posterior repairs (PRs), mostly following prior or concomitant hysterectomy and concomitant anterior colporrhaphy. All preoperative POP-Q,³ and PR-Q³ measurements used in the study were taken immediately before the PR, that is, at the end of any concomitant prolapse surgeries. Postoperative measurements were taken at the end of the PR surgery. At this point, vaginal skin closure prevented measurement of the postop RVFL. There were no patients excluded from a PR.

Table 2, using the same group of 300 women in Table 1 (unpublished) shows (i) the PR-Q defect marker; (ii) the action used in repairing the defect; (iii) the percentage of times the action was used; (iv) the result of that action; (v) equivalent POP-Q result of that surgical action.

The initial conclusion (from Table 1) is that the MV defects (Level II) are the smallest defects, provided the VV is reduced to its undisplaced position. The VV (Level I) defects (posterior vaginal vault descent [PVVD]^{1,2}—6 cm, Point C—minus 0.9 cm) are the largest defects. The Level III defects (perineal gap [PG]^{1,4}—2.9 cm, genital hiatus [GH]^{1,4}—3.7 cm) are the next largest. The Level II defects (MVL—1.3 cm, RVFL—1.1 cm, Ap—1.0 cm, Bp—1.0 cm) are relatively small, again provided the VV

TABLE 1 Pre-op and post-op results for (i) PR-Q and (ii) POP-Q surgical markers

Variable	Pre-op				Post-op			
	Mean	SD	Min	Max	Mean	SD	Min	Max
PR-Q posterior prolapse markers (cm)								
PG - Level III	2.9	1.0	0.3	6.0	0.0	0.0	0.0	0.0
PVVD (overall)—Level I	6.0	2.0	0.3	15.0	0.2	0.5	0.0	2.0
PVVD (SSC performed)—Level I	6.5	2.0	4.5	15.0	0.06	0.1	0.0	1.0
PVVD (no SSC performed)—Level I	3.5	1.0	0.3	5.5	0.6	0.4	0.0	2.0
MVL, undisplaced—Level II	1.3	0.6	0	3.5	0.2	0.1	0.0	0.7
Recto-vaginal fascial laxity (RVFL)—Level II	1.1	0.7	0	4.0	n/a		n/a	n/a
POP-Q posterior prolapse markers (cm)								
Point C - Level I	-0.9	2.3	-8.0	8.0	-6.3	1.4	-2.5	-10.0
Point Ap - Level II	1.0	1.4	-3.0	5.0	-2.9	0.3	-1.0	-3.0
Point Bp - Level II	1.0	1.5	-3.0	6.0	-2.9	0.3	-1.0	-3.0
Genital hiatus (GH) - Level III	3.7	0.9	1.5	6.5	2.6	0.7	1.5	4.5

Abbreviations: Min, minimum; Max, maximum; MVL, mid-vaginal laxity; Pre-op, preoperative; Post-op, postoperative; PG, perineal gap; PVVD, posterior vaginal vault descent; SD, standard deviation.

TABLE 2 PR-Q markers, guidelines for repair action, percentage of cases repair action used; results of surgical action (PR-Q); results of surgical action (POP-Q)

PR-Q marker	Our guideline for repair action	Percentage of cases action used	Result of action	POP-Q equivalent level
PG ⁴	Excise PG ⁴	100% ⁴	100% excised ⁴	30% ↓ GH ⁴
PVVD ²⁻³	SSC if PVVD > 5 cm	84% SSC (mean preoperative 6.0 cm to mean 0.2 cm postoperative)	SSC performed— 99% ↓ PVVD. No SSC— 83% ↓ PVVD	Point C from mean minus 0.9 to mean minus 6.3
MVL—vault undischased	Vaginal skin excision just under half MVL bilaterally	96% (67% of whom requiring excision of under 0.5 cm bilaterally)	85% mean reduction in MVL (1.3 cm preoperative to 0.2 cm postoperative)	Points Ap, Bp from 1.0 to minus mean 2.9
RVFL	Plicatory sutures if RVFL > 0.5 cm	76% (mean preoperative 1.1 cm)	Optimize plication though postoperative RVFL not applicable	

Abbreviations: GH, genital hiatus; MVL, mid-vaginal laxity; PG, perineal gap; RVFL, recto-vaginal fascial laxity.

descent is reduced. The cut-off used for the performance of a sacrospinous colpopexy (SSC) for VV support was a PVVD of 5 cm or more.

The second conclusion (from Table 2) is that there are high cure rates (99% reduction in PVVD—6.5–0.06 cm mean) for Level 1 defects in those having VV support using a SSC. Also from Table 2, there is a 100% cure of the Level III defect⁴ by excision of the PG and repair.⁴

Specific to Level II (Tables 1 and 2), the MVL was initially small (mean 1.3 cm) reducing to a mean of 0.2 cm (85% reduction) with under 0.5 cm bilateral skin trimming in 67% of cases. RVFL was again small (mean 1.1 cm), 76% requiring prerectal plicatory sutures.

These results confirm that the “cure” of a “rectocele” does not need to involve extensive dissection or layered repair of a perceived large Level II¹ defect of rectovaginal fascia (septum)³³⁻³⁵ and accompanying extensive excision of vaginal skin laxity, with the increased risk of dyspareunia.³² If the Level I and III defects were simultaneously addressed, repair work at Level II involved smaller dissection and relatively limited repair work. Whilst vaginal skin excision was required in 96% of cases, in the majority (67%), it was limited to under 0.5 cm bilaterally, in our view, reducing the risk of dyspareunia.³³

10 | CONCLUSIONS

The MV represents Level II of the vagina between the VV (Level I) and the vaginal introitus (Level III). The MV runs from the lower limit of the VV to include the hymen. Its length is a mean of 5 cm. Its shape in section overall is a compressed rectangle. Its longitudinal profile is created by its anterior and posterior walls being inverse trapezoid in shape, approximately 3.5 cm wide at the hymen and 4.5 cm at the border with the VV. Lateral walls are approximately 2.5 cm in the anteroposterior direction. Histology comprises three layers: (i) mucosa; (ii) muscularis (iii) adventitia. Immediate relations are pelvic floor musculature and lateral connective tissue to the sidewall of the pelvis, bladder anteriorly, and the rectum posteriorly.

MV surgery involving anterior and posterior colporrhaphy represents a key part of surgery for a majority of POP. MV prolapse staging uses POP-Q. Anterior MV prolapse can be quantitatively assessed using POP-Q while posterior MV prolapse can be quantitatively assessed with POP-Q or PR-Q. Around 50% of both cystocele and rectocele are due to VV defects.

POP will increase anterior MV width and length. Native tissue anterior colporrhaphy is the current conventional repair with mesh disadvantages outweighing advantages.

Posteriorly, Level II (MV) defects are far smaller (mean 1.3 cm) than Level I (mean 6.0 cm) and Level III (mean 2.9 cm). An understanding of the surgical anatomy can assist anterior and posterior colporrhaphy. In particular, if VV (Level I) support is employed and suitable perineorrhaphy⁴ performed (Level III), the Level II component of a posterior repair should be relatively small.

The MV (Level II) here is the same area, a mean of 5 cm in length, as the proposed combined Levels II and III in an earlier description.³⁶ Level III currently refers to the vaginal introitus, below the hymen, incorporating anterior and posterior vestibules and perineum^{1,4} (Figure 1).

AUTHOR CONTRIBUTIONS

Bernard T. Haylen, Dzung Vu, Audris Wong, and Sarah Livingstone contributed to the development concept, writing, and review of the paper.

ACKNOWLEDGEMENTS

The fine diagrams of Levent Efe (levent@leventefe.com.au) are acknowledged. The assistance of Dr John McNamara in many aspects of this article was most valuable. Open access publishing facilitated by University of New South Wales, as part of the Wiley - University of New South Wales agreement via the Council of Australian University Librarians.

CONFLICT OF INTEREST

The authors declare no conflict of interest.

DATA AVAILABILITY STATEMENT

The data that support the findings of this study are available from the corresponding author upon reasonable request.

ORCID

Bernard T. Haylen  <https://orcid.org/0000-0001-5436-2435>

REFERENCES

- Haylen BT, Maher CF, Barber MD, et al. An International Urogynecological Association (IUGA)/International Continence Society (ICS) Joint report on the terminology for pelvic organ prolapse. *Neurouro Urodyn*. 2016;35(2):137-168.
- Haylen BT, Vu D. Surgical anatomy of the vaginal vault. *Neurouro Urodyn*. 2022. <https://doi.org/10.1002/nau.24963>
- Haylen BT, Naidoo S, Kerr SJ, Chiu HJ, Birrell W. Posterior vaginal compartment repairs: where are the main anatomical defects? *Int Urogynecol J*. 2016;27(5):741-745.
- Haylen BT, Vu D. Surgical anatomy of the vaginal introitus. *Neurouro Urodyn*. 2022. [doi:10.1002/nau.24961](https://doi.org/10.1002/nau.24961)
- Swenson CW, Simmen AM, Berger MB, Morgan DM, DeLancey JOL. The long and the short of it: anterior vaginal wall length before and after vaginal repair. *Int Urogynae J*. 2015;26(7):1035-1039.
- Barnhart KT, Izquierdo A, Pretorius ES, Shera DM, Shabbout M, Shaunik A. Baseline dimensions of the human vagina. *Hum Reprod*. 2006;21(6):1618-1622. [doi:10.1093/advances/nmx009](https://doi.org/10.1093/advances/nmx009)
- Pendergrass PB, Reeves CA, Belovicz DJ, Molter DJ, White JH. The shapes and the dimensions of the human vagina as seen in three-dimensional vinyl polysiloxane casts. *Gynecol Obstet Invest*. 1996;42(3):178-182.
- Sorensen RL, Bretje TC. *Atlas of Human Histology* (Chapter 18). 2014. University of Minnesota Bookstore.
- Oxford Concise English Dictionary*. As stated Clarendon Press; 1995:P1500.
- Hsu Y, Chen L, Summers A, Ashton-Miller JA, DeLancey JOL. Anterior vaginal wall length and degree of anterior compartment prolapse seen on dynamic MRI. *Int Urogynecol J*. 2008;19(1):137-142.
- DeLancey JO. Fascial and muscular abnormalities in women with urethral hypermobility and anterior vaginal wall prolapse. *Am J Obstet Gynecol*. 2002;187:93-98.
- Summers A, Winkel LA, Hussain HK, DeLancey JOL. The relation between anterior and apical compartment support. *Am J Obstet Gynecol*. 2006;194:1438-1443.
- Stedmans Medical Dictionary*. 28th ed. As stated Lippincott, Williams & Wilkins; 2006: P995-P2083.
- King BM. Average—size erect penis: fiction, fact and the need for counselling. *J Sex Marital Ther*. 2021;47(1):80-89. [doi:10.1080/0092623X.2020.1787279](https://doi.org/10.1080/0092623X.2020.1787279)
- Masters WH, Johnson VE. *Human Sexual Response*. Little, Brown; 1966.
- Bray R, Derpapas A, Fernando R, Khullar V, Pancy DC. Does the vaginal wall thin as prolapse increases? *Int Urogynecol J*. 2017;28(3):397-402.
- Hsu Y, Chen L, DeLancey JOL, Ashton-Miller JAL. Vaginal thickness, cross-sectional area, and perimeter in women with and those without prolapse. *Obstet Gynecol*. 2005;105:1012-1017.
- Lauder JL, Park JL, Ellison RL, et al. The role of apical vaginal support in the appearance of anterior and posterior vaginal prolapse. *Obstet Gynecol*. 2008;111(1):152-157.
- Rooney K, Kenton K, Mueller ER, Fitzgerald MP, Brubaker L, Am J. Advanced anterior vaginal wall prolapse is highly correlated with apical prolapse. *Obstet Gynecol*. 2006;195(6):1837-1840.
- Bump RC, Mattiasson A, Bø K, et al. The standardization of female pelvic organ prolapse and pelvic floor dysfunction. *Am J Obstet Gynecol*. 1996;175(1):10-17.
- Haylen BT, Avery D, Chiu T, Birrell W. Posterior repair quantification (PR-Q) using key anatomical indicators (KAI). *Int Urogynecol J*. 2014;25(12):1665-1772.
- Balsamo R, Uricchio F, Costantini, et al. Anterior colporrhaphy and sacrospinous hysteropexy in women with pelvic organ prolapse: urodynamic findings and functional outcomes. *Eur J Obstet Gynecol Reprod Biol*. 2022;271:255-259.

23. Haylen BT, Yang V, Vu D, Tse K. Midline uterosacral plication anterior colporrhaphy combo (MUSPACC): preliminary surgical report. *Int Urogynecol J*. 2011;22:69-75.
24. Lacorre A, Vidal F, Campagne-Loiseau S, et al. Protocol for a randomized controlled trial to assess two procedures of vaginal native tissue repair for pelvic organ prolapse at the time of the questioning on vaginal prosthesis: the TAPP trial. *Trials*. 2020;21:624. doi:10.1186/s13063-020-04512-x
25. Cosson M, Collinet P, Ocelli B, Narducci F, CreÂpin G. The vaginal patch plastron for vaginal cure of cystocele preliminary results for 47 patients. *Eur J Obstet Gynecol Reprod Biol*. 2001;95:73-80.
26. Maher C. Anterior vaginal compartment surgery. *Int Urogynecol J*. 2013;24(11):1791-1802. doi:10.1007/s00192-013-2170-3
27. Maher C, Feiner B, Baessler K, et al. Surgery for women with anterior compartment prolapse. *Cochrane Database Syst Rev*. 2016;11(11):CD004014.
28. Weber AM, Walters MD. Anterior vaginal prolapse: review of anatomy and techniques for surgical repair. *Obstet Gynecol*. 1997;89(2):311-318.
29. Farrell SA, Dempsey T, Geldenhuys L. Histological examination of "fascia" used in colporrhaphy. *Obstet Gynecol*. 2001;98:794-798.
30. Larson KA, Luo J, Guire KF, Chen L, Ashton-Miller JA, DeLancey JOL. 3D analysis of cystoceles using magnetic resonance imaging assessing midline, paravaginal and apical defects. *Int Urogynaecol J*. 2012;23(3):285-293.
31. Halpern-Elenskaia K, Umek W, Bodner-Ader B, Hanzel E. Anterior colporrhaphy: a standardized operation? Systematic review of the technical aspects of a common procedure – randomized controlled trial. *Int Urogynaecol J*. 2018;29: 781-788.
32. Maher C, Feiner B, Baessler K, Christmann-Schmid C, Haya N, Brown J. Surgical management of pelvic organ prolapse in women. 2016. [cochrane.org/CD012376/MENSTR_surgical-management-pelvic-organ-prolapse-women](https://www.cochrane.org/CD012376/MENSTR_surgical-management-pelvic-organ-prolapse-women)
33. Francis WFA, Jeffcoate TNA. Dyspareunia following vaginal operations. *J Obstet Gynaecol Br Commonw*. 1961;68:1-10.
34. Richardson AC. The rectovaginal septum revisited: its relationship to rectocele and its importance in rectocele repair. *Clin Obstet Gynecol*. 1993;36:976-983.
35. Richardson AC. The anatomic defects in rectocele and enterocele. *J Pelv Surg*. 1995:214-221.
36. DeLancey JOL. Anatomical aspects of vaginal eversion after hysterectomy. *Am J Obst Gynecol*. 1992;166:117-124.

How to cite this article: Haylen BT, Vu D, Wong A, Livingstone S. Surgical anatomy of the mid-vagina. *NeuroUrol Urodyn*. 2022;41:1293-1304. doi:10.1002/nau.24994